

Early Loading of Interforaminal Implants Immediately Installed after Extraction of Teeth Presenting Endodontic and Periodontal Lesions

Roberto Villa, DDS;* Bo Rangert, PhD, MechEng[†]

ABSTRACT

Background: Infection in tooth extraction sites has traditionally been considered an indication to postpone implant insertion until the infection has been resolved.

Purpose: The aim of this study was to evaluate the survival rate of early-loaded implants placed immediately after extraction of teeth with endodontic and periodontal lesions in the mandible.

Materials and Methods: Twenty patients in need of mandibular implant treatment and with teeth showing signs of infection in the interforaminal area were included in the study. The patients received four to six implants (Brånemark System®, Nobel Biocare AB, Göteborg, Sweden) in or close to the fresh extraction sockets and received a provisional prosthesis within 3 days. Final prostheses were delivered after 3 to 12 months. The surgical protocol paid special attention to the preservation of high implant stability and control of the inflammatory response. The patients were followed up for 15 to 44 months.

Results: No implants were lost, resulting in a 100% survival rate. A mean marginal bone loss of 0.7 mm (SD 1.2 mm) was registered during the observation period. No signs of infection around the implants were detected at any follow-up visit.

Conclusion: A high survival rate can be achieved for immediately placed and early-loaded implants in the mandible despite the presence of infection at the extracted teeth.

KEY WORDS: immediate/early loading/function, immediate implant placement, implant placement in fresh sockets, infected extraction sites, infection, inflammatory response, tooth extraction

Immediate/early loading of implants in the completely edentulous mandible has demonstrated predictable results, similar to those of the traditional two-stage procedure, and is well accepted in the scientific literature.¹⁻⁸ The reduced treatment time achieved with immediate/early loading is an obvious advantage for the patient.

To reduce treatment times in indications in which tooth extraction precedes implant placement, it is sometimes desirable to install the implant immediately into the postextraction socket, without waiting for the site to heal. This treatment modality has received much attention in the literature,^{7,9-17} and when the implants are placed with a two-stage procedure into fresh extraction sockets, the results are generally good.⁹⁻¹³

Various studies have focused on the combined use of immediate postextractive implant placement and immediate/early loading in an attempt to further reduce treatment times.^{7,14-17} However, the clinical outcome of this treatment concept tends to vary. De Bruyn and Collaert reported a survival rate of 61% for early-loaded implants installed in postextraction sockets compared with 99.3% for healed sites.¹⁷ Balshi and Wolfinger and Chaushu and colleagues reported survival rates of 80% and 82.4%, respectively, for immediately loaded implants placed in fresh extraction sites.^{15,16} In contrast, encouraging results were reported by Cooper and colleagues and Grunder, who obtained survival rates of 100% and 97.3% respectively, for similar protocols in the mandible.^{7,14}

The presence of infection in a proposed implant site is today often seen as a contraindication for implant placement.¹⁸⁻²⁰ However, some authors have demonstrated that immediate implant placement in infected extraction sockets can be successful^{21,22} pro-

*Private practice, Biella, Italy; [†]Nobel Biocare AB, Göteborg, Sweden

Reprint requests: Dr. Roberto Villa, Via Duomo, 10, 13900 Biella, Italy; e-mail: r.villa@studiorobertovilla.it

©2005 BC Decker Inc

vided that careful preoperative care is granted. These findings are supported by results from experimental studies in dogs.^{23,24}

The natural healing process after tooth extraction normally takes care of a residual infection, especially if antibiotics are used. It can be hypothesized that the presence of an implant in such a site would not, per se, change that process. However, an infection increases the inflammatory activity, which may lead to increased bone resorption and increased risk of implant failure. Conventional granulation tissue removal, site curettage, and antibiotic treatment are believed to be effective in reducing the inflammatory activity. To counteract inflammation following implant insertion, an early onset of antibiotic treatment may be beneficial. Dent and colleagues reported a tendency to reduced implant failure when antibiotics were used preoperatively and in appropriate doses.²⁵

In addition to careful preoperative care, high initial implant stability seems to be an important prerequisite for the placement of implants into infected extraction sites, especially if immediate/early function is applied. Firm anchorage in the bone may be achieved by under-preparation of the implant site. Individual implant stability may also be improved by splinting; the splinted implants provide mutual support, which may counteract prosthetic mobility, thus stabilizing the individual implants themselves.^{26,27}

Based on the above considerations, the following hypothesis was formulated: with an appropriate biomechanical, surgical, and medical protocol, considering preservation of high implant stability and controlled inflammatory response, implants may be successfully osseointegrated when immediately placed and early loaded in postextraction sites.

The aim of this study was to test the above hypothesis by performing a clinical evaluation of early (within 3 days) loading of implants immediately placed in, or close to, extraction sockets of teeth showing advanced endodontic and periodontal lesions.

MATERIALS AND METHODS

From February 2001 to July 2003, 20 consecutive patients (10 men and 10 women; 49 to 70 years old) in need of partial or complete mandibular rehabilitation were enrolled. All patients were medically healthy. Seven patients were smokers, four of whom were considered heavy smokers (more than 15 cigarettes per

day). Ninety-seven implants with various surfaces, lengths, and diameters (Table 1) were placed in the mandible by the same surgeon. Ninety-three of the implants were installed in the interforaminal region, whereas four implants in three patients were installed posterior to the mental foramina.

The dentition in the opposing jaw varied (full or partial denture, implant-supported bridge, or natural teeth). Periodontal problems in the upper jaw and in the area of preserved teeth in the lower jaw were treated before implant placement.

Inclusion/Exclusion Criteria

The inclusion criteria were (1) the need for mandibular rehabilitation and (2) the presence of residual teeth in the interforaminal area with clinical and radiographic evidence of advanced endodontic and periodontal lesions judged to be no longer recoverable and unable to support a fixed prosthesis (Figure 1).

Surgical Protocol

Two days before surgery, the patients were administered antibiotic prophylaxis with amoxicillin 500 mg three times daily (Zimox, Pharmacia Italia, Milano, Italy); this daily dosage was maintained up to 5 days after surgery. On the day of treatment and after tooth extraction, a full-thickness flap was raised and the mental foramen was located. Granulation tissue in the sockets was removed, alveolar bone curettage was performed,

TABLE 1 Number of Implants of Different Types and Lengths

Implant Type	Implant Length, mm				Total
	18	15	13	8.5	
Standard, 3.75, RP	5	4	—	—	9
Standard, 4.0, RP	—	1	—	—	1
Mk II, 3.75, RP	1	—	—	—	1
Mk III, 3.75 RP	28	10 + (2)	—	—	38 + (2)
Mk III, 4.0, RP	5	1	—	—	6
TiUnite, Mk III, 3.75, RP	11	7	—	—	18
TiUnite, Mk III, 4.0, RP	17	1 + (1)	1	(1)	19 + (2)
TiUnite, Mk III, 3.3, NP	—	1	—	—	1
Total	67	25 + (3)	1	(1)	93 + (4)

Numbers in brackets correspond to implants that were not placed in the interforaminal area. NP = narrow platform; RP = regular platform

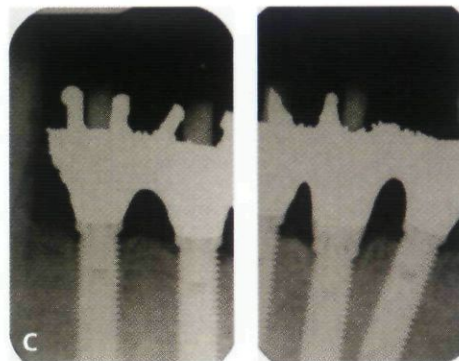
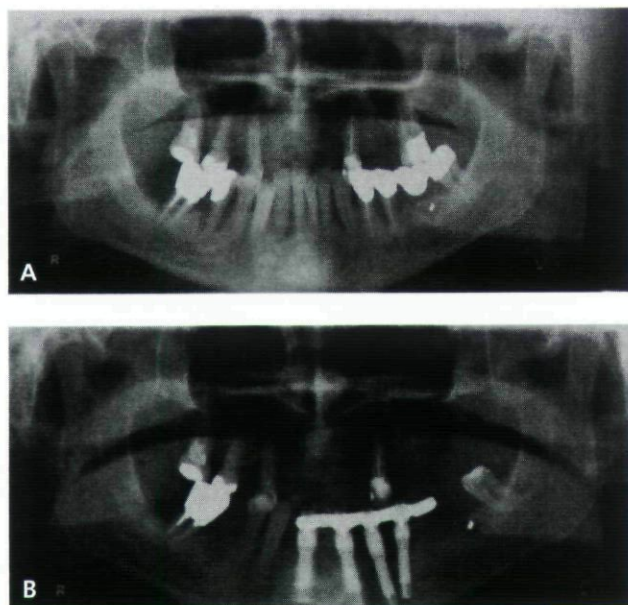


Figure 1 A, Pretreatment panoramic radiograph from a 60-year-old male patient showing advanced periodontal lesions involving most of the remaining mandibular teeth. Teeth 43 and 44 were judged to be recoverable and were therefore not extracted. Two remaining molars were also left, according to the wish of the patient. B, Panoramic radiograph 10 months post-surgery. C, Periapical radiographs 24 months postsurgery showing good bone healing around the four interforaminal implants.

and the implant sites were irrigated with an antibiotic solution (Rifocin, rifamycin sodium, Gruppo Lepetit S.P.A., Anagni [FR], Italy). Apical fistulae were present in two patients, and in four patients, pus surged from the surgical incision.

Brånemark System® implants (Nobel Biocare AB, Göteborg, Sweden) were installed in a one-stage procedure. The implants were inserted directly into or adjacent to the fresh extraction sockets. The exact number of each category was not registered, but at least two implants in each patient were placed into an extraction site. In sites intended for a Toronto bridge (resin-based tooth and alveolar replacements mounted on a metal bar), postextraction bone peaks were removed to obtain a flat ridge to facilitate implant installation. In sites destined for metal-ceramic reconstructions, a prosthetically ideal height position and mesiodistal position (as indicated by the postextraction sockets) of the implants were adopted. Each patient received four to six implants.

To ensure good primary stability, the drilling protocol included underpreparation of the implant site, no screw tapping, and no countersinking.

The implants were inserted using a torque controller (OsseoCare, Nobel Biocare AB); an insertion torque of 50 Ncm was aimed for and adopted in all but two cases. For two implants in one patient, the insertion torque did not exceed 20 Ncm owing to soft bone quality.

To facilitate the gap closure between the implant and the surrounding bone, three different procedures were followed, depending on the size and anatomy of the

extraction site: (1) spaces smaller than 1 mm between the implant and the alveolar bone were left without any extra measure²⁸; (2) spaces larger than 1 mm were filled with available autogenous bone collected during drilling and covered with a film of cellulose (Tabotamp, Ethicon, Neuchatel, Switzerland); and (3) if large volumes of bone were needed, demineralized bovine bone (Bio-Oss, Geistlich Pharma AG, Wolhusen, Switzerland), alone or mixed with available autogenous bone, was used and covered with a bioresorbable membrane (BioGide, Geistlich Pharma AG).

Multi-unit abutments (Nobel Biocare AB) were connected to the implants immediately after implant installation by applying the torque recommended by the manufacturer (20 or 32 Ncm). Flaps were adapted to the abutment and finally sutured with bioresorbable material (Vicryl 4-0 [polyglactin 910], Johnson & Johnson International, St-Stevens-Woluwe, Belgium).

Postoperative Care

Sutures were removed after 12 to 14 days. During this period, no tooth brushing was allowed in the treated area. All patients were given analgesics for pain control, antibiotics as previously described, and 0.2% chlorhexidine mouthwash twice daily for 2 to 3 weeks. A soft-food diet regimen was instituted.

Prosthetic Protocol

Impressions were taken immediately after surgery. Within 3 days after surgery, all patients received a pro-

visional prosthesis made of a rigid cast framework (chrome-cobalt alloy).

The final prosthesis was delivered after 3 to 12 months provided that the implants appeared to be clinically and radiologically osseointegrated and the patients were satisfied with the esthetics and function. Fourteen of the bridges were full-arch bridges, and six bridges were partial restorations supported by four implants. Thirteen of the reconstructions were Toronto bridges, and seven were metal-ceramic bridges. All prostheses were screw-retained to prevent cement infiltration of the surgical wound and to facilitate clinical follow-up examinations of the implants.

Implant Survival Criteria

An implant was classified as surviving if (1) it fulfilled its purported function, (2) it was stable when tested individually, (3) no pain or signs of infection were detected during clinical examination, and (4) no radiologic signs of periimplant pathology were seen.

Clinical and Radiographic Follow-up

Clinical assessment, including evaluation of implant stability (without the bridge in place), was performed 3 months after implant insertion (baseline) and at the time of delivery of the final restoration. Thereafter, clinical examinations were performed every 6 months. Radiographic examinations were performed at baseline and at the last follow-up visit during the observation period. Intraoral radiographs were taken, and efforts were made to position the film parallel to the implant axis. A specialist in oral radiology measured the distance from a reference point at the implant-abutment interface to the most coronal bone-to-implant contact.

Results

All patients were followed for a minimum of 1 year (range 15 to 44 months), and no patient dropped out of the study.

Ninety-three of the 97 implants were installed in the interforaminal region, whereas 4 implants were placed posterior to the mental foramina. All extracted teeth were endodontically or periodontally compromised. Moreover, two implants presented fistulae and four patients had suppuration surging from the surgical incision.

No implant failures occurred during the observation period (Table 2), giving a 100% survival rate. No radiolucency around the implants or clinical signs of

TABLE 2 Life Table Analysis

Period, mo	Implants in Function	Patients	Survival Rate, %
At baseline	97	20	100
0–6	97	20	100
6–12	97	20	100
12–24	64	13	100
24–36	37	7	100

infection were detected at any follow-up examination; the soft tissue was healthy, no pus or fistula was detected, and no signs of inflammatory reactions, such as pain or tissue swelling, were seen.

Readable radiographs from baseline and the last follow-up were obtained for 13 of the 20 patients. At baseline, the mean marginal bone level was 1.70 mm (SD 0.96 mm). A mean bone loss of 0.74 mm (SD 1.19 mm) was observed between baseline and the last follow-up visit (Table 3).

Two patients experienced complications. In one patient, a membrane was exposed in an area in which a fistula had been previously present; in another patient, cellulose film exposure occurred. Both complications were treated with chlorhexidine and healed within 3 to 4 weeks. No patient needed adjunctive antibiotic therapy. No prosthetic complications occurred.

Case Presentations

Two representative cases—one endodontic and one periodontal case—are presented in Figures 2 and 3.

The first case (see Figure 2) is a 57-year-old male patient showing significant periapical lesions at the residual teeth in the mandible. In addition to a large periapical lesion, a fistula was present in the right canine area. Despite the substantial lack of bone in this

TABLE 3 Marginal Bone Remodeling between Baseline and Last Follow-up Visit with the Patient as a Unit

	Bone Level at Baseline, mm	Bone Level at Last Visit, mm	Marginal Bone Loss, mm
Mean	1.70	2.45	0.74
SD	0.96	1.20	1.19
Number of observations	13	13	13

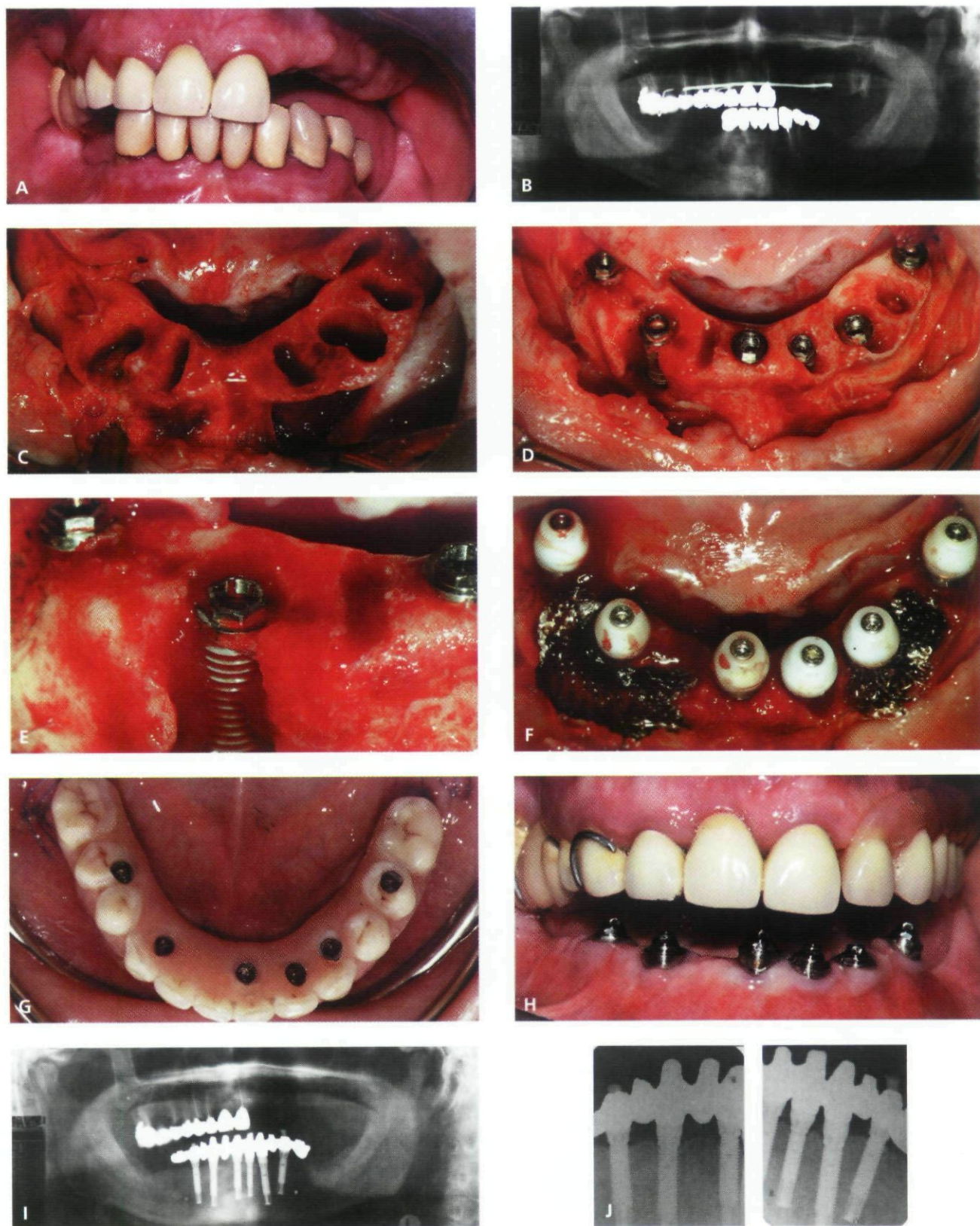


Figure 2 Clinical case of a male patient with endodontic problems in the mandible. *A*, Clinical pretreatment situation. *B*, Pretreatment panoramic radiograph showing significant periapical lesions at the residual teeth in the mandible. *C*, Postextraction sites with the presence of granulation tissue. *D*, Extractions performed and implants placed. *E*, Implant placed in the right canine position with a large buccal bone defect. *F*, Abutments and healing caps connected and bone grafting performed. *G*, Provisional bridge in place. *H*, Clinical image of the soft tissue healing at the 3-month examination. *I*, Panoramic radiograph taken 18 months postoperatively. *J*, Intraoral radiographs taken 18 months postoperatively showing good bone healing around the implants and the absence of radiolucency.

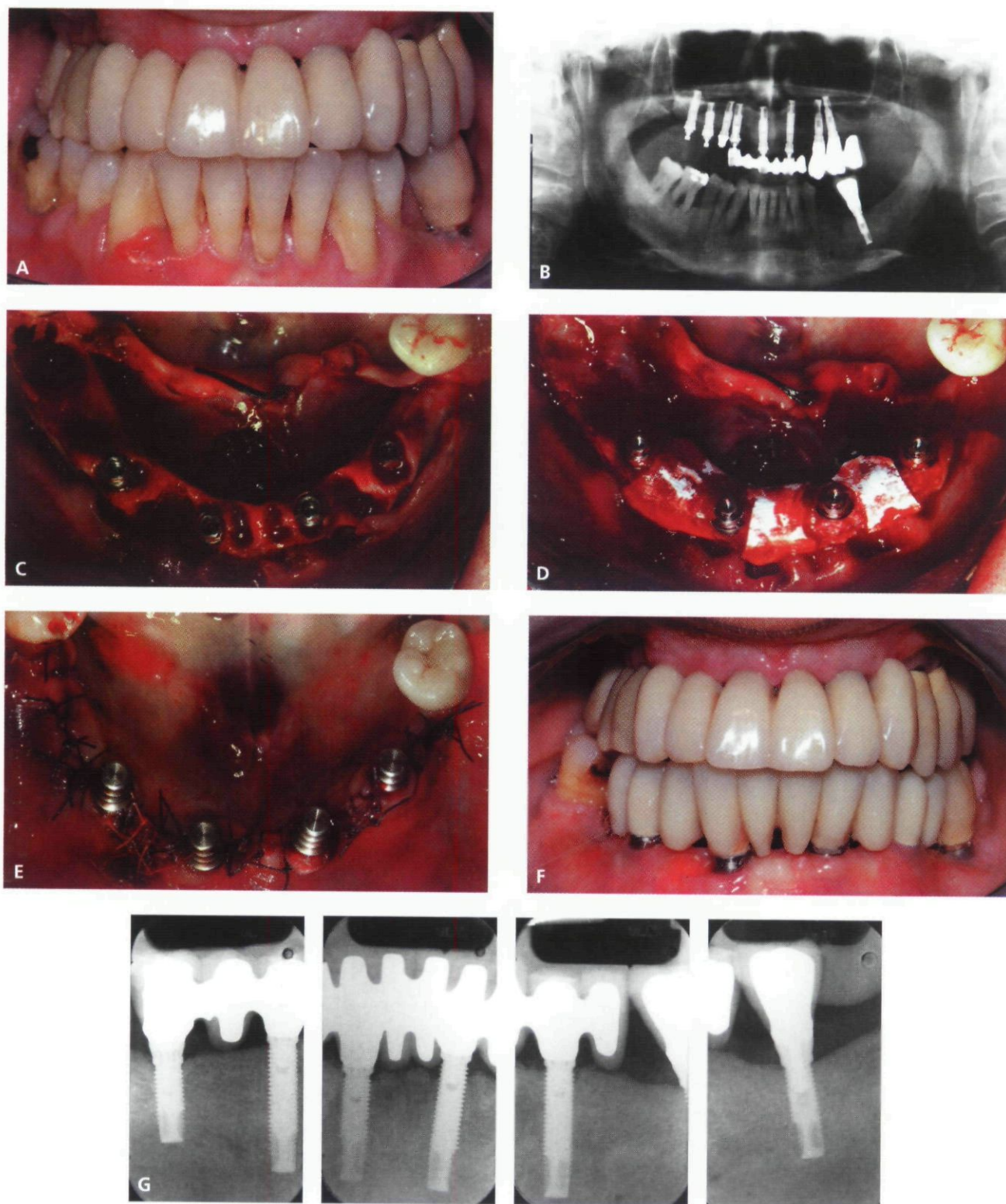


Figure 3 Clinical case of a female patient with advanced periodontal lesions in the mandible. *A*, Clinical pretreatment situation. *B*, Pretreatment radiograph. *C*, Extractions performed and implants placed. *D*, Abutments connected and bone grafting performed. *E*, Suture performed. *F*, Clinical image of the soft tissue healing 6 weeks postsurgery. *G*, Intraoral radiographs taken 23 months postoperatively showing good bone healing around the four implants placed in the interforaminal region. The radiographs also show two implants placed in a two-stage procedure in the molar area at different time points (one prior to and one after insertion of the four interforaminal implants).

area, an implant was placed into the extraction sockets and high implant stability was achieved (50 Ncm). The bone was reconstructed with autogenous bone collected during drilling and covered with a cellulose film (Tabo-tamp). The provisional bridge was delivered 3 days after surgery, and the final prosthesis was delivered after 5 months of satisfactory healing. Periapical radiographs performed 18 months postsurgery demonstrated good bone healing around the implants, and no radiolucency was detected in the areas of previous granuloma.

Figure 3 illustrates the case of a 57-year-old female patient with remaining residual mandibular teeth showing advanced periodontal lesions. At the time of surgery, a fistula was present in the right canine area and pus surged from the surgical incision. After bone curettage, four implants (two in the lateral incisor area and two in the left and right first premolar areas) were placed according to prosthetic and biomechanical needs. The bone was reconstructed with a mixture of demineralized bovine bone (Bio-Oss) and autogenous bone covered with a bioresorbable membrane (BioGide). Flaps were sutured with bioresorbable material (Vicryl 4-0). Figure 3F shows that satisfying soft tissue healing had been achieved already at the 6-week follow-up, except for a limited area of recession in region 42–43 as a result of membrane exposures. Periapical radiographs performed 23 months postoperatively showed good bone healing around the four implants placed in the interforaminal region.

DISCUSSION

The 100% implant survival rate and the normal marginal bone changes obtained in this study supports the hypothesis that early-loaded implants may be successfully osseointegrated when placed immediately after extraction of teeth presenting endodontic and periodontal lesions. The present protocol was based on biomechanical, surgical, and medical principles, considering preservation of high implant stability and a controlled inflammatory response. The design of this study did not permit distinguishing between the separate contributions of biomechanical and medical factors to the clinical results. However, it can be assumed that high initial implant stability, which is generally accepted as an important prerequisite for implant success, does not alone determine the clinical outcome. The same goes for other biomechanical parameters, such as load distribution, which is another important parameter that

most certainly influences implant survival. Even if mechanical criteria are met, an implant may be lost if persistent inflammation is not controlled after implant insertion. In such situations, an efficacious antibiotic protocol may play an important role. In this study, special attention was paid to control the infection and the consequent inflammation in the implant site. In addition to normal cleansing and curettage, the present protocol included an enhanced antibiotic regimen; the administration of antibiotics started 2 days before surgery, and the alveoli were rinsed with an antibiotic solution at the time of surgery. Although the antibiotic dosage was low compared with the dosage suggested by Dent and colleagues,²⁵ no signs of symptoms associated with implant failure were detected. This novel anti-inflammatory protocol may have prevented some potential implant losses in the study. There may be other ways of controlling the inflammatory process, but the results of this study point to the effectiveness of the present protocol. Further clinical investigations are recommended to explore its potential.

CONCLUSIONS

Early loading of immediately inserted implants after tooth extraction in the mandible is possible with a high survival rate in spite of pretreatment infections in the sites.

ACKNOWLEDGMENT

We thank Drs. Franco Biondi and Per Åstrand for their valuable contributions to the study.

REFERENCES

1. Randow K, Ericsson I, Nilner K, Petersson A, Glantz P-O. Immediate functional loading of Brånemark dental implants. *Clin Oral Implants Res* 1999; 10:8–15.
2. Ericsson I, Randow K, Nilner K, Peterson A. Early functional loading of Brånemark dental implants: 5-year clinical follow-up study. *Clin Implant Dent Relat Res* 2000; 2: 70–77.
3. Horiuchi K, Uchida H, Yamamoto K, Sugimura M. Immediate loading of Brånemark System implants following placement in edentulous patients: a clinical report. *Int J Oral Maxillofac Implants* 2000; 15:824–830.
4. Chow J, Hui E, Liu J, et al. The Hong Kong bridge protocol. Immediate loading of mandibular Brånemark fixtures using a fixed provisional prosthesis: preliminary results. *Clin Implant Dent Relat Res* 2001; 3:166–174.
5. Chiapasco M, Abati S, Romeo E, Vogel G. Implant-retained mandibular overdentures with Brånemark System MKII implants: a prospective comparative study between delayed

- and immediate loading. *Int J Oral Maxillofac Implants* 2001; 16:537–546.
6. Collaert B, De Bruyn H. Early loading of four or five Astra Tech fixtures with a fixed cross-arch restoration in the mandible. *Clin Implant Dent Relat Res* 2002; 4:133–135.
7. Cooper LF, Rahman A, Moriarty J, Chafee N, Sacco D. Immediate mandibular rehabilitation with endosseous implants: simultaneous extraction, implant placement, and loading. *Int J Oral Maxillofac Implants* 2002; 17:517–525.
8. Chee W, Jivrai S. Efficiency of immediately loaded mandibular full-arch implant restorations. *Clin Implant Dent Relat Res* 2003; 5:52–56.
9. Anneroth G, Hedström KG, Kjellman O, Köndell P-Å, Nordenram Å. Endosseous titanium implants in extraction sockets. An experimental study in monkeys. *Int J Oral Surg* 1985; 14:50–54.
10. Lazzara RJ. Immediate implant placement into extraction sites. Surgical and restorative advantages. *Int J Periodontics Restorative Dent* 1989; 9:333–343.
11. Becker W, Becker BE. Guided tissue regeneration for implants placed into extraction sockets and for implant dehiscences: surgical techniques and case reports. *Int J Periodontics Restorative Dent* 1990; 10:377–391.
12. Becker W, Lynch SE, Lekholm U, et al. A comparison of ePTFE membranes alone or in combination with platelet-derived growth factors and insulin-like growth factor-I or demineralized freeze-dried bone in promoting bone formation around immediate extraction socket implants. *J Periodontol* 1992; 63:929–940.
13. Jo YH, Hobo PK, Hobo S. Freestanding and multiunit immediate loading of the expandable implant: an up-to-40-months prospective survival study. *J Prosthet Dent* 2001; 85:148–155.
14. Grunder U. Immediate functional loading of immediate implants in edentulous arches: two year results. *Int J Periodontics Restorative Dent* 2001; 21:545–551.
15. Balshi TJ, Wolfinger GJ. Immediate loading of Brånemark implants in edentulous mandibles: a preliminary report. *Implant Dent* 1997; 6:83–88.
16. Chaushu G, Chaushu S, Tzohar A, Dayan D. Immediate loading of single-tooth implants: immediate versus non-immediate implantation. A clinical report. *Int J Oral Maxillofac Implants* 2001; 16:267–272.
17. De Bruyn H, Collaert B. Early loading of machined-surface Brånemark implants in completely edentulous mandibles: healed bone versus fresh extraction sockets. *Clin Implant Dent Relat Res* 2002; 4:136–142.
18. Maló P, Rangert B, Dvårsäter L. Immediate function of Brånemark implants in the esthetic zone. A retrospective clinical study with 6 months to 4 years of follow up. *Clin Implant Dent Relat Res* 2000; 2:137–145.
19. Glauser R, Rée A, Lundgren AK, Gottlow J, Hämmerle CHF, Schärer P. Immediate occlusal loading of Brånemark implants applied in various jawbone regions: a prospective 1-year clinical study. *Clin Implant Dent Relat Res* 2001; 3:204–213.
20. Lekholm U. Immediate/early loading of oral implants in compromised patients. *Periodontology* 2000 2003; 33:194–203.
21. Novaes AB Jr, Novaes AB. Immediate implants placed into infected sites: a clinical report. *Int J Oral Maxillofac Implants* 1995; 10:609–613.
22. Tripodakis AP. Sofortimplantation in infizierte und defekte Extraktionsalveolen und kontrollierte Sofortimplantatbelastung. Teil I: Einzelzahnimplantate. *Implantologie* 2001; 1:13–25.
23. Novaes AB Jr, Vidigal GM Jr, Novaes AB, Grisi MFM, Polioni S, Rosa A. Immediate implants placed into infected sites. A histomorphometric study in dogs. *Int J Oral Maxillofac Implants* 1998; 13:422–427.
24. Novaes AB Jr, Marcaccini AM, Souza SLS, Taba M Jr, Grisi MFM. Immediate placement of implants into periodontally infected sites in dogs: a histomorphometric study of bone-implant contact. *Int J Oral Maxillofac Implants* 2003; 18: 391–398.
25. Dent CD, Olson JW, Farish SE, et al. The influence of pre-operative antibiotics on success of endosseous implants up to and including stage II surgery: a study of 2,641 implants. *J Oral Maxillofac Surg* 1997; 55(Suppl 5):19–24.
26. Rangert B, Sullivan RM, Jemt T. Load factor control for implants in the posterior partially edentulous segment. *Int J Oral Maxillofac Implants* 1997; 12:360–370.
27. Duyck J, Van Oosterwyck H, Vander Sloten J, De Cooman M, Puers R, Naert I. Magnitude and distribution of occlusal forces on oral implants supporting fixed prostheses: an in vivo study. *Clin Oral Implants Res* 2000; 11:465–475.
28. Boticelli D, Berglundh T, Buser D, Lindhe J. The jumping distance revisited. An experimental study in the dog. *Clin Oral Implants Res* 2003; 14:35–42.

Copyright of Clinical Implant Dentistry & Related Research is the property of B.C. Decker Inc.. The copyright in an individual article may be maintained by the author in certain cases. Content may not be copied or emailed to multiple sites or posted to a listserv without the copyright holder's express written permission. However, users may print, download, or email articles for individual use.