

Scalloped Dental Implants: A Retrospective Analysis of Radiographic and Clinical Outcomes of 17 NobelPerfect™ Implants in 6 Patients

Hessam Nowzari, DDS, PhD;* Winston Chee, DDS, FACP;† Klaus Yi, DDS;‡ Mark Pak, DDS;§ Woun Ho Chung, DDS;§ Sandra Rich, PhD||

ABSTRACT

Background: The scalloped dental implant (NobelPerfect™, Nobel Biocare, Yorba Linda, CA, USA) is designed to biologically guide and facilitate interproximal bone remodeling during healing and to maintain bone height and papillae during functional loading. The design features of the scalloped implant include hard and soft tissue apposition areas, which are parallel to each other and mirror the cemento-enamel junction. The hard tissue surface area is intended for osseointegration. The soft tissue surface area is meant to support the connective tissue zone and to provide a space for the subgingival margin of the restoration. Current literature on the clinical performance of the scalloped dental implant is limited.

Purpose: The aim of this study was to evaluate whether the scalloped dental implant maintains interproximal bone and the overlying soft tissue.

Materials and Methods: Radiographs for six patients (mean age 40.5 years) treated with 17 implants (NobelPerfect) were reviewed for an 18-month follow-up evaluation of bone response. Orthodontic movement and/or autogenous bone augmentation had been provided to obtain the best possible soft and hard tissue dimensions prior to implant placement. A surgical guide was used for an optimal implant placement. No surgical flap was reflected, and implants were placed a minimum of 2 mm and a maximum of 3 mm apical (midbuccally) to the most apical portion of the surgical guide. Final optimal rotational alignment was achieved in all cases by not exceeding 45 Ncm. Implants were immediately restored with provisional crowns. Photographic documentation provided the basis for analysis of papillary response. Radiographic change in the interproximal bone level was obtained by computer analysis (*ImageJ* for Windows, National Institutes of Health, Bethesda, MD) by measuring the distance from the interproximal shoulder of the scalloped implant to the crest of the bone.

Results: When the scalloped implants were placed adjacent to existing natural dentition, the average bone level at placement and at 6, 12, and 18 months was -1.7, -3.5, -3.8, and -3.9 mm, respectively, compared with -1.0, -3.6, -4.3, and -4.4 mm respectively, when placed adjacent to other scalloped implants. Papillae formation exhibited no differences from the configuration that typically results after placement of conventional dental implants. Moreover, bone loss around the scalloped implants was notably greater than that expected after traditional implant placement.

Conclusion: This chart review of 17 scalloped implants, followed for 18 months, determined that the scalloped implant design resulted in bone loss that was more severe than that associated with properly placed conventional dental implants. Further, the design showed no evidence of exceptional capacity to increase or maintain soft tissue height.

KEY WORDS: bone loss, maxillary anterior, papillae formation, retrospective, scalloped dental implant

*Associate professor, clinical dentistry, and director, advanced periodontics, University of Southern California School of Dentistry, Los Angeles, CA, USA; †Ralph & Jean Bleak Professor of Restorative Dentistry and director, implant dentistry, University of Southern California School of Dentistry, Los Angeles, CA, USA; ‡assistant professor, clinical dentistry and advanced periodontics, University of Southern California School of Dentistry, Los Angeles, CA, USA; §Department of Prosthodontics, Samsung Medical Center, Seoul, Korea; ||associate professor, advanced periodontics, University of Southern California School of Dentistry, Los Angeles, CA, USA

Clinical trials have shown evidence of high implant survival and success rates in the maxillary anterior segment.¹⁻³ However, most of the published studies do

Reprint requests: Dr. Hessam Nowzari, University of Southern California Dental Science Center-DEN, 925 West 34th Street, Room 119, Los Angeles, CA 90089-0641, USA; e-mail: nowzari@usc.edu

© 2006 Blackwell Publishing, Inc.

DOI 10.2310/6480.2005.00034

not include detailed evaluation of esthetic parameters. A harmonious gingival display is highly valued by patients in this segment of the mouth and contributes significantly to facial expression.⁴ Patient satisfaction with maxillary anterior implants is unlikely to be met unless well-defined esthetic standards are addressed.⁵ In single implant sites without tissue deficiencies, an esthetic treatment outcome is generally successful because it depends on the tissue support provided by the adjacent teeth.^{6,7} In contrast, the esthetic outcome of multiple adjacent implants presents a major challenge for the clinician.^{8–10}

The scalloped implant is designed to keep or create interdental bony peaks that support the soft tissue, thereby maintaining or creating interimplant papillae.^{11–13} The primary esthetic goal of the scalloped implant design is to avoid the dark, triangular space known as the “black triangle.” The space appears when bone remodeling results in loss of osseous support for the papillae.^{14,15} The esthetic concern is increased when the patient has an alveolar morphotype leading to a pronounced scalloped profile of the hard and soft tissues, which can be further complicated by the gingival display of a high smile line.¹⁶ The scalloped implant offers a contour design in which the modified platform mirrors the natural cemento-enamel junction of the anterior teeth and follows the anatomic contour of the anterior alveolar bone crest.

The intention of the scalloped implant design is to influence the biology and preserve the interproximal bone. The manufacturer of the implant (Nobel Biocare, Yorba Linda, CA, USA) suggests that the implant design minimizes bone loss in the interproximal area of adjacent implants and enhances the formation of the interimplant papillae. Further, the design is expected to facilitate establishment of the biologic width, which is influenced by the location of the implant-abutment interface.^{17–19} Scalloped hard and soft tissue apposition areas are noted features of the design.

With regard to scalloped implant design, biologic considerations have been attentively analyzed and an attempt has been made to execute design concepts based on scientific principles. To date, however, theories of hard and soft tissue response to the scalloped implant design have not been clearly substantiated and a *Medline* literature review revealed that no compelling clinical evidence has been documented. No large randomized controlled trials or smaller observational clinical studies

have shown that tissues actually respond consistently to the curvature design of the scalloped implant, as suggested by clinicians and the manufacturers of the device. The literature can offer only several reports of case studies that have provided no more than short-term outcomes.^{13,20–22} Some of these publications provide a few illustrative radiographs, but no precise measurements of progressive bone loss have been presented by any of the investigators. Therefore, the present study was initiated to attempt to answer the following questions:

1. Does the scalloped implant allow for the maintenance of interproximal bone?
2. Does scalloped bone apposition remain stable?
3. Does the scalloped implant allow for the maintenance of interproximal papillae?
4. Do interimplant papillae remain stable?

METHODS AND MATERIALS

Under a chart review protocol approved by the University of Southern California Institutional Review Board (USC UPIRB #05-07-208), consecutive patients who received adjacent scalloped dental implants (multiple implants) in the maxillary anterior segment were selected. Six consecutively treated patients (two males, four females) with a mean age of 40.5 years (range 26–54 years) were evaluated. Orthodontic therapy and/or autogenous ridge augmentation had been performed to provide the best possible horizontal and vertical soft and hard tissue dimensions prior to implant placement. Hard and soft tissue conditions, including interproximal bone height and osseous contour, were evaluated using computed tomography and periapical radiographs. Anatomic conditions were reconfirmed at the time of surgery by direct sounding.

Selected cases fulfilled the following criteria:

- Bone quality of type 2 to 3 (Lekholm and Zarb²³) in the planned implant placement site and vertical bone height that housed ≥ 10 mm implant
- No history of smoking
- No systemic contraindications
- No parafunctional habits
- Primary implant stabilization was determined with an insertion torque of 45 Ncm

One of the six selected patients had been treated with two-stage implants. Three of the scalloped implants placed for the two-stage patient were located

in the maxillary posterior sextant. The five other subjects had only anterior sextant scalloped implants with immediate placement and immediate load.

Surgical Procedures

All surgical procedures were performed by one periodontist (H.N.). The surgical approach and techniques, which were used for all chosen subjects, are described as follows:

The primary reference for site preparation was the interproximal bone level. A surgical guide mimicking the planned restoration as it emerges from the site was used for an optimal implant placement. The surgical guide was tooth supported and identified the desired emergence of the crown from the soft tissue at its apical extension.

No surgical flap was reflected, and implants were placed a minimum of 2 mm and a maximum of 3 mm apical (midbuccally) to the most apical portion of the surgical guide. These guidelines were used to optimize the contours of the implant restorations.

Alignment of the interproximal peaks followed the natural arch curvature and not a straight line. Final rotational alignment was achieved by using the Nobel-Perfect™ implant driver, not exceeding 45 Ncm of torque. The manual torque wrench was used to complete the seating of the implants and align the interproximal Brånemark System® TiUnite peaks (Nobel Biocare AB, Göteborg, Sweden) with the interproximal bone.

Prosthetic Procedures/Insertion of the Provisional Crowns for One-Stage Immediate Function

Implants were immediately restored with provisional crowns for five subjects. Provisional restorations were fabricated using the provided coping. The copings were placed on the abutments, and a self-curing temporary acrylic shell was placed over the coronal part of the coping, after which the shell coping assembly was removed and brought to full contour extraorally on an implant analogue in order to minimize contamination of the surgical site. The acrylic was trimmed and polished to the premachined margin of the coping. The occlusal contacts of the provisional crowns were adjusted to light contact in maximal intercuspal position (pulling two layers of Mylar with light resistance) and to avoid excursions where possible.

Clinical Measurements

All patients had been monitored with measurements appropriate to the placement of the scalloped implant design. Seventeen scalloped implants (NobelPerfect) were placed and reviewed for 18 months post implant placement. Computerized evaluation of radiographic interproximal bone level was performed at time intervals of 0, 6, 12, and 18 months postsurgically. Periapical radiographs were obtained with a dental x-ray machine operating at 60 kVp. Long-cone paralleling projection, using a Rinn film holder, yielded a focusfilm distance of approximately 25 cm. Film speed group E (Kodak Ektaspeed, Eastman Kodak, Rochester, NY, USA) was used and developed immediately in an automatic developing machine. Only radiographs perpendicular to the long axis of the fixtures (ie, showing clearly visible fixture threads) were used for evaluation.

Mesial and distal marginal radiographic bone level changes were recorded using *ImageJ* for Windows. *ImageJ* is a public domain Java image processing program, based on *NIH Image*, which calculates area and pixel value statistics for user-defined selections.^{24,25} Spatial calibration was set to express dimensional units in millimeters. The interproximal shoulder of the implant served as a reference to the radiographic bone level. The fixture threads served as an internal reference. Bone level was measured as the distance from the interproximal shoulder of the scalloped implant to the crest of the bone.

Pre- and postsurgical radiographic evaluation of the scalloped implant to the neighboring teeth or adjacent scalloped implants was performed. The bone quality, based on the Lekholm and Zarb classification,²³ was clinically assessed during surgery. For each follow-up appointment, the radiographic change in the interproximal bone level was numerically calculated by comparing the previous level with the current level.

Data Analysis

Frequency data and all measurements are presented in Tables 1 and 2, with one-stage and two-stage measurements indicated separately. Radiographic and clinical photographs following one subject through the presurgical and postsurgical phases of one-stage treatment are presented.

RESULTS

When the scalloped implant was placed adjacent to the existing natural dentition, the average bone level at the

TABLE 1 Radiographic Analysis Comparing Implant-Implant and Implant Tooth Peri-Implant Mean Bone Level at 0, 6, 12, and 18 Months

Mean Peri-Implant Bone Level (mm)	T ₀ (Placement)	T ₁ (6mo)	T ₂ (12mo)	T ₃ (18mo)
Implant-implant (16 peri-implant sites T ₀ -T ₂)	-1.0	-3.6	-4.3	-4.4*
Implant-tooth (10 peri-implant sites T ₀ -T ₂)	-1.7	-3.5	-3.8	-3.9†

n = 13 one-stage scalloped implants for 5 subjects.

*Ten peri-implant sites at T₃.

†Eight peri-implant sites at T₃.

time of placement and at 6, 12, and 18 months was -1.7, -3.5, -3.8, and -3.9 mm, respectively, compared with -1.0, -3.6, -4.3, and -4.4 mm, respectively, when placed adjacent to scalloped implants (see Table 1).

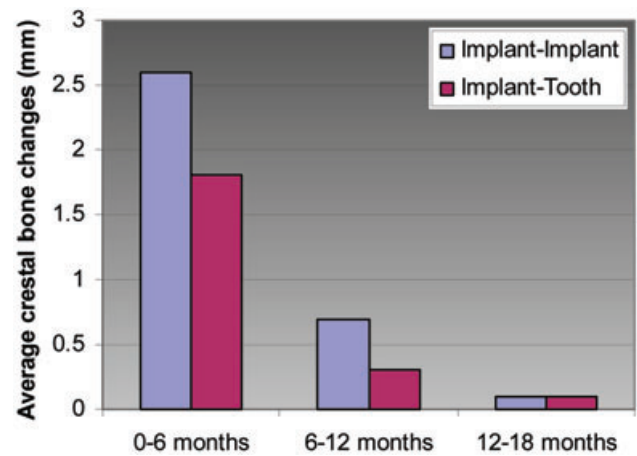


Figure 1 Average radiographic crestal bone change (mm) from placement to 18 months: implant-implant versus implant-tooth sites.

Table 2 presents raw data for all subjects, showing demographics and crestal bone measurements over time. The table is color-coded to indicate whether the site measured is an interproximal surface for implant-

TABLE 2 Mesial and Distal Radiographic Bone Level Measured at 0, 6, 12, and 18 Months (Distance from the Interproximal Shoulder of the Scalloped Implant to the Crest of the Bone)

Subject (ASA, Gender, Age)	Implant Position	T ₀ (Placement)		T ₁ (6 mo)		T ₂ (12 mo)		T ₃ (18 mo)	
		M	D	M	D	M	D	M	D
II, F, 49 yr (one stage)	7	-0.3	-1.0	-4.3	-3.6	-6.6	-4.7	*	*
	8	-1.8	-1.7	-3.4	-3.0	-4.1	-3.7	*	*
	9	1.4	-1.0	-3.6	-4.1	-3.9	-5.7	*	*
	10	-0.8	-5.8	-4.5	-3.9	-5.2	-4.8	*	*
I, F, 37 yr (one stage)	7	-2.3	-3.3	-3.4	-3.9	-4.8	-4.5	-5.2	-4.6
	8	-4.4	-3.2	-5.8	-3.0	-5.3	-5.1	-5.8	-5.8
I, F, 26 yr (one stage)	8	-3.7	-1.8	-4.7	-5.6	-4.6	-4.8	-4.9	-5.4
	9	-2.0	-1.1	-3.8	-3.0	-3.4	-3.1	-5.2	-3.9
II, M, 54 yr (one stage)	8	-1.4	1.8	-3.8	-4.0	-3.9	-3.9	-4.7	-3.9
	9	0.3	0.9	-4.5	-3.6	-4.4	-4.6	-4.7	-5.0
	10	0.9	-0.3	-2.1	-1.1	-2.4	-1.9	-2.5	-1.9
II, M, 36 yr (one stage)	8	-0.5	-0.6	-3.2	-3.1	-3.3	-3.3	-3.4	-3.6
	9	-0.4	-0.4	-2.7	-1.4	-3.0	-2.1	-3.0	-2.5
I, F, 41 yr (two stage)	9	-3.1	-2.3	-1.2	-3.0	*	*	-2.6	-3.0
	12	-0.6	0.6	-0.4	0.8	*	*	-3.3	-2.3
	13	-1.4	-1.7	-1.6	-1.4	*	*	-2.7	-3.6
	14	-1.6	-1.7	-1.7	-1.4	*	*	-2.8	-2.1

ASA = American Society of Anesthesiologists; D = vertical bone level measured on distal surface of implant; M = vertical bone level measured on mesial surface of implant.

Black = implant-tooth site; blue = implant-pontic site; red = implant-implant site.

*Data not available.

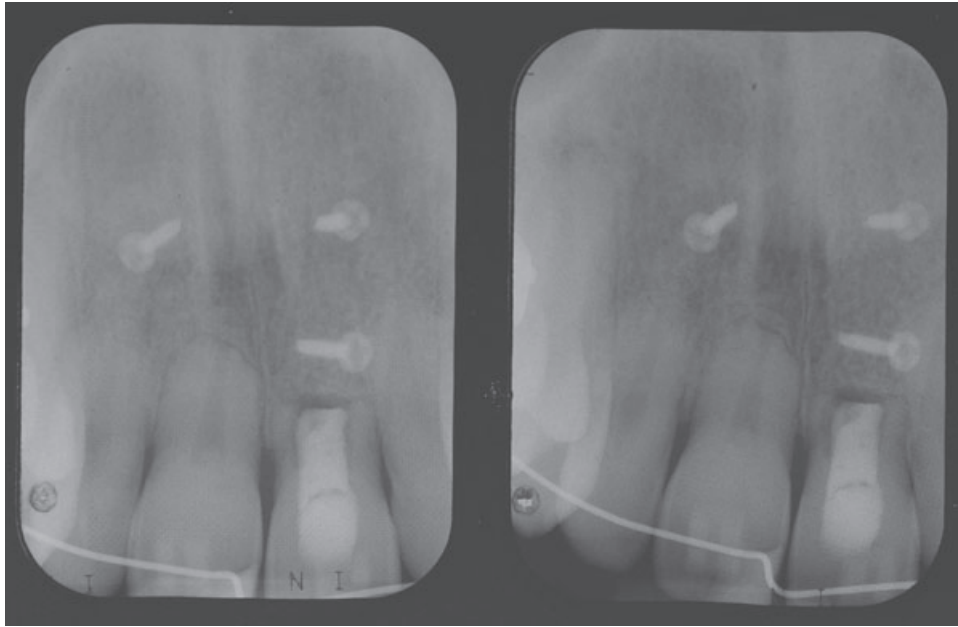


Figure 2 Radiographic view of the surgical site after autogenous bone grafting to enhance the buccolingual width of the bone.

implant, implant-tooth, or implant-pontic sites. For unknown reasons, 18-month follow-up data were not documented for one subject, who had four implants placed. However, Table 2 indicates that by the 12-month monitoring appointment, the patient had shown a pattern of bone loss similar to that of the other patients reviewed. Data for one two-stage subject are presented but have not been included in the averages calculated for Table 1 and Figure 1.

Figure 1 is a bar graph illustrating average crestal bone changes, implant-implant versus implant-tooth sites, for 13 one-stage scalloped implants from placement to 6 months, from 6 to 12 months, and from 12 to

18 months. As previously stated, no 18-month data were available for 4 of the 13 one-stage implants.

Figures 2 to 13 are presurgical, placement day, and postsurgical follow-up photographs and radiographs for a one-stage treatment subject.

DISCUSSION

The scalloped design did not promote superior interproximal bone and papilla height compared with previously reported outcomes of the conventional flat-platform design.²⁶ Bone remodeling occurred around the scalloped dental implants in a biologic response similar to or greater than that which has been

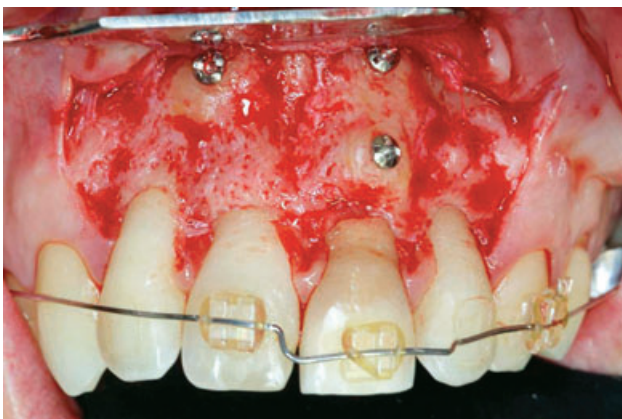

Figure 3 Clinical view of the grafted site. Autogenous cortical bone was used to optimize the bone width.

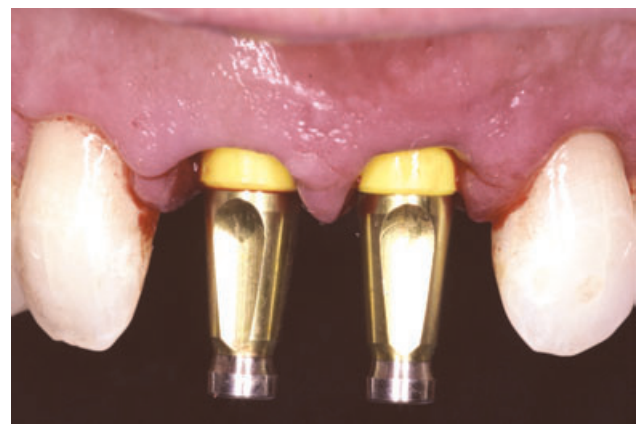


Figure 4 Following the insertion of the implants immediately after extractions, the impression was taken for the fabrication of the provisional teeth.

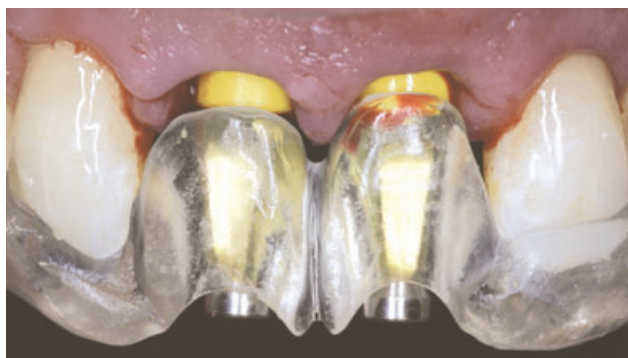

Figure 5 Clinical view of the impression copings and the surgical guide. The surgical template was used to take the impression.

described for flat prosthetic platforms.^{26,27} The supporting bone tissue receded to the level of the first thread of the implant and beyond.

Other investigators have documented bone loss around currently used implant designs. In a recent clinical and radiographic comparison of regular platform dental implants with surfaces roughened by anodic oxidation (TiUnite), dual acid-etched implants (Osseotite, 3i/Implant Innovations, West Palm Beach, FL, USA), and machined implants (Brånemark System), Aalam and Nowzari reported similar bone remodeling among implant groups that averaged 1.3 mm at 24 months, with a range of 1.2 to 1.5 mm.²⁸

When examining marginal bone resorption around TiUnite regular implants placed early in function, Vanden Bogaerde and colleagues reported 0.8 mm

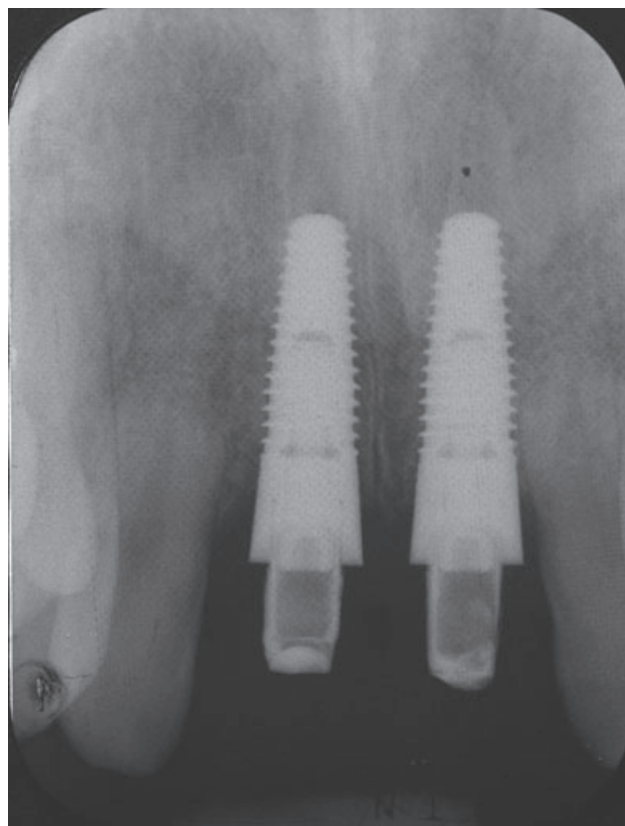


Figure 7 Radiographic view at 2 months postsurgery.

bone loss, as opposed to 1.6 mm, with machined-surface implants.²⁹ However, this reported difference between TiUnite and machined surface implants was not found to be statistically significant.

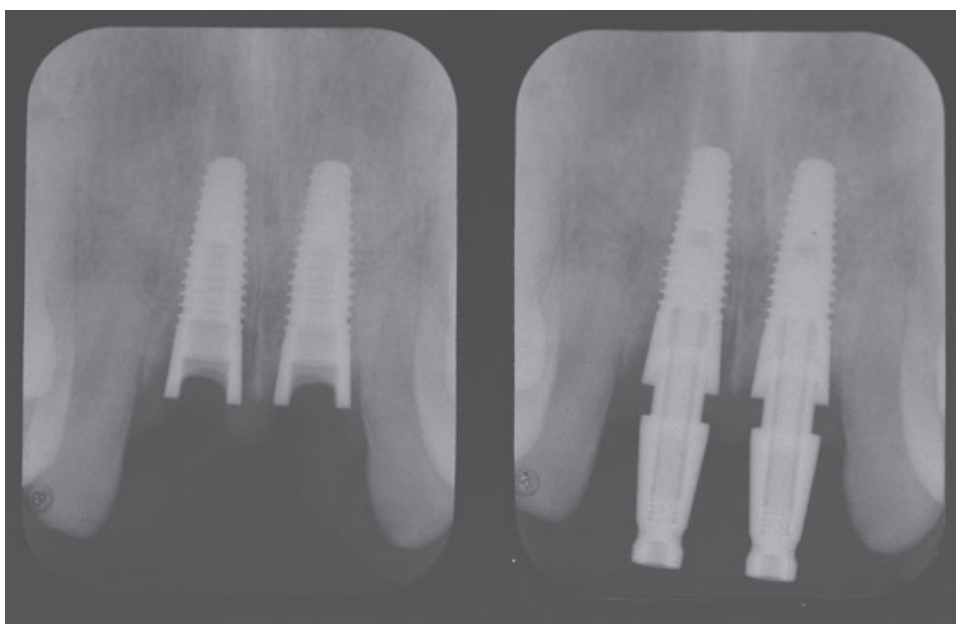


Figure 6 Radiographic views on the day of placement. Interproximal bone peaks are evident between implants.

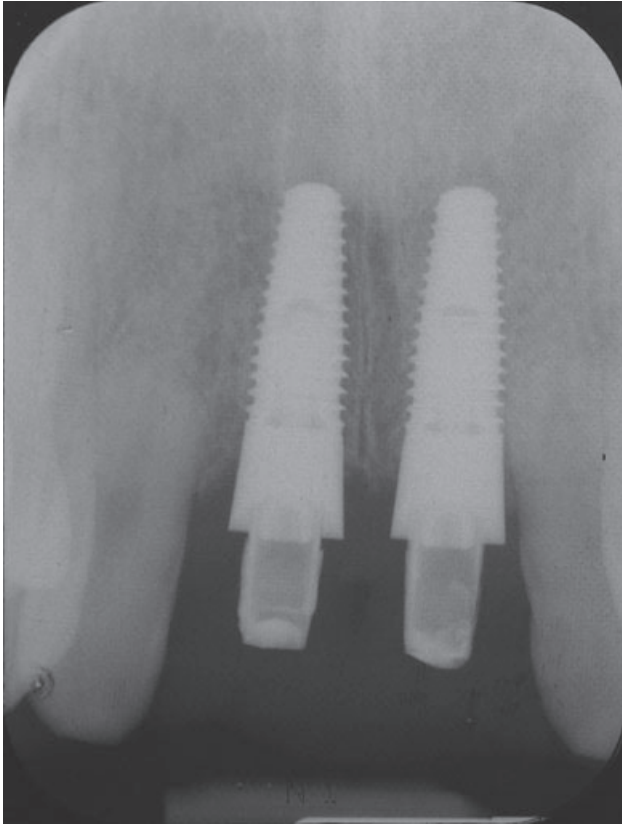


Figure 8 Radiographic view at 3 months postsurgery.

Another prospective clinical study evaluated directly loaded Brånemark System or Replace Select Tapered implants with a TiUnite surface (Nobel Biocare AB) in the maxilla; the marginal bone resorption was also reported to be 0.8 mm, with a standard deviation of 0.9 mm.³⁰ It should be noted that implants used in the present study have a body configuration similar to that of Replace Select Tapered implants; however, the latter are not scalloped.

Overall, prospective studies of Brånemark System implants with the TiUnite surface have reported a mean marginal bone resorption of 1.4 mm at 1 year³¹ and 1.3 mm at 4 years.³² In the latter study, Brånemark System TiUnite implants were immediately occlusally loaded and the standard deviation of bone loss was 0.9 mm. When Brånemark System Mk IV implants with a machined surface were evaluated after an immediate-loading protocol and flapless surgery in the maxilla, the marginal bone resorption averaged 1.0 mm during the first year of loading, 0.4 mm during the second year, and 0.1 mm during the third year.³³

The studies cited provide estimates of the amount of bone resorption that can be anticipated after implant

placement. The bone resorption detected around scalloped implants in the present study exceeded that which has been documented for traditional implants by other investigators.

Bone resorption noted around scalloped implants placed after a two-stage approach (see Table 2) also demonstrated a pattern similar to that observed around traditional platforms. It should be noted that at the time of second-stage surgery, all of these implants were covered by bone.

The scalloped implant is designed to biologically guide and facilitate bone remodeling.⁹ However, determining factors in interimplant papillae development are complex and cannot likely be met by limited design features.⁸ The black triangle is a significant problem in dental implant esthetics and can exist for reasons other than peri-implant bone height, such as the thickness of the bone, tooth morphology, and arrangement and quality of soft tissue fibers, including the dentogingival, circular, semicircular, transseptal, interpapillary, and intergingival fibers.

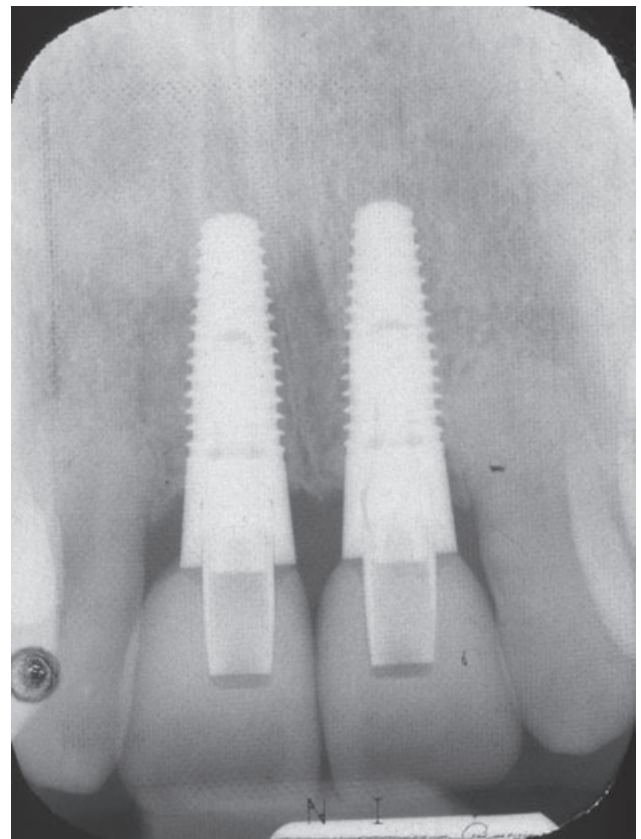


Figure 9 Radiographic view at 12 months postsurgery. Note resorption of interproximal bone peaks.

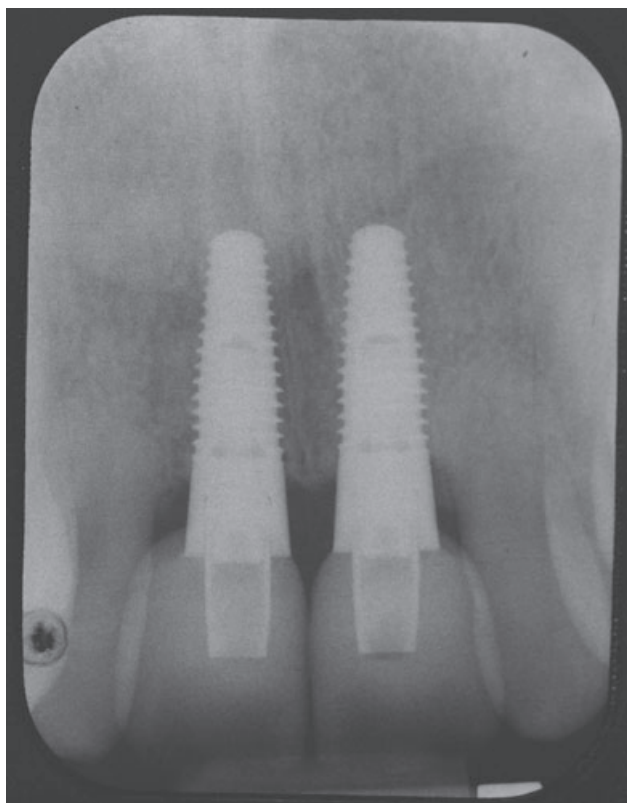


Figure 10 Radiographic view at 18 months postsurgery. Recession of the supporting bone tissue is evident interproximally.

In the natural dentition, tooth morphology correlates with periodontal biotype.^{16,34–36} Ochsenbein and Ross described healthy periodontal tissues by use of the biotype categories of “thin scalloped” (thin gingival tissue, long papillae, and thin, scalloped bone) and “thick flat” (thick gingival tissue, short and wide papillae, and thick, flat bone).³⁷ Olsson and Lindhe further described the periodontium with observations of associated tooth form and susceptibility to gingival recession.

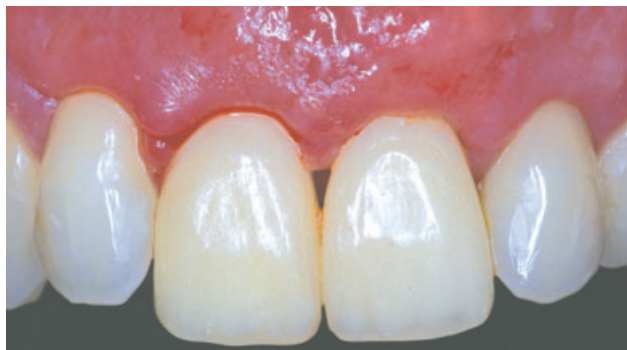

Figure 11 Clinical view of the provisional teeth placed on the same day as the surgical insertion of the implants. No suturing was needed because no surgical flap was raised.

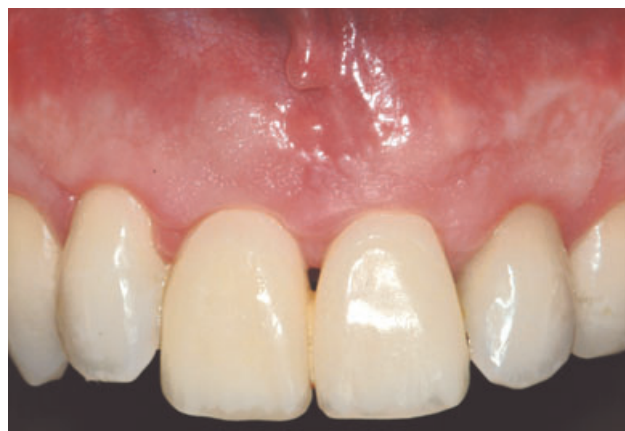

Figure 12 Clinical view 1 month postoperatively.

The triangular tooth is present with the scalloped and thin periodontium.³⁸ The contact area for the triangular tooth shape is at the coronal third of the crown, underlining a long and thin papilla. The squared tooth combines with a thick and flat periodontium. The contact area for the square tooth shape is at the middle third of the crown, supporting a short and wide papilla. None of the patients reviewed and evaluated in the present study were categorized as having a thin, highly scalloped biotype, which would have presented an additional problem of susceptibility to the black triangle owing to the extended distance from the contact point to the crest of the bone.¹⁵ Even so, when guidelines to control for proper contours of implant restorations were used and the buccal surface of the implant was placed 2 to 3 mm below the margin of the intended clinical crown, the peaks of the implant were often at or below the level of the bone peaks for implants placed immediately postextraction. These considerations call into question whether any average platform can accommodate the

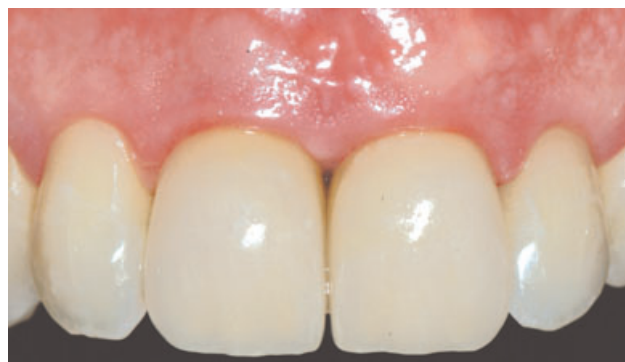

Figure 13 Clinical view of definitive restorations at 18 months. Note loss of papillae between implant-supported restorations. Note the presence of papillae between implant-supported restorations and natural teeth.

host of variations found clinically, even if the implant design is conceptually sound.

Bone characteristics that can significantly affect the soft tissue morphology are the thickness, height, and contour of the facial alveolar plate.¹⁶ The morphology of the alveolar plate exhibits a wide range of variation. A dynamic balance between functional forces and the alveolar bone shapes the alveolar morphology. The direction, intensity, and duration of the forces are reflected in the bone density and thickness. The thickness and height of the facial alveolar plate are also influenced by root-to-bone angulation. Labial inclination is associated with a thin and scalloped facial alveolar bone that is located in a more apical position than normally. Lingual inclination is associated with a thick and flat facial alveolar bone that is located in a more coronal position.

Implants placed in the cases reviewed for the present study were lingually inclined to provide a thicker coronal portion of the facial alveolar plate and counteract peri-implant bone resorption. Optimal vertical and horizontal enlargements of the facial alveolar plate are critical to the long-term maintenance of the soft tissue height.³⁹ In addition, no surgical flap was raised to prevent soft tissue loss and preserve the existing tissue.⁴⁰ In the present study, remodeling ultimately resulted in loss of the interimplant bone and papilla. No advantages for maintaining interproximal bone could be attributed to the scalloped implant.

Logic and science-based theories must be the starting point for all dental implant research. However, recommendations for use and marketing must be based on clinical evidence that new designs are truly efficacious in accomplishing what is claimed. Based on the findings in this study, the scalloped implant provided no advantages over traditional dental implant designs. The scalloped implants placed exhibited an unexpected average of approximately 4.0 mm of interproximal bone loss at 18 months of follow-up. Excessive bone resorption is undesirable and may threaten the long-term esthetics and stability of dental implants. Therefore, the results of this study raise a concern that further studies with long-term, prospective, controlled designs and greater numbers of subjects are urgently needed.

ACKNOWLEDGMENT

This study was supported by University of Southern California Advanced Periodontics Program research funds.

REFERENCES

1. Albrektsson T, Zarb G, Worthington P, Eriksson AR. The long-term efficacy of currently used dental implants: a review and proposed criteria of success. *Int J Oral Maxillofac Implants* 1986; 1:11–25.
2. Adell R, Eriksson B, Lekholm U, Brånemark PI, Jemt T. Long-term follow-up study of osseointegrated implants in the treatment of totally edentulous jaws. *Int J Oral Maxillofac Implants* 1990; 5:347–359.
3. Adell R, Lekholm U, Rockler B, Brånemark PI. A 15-year study of osseointegrated implants in the treatment of the edentulous jaw. *Int J Oral Surg* 1981; 10:387–416.
4. Locker ES. Patient-based outcomes of implant therapy: a review of the literature. *Int J Prosthodont* 1998; 11:453–461.
5. Chang M, Odman PA, Weenström JL, Anderson B. Esthetic outcome of implant supported single-tooth replacements assessed by patient and prosthodontist. *Int J Prosthodont* 1999; 12:335–341.
6. Jemt T. Regeneration of gingival papillae after single-implant treatment. *Int J Periodontics Restorative Dent* 1997; 17:326–333.
7. Jemt T. Restoring the gingival contour by means of provisional resin crowns after single-implant treatment. *Int J Periodontics Restorative Dent* 1999; 19:20–29.
8. Belser UC, Schmid B, Higginbottom F, Buser D. Outcome analysis of implant restoration located in the anterior maxilla: a review of the recent literature. *Int J Maxillofac Implants* 2004; 19(Suppl):30–42.
9. Palmer RM, Palmer PJ, Newton JT. Dealing with esthetic demands in the anterior maxilla. *Periodontology* 2000 2003; 33:105–118.
10. Zetu L, Wang H-L. Management of inter-dental/interimplant papilla. *J Clin Periodontol* 2005; 32:831–839.
11. Holt RL, Rosenberg MM, Zinser PJ, Ganeles J. Concept for a biologically derived, parabolic implant design. *Int J Periodontics Restorative Dent* 2002; 22:473–481.
12. Gadhia MH, Holt RL. A new implant design for optimal esthetics and retention of interproximal papillae. *Implant Dent* 2003; 12:164–169.
13. Wöhrle PS. NobelPerfect™ esthetic scalloped implant: rationale for a new design. *Clin Implant Dent Relat Res* 2003; 5(Suppl 1):64–73.
14. Nordland WP, Tarnow DP. A classification system for loss of papillary height. *J Periodontol* 1998; 69:1124–1126.
15. Tarnow DP, Magner AW, Fletcher P. The effect of the distance from the contact point to the crest of bone on the presence or absence of the interproximal dental papilla. *J Periodontol* 1992; 63:995–996.
16. Becker W, Ochsenein C, Tibbetts L, Becker RF. Alveolar bone anatomic profiles measured from dry skulls. Clinical ramifications. *J Clin Periodontol* 1997; 24:727–731.
17. Hermann JS, Buser D, Schenk RK, et al. Biologic width around one- and two-piece titanium implants. A histomet-

- ric evaluation of loaded non-submerged and submerged implants in the canine mandible. *Clin Oral Implants Res* 2001; 12:559–571.
18. Hermann JS, Schoolfield JD, Schenk RK, Buser D, Cochran DL. Influence of the size of the microgap on crestal bone changes around titanium implants. A histometric evaluation of unloaded non-submerged implants in the canine mandible. *J Periodontol* 2001; 72:1372–1383.
 19. Hermann JS, Buser D, Schenk RK, Cochran DL. Crestal bone changes around titanium implants. A histometric evaluation of unloaded non-submerged and submerged implants in the canine mandible. *J Periodontol* 2000; 71:1412–1423.
 20. Noelken R. Esthetic rehabilitation of incisors with hard and soft tissue augmentation and NobelPerfect™ implants. *Dent Implantol* 2003; 7:427–442.
 21. Leziy SS, Miller BA. Replacement of adjacent missing anterior teeth with scalloped implants: a case report. *Pract Proceed Aesthet Dent* 2005; 17:331–338.
 22. Mitrani R, Adolphi D, Tacher S. Adjacent implant-supported restorations in the esthetic zone: understanding the biology. *J Esthet Restor Dent* 2005; 17:211–223.
 23. Lekholm U, Zarb GA. Patient selection and preparation. In: Brånemark P-I, Zarb GA, Albrektsson T, eds. *Tissueintegrated prostheses: osseointegration in clinical dentistry*. Chicago: Quintessence Publishing Co, 1985:199–120.
 24. Rasband WS. ImageJ, 1997–2005. U.S. National Institutes of Health, Bethesda, Maryland, USA. Available at: <http://rsb.info.nih.gov/ij/> (accessed January 11, 2006).
 25. Abramoff MD, Magelhaes PJ, Ram SJ. Image processing with ImageJ. *Biophotonics Int* 2004; 11(7):36–42.
 26. Adell R, Lekholm U, Brånemark PI, et al. Marginal tissue reactions at osseointegrated titanium fixtures. *Swed Dent J* 1986; 28(Suppl):175–181.
 27. Cochran DL. Biologic width around titanium implants. A histometric analysis of the implant-gingival junction around unloaded and loaded non-submerged implants in a canine model. *J Periodontol* 1997; 68:186–198.
 28. Aalam AA, Nowzari H, Krivitsky A. Functional restoration of implants on the day of surgical placement in the fully edentulous mandible: a case series. *Clin Implant Dent Relat Res* 2005; 7:10–16.
 29. Vanden Bogaerde L, Pedretti G, Dellacasa P, Mozzati M, Rangert B, Wendelhag I. Early function of splinted implants in maxillas and posterior mandibles, using Brånemark System TiUnite implants: an 18-month prospective clinical multicenter study. *Clin Implant Dent Relat Res* 2004; 6:121–129.
 30. Ostman PO, Hellman M, Sennerby L. Direct implant loading in the edentulous maxilla using a bone density-adapted surgical protocol and primary implant stability criteria for inclusion. *Clin Implant Dent Relat Res* 2005; 7(Suppl):S60–S69.
 31. Friberg B, Dahlin C, Widmark G, Ostman PO, Billstrom C. One-year results of a prospective multicenter study on Brånemark System implants with a TiUnite surface. *Clin Implant Dent Relat Res* 2005; 7(Suppl 1): S70–S75.
 32. Glauser R, Ruhstaller P, Windisch S, et al. Immediate occlusal loading of Brånemark System TiUnite implants placed predominantly in soft bone: 4-year results of a prospective clinical study. *Clin Implant Dent Relat Res* 2005; 7(Suppl 1): S52–S59.
 33. Rocci A, Martignoni M, Gottlow J. Immediate loading in the maxilla using flapless surgery, implants placed in predetermined positions, and prefabricated provisional restorations: a retrospective 3-year clinical study. *Clin Implant Dent Relat Res* 2003; 5(Suppl 1):29–36.
 34. Pontoriero R, Carnevale G. Surgical crown lengthening: a 12-month clinical wound healing study. *J Periodontol* 2001; 72:841–848.
 35. Kois JC. Predictable single tooth peri-implant esthetics. Five diagnostic keys. *Compend Contin Educ Dent* 2001; 22:199–208.
 36. Salama H, Salama MA, Garber D, Adar P. Developing optimal peri-implant papillae within the esthetic zone. *J Esthet Dent* 1995; 7:125–129.
 37. Ochsenein C, Ross S. A concept of osseous surgery and its clinical applications. In: Ward HL, Chas C, eds. *A periodontal point of view: a practical expression of current problems integrating basic science with clinical data*. Springfield, IL: Charles C. Thomas Publishing, Co., 1973:276–323.
 38. Olsson M, Lindhe J. Periodontal characteristics in individuals with varying forms of the upper central incisors. *J Clin Periodontol* 1991; 18:78–82.
 39. Grunder U, Gracis S, Capelli M. Influence of the 3-D bone-to-implant relationship on esthetics. *Int J Periodontics Restorative Dent* 2005; 25:113–119.
 40. Campelo LD, Camara JR. Flapless implant surgery: a 10-year clinical retrospective analysis. *Int J Oral Maxillofac Implants* 2002; 17:271–276.

Copyright of Clinical Implant Dentistry & Related Research is the property of Blackwell Publishing Limited and its content may not be copied or emailed to multiple sites or posted to a listserv without the copyright holder's express written permission. However, users may print, download, or email articles for individual use.