

The Establishment of a Protocol for the Total Rehabilitation of Atrophic Maxillae Employing Four Zygomatic Fixtures in an Immediate Loading System – A 30-Month Clinical and Radiographic Follow-Up

Luis Rogério Duarte;* Hugo Nary Filho;† Carlos Eduardo Francischone;‡ Luiz Guillermo Peredo;§
Per-Ingvar Brånemark, PhD¶

ABSTRACT

Background: The existing approaches to the treatment of the atrophic maxilla are difficult and involve an element of risk.

Purpose: The aim of the present study was to establish a new surgical/prosthetic protocol for the treatment of extremely atrophic maxillae using four zygomatic implants (ZIs) in an immediate loading system.

Materials and Methods: Twelve patients were treated with the surgical placement of 48 ZIs, and the totally edentulous maxillae were rehabilitated with protocol-type maxillary prostheses rigidly fixed to the ZIs in an immediate loading system. Follow-up was conducted at 6 months and again at 30 months.

Results: Of the 48 ZIs inserted, one implant failed to achieve osseointegration. The prosthetic components fitted well and no sinus pathology was detected in any of the patients.

Conclusion: The surgical/prosthetic protocol showed that it was possible to insert four ZIs in an immediate loading system and achieve stability for up to 30 months.

KEY WORDS: atrophic maxilla, immediate loading, zygomatic implants

There are several technical approaches to the treatment of the atrophic maxilla involving a series of clinical considerations and producing different results. Special attention should also be given to the patients' aspirations.

*Professor, Postgraduate Implantology Program, Federal University of Bahia, Salvador, Bahia, Brazil; †Chair of Oral Surgery, Sagrado Coração University, Bauru, SP, Brazil; ‡Chair of Implantology, Sagrado Coração University, and Titular Professor of Operative Dentistry, São Paulo University, Bauru, SP, Brazil; §Master of Science in Implantology, private practice, Santa Cruz, Bolívia; ¶President of Brånemark Osseointegration Center, Göteborg, Sweden, and President of P. I. Brånemark Institute, Bauru, Brazil

Reprint requests: Luis Rogério Duarte, Av. Prof. Magalhães Neto, n.1541, SI. 4006, Instituto Renaissance, Pituba, Salvador, Bahia, Brazil CEP-41810-011; e-mail: luisrogerioduarte@mac.com

© 2007, Copyright the Authors
Journal Compilation © 2007, Blackwell Munksgaard

DOI 10.1111/j.1708-8208.2007.00046.x

Establishing a prognosis for the reconstructive rehabilitation of the atrophic maxilla using grafts is difficult for a number of reasons. These techniques involve an element of risk, since they demand good surgical technique, good quality soft tissues covering the graft, and a great deal of cooperation on the part of the patient as well as a general standard of health favorable to the repair. Unfortunately, these characteristics cannot always be found in the same patient, and thus complications tend to appear. Contamination or exposure of the graft may lead to partial or total graft loss. Even in those cases where the course of the treatment runs without incident and implants are placed, risks remain relative to the maintenance of both the hard and soft tissues.¹⁻³

The results obtained from these treatments with regard to the positioning of the implants, aesthetic quality, and functionality also have to be considered.⁴⁻⁷

Such highly invasive procedures invariably bring some degree of suffering to the patient and so it has been necessary to develop an alternative form of treatment for these cases.^{8,9}

The development of the zygomatic implant (ZI) (Nobel Biocare, Göteborg, Sweden) represents an excellent alternative for these situations. It is initially conceived as a treatment for the victims of traumas or tumor resection where there is considerable loss of maxillary structure. Following maxillectomy, many patients retain anchorage regions only in the body of the zygoma or in the frontal extension of the zygomatic bone.^{10,11} This being the case, a modification to the form of the implants is necessary, making the implants longer and inclining the head to make the prosthetic rehabilitation viable.

This technique has been applied in some research centers since 1989. Brånemark and colleagues¹² carried out the treatment of 81 patients in a preliminary study, installing 132 ZIs and obtaining a success rate of 97%. These results are similar to those obtained with conventional implants in all of the different alveolar regions. Taking the difficulties of the rehabilitation of this type of patient into consideration, such results confer on the technique a reasonably high degree of predictability.

At a second point in the development of this technology, ZIs have been used in patients who have presented severe maxillary atrophy in situations other than the sequelae of tumor resection. In these cases, the technique signifies a simplification of the treatment itself with reduction of costs, treatment time, and suffering, since the surgery is less invasive and has the same prognosis of success as treatment with conventional implants. The results obtained with these patients are encouraging its clinical use.¹³

Immediate loading allows the patient to be submitted to a joint surgical/prosthetic form of treatment without the need to wait for the normal period of osseointegration, allowing masticatory function to be restored by means of a fixed implant-supported complete denture.

Although the clinical reports of the immediate loading of implants in the literature to date only describe specific cases in the hands of skilled practitioners, the results have been good.⁷ The use of ZIs in immediate function is also encouraging since the rigid splinting of inclined implants distributes the axial

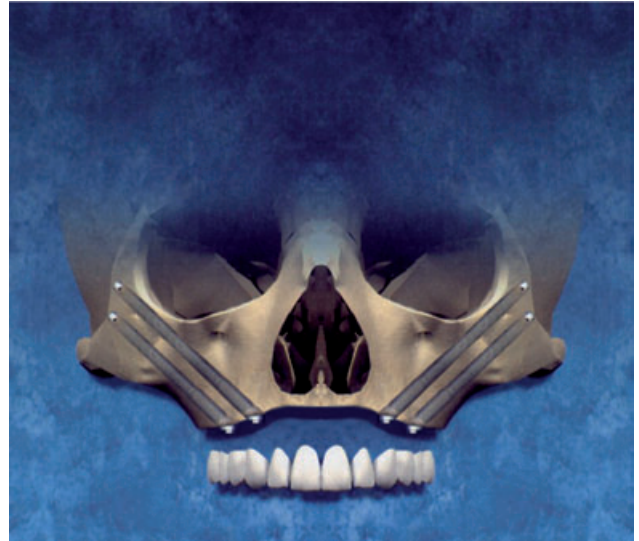

Figure 1 Scheme proposed in this study idealized by Prof. Brånemark (2001)¹⁶ (adapted from Nobel Biocare).

and lateral loads, thus stabilizing the rehabilitative system.^{14,15}

The majority of authors who have classified maxillary bone atrophy recognize that the rehabilitation of the severely resorbed maxilla is a challenge and usually recommend reconstruction with large autogenous bone grafts from extraoral donor areas.^{16–19}

The objective of this study was to develop and verify by means of clinical research the efficacy of a rehabilitative system for the atrophic maxilla employing four ZIs in an immediate loading system (Figure 1).

MATERIAL AND METHODS

Selection of Patients

The patients were selected from the implantology area of the surgery and prosthetics clinics of the postgraduate program in odontology at the Sagrado Coração University (Bauru, SP, Brazil) according to the following criteria:

1. an alveolar rim lacking the height, thickness, and arch perimeter that would make the insertion of four conventional implants possible in the anterior region, confirmed by means of panoramic radiography and computerized tomography; and
2. pneumatization of the sinus in the posterior region leaving only 1–2 mm of bone in the premolar region.

Patients who did not present an acceptable standard of health to undergo the surgical procedures proposed and patients who showed signs of bruxism were excluded.

Prior Prosthetic Preparation

The patients were subjected to a clinical evaluation with the aim of diagnosing possible deficiencies in the conditions of the alveolar rim and the prosthetic devices used.

The prostheses were evaluated in relation to functional and aesthetic characteristics such as the size and shape of the teeth, state of conservation, occlusal balance, vertical dimension, and phonetic and masticatory condition.

Records were obtained to produce complete dentures in the usual fashion.

Once tested in the mouth and approved by the patient and dentist, an impression of the teeth was taken that would serve as an index in the laboratory and to obtain a model of the prosthesis in clear acrylic resin, which was referred to as a “multifunctional guide” (MFG) (Figure 2). This “D”-shaped guide with a palatal point of support, which includes only the buccal surfaces of the teeth, is used for surgical orientation, and in the prosthetic phase to transfer the position of the implants to the plaster model, to make the impression, and to obtain a register of the occlusal relationship.

The tomographic study produced a three-dimensional reconstruction of the entire maxilla from 1-mm-thick sequential axial cuts (Figure 3). This reconstruction served to evaluate bone availability in the alveolar region and in the body of the zygomatic bone, so defining the surgical strategy. The possibility of exe-

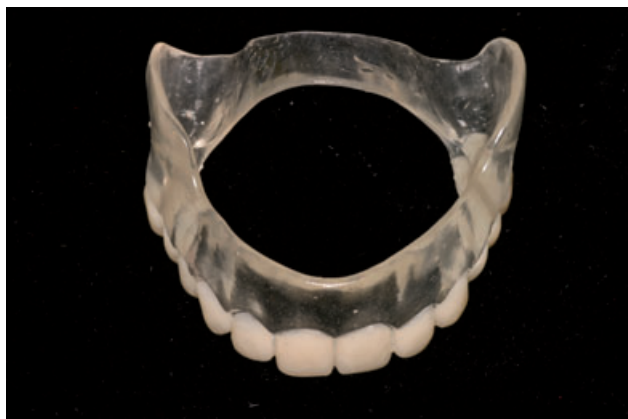

Figure 2 Replica of the wax-up in pressed acrylic, which functions as the multifunctional guide.

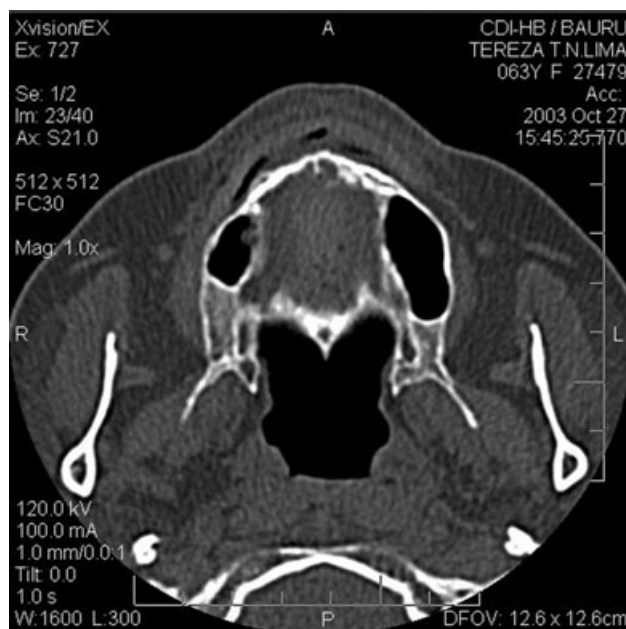

Figure 3 Computerized tomography – axial cut through the region of the maxilla.

cuting the technique using four ZIs, the positions of the implants, points of occlusal emergence, and lengths could then be estimated and the patient could proceed to the surgical phase.

As initial documentation, intra- and extraoral photographs, orthopantomographic and lateral skull cephalostat radiographs and posterior–anterior x-rays of the maxillary sinuses, as well as the abovementioned computer tomography, were all standardized.

Surgical Technique

Following general anesthesia, a crestal incision was made at the level of the alveolar ridge, extending from the region of the first superior molar on the left side to the first superior molar on the right side, with two oblique distal incisions through the mucosa and the periosteum, lifting a full thickness flap. In this process, the ample exposure of the maxilla (Figure 4), the buccal face of its edge, piriform opening, foramen and infraorbital edge, and the body of the zygomatic arch were sought. Part of the palate was also dissected, making observation of the whole anatomy easier.

Bone windows 5 mm wide and 10 mm long were made on either side of the most superior and lateral aspect of the anterior wall of the maxilla, with spherical diamond-tipped burs, while attempting to maintain the integrity of the sinus membrane. The mucosa was laterally displaced, from the portion of the alveolar ridge

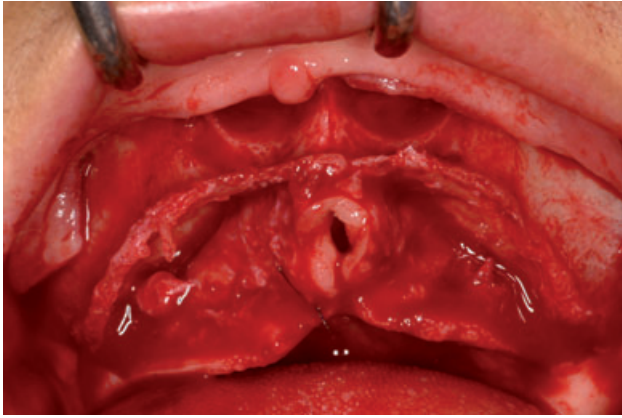


Figure 4 Total exposure of the maxilla following incision.

to the body of the zygomatic bone, where the implant was to be placed.

The direction of the drilling took into consideration the biomechanics of the future rehabilitation and design of the prosthesis by seeking to project the emergence of the distal implants as far to the posterior as possible. The anterior implants took the region of the canines and the lateral incisors as a reference for the occlusal point of emergence. Observation of the local bone anatomy was, however, the determining factor in directing the drilling to avoid fenestration to the buccal and lingual sides. Another objective was to diminish the palatine projection of the implants while respecting the previously described limits. In all cases, the direction of the implants was anterior–posterior, and although there was a distancing of the platforms, the apices remained very close. If bone was not available for the implants in the zygomatic region, then the lateral wall of the orbit was approached at a tangent protecting the eye with separators (Figure 5).

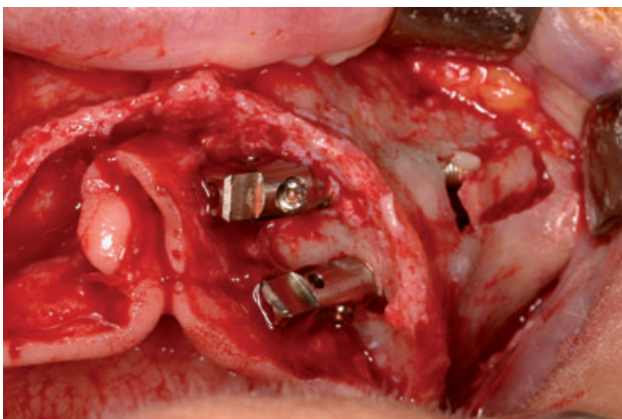


Figure 5 ZI distal installation on premolar or first molar position and ZI installation on mesial canine position.

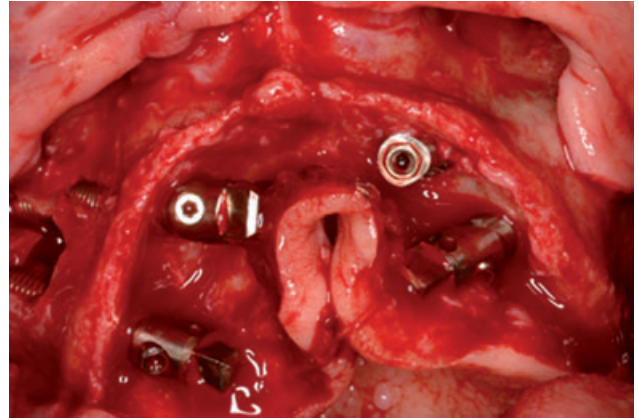


Figure 6 ZIs installed according to the technique recommended in this study.

The drilling sequence included only three burs: a 2.9-mm spherical burr and cylindrical burs of 2.9 and 3.5 mm in diameter. Pilot burs were not used to avoid further dilation of the alveolar bone portion, which was always very slender. The insertion of the implants followed the recommended technique (Figure 6), seeking an anchorage in the body of the zygomatic bone and in the ridge at the rim of the maxilla. The occlusal point of emergence was defined by the trajectory of the perforations; however, the inclination of the platform of the head of the implant was defined by the objective of parallelism between the abutments to be installed. The MFG proved very useful for defining the final positions of the implants.

The drilling, as well as the insertion of the 4- to 5-mm machine-surfaced ZIs (Nobel Biocare AB), was performed under constant water irrigation to prevent

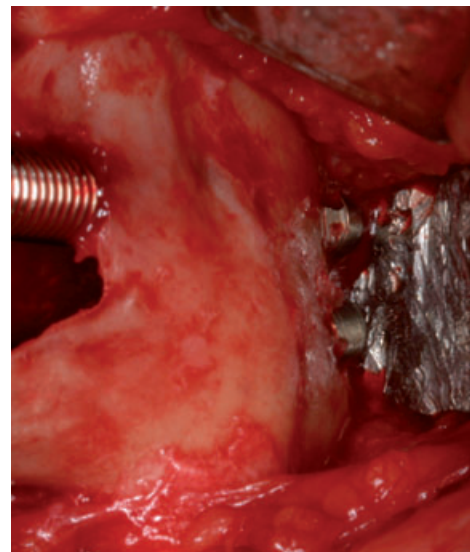


Figure 7 Top of the ZIs through zygomatic bone.

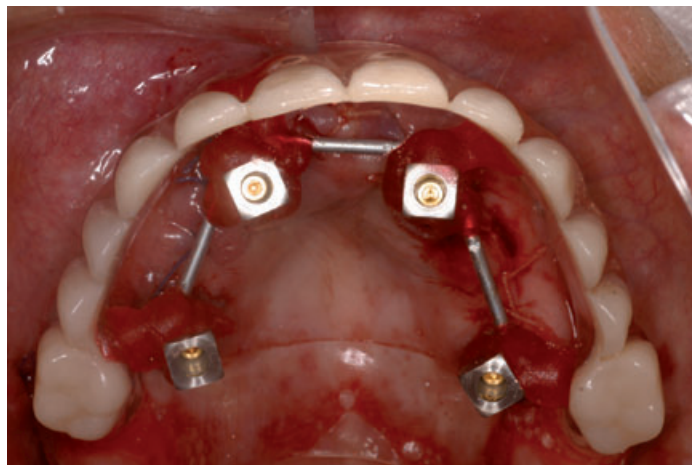


Figure 8 Transfers joined to the multifunctional guide.

overheating. The parameter for the seating level of the implant was the height of the surrounding bone ridge. It was sought to leave the hexagonal platform of the head of the implant well above the level of the ridge, not always allowing for the total covering of the threads (Figure 7).

With the subsequent selection, placement, and tightening of the standard prosthetic abutments (3i Implant Innovations, Palm Beach Garden, FL, USA) and the suture of the soft tissue, the surgical phase ended, and the prosthetic phase began.

Prosthetic Phase

Approximately 6 hours after the conclusion of the surgical procedure, the transfers were screwed onto the abutments, and the MFG, produced at the time of prior prosthetic preparation, was placed into the mouth and attached to the transfers using acrylic pattern resin (Figure 8) (GC America, Inc., Alsip, IL, USA). The max-

illomandibular relationship was recorded using the same resin at four different points along the MFG (Figure 9), while lubricating the mandibular teeth with vaseline. Fifteen minutes were allowed for the polymerization of the pattern resin, and then the patients were asked to open and close their mouths repeatedly to check the accuracy of the records.

Low-viscosity condensation silicon-type impression material (Zhermack, Badia-Polesine, Italy) was then injected between the open tray transfers and the MFG to copy as many details around the abutments and soft tissues as possible. Once the impression was obtained, the transfers were unscrewed, the MFG was removed, protective caps were placed back over the abutments, and the patients were discharged.

The analogs were screwed onto the transfers inside the impression and a silicone gingiva (Gingifast, Zhermack) was applied around them. Once the plaster

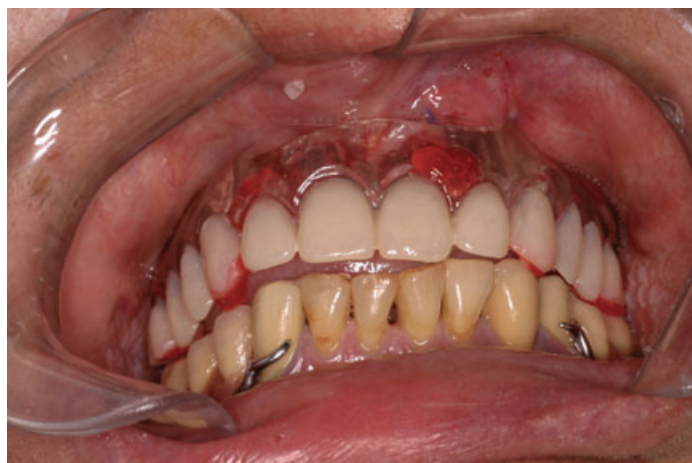

Figure 9 Maxillomandibular relationship was recorded using the same resin at four different points along the multifunctional guide.

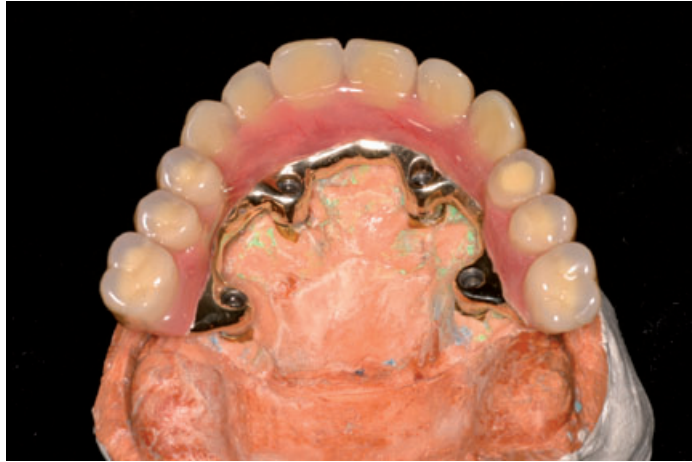

Figure 10 Prostheses ready to be clinically tested in the patient's mouth.

model had set, it was positioned in the articulator with the MFG still attached using the four occlusal points registered in the mouth. The metallic framework of the prosthesis was founded in type IV gold (Stabilor G, Degussa, Dusseldorf, Germany) to promote rigidity, aesthetic quality, hygiene, and mechanical retention and was tested for passivity the next day by screwing the framework into position over the abutments to verify the seating.

The acrylic teeth were fixed to the gold framework with wax for a try-in to check the predetermined aesthetic and occlusal characteristics of the tooth assemblies. And finally, the acrylization was carried out (Figure 10).

Immediately after the finished prostheses were placed, the occlusal adjustments recommended by Kim and colleagues²⁰ were made (Figure 11).

Immediate Postoperative Evaluation

An immediate clinical evaluation was carried out to check for postoperative characteristics such as the presence of edema and hematomas, sensorial and motor alterations, and pain. The quality of the mucosa and the presence of peri-implantary tissue inflammation were also observed at this point.

Orthopantomographic and Waters posterior–anterior radiographs (facial sinuses) were taken to identify the position of the fixtures, the adaptation of the prosthetic components, and the condition of the sinuses.

Postoperative Control Period

The patients were subject to monthly clinical controls at which small occlusal adjustments were made, including

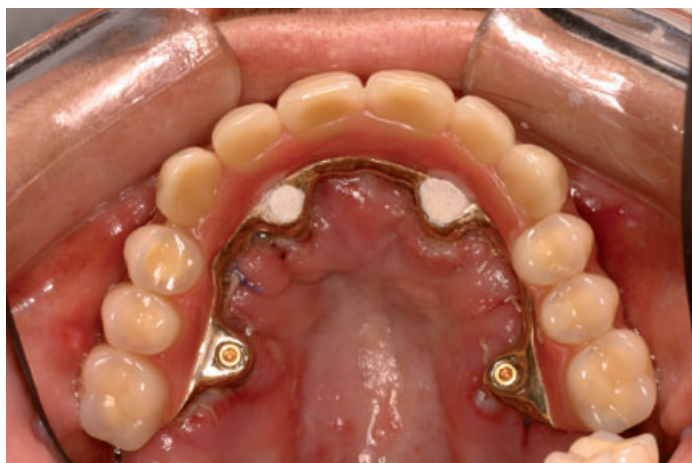

Figure 11 Occlusal view of the installed prosthesis.

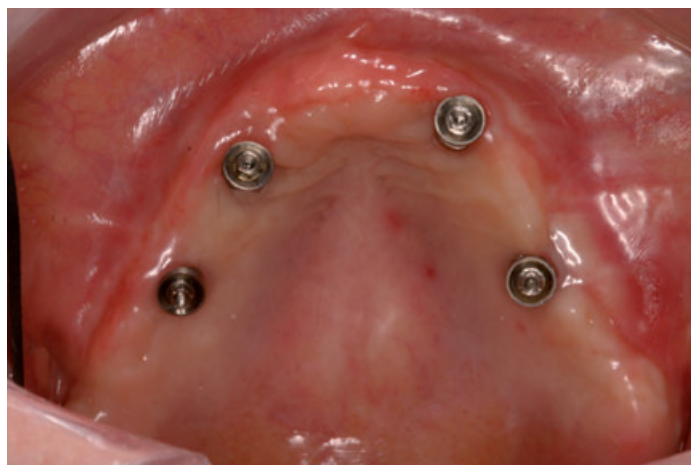

Figure 12 Occlusal view of the prosthetic abutments following the removal of the prosthesis after 6 months.

hygiene and plaque-control sessions, during the 6-month period following the placement of the prostheses.

6-Month Evaluation

The data for this study was collected 6 and 30 months after surgery when the prostheses and prosthetic abutments were removed for cleaning, and the implants were clinically verified for absence of pain and mobility by individual manipulation (Figure 12).

Following replacement, the screws were immediately tightened; occlusion was rechecked, and orthopantomographic radiographs and posterior–anterior and Waters x-rays were taken, paying special attention to the radiotransparency of the maxillary sinuses.

RESULTS

In this study, 48 ZIs were installed in 12 patients over a 9-month period. At the 6-month evaluation, only one implant was considered unsuccessful, as the removal of the prosthetic abutment was not possible since the implant presented rotational mobility. Even so, the patient was asymptomatic, and there was no gingival inflammation.

At the 6-month control, gingival inflammation of the mucosa around the abutments was present in some cases and not in others, although it was not always possible to associate this with the patients' standards of hygiene, since both types of response could be seen in the same arch. The probing procedures were difficult to carry out due to the length of the abutments and the shape of the heads of the implants.

All the prostheses were in good condition; none of the screws were loose, nor was there significant wear. The patients were able to maintain adequate hygiene except

where the acrylic gingiva was very close to the keratinized mucosa. It was only necessary to modify one prosthesis due to the loss of a ZI. In this case, the infrastructure and the three remaining fixtures were retained, and the immediate adaptation to the substituted implant was carried out.

Identification of any sinus pathologies was sought from the posterior–anterior x-rays because these images show little detail of the bone–titanium interface area while the periapical x-rays, which serve to verify the adaptation of the prosthetic components, offer little information about the maxillary sinus due to the superimposition of the bone ridge. The maxillary sinuses presented normal radiotransparency during the 6-month period with the exception of the regions near the implants where some proliferative process may have occurred. No radiographic alterations that would compromise the stability of the implants were observed, even in the case of the implant that was considered unsuccessful. Equally, no problems were noted with the fitting and position of the prosthetic components or of the metallic infrastructure.

At the 30-month follow-up, one further implant presented rotational mobility and also had to be replaced. Nevertheless, all the patients demonstrated great satisfaction with the treatment and with the improvements in masticatory, aesthetic, phonetic, and psychological conditions and so would recommend it.

DISCUSSION

The first observation to be made is that great attention must be paid to the prosthetic/surgical protocol proposed here.

The surgical procedure demands good knowledge of the anatomical area involved, since the bone available in the body of the zygoma in some patients was insufficient for the anchorage of the implants. In these cases, it was necessary to direct the implants toward the eye socket, and this caused some postoperative discomfort such as conjunctival and periorbital edema and hematoma, although these healed in a few days. The surgeries also demanded ample exposure of the sinuses and the removal of a considerable window in the anterior wall of the maxilla with large vestibular fenestrations principally for the anterior implants. One interesting finding was that postoperative paresthesia lasted for weeks before the symptoms abated.

The prosthetic procedure followed the conventional guidelines using standard abutments and the MFG for the transfer and register of the occlusal relations. The handling of these patients, however, involved adapting those guidelines since the surgical procedures were executed in the hospital, and the prosthetic stage was undertaken in the clinic. This meant that it was necessary to wait between 4 and 8 hours for the patients to recuperate following surgery. However, this wait did not delay the finalization of the prostheses, which were completed between 2 and 4 days after the surgeries.

The drilling for the implants which are to be placed in the region corresponding to the canines or lateral incisors requires special attention from the surgeon with regard to the anatomical features that may affect the insertion of the implant. Once located, the infraorbital nerve serves as a reference point maintaining the oblique position of the drill in the direction of the superior portion of the zygomatic bone, which forms part of the lateral wall of the eye socket. In two of the cases in this study, there was invasion of the orbital cavity, since it presented a concavity which was inevitably breached when the best anchorage point in the zygomatic bone was sought.

A hematoma could be seen in both cases immediately after surgery, caused by bleeding at the level of the sclera and the subconjunctival tissue. The hematomas regressed completely within 15 days and no further symptoms were reported by the patients, but these cases underline the importance of using biomodels, which should be standard reverse planning protocol when the technique proposed in this study is used.

The principal objective of surgery for immediate loading is the anchorage and primary stabilization of the

implants so that osseointegration, which occurs during the normal healing and bone remodeling period, can take place protected by the metallic infrastructure, which in turn provides highly important secondary stability for the balance of the system.^{12,14,21} An important detail underpinning the technique proposed is the underdrilling achieved by using neither the pilot burr nor the 4-mm burr recommended in the classic system. In this way, extremely rigid anchorage is achieved providing excellent initial stability to such an extent that in some cases in this study, the mounting bent under the torque of manual insertion without damaging the head of the implant and had to be substituted. Care must also be taken opening the patient's mouth so that the position equivalent to the second premolars proposed by this protocol may be fixed as far to the posterior as possible, optimizing the cantilever and increasing the area of the polygon created. In certain cases, a lesion was caused to the corner of the mouth by the burr in attempting to reach the ideal drilling point, but it is worth pointing out that, in all the patients, a polygonal distribution with only small variations due to individual anatomic availability was achieved.

In the cases described in this study, we noted that the canine pillars were so resorbed as to make the insertion of conventional implants impossible. In cases where immediate loading is recommended, the use of the technique proposed here increases the possibility of anchorage of the implant, since its apex is positioned in the zygomatic bone offering a distribution of axial and lateral loads in a structure of excellent quality from the anatomical point of view.^{22,23}

The placement of the abutments during the surgical phase is made easier by the complete opening of a mucoperiosteal flap, but it is important to be aware that conjunctive tissue in the palate as well as gingiva and soft tissue around the implants may facilitate the retention of food and the formation of plaque. The prosthetic gingiva must be as convex as possible to facilitate oral hygiene procedures. Some peri-implantary inflammation and bleeding was observed in the cases treated but had not compromised osseointegration by the time of the 6- and 30-month reevaluations. Perhaps the cause of these alterations is the perforation of the head of the implant, which houses the abutment screw and which creates a third slot in the system of fittings, facilitating the migration and access of bacteria. A possible future change in the design of ZIs may reduce this difficulty

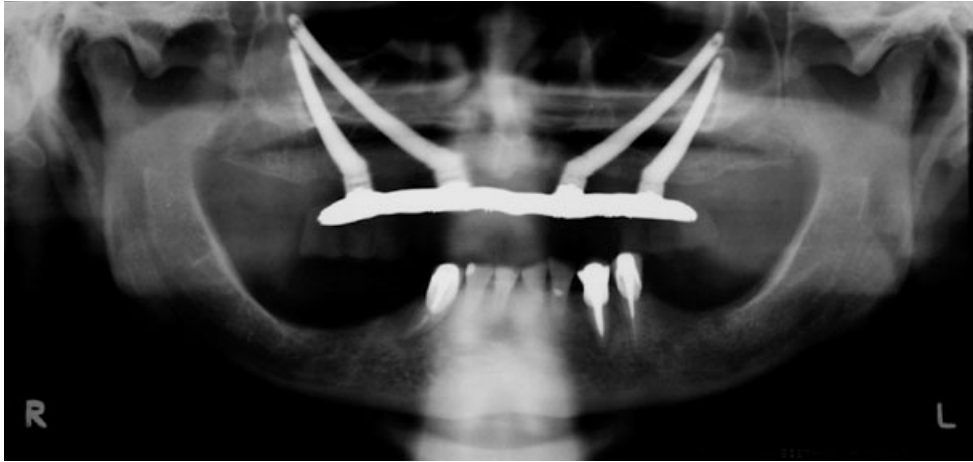


Figure 13 Immediate postoperative panoramic x-ray.

despite us believing, in accordance with the literature, that other factors also influence alterations in the tissues.²⁴

In the prosthetic phase, it was noticed that a precise MFG made the procedure of transferring the positions of the implants easier. It also facilitates the work of reassembling the articulator and remounting the teeth by providing the lab technician with references, meaning that the treatment time proposed in this study may be respected. Panoramic (Figure 13) and periapical x-rays were always taken at the time of testing in the mouth to observe the seating of the framework in order to give passivity to the prosthetic system. There were no technical difficulties in carrying out these tests except the swelling, which caused a certain discomfort to the patients.

In the prosthetic installation phase, the definitive gold screws were also placed without difficulty. In some cases, the insertion plane of the prosthesis was posterior to anterior where the implants diverged to achieving a greater area of polygon. In accordance with the proposed protocol, the occlusal adjustments were then carried out. In the case of patient number 2, where the looseness of the system at the 6-month follow-up confirmed the rotation of fixture 1 (Table 1), the occlusal adjustment was deficient, probably causing anterior overloading. The patient also exhibited signs of bruxism, with wear to the lower removable partial prosthesis, and missed the first control for personal reasons. Despite the loss of this implant, the prosthesis continues to function, and the patient remained asymptomatic 30 months after the surgery. In the case of patient number 5, where fixture number 4 was considered a

failure at the 30-month follow-up (Table 2), stability was similarly recovered by the insertion of a new implant.

The radiographic tests conducted at the 6-month follow-up were repeated at 30 months (Figure 14). One of the concerns with this technique would be the possibility of alterations in the sinus mucosa, since all of the membranes are perforated during the surgical procedure. No pathology was observed during the follow-up period, and as in the study by Petruson,²⁵ who carried out sinuscopy in several patients rehabilitated with ZIs, no pathological alteration occurred during the 30-

TABLE 1 Life Table Showing the Number of Successful Implants at 6 Months

Patients	Osseointegration 6-Month Reevaluation			
	ZI 1	ZI 2	ZI 3	ZI 4
1	●	●	●	●
2	○	●	●	●
3	●	●	●	●
4	●	●	●	●
5	●	●	●	●
6	●	●	●	●
7	●	●	●	●
8	●	●	●	●
9	●	●	●	●
10	●	●	●	●
11	●	●	●	●
12	●	●	●	●

Legend ● Yes ○ No

TABLE 2 Life Table Showing the Number of Successful Implants at 30 Months

Patients	Osseointegration 30-Month Reevaluation			
	ZI 1	ZI 2	ZI 3	ZI 4
1	●	●	●	●
2	○	●	●	●
3	●	●	●	●
4	●	●	●	●
5	●	●	●	○
6	●	●	●	●
7	●	●	●	●
8	●	●	●	●
9	●	●	●	●
10	●	●	●	●
11	●	●	●	●
12	●	●	●	●

Legend ● Yes ○ No

month follow-up period. No problems with the fitting and position of the prosthetic components or framework were observed during the radiographic follow-up period.

CONCLUSION

While respecting the limitations and short control period of this study, it may be concluded that the rehabilitation of atrophic maxillae proposed here, using four ZIs in an immediate loading system, is practicable for surgeons with broad clinical experience and that it appears to represent an excellent alternative to bone graft techniques.

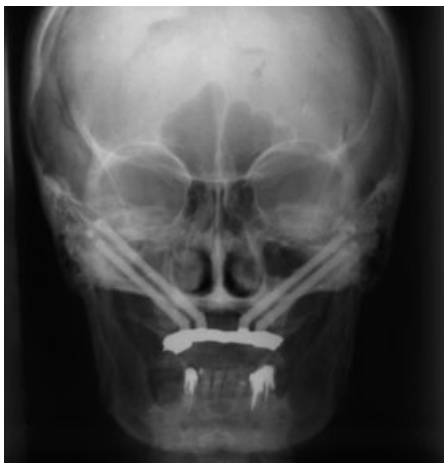

Figure 14 Maxillary sinus x-ray at 30-month control.

ACKNOWLEDGMENT

The authors express special thanks to Dr. Tomas Albrektsson for his friendship and advice.

REFERENCES

1. Kahnberg K-E, Nyström E, Bartholdsson L. Combined use of bone grafts and Brånemark fixtures in the treatment of severely resorbed maxillae. *Int J Oral Maxillofac Implants* 1989; 4:297–304.
2. Adell R, Lekholm U, Rockler B, Brånemark PI. A 15 year of study of osseointegrated implants in the treatment of edentulous jaw. *Int J Oral Surg* 1981; 6:387–416.
3. Nyström E, Kahnberg K-E, Gunne J. Bone grafts and Brånemark implants in the treatment of the severely resorbed maxilla: a 2-year longitudinal study. *Int J Oral Maxillofac Implants* 1993; 8:45–53.
4. Desjardins RP. Prosthesis design for osseointegrated implants in the edentulous maxilla. *Int J Oral Maxillofac Implants* 1992; 7:311–320.
5. Jemt T, Lekholm U. Implant treatment in edentulous maxillae: a 5 year follow-up report on patients with different degrees of jaw resorption. *Int J Oral Maxillofac Implants* 1995; 10:303–311.
6. Keller EE, Tolman DE, Eckert SE. Maxillary antral-nasal autogenous bone graft reconstruction of compromised maxilla: a 12-year retrospective study. *Int J Oral Maxillofac Implants* 1999; 14:707–721.
7. Filho HN, Ilg JP. Atrofia severa da maxila. In: Dinato JC, Polido WD, eds. *Implantes osseointegrados: cirurgia e prótese*. 1st ed. São Paulo, Brazil: Artes Médicas, 2001:343–372.
8. Roumanas E, Nishimura R, Beumer III J, Moy P, Weinlander M, Lorant J. Craniofacial defects and osseointegrated implants: six year follow-up report on the success rates of craniofacial implants at UCLA. *Int J Oral Maxillofac Implants* 1994; 9:579–585.
9. Venturelli A. A modified surgical protocol for placing implants in the maxillary tuberosity: clinical results at 36 months after loading with fixed partial dentures. *Int J Oral Maxillofac Implants* 1996; 11:743–749.
10. Jensen OT, Brown C, Blacker J. Nasofacial prostheses supported by osseointegrated implants. *Int J Oral Maxillofac Implants* 1992; 7:203–211.
11. Weischer T, Schettler D, Mohr C. Titanium implants in the zygoma as retaining elements after hemimaxillectomy. *Int J Oral Maxillofac Implants* 1997; 12:211–214.
12. Brånemark PI, Grondahl K, Öhrnell L-O, et al. Zygoma fixture in the management of advanced atrophy of the maxilla: technique and long-term results. *Scand J Plast Reconstr Surg Hand Surg* 2004; 38:70–85.
13. Matsumoto MA. Fixação zigomática. *Pesquisa Odontológica Brasileira Brazilian Oral Research*. Vol.14. São Paulo, Brazil: SBPQO, Universidade de São Paulo, 2000:21.

14. Duarte LR, Peredo LG, Filho HN, Franchischone CE, Brånemark P-I. Reabilitação da maxila atrofica utilizando quatro fixações zigomáticas em sistema de carga imediata. *Implants News* 2004; 1:25–30.
15. Bedrossian E, Stumpel L. Immediate stabilization at stage II of zygomatic implants: rationale and technique. *J Prosthet Dent* 2001; 86:10–14.
16. Brånemark PI, Grondahl K, Worthington P. Osseointegration and autogenous onlay bone grafts: reconstruction of the edentulous atrophic maxilla. 1st ed. Chicago, IL: Quintessence Books, 2001:160.
17. Sutton DN, Lewis BRK, Patel M, Cawood JI. Changes in facial form relative to progressive atrophy of the edentulous jaws. *Int J Oral Maxillofac Surg* 2004; 33:676–682.
18. Misch CE. Classificação e planos de tratamento para arcos parcial e completamente edêntulos em implantodontia. In: Misch CE, ed. *Implantes dentários contemporâneos*. São Paulo, Brazil: Santos, 2000:163–174.
19. Spiekermann H. *Color atlas of dental medicine – implantology*. Stuttgart, Germany: Tieme, 1995:388.
20. Kim Y, Oh T-J, Misch CE, Wang H-L. Occlusal considerations in implant therapy: clinical guidelines with biomechanical rationale. *Clin Oral Implants Res* 2005; 16:1–26.
21. Jiménez-López V. Carga ou função imediata em implantodontia: aspectos cirúrgicos, protéticos, oclusais e de laboratório. São Paulo, Brazil: Quintessence Editora Ltda, 2005:288.
22. Rigollizzo MB, Camilli JA, Francischone CE, Padovani CR, Brånemark PI. Zygomatic bone: anatomic bases for osseointegrated implant anchorage. *Int J Oral Maxillofac Implants* 2005; 20:441–447.
23. Nkenke E, Hahn M, Lell M, et al. Anatomic site evaluation of the zygomatic bone for dental implant placement. *Clin Oral Implants Res* 2003; 14:72–79.
24. Al-Nawas B, Weneger J, Bender C, Wagner W. Critical soft tissue parameters of the zygomatic implants. *J Clin Periodontol* 2004; 31:497–500.
25. Petruson B. Sinuscopy in patients with titanium implants in the nose and sinuses. *Scand J Plast Reconstr Surg Hand Surg* 2004; 38:86–93.

Copyright of Clinical Implant Dentistry & Related Research is the property of Blackwell Publishing Limited and its content may not be copied or emailed to multiple sites or posted to a listserv without the copyright holder's express written permission. However, users may print, download, or email articles for individual use.

Copyright of Clinical Implant Dentistry & Related Research is the property of Blackwell Publishing Limited and its content may not be copied or emailed to multiple sites or posted to a listserv without the copyright holder's express written permission. However, users may print, download, or email articles for individual use.