

Survival of NobelDirect Implants: An Analysis of 550 Consecutively Placed Implants at 18 Different Clinical Centers

Tomas Albrektsson, MD, PhD;* Jan Gottlow, DDS, PhD;† Luiz Meirelles, DDS;‡ Per-Olov Östman, DDS;§ Antonio Rocci, DDS;¶ Lars Sennerby, DDS, PhD*

ABSTRACT

Background: A recently introduced implant, the NobelDirect (Nobel Biocare AB, Göteborg, Sweden), has previously been documented with substantial bone resorption in a large number of operated cases.

Purpose: The aim of this study was to evaluate the failure rate of NobelDirect implants in a retrospective multicenter survey.

Materials and Methods: A total of 550 NobelDirect implants consecutively placed in over 269 patients at 18 centers were evaluated with regard to failure rate after an average follow-up of about 1 year.

Results: The overall failure percentage was 10.9% (59 failures). The 58 implants not loaded directly showed only one failure (1.7%) versus 58 failures (11.8%) of those implants that were loaded directly. A chemical x-ray photoelectron spectroscopy analysis of an implant from the original batch showed up to 3.5% silicon at parts of the implants. A retrieval analysis of one implant removed at 2 years after placement demonstrated bone resorption down to the level of the fifth thread.

Conclusions: It is concluded that the NobelDirect implant, if placed with a punch procedure, ground down in situ, and loaded directly, shows an unusually high failure rate at 1 year.

KEY WORDS: dental implants, failures, one-piece implant, retrospective clinical study

The NobelDirect implant (Nobel Biocare AB, Göteborg, Sweden) was launched clinically in 2004. The implant was claimed by the company to be simple to use by a nonspecialist and to result in negligible bone resorption. The implant was recommended for place-

ment without surgical flaps, to be loaded directly, and to be ground down in situ to fit the crown.

Previous studies have reported on problems with bone resorption around NobelDirect/Perfect implants.¹⁻³ The present article was aimed at a survival analysis of NobelDirect implants and includes the 115 implants previously reported by Östman and colleagues² and the 117 implants previously reported by Sennerby and colleagues,³ but now analysed for a further follow-up of about half a year. In addition, this article presents a survival analysis of yet another 318 consecutively placed NobelDirect implants not previously published, that is, a total of 550 implants are reported. Furthermore, a chemical analysis of one NobelDirect implant from a 2004 batch is presented and a retrieval analysis of one implant is reported.

MATERIALS AND METHODS

The current retrospective material consisted of 550 consecutively placed NobelDirect implants in more than 269 patients at 18 different clinics (Table 1). In this

*Professor, Department of Biomaterials, Institute for Clinical Sciences, Sahlgrenska Academy, University of Göteborg, Göteborg, Sweden; †associate professor, Department of Biomaterials, Institute for Clinical Sciences, Sahlgrenska Academy, University of Göteborg, Göteborg, Sweden, and The Brånemark Clinic, Public Dental Health Service, Göteborg, Sweden; ‡research fellow, Department of Biomaterials, Institute for Clinical Sciences, Sahlgrenska Academy, University of Göteborg, Göteborg, Sweden; §research fellow, Department of Biomaterials, Institute for Clinical Sciences, Sahlgrenska Academy, University of Göteborg, Göteborg, Sweden, and private practice, Falun, Sweden; ¶clinical director, private practice, Chieti, Italy

Reprint requests: Prof. Tomas Albrektsson, Department of Biomaterials, Institute for Clinical Sciences, Sahlgrenska Academy, Göteborg University, PO Box 412, SE 405 30 Göteborg, Sweden; e-mail: tomas.albrektsson@biomaterials.gu.se

© 2007, Copyright the Authors

Journal Compilation © 2007, Blackwell Munksgaard

DOI 10.1111/j.1708-8208.2007.00054.x

TABLE 1 Overview of NobelDirect Implants of the Present Study

Center	Implants	Failed implants	% Failure
1	158	7	4.4
2	115	7	6.1
3	69	12	17.4
4	57	7	12.3
5	31	2	6.5
6	21	2	9.5
7	20	4	20.0
8	15	5	33.0
9	11	2	18.1
10	11	0	0
11	10	8	80.0
12	8	1	12.5
13	6	0	0
14	6	0	0
15	5	0	0
16	4	0	0
17	2	1	50.0
18	1	1	100.0
All	550	59	10.7

article, the implants were only analysed with respect to survival or failure with a closing date of December 31, 2006. Survival is defined as an implant still in the jaw of the patient and does not inform of quality of survival; hence, a surviving implant may be functioning excellently or displaying severe side effects in the form of bone saucerization or other clinical problems. Failed implants are defined as those that have been removed from the jaws for one reason or another. Unaccounted for implants are those wherein the patient has dropped out of the study for any reason.

The participating clinicians submitted information about the number of placed and failed implants, implant length/diameter, position, and type of loading protocol. Implants loaded within 6 weeks were regarded as belonging to the immediate/early loading group and

implants with more than 6 weeks of healing to the delayed loading group.

The average follow-up time in this material was about 1 year, with a range of 1 month to 2 years.

Chemical Analysis

The chemical composition of a NobelDirect implant from a 2004 batch was monitored using x-ray photoelectron spectroscopy (XPS); a PHI 5500 (Perkin Elmer, Physical Electronics division). At the delivery of the implant to the chemical analysis unit, it was still in its unbroken, sterile package. Monochromatic AlK α X-ray radiation operated at 350 W was utilized, and the relative energy scale was fixed with C 1s. Morphological description was performed with scanning electron microscopy (SEM) using a LEO Ultra 55 FEG SEM (Leo Electron Microscopy Ltd, Cambridge, UK) equipped with an Oxford Inca EDX system (Oxford Instruments Nano Analysis, Bucks, UK), operating between 1 and 7 kV. A secondary electron detector was used to obtain images with good topographical resolution.

Retrieval Analysis

A 77-year-old female patient received three NobelDirect implants on each side in the mandible. Surgery was performed according to the NobelDirect protocol but with an open flap procedure. Implants were placed bilaterally in the first premolar and in the first and second molar positions (Figure 1A). Immediately after surgery, impressions were taken for fabrication of temporary bridges that were mounted on the same day. Careful adjustment of occlusal contact was performed. Three months post insertion, at the time for definitive impression, the patient complained of pain in the posterior area on both sides. Clinically, pus was visible around the rightmost posterior implant and, radiographically, some bone loss was observed. Extensive hygienic efforts were performed to stop the infection. At the 6-month follow-up, radiographs showed craterlike destructions around three of the implants. One year after insertion, the two most posterior implants in the left mandible were removed by a trephine. The implants were surrounded by granulation tissue in a craterlike destruction. Two years after insertion, the implant in the right first molar region was also removed due to unacceptable bone loss (see Figure 1B).

The latter implant was retrieved and immersed in 4% neutral, buffered formaldehyde for fixation. The

TABLE 2 Number of Placed and Failed Implants with Regard to Loading Time

	Implants	Lost	%
All implants	550	59	10.7
Immediate/early loading	492	58	11.8
Delayed loading	58	1	1.7

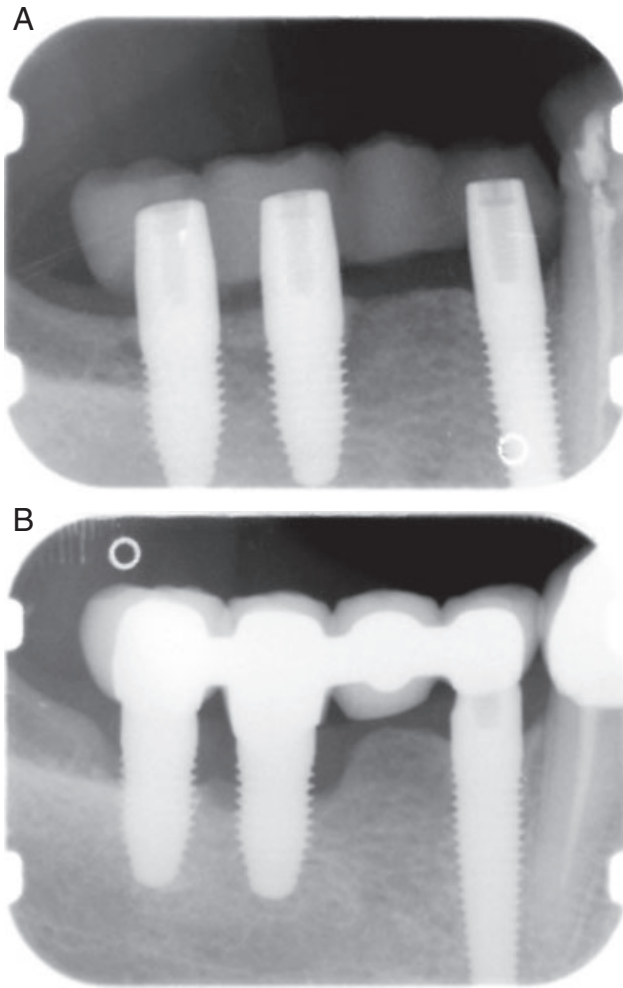


Figure 1 Radiographs of NobelDirect implants in the right mandible (A) at placement and (B) after 1 year of loading. Note the marginal bone resorption. The middle implants were surgically removed after 2 years of loading.

specimen was then dehydrated in a graded series of alcohol solutions and embedded in a light-curing resin (Technovit 7200, VLC, Heraeus Kultzer GmbH & Co., Wehrheim, Germany). Cutting and grinding was performed as described by Donath.⁴ The final sections were approximately 10 μ m thick and were stained with toluidine blue. Histologic analyses were performed in a Nikon H 550L microscope (Teknoptik AB, Huddinge, Sweden) coupled to an HP 7100CMT computer with appropriate software. Analyses were performed using lenses of 10 to 40 \times magnification and eye pieces of 10 \times magnification.

RESULTS

The overall clinical results of the 550 implants with an average follow-up time of 1 year showed 59 failures, that is, a failure percentage of 10.7%. When separating the 58

implants that were loaded after 6 weeks of healing from the 492 that were immediately/early loaded according to the instructions from the manufacturer, we had one failure (1.7%) in the former but 11.8% failures in the latter group (Table 2). Two implants (in two patients) were unaccounted for. Although 80 implants lacked information about length and diameter, the 55 3-mm implants showed a failure rate of 20%; all but one had been subjected to immediate/early loading (Table 3).

The retrieved implant had no visible bone contact above the level of the fifth thread (Figure 2A). Fibrous tissue rich with inflammatory cells separated the implant and the bone. Plaque and bacteria were observed on the implant surface. The bone surfaces at the bottom of the defect showed signs of ongoing resorption (see Figure 2B). In four threads, there was sparse bone-implant direct contact; the bone inside the threads had numerous cement lines giving it a rather disordered design compared to general findings around retrieved implants.

From a chemical point of view, XPS analyses (Table 4) revealed small amounts of nitrogen and silicon and high amounts of phosphorus. There were titanium and carbon peaks, too, the latter consisting of C-C bindings, possibly originating from hydrocarbons in the surrounding air. The levels of silicon were rather significant at the peak of the screw, about 3.5%. Levels of phosphorus in the middle of the screw were 7.8%.

DISCUSSION

Osseointegration is, generally, a successful procedure resulting in high levels of clinical benefits for partly or totally edentulous individuals.⁵⁻⁹ However, osseointegration is not identical to clinical success; if biology is challenged, the response may be bone saucerization and increased rates of implant failure. We have repeatedly seen this unwanted response with different oral implant

TABLE 3 Number of Placed and Failed Implants with Regard to Implant Diameter

	Implants	Lost	%
3 mm	55	11	20
3.5 mm (Narrow Platform)	68	8	11.8
4.3 mm (Regular Platform)	287	8	2.8
5.0 mm (Wide Platform)	60	8	13.3
Information missing	80	24	—
All	550	59	10.7

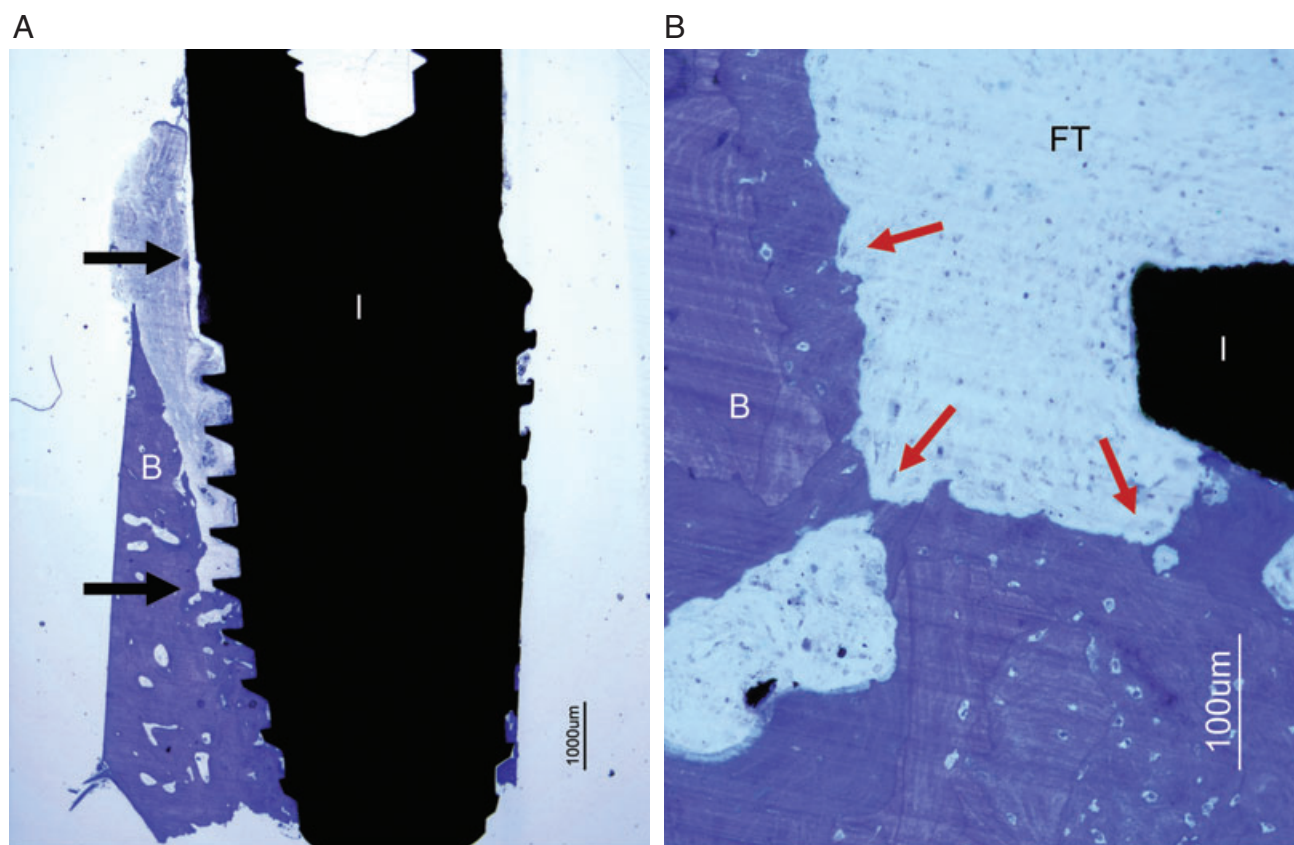


Figure 2 A, Light micrograph showing an overview of the retrieved clinical implant showing bone resorption to the level of the fifth thread at 2 years. Arrows point to the reference point and the bottom of the vertical bone defect. Bar = 1 mm. Toluidine blue. B, Close up of the bottom of the defect. The bone (B) surfaces are showing ongoing resorption (arrows). Bar = 100µm. Toluidine blue. B = bone; I = implant; FT = fibrous tissue; I = implant.

systems such as hollow cylinders,¹⁰ the Straumann F implant,¹¹ aluminium oxide devices,¹¹ solid cylindrical implants,¹² the first generation of hydroxylapatite-coated implants,¹³ sharp threaded needlelike designs,¹⁴ and now with a tapered implant placed with a combination of various bold interventions.¹⁻³ In this list of poorly functioning osseointegrated oral implants, which in no way is complete, it is interesting to observe that

TABLE 4 Results from X-ray Photoelectron Spectroscopy Analyses of One NobelDirect Implant

Element	Atomic % (range)*
O	16.7–38.5
Ti	3.6–9.8
N	0.3–0.9
C	42.5–74.1
P	0.4–7.8
Si	0.3–3.5

*Based on seven measurements at different parts of the implant.

several of our major commercial companies of today are represented, although never more than once for each company. In many cases, commercial hype has replaced the careful scientific approach once represented by the early pioneers of osseointegration.¹⁵⁻¹⁷ In fact, we cannot solely blame the involved commercial bodies, since oral implants nowadays are routinely placed by clinicians who obviously do not ask for clinical results before testing these various systems, perhaps acceptable if implant changes are small but not so after substantial changes in implant design or recommended handling of it. Unfortunately, control bodies such as the Food and Drug Administration have placed oral implants in their category IIa where clinical pretrials are deemed unnecessary. Europeans have followed suit in their CE-marking procedure that neither asks for any clinical pretrials before introducing novel implants on the market.

The present authors have observed high failure rates with an oral implant system that was launched in 2004.

It is noteworthy that of the 550 implants included in this study, 273 (50%) were placed by two clinicians only, with all their implants being included in two separate studies arranged by the responsible company, Nobel Biocare. Furthermore, 412 of the implants (75%) representing eight centers were known, if not fully analyzed, to the present authors before our critique on this implant was public knowledge; hence, our data have not been skewed by the fact that only dissatisfied users contacted us after the news had spread. Table 1 presents seemingly different clinical outcomes for different centers. However, center 1, with no less than 158 implants and a failure rate of only 4.4% of those, is at the same time the center with the greatest proportion of those implants that displayed more than 3-mm bone loss.³ The responsible clinician informed that several of the implants with substantial bone resorption, although still in situ, were possible candidates for later removal to prevent further destruction of the harboring bone.

The dogma that all oral implants will succeed is obviously a dead one. Those of us who have used the listed implants have been led to violate the “*primum non nocere*” principles that are essential in patient caretaking. It is true that most patients with failed implants can be reoperated without simultaneous need of bone grafts. This may seem a simple procedure for the doctor. However, it is different for the patient. In the past, we used to interview patients with osseointegrated implants about their experience as edentulous individuals.^{18–19} One question concerned the worst experience in their time without teeth, a question to which we had expected responses reflecting inability to eat certain foods, potential calamities with loss of their false teeth, etc. However, the most common, if unexpected, response was that their worst experience was the day of oral surgery when they were treated with implants, a good illustration to the problem of being in the wrong end of the scalpel.²⁰

Naturally, we cannot totally exclude the possibility that previously reported severe bone resorption with NobelDirect implants^{2–3} depends on hardware parameters. One such hardware parameter that cannot be regarded to be without risk is that the roughened surface is placed in the soft tissues. We know only one limited study in patients wherein experiments with rough surfaces in soft tissues have been undertaken, and this study was investigating a healed situation, 1 year after implant placement.²¹ However, we were unable to investigate this

parameter in a controlled manner in the present study. Another potential risk with the one-piece NobelDirect implant is its tapered design; theoretically, such implants may be overtorqued at insertion if clinicians decide to give priority to put them home in the bone, which may result in undue bone resorption due to microfractures or stress concentration with resultant bone resorption. However, we are unaware of any increased frequency of clinical problems in other reports with similarly tapered implants.^{7,22}

Our chemical analysis of an implant from an early batch revealed presence of high levels of phosphorus and silicon ions. The former is presumably associated with the electrolyte used to prepare these implants; the presence of phosphorus ions cannot be regarded as surprising or implying any reasons for the observed high failure rate. Ordinary oxidized implants with similar phosphorus ions in the surface have shown good clinical results for 4 years.⁷ The presence of silicon ions is more difficult to explain. One cannot exclude the possibility that these ions represent remains of silicon oil; if so, they may be responsible for pathology, but other explanations are possible such as decontamination from the package. Although silicon (possibly in form of silica) is not a common finding in chemical analyses of implants, we are unable to state if the observed 3 to 4% Si-levels can explain the generally high level of implant failure.

However, what speaks against all these theories attempting to explain unacceptable bone resorption and increased failure rates of the NobelDirect implant is the fact evidenced in our own material, that of 58 failures for immediately loaded implants ($n = 492$) and only one failure (1.7%) if implants were placed with a surgical flap, and direct occlusion was avoided for some time ($n = 58$). This observation is supported by findings of Sennerby and colleagues³ that their conservatively treated implants showed an average bone loss of 1.6 mm in contrast to those placed according to recommendations from the manufacturer when average bone resorption was 2.6 mm at 1 year of follow-up. Therefore, the combined effect of recommended clinical handling procedures seems to be the most incriminating evidence for observed problems with the NobelDirect implant. The critical report on the NobelDirect implant presented by the Swedish Medical Product Agency (Läkemedelsverket) on December 6, 2006, with an addendum on February 15, 2007, demands that the company behind this product is to carefully explain the background to the

unacceptable bone loss, to present necessary skills to use this implant properly, and to present advisory notice to inform customers and other control bodies of these changes in the recommendations on how to use the NobelDirect.²³ Hopefully, these changes will lead to improved survival rates of this implant that, with currently recommended insertion techniques, have resulted in quite unacceptable clinical outcomes with 11.8% failures on top of a great number of implants with severe bone loss. In fact, these problems have been so substantial that the present authors would not recommend any clinical usage of the NobelDirect/Perfect implant designs before publication of proper long-term data including evidence of steady-state bone as evaluated in individual radiographs. To us, this would seem a minimum demand in “putting patients first” – in a case like this, we have to know, not believe, that a specific implant is without harm to our patients.

REFERENCES

- Nowzari H, Chee W, Yi K, Pak M, Chung WH, Rich S. Scalloped dental implants: a retrospective analysis of radiographic and clinical outcomes of 17 Nobel perfect implants in 6 patients. *Clin Implant Dent Relat Res* 2006; 8:1–10.
- Östman PO, Hellman M, Albrektsson T, Sennerby L. Direct loading of Nobel Direct and Nobel Perfect one-piece implants: a 1-year prospective clinical and radiographic study. *Clin Oral Implants Res* 2007. (In press)
- Sennerby L, Becker W, Jonsson L, Johansson LÅ, Albrektsson T. Short term clinical results of Nobel Direct implant. A retrospective multicentre analysis. *Clin Oral Implants Res* 2007. (In press)
- Donath K. Die Trenn-Dünnschliff-Technik zur herstellung histologischer präparate von nicht schneidbaren gewebe und. materialen. *Der Präparator* 1988; 34:197–206.
- Brånemark PI, Hansson B-O, Adell R, et al. Osseointegrated implants in the treatment of the edentulous jaw. *Scand J Plast Reconstr Surg* 1977; 11(Suppl 16):1–116.
- Albrektsson T, Dahl E, Enbom L, et al. Osseointegrated oral implants. A Swedish multicenter study of 8139 consecutively inserted Nobelpharma implants. *J Periodontol* 1988; 59:287–296.
- Glauser R, Ruhstaller P, Windisch S, et al. Immediate occlusal loading of Brånemark system TiUnite implants placed predominantly in soft bone: 4-year results of a prospective, clinical study. *Clin Implant Dent Relat Res* 2005; 7(Suppl 1):S52–S59.
- Rasmusson L, Roos J, Bystedt H. A 10-year follow-up study of titanium dioxide-blasted implants. *Clin Implant Dent Relat Res* 2005; 7:36–42.
- Bornstein M, Schmid B, Belser U, Lussi A, Buser D. Early loading of non-submerged titanium implants with a sand-blasted and acid-etched surface. 5-year results of a prospective study in partially edentulous patients. *Clin Oral Implants Res* 2005; 16:631–638.
- Malmquist J, Sennerby L. Clinical report on the success of 47 consecutively placed Core-vent implants followed from 3 months to 4 years. *Int J Oral Maxillofac Implants* 1990; 5:53–60.
- Albrektsson T, Sennerby L. State of the art in oral implants. *J Clin Periodontol* 1991; 18:474–481.
- Albrektsson T. On long-term maintenance of the osseointegrated response. *Aust Prosthodont J* 1993; 7(Suppl):15–24.
- Albrektsson T. Hydroxyapatite-coated implants: a case against their use. *J Oral Maxillofac Surg* 1998; 56:1312–1326.
- Haugesund Byrett. Norway. Sak nr. 99–006559 A, 2000.
- Brånemark PI, Breine U, Adell R, Hansson BO, Lindström J, Ohlsson Å. Intraosseous anchorage of dental prostheses I. Experimental studies. *Scand J Plast Reconstr Surg* 1969; 3:81–89.
- Schroeder A, Pohler O, Sutter F. Gewebsreaktion auf ein Titan-Hohlzylinderimplantat mit Titan-Spritzobefläche. *Schweiz Mschr Zahnheilk* 1976; 86:713–725.
- Schulte W, Heimke G. The Tübingen implant. *Quintessenz* 1976; 27:17–23.
- Blomberg S. Psychological response. In: Brånemark PI, Zarb G, Albrektsson T, eds. *Tissue integrated prostheses. Osseointegration in clinical dentistry*. Chicago, IL: Quintessence, Inc., 1985:165–176.
- Albrektsson T, Blomberg S, Brånemark A, Carlsson GE. Edentulousness – an oral handicap. Patient attitudes to treatment with jawbone-anchored prostheses. *J Oral Rehab* 1987; 14:503–511.
- Albrektsson T. Preface. In: Albrektsson T, Bratthall D, Glantz PO, Lindhe J, eds. *Tissue preservation in caries treatment*. London: Quintessence, 2001:7.
- Wennerberg A, Sennerby L, Kultje C, Lekholm U. Some soft tissue characteristics at implant abutments with different surface topography, a study in humans. *J Clin Periodontol* 2003; 30:88–94.
- Drago CJ, Del Castillo RA. A retrospective analysis of Osseotite NT implants in clinical practice: 1-year follow-up. *Int J Periodontics Restorative Dent* 2006; 26:337–345.
- Åstrand P, Glantz P-O, Klinge B. Viewpoints on the contents of the document attached to the statement by Nobel Biocare 2006-08-31, English version of Expert Statement. Uppsala, Sweden: Läkemedelsverket, 2006-09-11.

Copyright of Clinical Implant Dentistry & Related Research is the property of Blackwell Publishing Limited and its content may not be copied or emailed to multiple sites or posted to a listserv without the copyright holder's express written permission. However, users may print, download, or email articles for individual use.

Copyright of Clinical Implant Dentistry & Related Research is the property of Blackwell Publishing Limited and its content may not be copied or emailed to multiple sites or posted to a listserv without the copyright holder's express written permission. However, users may print, download, or email articles for individual use.