

# Immediate Rehabilitation of the Mandible with Fixed Full Prosthesis Supported by Axial and Tilted Implants: Interim Results of a Single Cohort Prospective Study

Luca Francetti, MD, DDS; Enrico Agliardi, MD; Tiziano Testori, MD, DDS; Davide Romeo, DDS; Silvio Taschieri, MD, DDS; Massimo Del Fabbro, BSc, PhD

---

## ABSTRACT

*Purpose:* The aims of this prospective study were to assess the treatment outcome of immediately loaded full-arch fixed bridges anchored to both tilted and axially placed implants for the rehabilitation of the mandible and to compare the outcome of axial versus tilted implants.

*Materials and Methods:* Sixty-two patients (34 women and 28 men) were included in the study. Each patient received a full-arch fixed bridge supported by two axial implants and two distal tilted implants (All-on-Four®, Nobel Biocare AB, Göteborg, Sweden). Loading was applied within 48 hours of surgery. Patients were scheduled for follow-up at 6, 12, 18, and 24 months, and annually up to 5 years. At each follow-up, plaque level and bleeding scores were assessed; moreover, patient's satisfaction for aesthetics and function was evaluated by a questionnaire. Radiographic evaluation of marginal bone level change was performed at 1 year.

*Results:* The overall follow-up range was 6 to 43 months (mean 22.4 months). Forty-four patients were followed for a minimum of 1 year. No implant failures were recorded to date, leading to a cumulative implant survival and prosthesis success rate of 100%. Plaque level and bleeding scores showed progressive decrease over time, parallel to increase of satisfaction for both aesthetics and function. No significant difference in marginal bone loss was found between tilted and axial implants at 1-year evaluation.

*Conclusion:* The present preliminary data suggest that immediate loading associated with tilted implants could be considered a viable treatment modality for the mandible.

**KEY WORDS:** edentulous mandible, endosseous implants, immediate loading, tilted implants, TiUnite surface

---

Immediate loading of implant-supported full-arch rehabilitation for the mandible is a predictable procedure, as testified by recent consensus reports and systematic reviews.<sup>1-9</sup> The progressive reduction of the number of implants bearing a full-arch fixed prosthesis in the completely edentulous mandible is supported by

theoretical considerations on mechanical load<sup>10</sup> and by strain gauge measurements of implant loading in vivo.<sup>11</sup> Clinical studies also demonstrated that four implants, when optimally spread, can be sufficient to ensure long-term success of full-arch prosthesis.<sup>12</sup> In a recently proposed technique, two anterior implants are placed in regions 32 and 42, orthogonal to the occlusal plane, while two distal implants, in regions 35 and 45, are tilted about 30 degrees relative to the occlusal plane.<sup>13</sup>

The rationale of tilting implants is related to surgical and prosthetic advantages, as previously described.<sup>14-16</sup> Fixtures of 15 mm or longer can be placed in a dense bony structure such as the anterior wall of the mental loop, enhancing primary stability. Long cantilever can be avoided, improving load distribution,

---

Centre for Research in Oral Implantology, Department of Health Technologies, Istituto Ortopedico Galeazzi I.R.C.C.S., University of Milan, Milan, Italy

Reprint requests: Luca Angelo Francetti, Istituto Ortopedico Galeazzi, Via R. Galeazzi 4, 20161 Milan, Italy; e-mail: luca.francetti@unimi.it

© 2008, Copyright the Authors

Journal Compilation © 2008, Wiley Periodicals, Inc.

DOI 10.1111/j.1708-8208.2008.00090.x

and the anterior–posterior spread can be increased, independent of the shape of the mandibular body.

Recent studies by Krekmanov and colleagues<sup>14</sup> and Aparicio and colleagues<sup>15</sup> showed no difference in the marginal bone loss between tilted and non-tilted implants placed either in the maxilla or in the mandible.

The aim of this study was to report on the 1-year results of a prospective single cohort study evaluating immediate rehabilitation of the completely edentulous mandible when using four implants between the mental foramina. A second objective was to compare tilted and axially placed implants.

## MATERIALS AND METHODS

The study was designed as a prospective single-cohort clinical trial. Consecutively treated patients were included and scheduled to be followed for up to 5 years after loading. Surgical interventions were done in two clinical centers by two experienced operators (L.F. and E.A.) that followed the same clinical protocol.

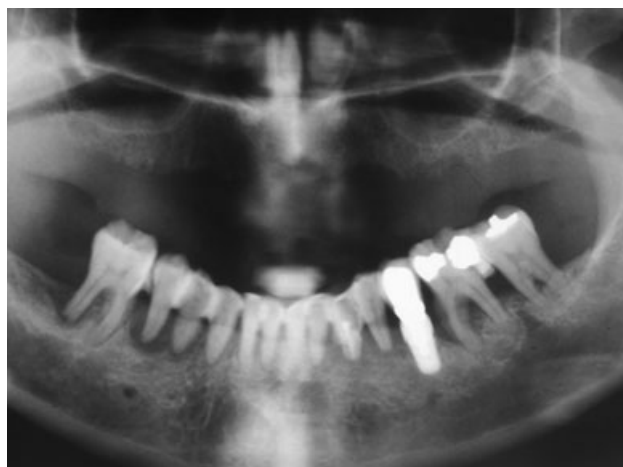### Patient Selection Criteria

The inclusion criteria for the recruitment of the patients were:

- 18 years or older;
- Patients in general good health condition, able to undergo surgical treatment (ASA-1/ASA-2);
- Completely edentulous mandible or mandibular teeth with an unfavorable long-term prognosis;
- Adequate bone height and thickness for the placement of implants at least 10 mm long and 4 mm wide without the need for bone augmentation procedures;
- Informed consent of the patient.

The exclusion criteria were:

- Presence of acute infection at the implant site; hematologic diseases; serious problems of coagulation; diseases of the immune system; uncontrolled diabetes; and metabolic diseases affecting bone, pregnancy, or lactation;
- Inadequate oral hygiene level (full-mouth plaque score and full-mouth bleeding score greater than 20%) and poor motivation to maintain good oral hygiene throughout the study;
- Irradiation of the head or neck region, or chemotherapy within the past 60 months;
- Severe bruxism or clenching



**Figure 1** Pretreatment panoramic radiograph from a 50-year-old female patient showing advanced periodontal lesions involving most of the remaining teeth and one mandibular implant.

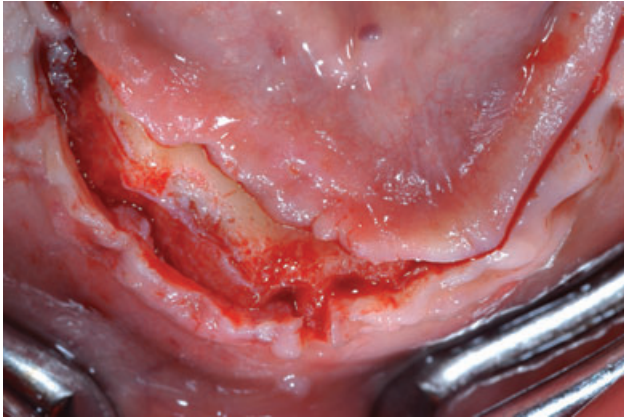
Preliminary screening was performed using panoramic orthopantomographs (Figure 1) or computerized tomographic scans. Patients eligible for inclusion were informed of the protocol and follow-up details, and also of the possible alternative treatments.

### Surgical Protocol

One hour prior to surgery, patients took 2 g of amoxicillin and clavulanic acid (Augmentin®, Roche, Milan, Italy) as prophylaxis. Starting 3 days before surgery and then daily for 7 days following surgery, chlorhexidine digluconate 0.2% mouthwash (Curasept®, Curaden Healthcare s.r.l., Milan, Italy) was prescribed to the patients. All patients were sedated with 5 mg e.v. of diazepam (Valium®, Roche) prior to surgery.

After preparation of the patient, local anesthesia of the mandible with articaine chlorhydrate 4% and adrenaline 1:100, 000 (Alfacaina N, Weimer Pharma, Rastatt, Germany) was administered; the block of the inferior dental nerve was usually avoided.

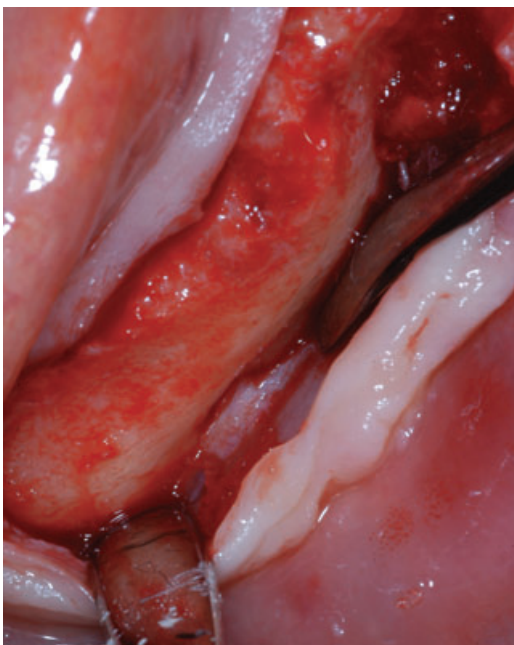
Implants and abutments were placed according to a previously described protocol (All-on-Four®, Nobel Biocare AB, Göteborg, Sweden) (Figures 1–6). To allow an immediate rehabilitation, the implants were inserted with a final torque of 40 to 50 Ncm. Bone quality was assessed according to Lekholm and Zarb classification.<sup>17</sup> Specific procedures were adopted for increasing the primary stability of the fixtures during site preparation. During the early phase of drilling, the clinician evaluated bone density. According to this, the implant site



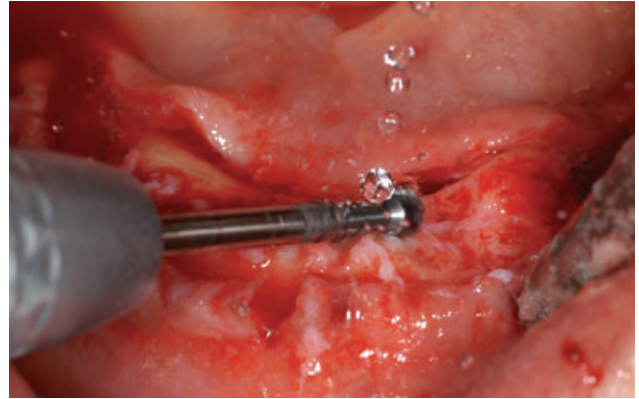
**Figure 2** Midcrestal incision of the ridge with the flap partially raised.

could be slightly underprepared in full length in order to guarantee the highest implant stability.

In case one axial implant could not be inserted with a torque  $\geq 30$  Ncm, immediate loading was still allowed because this implant was splinted to adjacent stable implants. In case either two or more of the tilted implants or one axial implant did not achieve the required primary stability, immediate loading was not applied and implants were left to heal for at least 2 months before the prosthetic phase. A torque controller (Osseocare®, Nobel Biocare AB) with a torque limit of 50 Ncm was used for implant insertion. A manual



**Figure 3** Clinical view of the mental nerve.

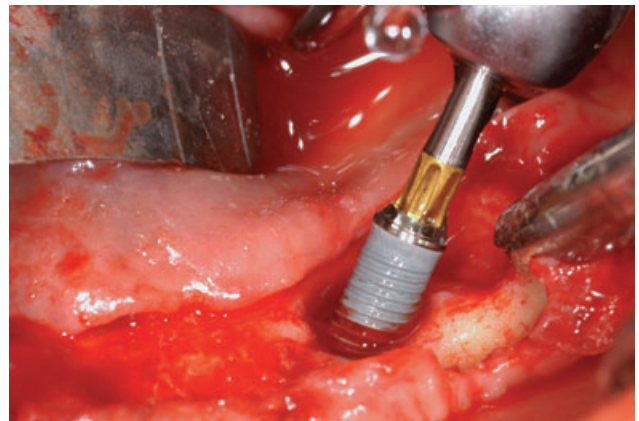


**Figure 4** Regularization of the edentulous crest performed with a rotating instrument.

wrench was employed in case of incomplete seating of the implant. Countersink was avoided to engage as much of the crestal bone as possible. A bicortical anchorage was attempted whenever possible.

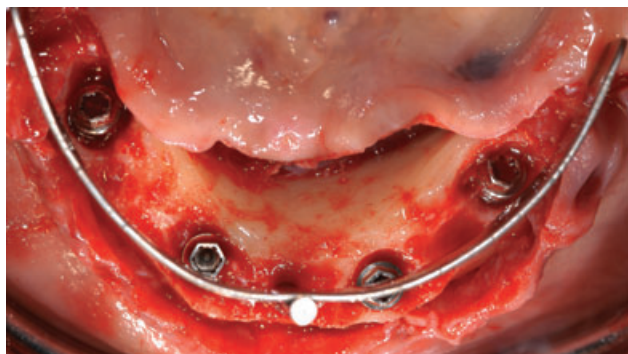Abutments (MUA®, Nobel Biocare AB) were connected to the implants (Figure 7). In particular, on distal implants, abutments angulated of 30 degrees with respect to the long axis of the fixture were positioned to obtain an optimal orientation for the prosthetic screw access. These abutments emerged at the second premolar position. Straight abutments were placed over the anterior implants. After positioning the coping, the soft tissues were sutured with a 5-0 resorbable suture (Monocryl or Vicryl, Johnson & Johnson, St-Stevens-Woluwe, Belgium).

An impression was taken utilizing a silicon putty polyvinilsyloxane (Elite Implant Impression Material, Zhermack®, Badia Polesine, Rovigo, Italy) directly on the coping. Then, four healing caps were placed upon the multiunit abutments.



**Figure 5** Insertion of the posterior implant.

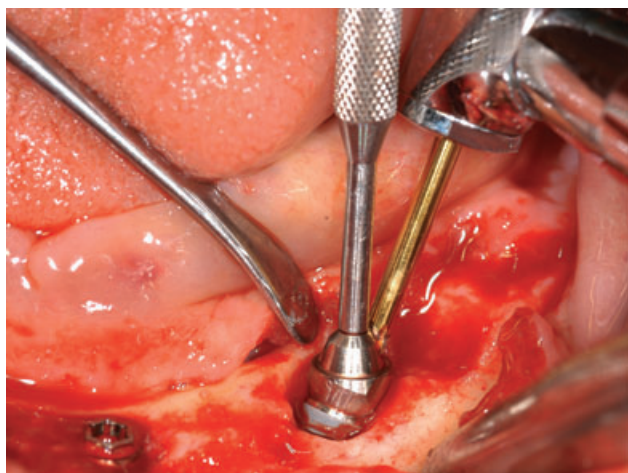




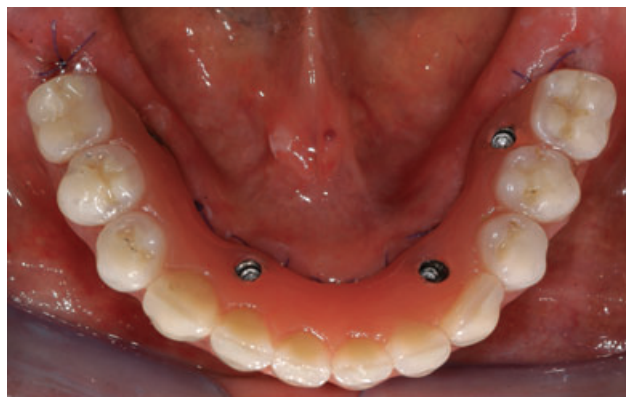
**Figure 6** Clinical view with all the implants and the Maló Guide in place.

Analgesics and anti-inflammatory drugs (Naprossene Sodico, Synflex Forte®, Recordati, Milan, Italy) were prescribed post-surgery in case of pain. Ice packs were provided.

Acrylic temporary prosthesis with 10 teeth was delivered within 48 hours (Figures 8 and 9). Healing caps were removed, and the prosthesis was placed over the abutments. Screws were tightened over the MUA with a torque of 10 Ncm, following the manufacturer's instructions. All centric and lateral contacts were assessed by a 40 µm articulating paper (Bausch Articulating Paper, Nashua, NH, USA) and adjusted if necessary until they were present only between 33 and 43, according to Maló protocol.<sup>13</sup> The screw access was then covered with provisional resin cement (Fermit-N®, Ivoclar Vivadent AG, Schaan, Liechtenstein). The complete prosthesis was allowed to obtain stabilization of implants in order to avoid the risk of overcoming



**Figure 7** Positioning of the 30 degrees Multi-Unit® abutments on the left posterior implant.



**Figure 8** Occlusal view of the immediate provisional prosthesis.

the micromovement threshold, thereby impairing osseointegration.<sup>18</sup>

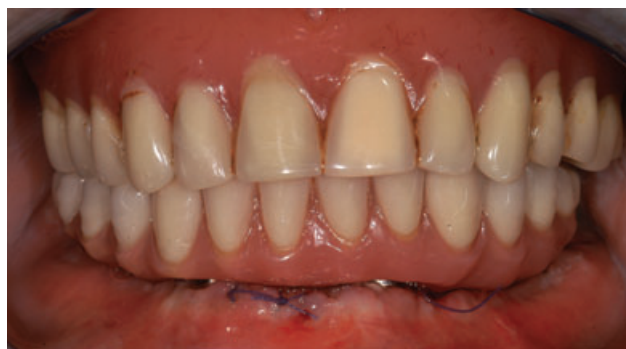At the time of prosthesis delivery, a panoramic radiograph was made to check implant position and the coupling between prosthetic components.

The patients were scheduled for weekly control visits during the first month. During each visit, prosthetic functionality and tissue healing were evaluated. Every 3 months, oral hygiene level was evaluated.

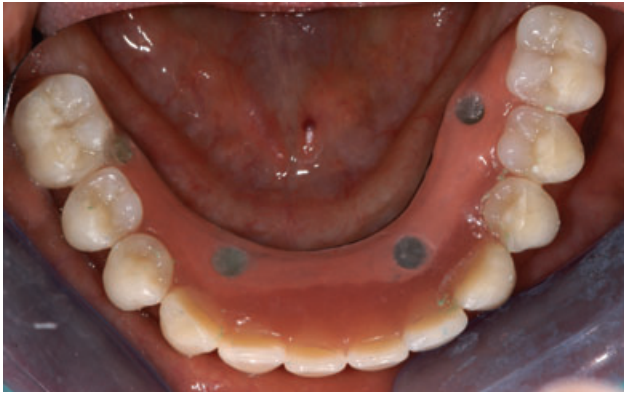After surgery, patients were instructed to avoid brushing and any trauma to the surgical site. A cold and soft diet was recommended for the first day, and a soft diet for the first week.

After 4 to 6 months of loading, in the absence of pain and inflammatory signs, the patients received the final prosthesis, fabricated by means of the CAD-CAM Procera® system (Nobel Biocare AB) (Figures 10 and 11).

The patients were scheduled to be followed up for 60 months to collect information on the long-term prognosis of such rehabilitative protocol.



**Figure 9** Frontal view of the immediate prosthesis with a resorbable suture.



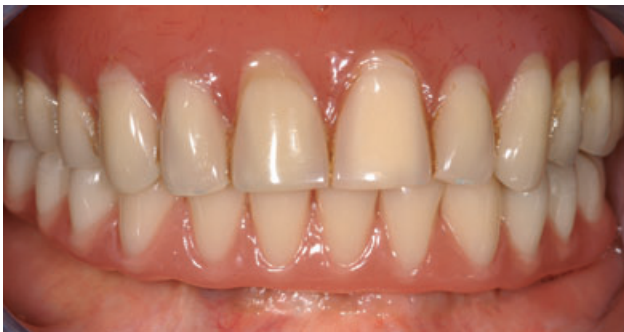**Figure 10** Occlusal view of the definitive prosthesis.

### Data Collection and Follow-Up

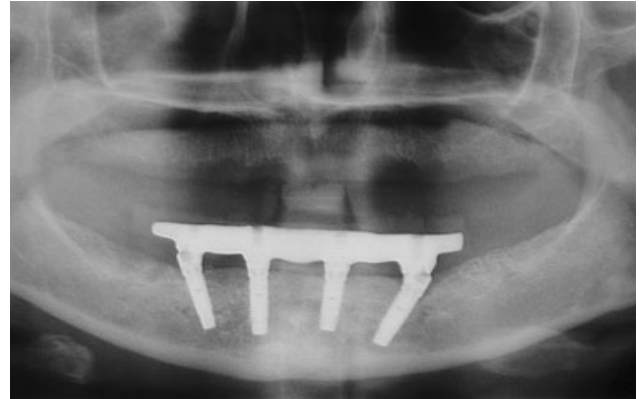
Information on bone quality and quantity, implant characteristics, insertion torque, and the presence of dehiscences or fenestrations was noted on apposite form at surgery. Interimplant distances and cantilever lengths were measured for both provisional and final prosthesis.

Follow-up visits were scheduled every 6 months for the first 2 years, and yearly thereafter up to 5 years. At all follow-up visits, periapical radiographs using a paralleling technique and an individual X-ray holder were performed for evaluation of peri-implant bone level change over time. A panoramic radiograph was also taken at the 1-year follow-up to evaluate overall bone level and condition (Figure 12).

Plaque index and bleeding index were evaluated at the implant level. Each implant was examined on four aspects (mesial, distal, vestibular, lingual). Any site in which plaque could be detected by the naked eye or with a probe accounted for 6.25% (1/16) of the total score (100%), independent of the amount of plaque. The same was made for bleeding index, considering positive any site that showed bleeding on probing.



**Figure 11** Frontal view of the definitive prosthesis.



**Figure 12** One-year posttreatment panoramic radiograph.

Mobility of the prosthetic structure and occlusion were also checked. Any complication with the prosthetic components was noted.

Finally, the patients' satisfaction was assessed by means of a questionnaire.

At the 1-year follow-up visit, the prostheses were removed and the stability of each implant was tested with the pressure of two opposing instruments.

The outcome measures evaluated for the present study were:

1. Prosthesis stability: prosthesis in function, without mobility and pain. Prosthesis stability was tested by means of two opposing instruments' pressure.
2. Prosthesis failure: prosthesis removed for any reason.
3. Implant survival: no evidence of peri-implant radiolucency on periapical radiographs, no suppuration or pain at the implant site or ongoing pathologic processes, and absence of complaint of neuropathies or persistent paresthesia.<sup>19</sup>
4. Marginal bone level change: Each periapical radiograph was scanned at 600 dpi with a scanner (Epson Perfection Pro, Epson Italia, Cinisello Balsamo, Milan, Italy), and the marginal bone level was assessed with an image analysis software (UTHSCSA Image Tool version 3.00 for Windows, University of Texas Health Science Center in San Antonio, TX, USA) by an independent blinded evaluator. Implant neck was the reference for each measurement. Mesial and distal values were averaged so as to have a single value for each implant. Bone loss around tilted and axial implants was compared by using paired *t*-test. The value  $p = .05$  was considered as the level of significance.

**TABLE 1** Implant Distribution According to Implant Type and Length

	11.5 mm	13 mm	15 mm	Total
Mk IV	2	32	82	116
Speedy	4	21	107	132
Total	6	53	189	248

## RESULTS

### Patient Demographics

From March 2004 to May 2007, a total of 62 healthy patients (34 women and 28 men; mean age 56 years; range 35 to 77 years) have been rehabilitated with an immediately loaded implant-supported fixed mandibular prosthesis supported by four implants.

Twenty-five patients (40.3%) were smokers (average daily consumption: 5.6 cigarettes), with six of them smoking more than 20 cigarettes per day.

Patients had different types of opposing dentition: removable prostheses (27 cases), natural teeth (eight cases), natural teeth and fixed prostheses on natural teeth (eight cases), fixed prostheses on natural teeth (three cases), implant-supported bridges (nine cases), natural teeth and two implant-supported bridges (four cases).

In total, 248 implants were inserted. Table 1 reports the distribution of implants according to type and length. All implants had a diameter of 4 mm. Forty implants were placed in fresh extraction sockets of 30 patients. Of these, 20 were tilted implants that only partially engaged the extraction socket. One hundred and sixteen implants were Brånemark System® Mk IV (mean insertion torque  $46.72 \pm 4.71$ ), while 132 were NobelSpeedy™ Groovy® (mean insertion torque  $49.39 \pm 2.38$ ).

Table 2 shows the distribution of bone quality and quantity at implant sites.

All patients could be rehabilitated according to the immediate loading protocol within 48 hours of surgery, as planned.

### Complications

One patient reported a light ipoesthesia on the left side of the lower lip after surgery which resolved after 6 months.

**TABLE 2** Implants in Relation to Bone Quality and Quantity\*

Bone Quantity	Bone Quality				Total (%)
	1 (%)	2 (%)	3 (%)	4	
A	10 (4)	17 (7)	30 (12)	0	57 (23)
B	14 (5)	42 (17)	14 (6)	0	70 (28)
C	54 (22)	27 (11)	6 (2)	0	87 (35)
D	24 (10)	10 (4)	0	0	34 (14)
E	0	0	0	0	0
Total	102 (41)	96 (39)	50 (20)	0	248

\*According to Lekholm and Zarb's classification.<sup>17</sup>

The most frequent prosthetic complication was the fracture of the acrylic prosthesis that occurred in seven cases (11%). To date, no fracture of the definitive prostheses has been reported.

### Survival Rates

The mean follow-up duration was 22.4 months. No implant was lost to date, so the cumulative implant survival rate was 100%. No prosthetic failure occurred, resulting in 100% prosthesis stability, as from Table 3.

Peri-implant bone loss after 1-year follow-up could be evaluated for 30 patients ( $n = 60$  implants per group). This parameter averaged  $0.7 \pm 0.4$  and  $0.7 \pm 0.5$  mm for axial and tilted implants, respectively. Such difference was not significant ( $p > .05$ ). At the 1-year visit, all implants were stable according to the opposing instrument pressure test.

Table 4 shows plaque and bleeding scores recorded during scheduled controls.

From 26 patients, the mean cantilever value for the right side was  $7.23 \pm 1.27$  mm (SD) and  $14.46 \pm 1.68$  mm for the immediate and final prostheses,

**TABLE 3** Life Table Analysis of Surviving Implants

Time Period (months)	Functioning implants (%)
Loading-6	248 (100)
6-12	248 (100)
12-18	176 (71)
18-24	164 (66)
24-36	112 (45)
36-48	40 (16)



**TABLE 4** Plaque Index and Bleeding on Probing Index

	6 months (48 Patients)	12 months (42 Patients)	18 months (30 Patients)	24 months (21 Patients)
PI (%)	13.28 ± 5.99	8.92 ± 7.19	4.93 ± 3.97	3.12 ± 3.68
BoP (%)	3.39 ± 4.82	1.64 ± 3.1	0.42 ± 1.59	0.57 ± 1.88

Data are expressed as percentages as detailed in the text.

respectively, while for the left side it was  $6.84 \pm 1.62$  mm for the provisional prosthesis and  $14.65 \pm 1.72$  mm for the definitive restoration. No difference was found between the left and right side values at each evaluation.

## DISCUSSION

Noncontrolled trials are not the ideal study design to assess the efficacy of a clinical procedure. However, they can provide useful information on the prognosis of a specific type of intervention. Nevertheless, any comparison with alternative techniques must be avoided as this would lead to biased conclusions.

Early and immediate loading procedures are widely documented in the dental literature and are comparable to conventional loading in many clinical situations.<sup>1-9</sup>

The trend for most medical procedures is to reduce treatment time and simplify clinical protocols. The last frontier in implant dentistry is represented by reducing the number of implants supporting a prosthetic rehabilitation, as well as the time elapsing between implant placement and prosthetic loading. The lowest number was proposed with the Brånemark Novum concept, in which only three implants were used. However, such protocol was targeted only to a restricted population of patients because of the very selective morphological and anatomical requirements.<sup>20-23</sup> The results of the present investigation are in line with previous clinical reports in which fixed bridges supported by four implants were successfully used for the early<sup>12,24,25</sup> or immediate<sup>13</sup> rehabilitation of fully edentulous mandibles.

Most clinical articles point out that one of the key factors for successful immediate rehabilitation is adequate implant primary stability. The latter can be achieved by using osteoconductive implant surfaces in combination with a modified preparation of the implant site. It is probably critical to reduce micromovements at the implant-bone interface in order to achieve and maintain osseointegration over time in immediate loading procedures.<sup>18,26</sup> Therefore, a rapid splinting of implants with a fixed bridge is important.

The optimal position and inclination of implants have also been investigated by several authors. Some biomechanical advantages of using tilted implants have been identified: obtainment of a wide anterior-posterior spread, avoidance of long cantilevers, and achievement of a favorable distribution of the occlusal load.<sup>14</sup> It could also be speculated that tilted implants can be placed and anchored with greater cortical bone contact than axial ones, thereby achieving good primary stability.

Tests on models<sup>27</sup> and by finite element (FE) analysis<sup>28</sup> performed on single angulated implants showed that tilting implants may increase the stress to surrounding bone. Tilted fixtures may also be subjected to bending, possibly increasing the marginal bone stress.<sup>29</sup> However, when the implant belongs to a multiple implant-supported prosthesis, the spread of the implants and the rigidity of the prosthetic structure should reduce the bending.<sup>30</sup> In a two-dimensional FE analysis, Zampelis and colleagues<sup>31</sup> evidenced that distal tilting of implants splinted in a fixed restoration did not increase the stress in the marginal bone compared to axial implants.

According to some authors,<sup>14-16,32,33</sup> a limited inclination of an implant (between 15 and 30 degrees) has no deleterious effect for the load transfer to the surrounding bone.

Strain gauge measurements performed by Krekmanov and colleagues<sup>14</sup> showed no significant differences in forces and bending moments between tilted and non-tilted implants. Moreover, theoretical models show that an increased prosthetic base, because of the inclination of the implants, can reduce the force acting over the implants.<sup>14</sup> Therefore, from a biological point of view, the position of the neck of the implant can be more important than the inclination of the implants themselves.

Care must be paid to the preparation of the tilted implant sites because of the closeness of the mental nerve. It is important to identify and isolate the nerve's foramen and to carry out a clinical and radiographic evaluation of its loop. The latter in fact represents the

posterior limit of intraforaminal implant rehabilitation. In our clinical experience, we found wide differences in the shape and in the length of mental nerve loop.

Another critical step is the placement of the angulated abutments for posterior implants. A countersinking is often required distally to the implant's neck to facilitate abutment placement. It is difficult to say if the advantages of using tilted implants and angulated abutments can overcome technical difficulties of the procedure and slightly greater material cost as compared to using four axial implants. However, in the present investigation, no implant failure occurred and a very limited peri-implant bone loss was observed over the follow-up period, suggesting that from a clinical and biological standpoint, the technique can be successfully used.

Concerning the incidence of fracture of the acrylic prostheses (11%), in the present study it was slightly lower than that reported by Maló and colleagues<sup>13</sup> (27%). Such complication occurred exclusively in men with a short face morphotype, mostly between 4 and 6 months of function. It can be speculated that one of the possible causes for such inconvenience was the progressive shift from a soft diet to a diet including hard food. Progressive wear of the resin because of repeated deglutition and mastication cycles can also be a factor in the genesis of provisional prosthesis fracture. It was noted that six out of seven fractures occurred close to one of the temporary abutments of the anterior implants, which is a weak point of the structure. Fractures were always repaired by the clinician without dispatching the prostheses to the laboratory, avoiding further discomfort to the patient. No correlation was found between such fractures and the type of opposing dentition.

We noted a progressive decrease in plaque and bleeding index. We believe that the contribution of dental hygienists was important not only for professional cleaning, but also for their active role in patient's education and motivation to maintaining optimal levels of oral hygiene.

In addition, the refined metal structure of the final prosthesis was less retentive for plaque with respect to the acrylic resin of the provisional prosthesis. Finally, cleaning can be considered easier as compared to other types of rehabilitation based on a greater number of implants, because of the presence of less implant surfaces to be cleaned and the wider interimplant distance.

## CONCLUSION

The preliminary results of the present prospective study are positive and in agreement with a previous retrospective study.<sup>13</sup>

The present study showed good clinical outcomes when using two tilted and two axial implants and a fixed prosthesis for rehabilitation of the edentulous mandible.

Minimal incidence of surgical complications, high implant and prosthesis survival rates, and improved levels of oral hygiene throughout the study suggest that the use of two tilted and two axial implants is a predictable technique for prosthetic rehabilitation of the edentulous mandible. However, long-term data are needed to confirm this statement.

## REFERENCES

1. Castellon P, Blatz MB, Block MS, Finger IM, Rogers B. Immediate loading of dental implants in the edentulous mandible. *J Am Dent Assoc* 2004; 135:1543–1549.
2. Chiapasco M. Early and immediate restoration and loading of implants in completely edentulous patients. *Int J Oral Maxillofac Implants* 2004; 19:76–91.
3. Esposito M, Grusovin MG, Willings M, Coulthard P, Worthington HV. Interventions for replacing missing teeth: different times for loading dental implants. *Cochrane Database Syst Rev* 2007. DOI: 10.1002/14651858.CD003878.pub3
4. Misch CE, Hahn J, Judy KW, et al. Immediate Function Consensus Conference. Workshop guidelines on immediate loading in implant dentistry. *J Oral Implantol* 2004; 30:283–288.
5. Ioannidou E, Doufexi A. Does loading time affect implant survival? A meta-analysis of 1,266 implants. *J Periodontol* 2005; 76:1252–1258.
6. Romanos GE, Testori T, Degidi M, Piattelli A. Histologic and histomorphometric findings from retrieved, immediately occlusally loaded implants in humans. *J Periodontol* 2005; 76:1823–1832.
7. Attard NJ, Zarb GA. Immediate and early implant loading protocols: a literature review of clinical studies. *J Prosthet Dent* 2005; 3:242–258.
8. Del Fabbro M, Testori T, Francetti L, Taschieri S, Weinstein R. Systematic review of survival rates for immediately loaded dental implants. *Int J Periodontics Restorative Dent* 2006; 26:249–263.
9. Jokstad A, Carr AB. What is the effect on outcomes of time-to-loading of a fixed or removable prosthesis placed on implant(s)? *Int J Oral Maxillofac Implants* 2007; 22:19–48.
10. Rangert B, Jemt T, Jorneus I. Forces and moments on Bråne-mark implants. *Int J Oral Maxillofac Implants* 1989; 4:241–247.



11. Duyck J, Van Oosterwyck H, Van der Sloten J, De Cooman M, Puers R, Naert I. Magnitude and distribution of occlusal forces on oral implants supporting fixed prostheses: an in vivo study. *Clin Oral Implants Res* 2000; 11:465–475.
12. Brånemark P-I, Svensson B, van Steenberghe D. Ten-year survival rate of fixed prostheses on four or six implants ad modum Brånemark in full edentulism. *Clin Oral Implants Res* 1995; 6:227–231.
13. Maló P, Rangert B, Nobre M. “All-on-Four” immediate-function concept with Brånemark system implants for completely edentulous mandibles: a retrospective clinical study. *Clin Implant Dent Relat Res* 2003; 5(Suppl 1):2–9.
14. Krekmanov L, Kahn M, Rangert B, Lindstrom H. Tilting of posterior mandibular and maxillary implants of improved prosthesis support. *Int J Oral Maxillofac Implants* 2000; 15:405–414.
15. Aparicio C, Perales P, Rangert B. Tilted implants as an alternative to maxillary sinus grafting: a clinical, radiologic, and periotest study. *Clin Implant Dent Relat Res* 2001; 3:39–49.
16. Aparicio C, Arevalo X, Ouzzan W, Granados C. A retrospective clinical and radiographic evaluation of tilted implants used in the treatment of the severely resorbed edentulous maxilla. *Appl Osseointegration Res* 2002; 3:17–21.
17. Lekholm U, Zarb GA. Patient selection and preparation. In: Brånemark P-I, Zarb GA, Albrektsson T, eds. *Tissue-integrated prostheses: osseointegration in clinical dentistry*. Chicago, IL: Quintessence, 1985:199–209.
18. Szmukler-Moncler S, Salama H, Reingewirtz J, Dubruille JH. Timing of loading and effect of micro-motion on bone-implant interface: a review of experimental literature. *J Biomed Mater Res (Appl Biomater)* 1998; 43:192–203.
19. Albrektsson T, Zarb G, Worthington P, Erikson AR. The long-term efficacy of currently used dental implants: a review and proposed criteria of success. *Int J Oral Maxillofac Implants* 1986; 1:11–25.
20. Brånemark P-I, Engstrand P, Ohnrell LO, Grondahl K, Nilsson P, Hagberg K. Brånemark Novum: a new treatment concept for rehabilitation of the edentulous mandible. Preliminary results from a prospective clinical follow-up study. *Clin Implant Dent Relat Res* 1999; 1:2–16.
21. De Bruyn H, Kisch J, Collaert B, Lindén U, Nilner K, Dväsäter L. Fixed mandibular restorations on three early-loaded regular platform Brånemark implants. *Clin Implant Dent Relat Res* 2001; 3:176–184.
22. Hatano N, Yamaguchi M, Suwa T, Watanabe K. A modified method of immediate loading using Brånemark implants in edentulous mandibles. *Odontology* 2003; 91:37–42.
23. Henry PJ, van Steenberghe D, Blomback U, et al. Prospective multicenter study on immediate rehabilitation of edentulous lower jaws according to the Brånemark Novum protocol. *Clin Implant Dent Relat Res* 2003; 5:137–142.
24. De Bruyn H, Collaert B. Early loading of machined-surface Brånemark implants in completely edentulous mandibles: healed bone versus fresh extraction sites. *Clin Implant Dent Relat Res* 2002; 4:136–142.
25. Engquist B, Astrand P, Anzen B, et al. Simplified methods of implant treatment in the edentulous lower jaw: a 3-year follow-up report of a controlled prospective study of one-stage versus two-stage surgery and early loading. *Clin Implant Dent Relat Res* 2005; 7:95–104.
26. Szmukler-Moncler S, Piattelli A, Favero GA, Dubruille JH. Considerations preliminary to the application of early and immediate loading protocols in dental implantology. *Clin Oral Implants Res* 2000; 11:12–25.
27. Clelland N, Gilat A, McGlumphy E, Brantley W. A photoelastic and strain gauge analysis of angle abutments for an implant system. *Int J Oral Maxillofac Implants* 1993; 8:541–548.
28. Clelland N, Lee J, Bimbenet O, Brantley W. A three-dimensional finite element stress analysis of angled abutments for an implant placed in the anterior maxilla. *J Prosthodont* 1995; 4:95–100.
29. Rangert B, Sullivan RM, Jemt T. Load factor control for implants in the posterior partially edentulous segment. *Int J Oral Maxillofac Implants* 1997; 12:360–370.
30. Daellenbach K, Hurley E, Brunski J, Rangert B. Biomechanics of in-line vs. offset implants supporting a partial prosthesis [abstract # 1327]. *J Dent Res* 1996; 75(special issue):183.
31. Zampelis A, Rangert B, Heijl L. Tilting of splinted implants for improved prosthodontic support: a two-dimensional finite element analysis. *J Prosthet Dent* 2007; 97:S35–S43.
32. Fortin Y, Sullivan RM, Rangert B. The Marius implant bridge: surgical and prosthetic rehabilitation for the completely edentulous upper jaw with moderate to severe resorption: a 5-year retrospective clinical study. *Clin Implant Dent Relat Res* 2002; 4:69–77.
33. Calandriello R, Tomatis M. Simplified treatment of the atrophic posterior maxilla via immediate/early function and tilted implants: a prospective 1-year clinical study. *Clin Implant Dent Relat Res* 2005; 7(Suppl 1):S1–12.

Copyright of Clinical Implant Dentistry & Related Research is the property of Blackwell Publishing Limited and its content may not be copied or emailed to multiple sites or posted to a listserv without the copyright holder's express written permission. However, users may print, download, or email articles for individual use.