

# Anatomical Bases for the Insertion of Zygomatic Implants

Marcelle Rossi, PhD;\* Luís Rogério Duarte, MSc;† Robson Mendonça, MSc;‡ Atson Fernandes, PhD§

---

## ABSTRACT

*Purpose:* The purpose of this study was to obtain anatomical information for installing four zygomatic implants, by measurements of maxillae and zygomata.

*Materials and Methods:* Linear and angular measurements were obtained from the maxillae and zygomata of 40 dry skulls.

*Results:* Based on mean and standard deviation values, the installation angle of the additional implant in the four zygoma technique was between 25° and 47°, and that of the conventional zygomatic implant was between 39° and 62°. The distance between the alveolar crest in the canine region and the lateral margin of the orbital socket was 53.42 mm, and between the alveolar crest in the premolar region and the area closest to the lateral margin of the orbital socket was 42.47 mm.

*Conclusions:* When the angle of installation of the additional implant is less than 25° and that of the conventional zygomatic implant is less than 39°, perforation of the maxilla, zygoma, or the infratemporal fossa must be avoided. When the angle of installation of an additional implant is greater than 47° and that of the conventional zygomatic implant is greater than 62°, perforation of the orbital floor must be avoided. The length of an additional implant was greater than the length of a conventional zygomatic implant, and should be measured prior to drilling, because the greatest value found for this distance was 61.94 mm, while the maximum length of the zygomatic implants currently available on the market is 52.5 mm.

**KEY WORDS:** anatomy, atrophic maxillae, zygomatic bone, zygomatic implants

---

The rehabilitation of edentulous patients by means of implant-supported prostheses with satisfactory results is well documented. However, in treating the maxilla, bone atrophy and pneumatization of the maxillary sinus reduce the possibility of using this mode of rehabilitation.<sup>1–3</sup> Many alternative procedures have then been studied such as the use of composite grafts,<sup>4</sup> Le Fort I osteotomy,<sup>5</sup> iliac crest grafts,<sup>6,7</sup> and maxillary sinus grafts.<sup>8,9</sup> These therapeutic options increase the length of

treatment time, may require hospitalization, and make the use of a provisional prosthesis impossible during the healing period.<sup>10</sup>

An alternative for patients presenting severe atrophy of the maxilla is the zygomatic implant developed by Prof. Branemark in 1988.<sup>11</sup> With a length of 35 to 52.5 mm, this implant must be inserted from the palatal aspect of the resorbed maxilla in the region of the second premolar, through the maxillary sinus into the compact bone of the zygoma.<sup>10–12</sup> The insertion of between two and four further implants in the premaxilla allows for the use of a hybrid fixed prosthesis,<sup>10</sup> constituting a stable biomechanical polygon.<sup>13</sup>

The insertion of this type of implant makes the use of bone grafts unnecessary, reducing morbidity and treatment time.<sup>2,3,14–17</sup>

Modifications to the technique originally proposed have been presented in the literature, such as the insertion of multiple zygomatic implants,<sup>18</sup> or four implants, two on either side.<sup>13</sup> In the four-implant protocol, two zygomatic implants are inserted using the original technique,<sup>11,12</sup> and two additional zygomatic implants are

---

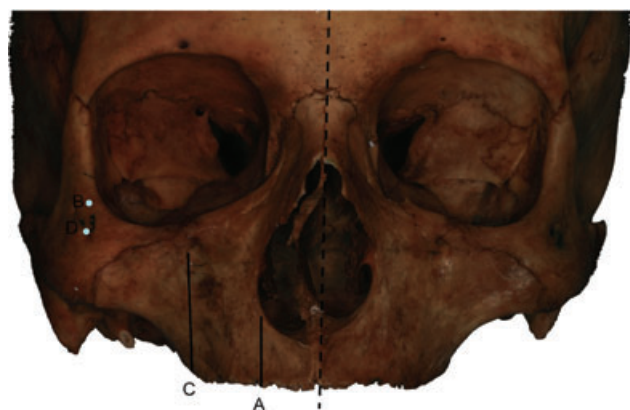
\*Doctor of anatomy, professor at the Bahia School of Medicine and Public Health, Bahia, Brazil; †MSc in implantology, professor of implantology at the Federal University of Bahia, Bahia, Brazil; ‡MSc in clinical odontology, professor of implantology at the Federal University of Bahia, Bahia, Brazil; §doctor of anatomy, professor at the Bahia School of Medicine and Public Health, and at the State University of Bahia and Bahia School of Medicine and Public Health, Bahia, Brazil

Reprint requests: Marcelle Alvarez Rossi, Instituto Renaissance – Reabilitação Oral com Implantes, Av. Prof. Magalhães Neto, n.1541, Centro Medico Hospital da Bahia, SL. 4006, Pituba, CEP: 41810-011 Salvador, Bahia, Brazil; e-mail: marcellerossi@hotmail.com

© 2008, Copyright the Authors

Journal Compilation © 2008, Wiley Periodicals, Inc.

DOI 10.1111/j.1708-8208.2008.00091.x



**Figure 1** Skull frontal view showing the points B and D and the anatomic references to the points A and C.

inserted, emerging in the region of the canines or lateral incisors. This treatment alternative is based on the immediate loading concept.<sup>1,13</sup>

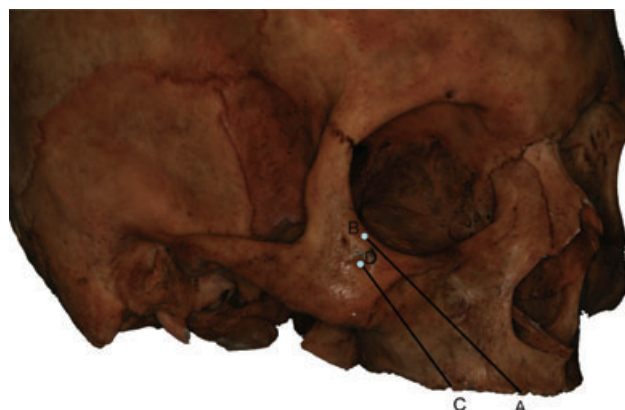
According to Kato and colleagues,<sup>14</sup> who evaluated 28 bones in cadavers using computerized tomography, and Rigolizzo and colleagues,<sup>3</sup> who measured sections of zygomatic bone in 60 dry skulls, it can be stated that the average dimensions of this bone make the insertion of two implants safely possible. In the former study, greater bone density was found in the region of the angle between the frontal process and the temporal process of the zygoma,<sup>14</sup> and in the latter greater bone thickness was found in the areas nearest to the lateral margin of the orbital socket.<sup>3</sup>

Anatomical studies applied to the conventional zygomatic implant technique<sup>19</sup> and to the four zygomatic implants technique are scarce, despite the importance of such knowledge to the safety of the procedure.<sup>3,11,19</sup>

The objective of this study was to obtain anatomical information by measuring the angular and linear dimensions of the maxilla and the zygoma in dry skulls, in order to guarantee the safe insertion of four zygomatic implants.

## MATERIALS AND METHODS

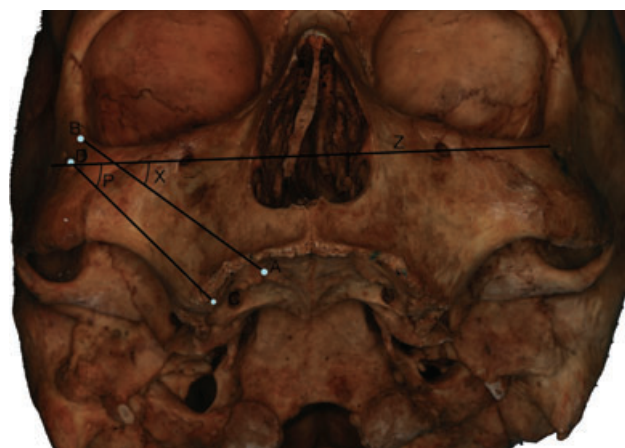Forty dry skulls (80 maxillae and zygomata) from the collection belonging to the anatomy department at the Bahia School of Medicine and Public Health were used. Every skull used was toothless, without the alveolar process and presented atrophy of the premaxilla. This investigation was approved by the Research Ethics Committee of the Bahia School of Medicine and Public Health – EBMSP-FBDC.



**Figure 2** Skull lateral view showing the lines AB and CD.

The following measurement points and lines were defined (Figures 1–3):

1. Point A: The lowermost point of the alveolar crest, taking a line from the lateral margin of the nasal incisure shifted 5 mm to the palatal side, corresponding to the starting point of the perforation for an additional zygomatic implant in the four zygoma technique.
2. Point B: The lowermost point on the lateral margin of the orbital socket, corresponding approximately to the end point of an additional zygomatic implant in the four zygoma technique.
3. Point C: The lowermost point of the alveolar crest, taking a line at a tangent to the lateral margin of the infraorbital foramen shifted 5 mm to the palatal side, corresponding to the starting point of the perforation for a conventional zygomatic implant.
4. Point D: Located one-third of the distance between the lowermost point of the lateral margin of the



**Figure 3** Skull frontal view showing the points A, B, C, and D; the lines AB and CD; and the angles X and P.

**TABLE 1 Angular and Linear Measurements of the Maxilla and Zygoma**

Measurement	N	Mean	Median	SD	Minimum	Maximum
AB	80	53.4209	54.2500	4.08355	43.40	61.94
CD	80	42.4721	43.0350	3.20351	34.87	51.50
X	80	35.80	35.50	5.649	25	47
P	80	50.50	50	5.532	39	62

orbital socket and the lowermost point of the zygomaticomaxillary suture, corresponding approximately to the end point of a conventional zygomatic implant.

5. Line Z: Line passing through the infraorbital foramen.

Measuring of the linear and angular dimensions of the maxilla and zygoma was carried out based on the points and lines defined earlier. A digital paquimeter (Mitutoyo, Aurora, IL, USA) was used to take the linear measurements. A protractor and a set square, superimposed over the lines marked, were used to take the angular measurements. The linear measurements were recorded in millimeters, and the angular measurements in degrees.

### Linear Measurements (See Figures 2 and 3)

Length of line AB refers to the length of an additional zygomatic implant in the four zygoma technique. Length of line CD refers to the length of a conventional zygomatic implant.

### Angular Measurements (See Figure 2)

Angle X is the angle between lines AB and Z, corresponding to the angle of insertion of an additional zygomatic implant in the four zygoma technique. Angle P is the angle between lines CD and Z, corresponding to the angle of insertion of a conventional zygomatic implant.

For the purposes of statistical analysis, a database was created in Excel 2000 and analyzed using EpiInfo 6.0 software. The Mann–Whitney test was used to compare the angular measurements X and P, the linear measurements AB and CD, and the measurement CD on the two different sides. The *t*-test was used to compare the measurement AB on the two different sides. A 5% level of significance was adopted in these tests.

## RESULTS

The results obtained are presented in Table 1.

### Linear Measurements

The mean length of AB, corresponding to an additional zygomatic implant in the four zygoma technique was 53.42 mm (SD = 4.08355). The minimum length of this line was 43.4 mm, and the maximum length was 61.94 mm.

The mean length of line CD, corresponding to a conventional zygomatic implant, was 42.4721 mm (SD = 3.20351). The minimum length of this line was 34.87 mm, and the maximum length was 51.5 mm.

Comparing the lengths of AB and CD, the Mann–Whitney test showed that the linear measurement AB was greater than CD ( $p < .001$ ).

Comparing the lengths of AB and CD, respectively, on different sides, the *t*-test and Mann–Whitney test showed no statistically significant difference between the two sides ( $p = .539$ ;  $p = .729$ ).

### Angular Measurements

The mean of the installation angle, corresponding to an additional zygomatic implant, in the four zygoma technique (X) was 35.8° (SD = 5.649). The minimum angle was 25° and the maximum angle was 47°.

The mean of the installation angle, corresponding to a conventional zygomatic implant (P) was 50.5° (SD = 5.532). The minimum angle was 39°, and the maximum angle was 62°.

Comparing X and P, the Mann–Whitney test showed that the angular measurement P was greater than X ( $p < .001$ ).

Comparing X and P, respectively, on different sides, the Mann–Whitney test showed no statistically significant difference between the two sides ( $p = .296$ ;  $p = .142$ ).

## DISCUSSION AND CONCLUSIONS

In this study, line Z, which passes through the infraorbital foramen, was used as a plane of reference, because

this is not affected by the resorption of the alveolar process.

The starting point of the perforation for an additional implant in the four zygoma technique must be in the region of canine, slightly to the palatal side. Because totally edentulous skulls were used, representing the type of patients who would be submitted to this surgical technique, this position was estimated from the lateral margin of the nasal incisure (point A), in accordance with anatomical knowledge of the region.<sup>20</sup> The end point of this implant was determined as being the lowermost point on the lateral margin of the orbital socket (point B). This location corresponds to the area of greatest bone thickness of the zygoma according to Rigolizzo and colleagues.<sup>3</sup>

The starting point of the perforation for a conventional zygomatic implant must be in the region of the second premolar, slightly to the palatal side. In the skulls used, this position was estimated from the infraorbital foramen (point C), according to the study made by Uchida and colleagues<sup>19</sup> in which a line passing through the infraorbital foramen, parallel to the median line, coincided with the region of the second premolar in nine of the 10 dentate maxillae evaluated. The end point of this implant was determined as being at one-third of the distance between the lowermost point of the lateral margin of the orbital socket and the lowermost point the zygomaticomaxillary suture (point D). This location corresponds to the area of greatest bone thickness of the zygoma according to Rigolizzo and colleagues.<sup>3</sup>

The angle of insertion of a zygomatic implant also deserves special attention. A correct angle should prevent damage to important anatomical structures in the orbital socket or infratemporal fossa. The angle of installation of an additional zygomatic implant measured in this study (angle X) varied between 25° and 47°, with a mean of 35.8°. Thus, when the angle of installation of this implant is less than 25°, perforating the lateral wall of the maxilla and the zygoma or the infratemporal fossa must be avoided. When the angle of installation of this implant is greater than 47°, perforating the orbital floor must be avoided.

The angle of insertion of a conventional zygomatic implant measured in this study (angle P) varied between 39° and 62°, with a mean of 50.5°. Thus, when the angle of insertion of this implant is less than 39°, perforating of the lateral wall of the maxilla and the zygoma or the infratemporal fossa must be avoided. When the angle of

insertion of this implant is greater than 62°, perforating of the orbital floor must be avoided. In the study made by Uchida and colleagues<sup>19</sup> in which similar points and lines of reference were used, these values varied between 43.8° and 50.6°.

The statistical difference between the angles of insertion of an additional implant (angle X) and of a conventional zygomatic implant (angle P) demonstrates that those implants would not be parallel. The angle of the conventional zygomatic implant is probably greater because of the fact that the starting point for the perforation is located further to the posterior, demanding that it should be more inclined toward the zygoma, which is positioned more laterally.

The distances between the starting points of the perforations and the end points of the zygomatic implants were measured to determine the average lengths and variations in length of the conventional and additional zygomatic implants. The minimum value found for the additional implant was 43.4 mm, the maximum was 61.94 mm, and the mean value was 53.42 mm. The minimum value found for the conventional implant was 34.87 mm, the maximum was 51.5 mm, and the mean value was 42.47 mm. Uchida and colleagues<sup>19</sup> found that these values varied for conventional implants between 44.3 and 54.3 mm, with a mean of 50.2 mm, using similar points and lines of reference.

On average, the length of an additional implant (line AB) was greater than the length of a conventional implant (line CD), because of the fact that the additional implant has a starting point more anterior. The distance AB should be measured prior to drilling for the installation of an additional zygomatic implant, because the greatest and the mean values found for this distance were 61.94 and 53.42 mm, respectively, while the maximum length of the zygomatic implants currently available on the market is 52.5 mm.

## REFERENCES

1. Brånemark P-I, Gröndahl K, Öhrnell L-O, et al. Zygoma fixture in the management of advanced atrophy of the maxilla: technique and long-term results. *Scand J Plast Reconstr Surg Hand Surg* 2004; 38:70–85.
2. Malevez C, Abarca M, Durdu F, Daelemans P. Clinical outcome of 103 consecutive zygomatic implants: a 6–48 months follow-up study. *Clin Oral Implants Res* 2004; 15:18–22.

3. Rigolizzo MB, Camilli JA, Francischone CE, Padovani CR, Brånemark P-I. Zygomatic bone: anatomic bases for osseointegrated implant anchorage. *Int J Oral Maxillofac Implants* 2005; 20:441–447.
4. Breine U, Brånemark P-I. Reconstruction of alveolar jawbone. An experimental and clinical study of immediate and preformed autologous bone grafts in combination with osseointegrated implants. *Scand J Plast Reconstr Surg* 1980; 14:23–48.
5. Isaksson S, Ekfeldt A, Alberius P, Blomqvist JE. Early results from reconstruction of severely atrophic (class VI) maxillas by immediate endosseous implants in conjunction with bone grafting and Le Fort I osteotomy. *J Oral Maxillofac Surg* 1993; 22:144–148.
6. Adell R, Lekholm U, Gröndahl K, Brånemark P-I, Lindstrom L, Jacobsson M. Reconstruction of severely resorbed edentulous maxillae using osseointegrated fixtures in immediate-autogenous grafts. *Int J Oral Maxillofac Implants* 1990; 5:233–246.
7. Isaksson S, Alberius P. Maxillary alveolar ridge augmentation with onlay bone grafts and immediate endosseous implants. *J Craniomaxillofacial Surg* 1992; 20:2–7.
8. Boyne PJ, James RA. Grafting of the maxillary sinus floor with autogenous marrow and bone. *J Oral Surg* 1980; 38:613–616.
9. Wood RM, Moore DI. Grafting of the maxillary sinus with intraorally harvested autogenous bone prior to implant placement. *Int J Oral Maxillofac Implants* 1988; 3:209–214.
10. Bedrossian E, Stumpel L, Beckely M, Indersano T. The zygomatic implant: preliminary data on treatment of severely resorbed maxillae. A clinical report. *Int J Oral Maxillofac Implants* 2002; 17:861–865.
11. Darle C. Minimized treatment for maximal predictability: a new procedure for rehabilitating the severely resorbed maxilla. *Talk of the times* 4. 1st ed. Göteborg, Sweden: Nobel Biocare AB, 1999:5.
12. Brånemark P-I. Surgery and fixture installation. *Zygomaticus fixture clinical procedures*. 1st ed. Göteborg, Sweden: Nobel Biocare AB, 1998:1.
13. Duarte LR, Peredo LG, Nary Filho H, Francischone CE, Brånemark P-I. Reabilitação da maxila atrófica utilizando quatro fixações zigomáticas em sistema de carga imediata. *Implant News* 2004; 1:45–50.
14. Kato Y, Kizu Y, Tonogi M, Ide Y, Yamane G-y. Internal structure of zygomatic bone related to zygomatic fixture. *J Oral Maxillofac Surg* 2005; 63:1325–1329.
15. Petruson B. Sinuscopy in patients with titanium implants in the nose and sinuses. *Scand J Plast Reconstr Surg Hand Surg* 2004; 38:86–93.
16. Hirsch J-M, Öhrnell L-O, Henry PJ, et al. A clinical evaluation of the zygoma fixture: one year of follow-up at 16 clinics. *J Oral Maxillofac Surg* 2004; 62(Suppl 2):22–29.
17. Boyes-Varley JG, Howes DG, Lownie JF, Blackbeard GA. Surgical modifications to the Brånemark zygomaticus protocol in the treatment of the severely resorbed maxilla: a clinical report. *Int J Oral Maxillofac Implants* 2003; 18: 232–237.
18. Bothur S, Jonsson G, Sandahl L. Modified technique using multiple zygomatic implants in reconstruction of the atrophic maxilla: a technical note. *Int J Oral Maxillofac Implants* 2003; 18:902–904.
19. Uchida Y, Goto M, Katsuki T, Akiyoshi T. Measurement of the maxilla and zygoma as an aid in installing zygomatic implants. *J Oral Maxillofac Surg* 2001; 59:1193–1198.
20. Madeira C. *Anatomia da face*. Rio de Janeiro, Brazil: Guanabara Koogan, 2001.

Copyright of Clinical Implant Dentistry & Related Research is the property of Blackwell Publishing Limited and its content may not be copied or emailed to multiple sites or posted to a listserv without the copyright holder's express written permission. However, users may print, download, or email articles for individual use.