

Temporary Implant-Supported Prosthesis for Immediate Loading According to a Chair-Side Concept: Technical Note and Results from 37 Consecutive Cases

Pär-Olov Östman, DDS;*† Mats Hellman, DDS;*† Lars Sennerby, DDS, PhD;* Ann Wennerberg, DDS, PhD*‡

ABSTRACT

Background: During the last years, focus has been paid to implant treatment using immediate function protocols, and different approaches to provide patients with temporary constructions have been presented. Most of these techniques involve dental technicians producing the temporary construction, for example, rebuilding existing dentures, acrylic bridges, etc.

Purpose: The purpose of this prospective clinical study was to evaluate the clinical outcome of a chair-side technique of a cost-effective temporary prosthesis. Fixture survival rate and risk of temporary bridge failure were analyzed.

Materials and Methods: Thirty-seven partially or totally edentate patients (18 female and 19 male; mean age: 66.7 years) treated with chair-side manufactured temporary restorations (QuickBridge™, BIOMET 3i, Palm Beach, FL, USA) for immediate loading have been evaluated. The prostheses extended from two unit bridges supported by two implants to full-arch construction supported by six implants. The temporary prostheses were monitored from the day of surgery and delivery to the time of replacement with a permanent prosthetic construction 3 to 6 months later.

Results: No implants were lost during the observation time. One (3%) temporary prosthesis fractured and additional two (6%) loosened during the follow-up time.

Conclusions: The study indicated that the tested chair-side concept for manufacturing of temporary prosthesis for immediate loading of dental implants is a viable approach.

KEY WORDS: dental implants, immediate loading, primary stability, prospective study, temporary implant prosthesis

During the last 40 years, prosthetic rehabilitation of edentulous patients with implant-supported bridges has developed into a viable and predictable treatment option. The fact that long-term studies have reported high clinical survival rates with the original protocols¹ has given clinicians and researchers' confidence to further develop and refine the osseointegration

technique. Consequently, implants have been used in more challenging situations and for wider indications.² For instance, we have gone from rehabilitation of the edentulous mandible with implants in the intra-foramina region to single implants in grafted areas in the posterior parts of maxillae. A similar trend is seen for timing of implant loading. A submerged healing period of 3 to 6 months was originally considered a prerequisite for achieving osseointegration of titanium implants.¹ However, during the last 10 to 15 years, this traditional protocol has been questioned and challenged. Numerous clinical studies have reported on the outcome of early and immediate loading in various clinical situations.^{3,4} Many patients seek implant treatment, which today is a well-established treatment modality for prosthetic rehabilitation of the edentulous patients. Patients also wish for as short treatment period as possible.

*Department of Biomaterials, Institute for Surgical Sciences, Sahlgrenska Academy, Göteborg University, Göteborg, Sweden; †private clinic, Falun, Sweden; ‡Department of Prosthodontics, Sahlgrenska Academy, Göteborg University, Göteborg, Sweden

Reprint requests: Dr. Pär-Olov Östman, Holmgatan 30, SE-79171 Falun, Sweden; e-mail: po@holmgatan.se

© 2007, Copyright the Authors

Journal Compilation © 2007, Blackwell Munksgaard

DOI 10.1111/j.1708-8208.2007.00069.x




Figure 1 The QuickBridge components: on a conical abutment (A), a titanium conical part is mounted (B). The PEEK plastic cap (C) is snapped on the titanium cone (D).

Different approaches to providing patients with temporary prosthesis have been presented. Most of these techniques involve converting existing dentures into acrylic bridges. The laboratory procedures are well-controlled and have several advantages to chair-side manufacturing of temporary prosthesis such as better finish and aesthetic. On the other hand, the laboratory-produced temporary prosthesis needs extended logistic, tends to be more expensive treatment, and takes longer time to produce. The use of chair-side made temporary prosthesis have the advantage of an immediate handicap

reduction, immediate splinting, and cost-effectiveness. Moreover, a chair-side provisional prosthesis can be manufactured and delivered during remaining anesthesia induced for the surgical placement of the implants. On the downside, the aesthetic outcome may be less compared to laboratory-made temporary prosthesis, and there is a possible risk for temporary material contamination of newly operated areas.

The aim of the present study was to evaluate a chair-side cost-effective temporary bridge concept for immediate loading of dental implants.

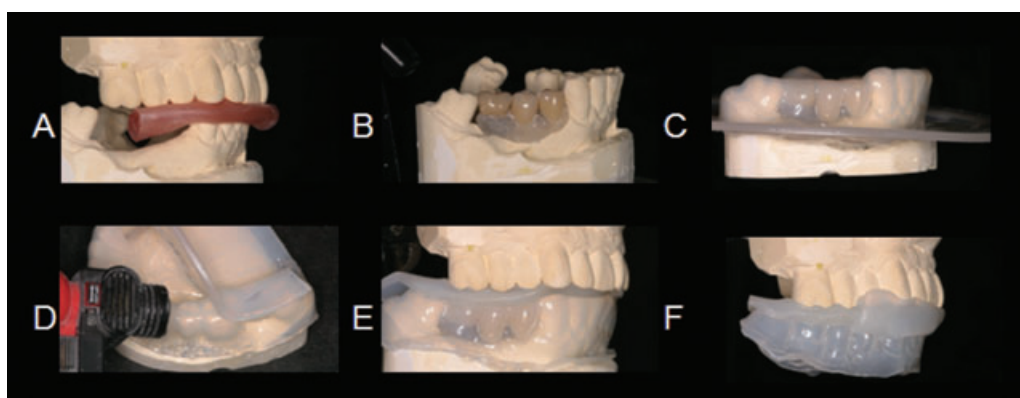


Figure 2 At the dental laboratory, a stone model (A) is made. If teeth are missing, a tooth wax-up is made (B). A translucent vacuum template is made (C) using a 2.5 mm thick thermoformed material. On the template, impressions are made of the opposite jaw (D–F) in order to orient the mold in the mouth.

MATERIALS AND METHODS

Temporary Bridge Concept

The concept (QuickBridge™, BIOMET 3i, Palm Beach, FL, USA) aims at making a cement-retained temporary prosthesis on abutments for a screw-retained permanent prosthesis. The components fit to conical abutments (BIOMET 3i) and consist of two parts: (1) a conical part made of titanium alloy that is attached to the conical abutment with a fixation screw using 20 Ncm of torque and (2) a plastic cap (PEEK) which is snapped on the abutment (Figure 1). The latter will be integrated with the provisional prosthesis. Although the retention of the plastic cap to the titanium cone is firm, it is recommended to use temporary cement.

Study Group

A total of 37 patients seeking dental implant treatment (18 female and 19 male; mean age: 66.7 years) were provided with chair-side temporary restorations according to the present concept and evaluated throughout its functional time, 3 to 6 months, until replacement with a permanent prosthesis. Ten patients were treated in the partially edentate mandible, 12 in the partially edentate maxilla, 7 in the totally edentate mandible, and 8 in the totally edentate maxillae. All patients were treated with immediate loading.

Surgery

Mid-crestal incisions were used to reflect a flap to expose the implant sites. Bone quality and quantity were determined according to Lekholm and Zarb's⁵ criteria. Implant placement was made in underprepared sites in order to enhance primary stability. All implants placed exceeded an insertion torque of 30 Ncm. A total of 132 fixtures (7 Osseotite®, 22 Osseotite NT®, 32 Certain PREVAIL®, and 71 Certain PREVAIL® NanoTite™) (BIOMET 3i) were placed. Before adaptation and suturing of the flaps, (Figure 3, A–I) conical abutment, QuickBridge titanium cone, and PEEK snap-on caps were mounted (see Figure 3, J–M).

Prosthetic Procedures

An alginate impression of both jaws was made before surgery. In cases presenting with full dentures, impressions were made of the denture. Occlusal record was preformed.

At the dental laboratory, a stone cast was made and the casts were registered in an articulator (Figure 2A). If teeth were missing, a tooth wax-up was made (see Figure 2B). A translucent vacuum template was made (see Figure 2C) using a 2.5 mm thick thermoformed material (ethyl-veny-acetat, Ergoflex 95®, Erkodent®, Erich Kopp GmbH, Pfalzgrafenweiler, Germany). On the template, impressions were made of the opposite jaw (see Figure 2, D–F).

The translucent template was mounted to verify that the temporary parts fit into the template (see Figure 3, N and O). Protemp™ 3 Garant (3M, ESPE, St. Paul, MN, USA) was injected into the template (see Figure 3, P and Q). The template was seated and allowed to set for 4 minutes. The temporary prosthesis was removed from the titanium interface and trimmed outside the mouth (see Figure 3, R–U). During the initial healing time, 10 days, the temporary prostheses were fixated with 1% chlorhexidine gel. Cantilevers were not allowed to exceed 5 mm. The extension of bridges ranged from three units supported by two implants to full-arch construction with 10 to 12 units supported by six implants (Table 1).

The temporary bridges were monitored throughout the functional time ranging from 3 to 6 months.

RESULTS

No adverse soft tissue reactions which could be related to the temporary prostheses were observed during healing after implant surgery. One (3%) temporary prosthesis fractured after 10 days in use. The fracture line was seated at one of the caps. Two of the temporary prostheses loosened from the titanium cones and were re-cemented with temporary cement. No implant failed during the observation time.

DISCUSSION

The focus on immediate loading has promoted the dental profession to develop techniques to provide patients with fixed provisional restorations, made in a laboratory or chair-side. Full-arch provisional reconstructions have so far been difficult to make chair-side. Laboratory-made provisional constructions have several advantages with regard to finish and aesthetic, but are often less cost-effective. It is the experience of the present authors that many patients decline the possibility of immediate loading with a laboratory-made temporary bridge because of costs.

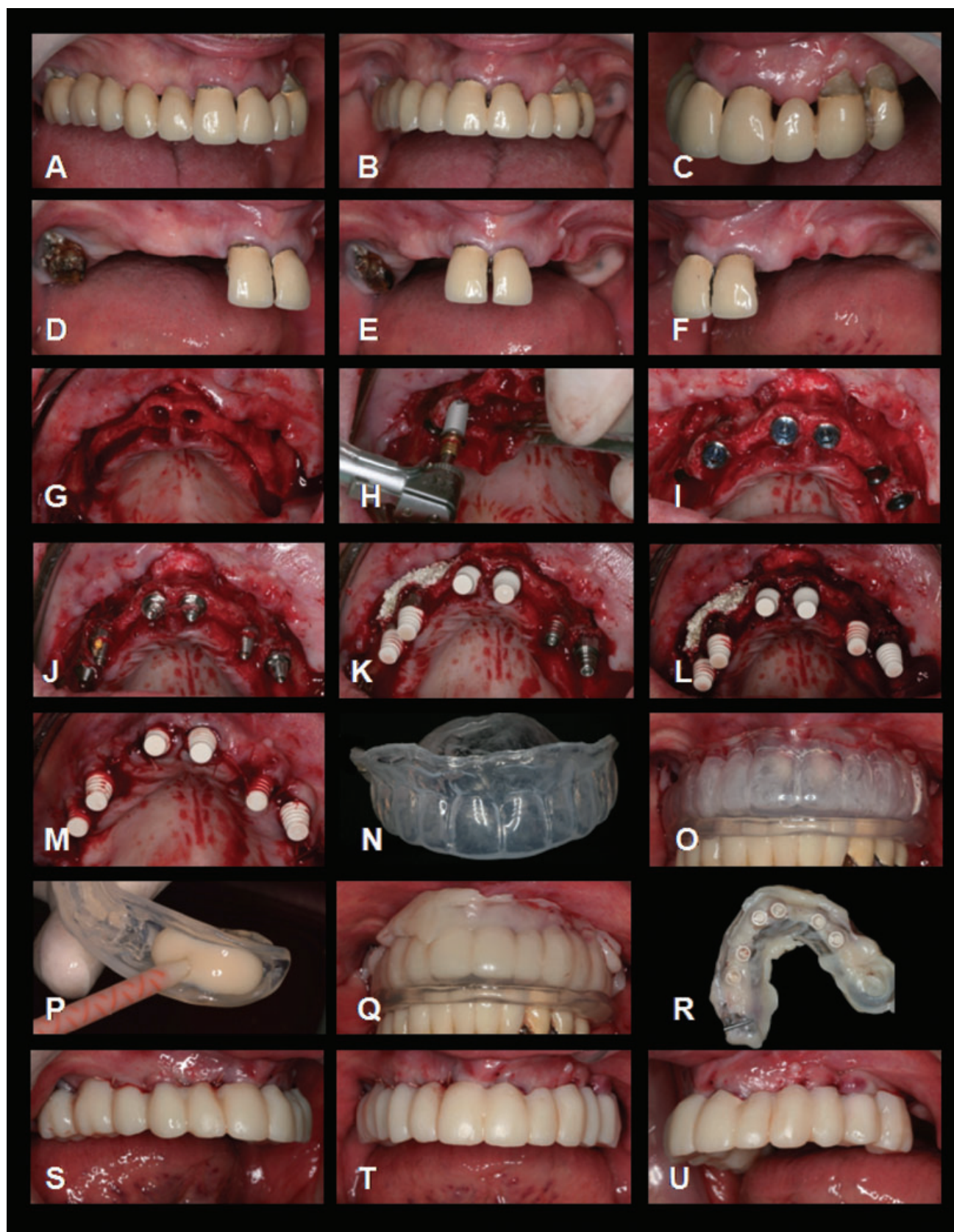


Figure 3 Immediately after fixture installation (A–I), and abutments connection (J) the QuickBridge titanium cone and the PEEK snap-on cap were mounted (K–M). The translucent template was mounted to verify that the temporary parts fit into the template (N and O). The self-setting temporary material was injected into the template (P) and allowed to set for 4 minutes (Q). The temporary prosthesis was removed from the titanium interface and trimmed outside the mouth (R–U).

TABLE 1 Prosthetic Extension by Case

Case	Region	Prosthetic Extension	No Cantilever	No Pontics	Number of Fixtures	Implant Site					
						1	2	3	4	5	6
1	Partial mandible	44-46	0	1	2	44	46				
2	Partial mandible	36-37	0	0	2	36	37				
3	Partial mandible	44-46	0	1	2	44	46				
4	Partial mandible	45-47	0	1	2	45	47				
5	Partial mandible	35-37	0	1	2	35	37				
6	Partial mandible	33-36	1	1	2	33	35				
7	Partial mandible	34-35	0	0	2	34	35				
8	Partial mandible	44-46	0	0	3	44	45	46			
9	Partial mandible	44-47	0	1	3	44	46	47			
10	Partial mandible	31-46	1	2	4	31	42	44	45		
11	Partial maxillae	15-13	0	1	1	15					
12	Partial maxillae	24-25	0	0	2	24	25				
13	Partial maxillae	24-26	0	1	2	24	26				
14	Partial maxillae	24-26	0	1	2	24	26				
15	Partial maxillae	24-25	0	0	2	24	25				
16	Partial maxillae	24-27	1	1	2	24	26				
17	Partial maxillae	12-16	1	1	3	12	13	15			
18	Partial maxillae	12-22	0	1	3	12	21	22			
19	Partial maxillae	12-15	0	1	3	12	13	15			
20	Partial maxillae	14-16	0	0	3	14	15	16			
21	Partial maxillae	11-26	1	2	4	11	21	23	25		

TABLE 1 Continued

Case	Region	Prosthetic Extension	No Cantilever	No Pontics	Number of Fixtures	Implant Site					
						1	2	3	4	5	6
22	Partial maxillae	13-22	0	1	4	13	11	21	22		
23	Total mandible	35-45	1 + 1	4	4	34	32	42	44		
24	Total mandible	36-46	1 + 1	6	4	35	33	42	45		
25	Total mandible	35-45	1 + 1	4	4	45	43	33	35		
26	Total mandible	36-46	1 + 1	6	4	45	43	32	35		
27	Total mandible	36-46	1 + 1	6	4	36	33	43	46		
28	Total mandible	36-46	1 + 1	5	5	45	43	41	33	35	
29	Total mandible	36-46	1 + 1	5	5	45	43	41	33	35	
30	Total maxillae	16-26	1 + 1	5	5	14	13	11	21	23	25
31	Total maxillae	16-26	1 + 1	4	6	15	13	11	22	23	25
32	Total maxillae	16-26	1 + 1	4	6	15	12	11	21	22	25
33	Total maxillae	16-26	1 + 1	4	6	15	13	11	21	23	25
34	Total maxillae	16-26	1 + 1	4	6	15	13	11	21	23	25
35	Total maxillae	16-26	1 + 1	4	6	15	12	11	21	22	25
36	Total maxillae	16-26	1 + 1	4	6	15	13	11	21	23	25
37	Total maxillae	16-26	1 + 1	4	6	15	13	11	21	23	25

Chair-side temporary bridges have the advantages of being a quick and cost-effective treatment because they can be produced directly after surgery while the patient is still anesthetized. The construction protects the wound from trauma from day 1, thereby making the first days after surgery more pleasant for the patients. It is also possible that the immediate temporary prosthesis may facilitate soft tissue healing, leading to better aesthetic. The downside of chair-side temporary bridges is the risk of acrylic or composite contamination of the wound. However, no adverse reactions toward the bridge were observed in the present study.

In many papers on implant-supported dental prostheses, it is argued that splinting will reduce the occlusal load transfer to the implants compared to a situation with freestanding implant units. According to Glantz and colleagues,^{6,7} favorable loading conditions were achieved via rigid implant-supported bridge. Splinting also reduces the lateral forces on implants, if they are three or more in number and placed in a tripod or cross-arch situation.^{8,9} In such situations, lateral forces are partly compensated by the more favorable axial implant forces. On the other hand, only two implants splinted will not offer this load reduction as these implants will be placed “in-line” with no offset implant to counteract the lateral forces. The principle of cross-arch stabilization is well-documented clinically^{10,11} and also by in vivo load measurements.¹² Therefore, it could be argued that good treatment results can be reached provided that a provisional bridge is connected to the implants as soon as possible after fixture placement. It seems that parameters such as firm primary implant stability, immediate splinting, and controlled occlusion/articulation are important for a successful clinical outcome. These parameters together with the use of surface-modified implants probably help to avoid micromotion at the bone-implant interface which can be detrimental for the integration process.

The study indicated that the tested chair-side concept for manufacturing of temporary prosthesis for immediate loading of dental implants is a viable approach.

REFERENCES

1. Albrektsson T, Branemark PI, Hansson HA, Lindstrom J. Osseointegrated titanium implants. Requirements for ensuring a long-lasting, direct bone-to-implant anchorage in man. *Acta Orthop Scand* 1981; 52:155–170.
2. Testori T, Wiseman L, Woolfe S, Porter SS. A prospective multicenter clinical study of the Osseotite implant: four-year interim report. *Int J Oral Maxillofac Implants* 2001; 16:193–200.
3. Chiapasco M. Early and immediate restoration and loading of implants in completely edentulous patients. *Int J Oral Maxillofac Implants* 2004; 19:76–91.
4. Ganeles J, Wismeijer D. Early and immediately restored and loaded dental implants for single-tooth and partial-arch applications. *Int J Oral Maxillofac Implants* 2004; 19:92–102.
5. Lekholm U, Zarb GA. Patient selection. In: Brånemark P-I, Zarb GA, Albrektsson T, eds. *Tissue integrated prostheses. Osseointegration in clinical dentistry*. Chicago, IL: Quintessence, 1985:199–209.
6. Glantz P-O, Strandman E, Svensson SA, Randow K. On functional strain in fixed mandibular reconstructions. I. An in vitro study. *Acta Odontol Scand* 1984; 42:241–249.
7. Glantz P-O, Strandman E, Randow K. On functional strain in fixed mandibular reconstructions. II. An in vivo study. *Acta Odontol Scand* 1984; 42:269–276.
8. Rangert B, Jemt T, Jörneus L. Forces and moments on Brånemark implants. *Int J Oral Maxillofac Implants* 1989; 4:241–247.
9. Rangert B, Sullivan R, Jemt T. Load factor control for implants in the posterior partially edentulous segment. *Int J Oral Maxillofac Implants* 1997; 12:360–370.
10. Maló P, Rangert B, Nobre M. “All-on-Four” immediate-function concept with Brånemark System implants for completely edentulous mandibles: a retrospective clinical study. *Clin Implant Dent Relat Res* 2003; 5(Suppl 1):2–9.
11. Maló P, Rangert B, Nobre M. “All-on-4” immediate-function concept with Brånemark System implants for completely edentulous maxilla: a 1-year retrospective clinical study. *Clin Implant Dent Relat Res* 2005; 7(Suppl 1):88–94.
12. Duyck J, Van Oosterwyck H, Vander Sloten J, De Cooman M, Puers R, Naert I. Magnitude and distribution of occlusal forces on oral implants supporting fixed prostheses: an in vivo study. *Clin Oral Implants Res* 2000; 11:465–475.

Copyright of Clinical Implant Dentistry & Related Research is the property of Blackwell Publishing Limited and its content may not be copied or emailed to multiple sites or posted to a listserv without the copyright holder's express written permission. However, users may print, download, or email articles for individual use.