

A Retrospective Study on 287 Implants Installed in Resorbed Maxillae Grafted with Fresh Frozen Allogeneous Bone

Francesco Carinci, MD;* Giorgio Brunelli, MD;† Maurizio Franco, MD;‡ Alessandro Viscioni MD;§ Leone Rigo, MD;‡ Riccardo Guidi, DDS;§ Laura Strohmenger, MD||

ABSTRACT

Background: Several studies have been performed to evaluate the clinical outcome of implants inserted into maxillae grafted with autogenous bone but few reports have focused on maxillae grafted with fresh-frozen allogeneous bone (FFAB).

Purpose: The purpose of this study is to retrospectively evaluate the clinical outcome of implants installed in resorbed maxillae augmented with FFAB.

Materials and Methods: A total of 69 patients whom had been treated with FFAB grafts to their maxillae and implant placement 4 to 6 months later were retrospectively evaluated. Edentulism was total and partial in 22 and 47 cases, respectively. A total of 287 implants of various systems had been used. A life table analysis was performed. Marginal bone loss was calculated in radiographs.

Results: Five of the 287 implants were lost, giving a survival rate (SVR) of 98.3% over a mean follow-up time of 26 months. The marginal bone resorption at the implants was 1.68 mm (SD = 0.44) after 1 year and 1.85 mm (SD = 0.98) after 4 years. The cumulative success rate based on defined criteria was 96% in the first year but decreased to 40% at 4 years because of marginal bone loss. The Kaplan–Meier algorithm demonstrated a better outcome for female patients, removable dentures, and total edentulism. No differences were detected among diameters, lengths, and implant site.

Conclusion: Implants placed in FFAB showed a high SVR similar to that reported in previous studies on maxillae grafted with autogenous iliac crest bone. Although our data point to more marginal bone loss in partially edentulous patients and for fixed prosthetic restorations, the use of FFAB for reconstruction of the atrophic jaw prior to implant placement can be considered as a reliable alternative to autogenous bone.

KEY WORDS: allograft, homograft, iliac crest, implant, life table analysis, maxilla

INTRODUCTION

The anatomic limitations of residual alveolar bone can cause problems for the insertion of dental implants.¹ Less-than-ideal sites can result in an esthetic and

functional compromise since implant placement requires an adequate quantity and quality of bone. In many cases, however, this anatomic problem can be solved with autogenous bone grafts, which are the most predictable and successful materials available.^{2–6}

Although good clinical outcomes have been reported, especially in recent years, few reports focused on implants inserted into maxillae grafted with fresh frozen allogeneous bone (ie, fresh-frozen allogeneous bone [FFAB]).

Many forms of banked allogeneous bone are available to the surgeon such as FFAB, freeze-dried bone, and demineralized freeze-dried bone. Each one of these grafts carries risks and has unique limitations and handling properties. In order to use these materials appropriately, the surgeon must be familiar with the

*Associate professor, Maxillofacial Surgery, University of Ferrara, Ferrara, Italy; †consultant, Maxillofacial Surgery, University of Ferrara, Ferrara, Italy; ‡consultant, Department of Maxillofacial Surgery, Civil Hospital, Castelfranco Veneto, Italy; §consultant, Dental School, University of Milan, Milan, Italy; ||professor, Dental School, University of Milan, Milan, Italy

Reprint requests: Prof. Francesco Carinci, Chair of Maxillofacial Surgery, Arcispedale S. Anna, Corso Giovecca 203, 44100 Ferrara, Italy; e-mail: crc@unife.it

© 2008, Copyright the Authors

Journal Compilation © 2008, Wiley Periodicals, Inc.

DOI 10.1111/j.1708-8208.2008.00133.x

properties of each and must feel confident that the bone bank providing the graft is supplying a safe and sterile graft.⁷

Regarding the use of FFAB in oral and maxillofacial surgery, only two articles are to be found in the literature. In 1992 Perrot⁸ used it in combination with autologous bone from the iliac crest to restore atrophic jaws (eight patients) and FFAB alone in one case of ameloblastoma, and one case of mixoma of the mandible (two patients): his outcome was – after prosthetic restoration – a survival rate (SVR) of 98.8% (one implant lost out of 29). In 2002, Rochanawutanon⁹ demonstrated that even after the resection of big portions of the mandible FFAB can be used as he reported on four cases with a follow-up of over 12 years.

Since FFAB has ever increasing clinical applications, and no report is available on implants inserted into maxillae grafted with FFAB, we therefore decided to perform a retrospective study on 69 patients operated on in our clinic.

MATERIALS AND METHODS

Patients

In the period between December 2003 and December 2006, 81 patients (52 females and 29 males) with a median age of 52 years were operated on at the Civil Hospital, Castelfranco Veneto, Italy. Among them, 69 patients (42 females and 27 males) with a median age of 53 years were treated with a maxillary FFAB graft and implants. Forty-seven patients showed partial edentulism and 22 were completely edentulous. Informed written consent approved by the local Ethics Committee was obtained from patients to use their data for research purposes.

Graft Material

The FFAB is a mineralized, nonirradiated, only disinfected, and frozen homologous bone (Veneto Tissue Bank, Treviso, Italy). The bone is harvested from the anterior and posterior iliac crest, during the first 12 hours after donor death. The bone is then disinfected for at least 72 hours at -4°C , in a polychemotherapeutic solution of vancomycin, polymyxin, glazidine, and lincomycin, following that the sample is irrigated with a sterile saline solution. The sample is then subdivided into corticomedullary blocks, packed in double sterile casing and frozen at -80°C .

The requirements for homologous bone donors are more stringent with respect to those of organ donors. The presence of risk factors such as contagious disease, neoplasm, rheumatismal and/or degenerative diseases, and sepsis necessarily disqualifies the donor. In order to detect infectious agents, the following tests are performed on donor blood samples taken within 8 hours of death: anti-HIV-I/II Ab; anti-HCV Ab; HbsAg; anti-HBc Ab; anti-HBs Ab; anti-HTLV-I/II Ab; anti-Ag treponemal Ab; anti-CMV IgG Ab; anti-CMV IgM Ab; anti-toxoplasma IgG Ab; and anti-toxoplasma IgM Ab. A culture is also performed to detect aerobic and anaerobic bacteria, mycobacteria, and mycotic agents. As a further safety method, a serological follow-up is conducted using polymerase chain reaction techniques to detect any viral RNA or DNA of HIV, HCV, and HBV. This method reduces the “diagnostic window period” to 7 days for HIV, HCV, and HBV.

Grafting Technique

FFAB was grafted to the patient's maxillae under general anesthesia. FFAB was used en block (Figures 1 and 2). Usually the mean post-grafting period was 6 months before implant surgery (Figure 3), and the final prosthetic restoration was delivered after an additional 6 months (Figure 4).

Subjects were screened according to the following inclusion criteria: controlled oral hygiene; the absence of any lesions in the oral cavity; and sufficient residual bone volume after grafting to receive implants of at least 3.0 mm in diameter and 8.0 mm in length; in addition, the patients had to agree to participate in a postoperative check-up program.

Exclusion criteria were as follows: those with insufficient bone volume; patients with bruxism; those who smoke more than 20 cigarettes/day and excessively

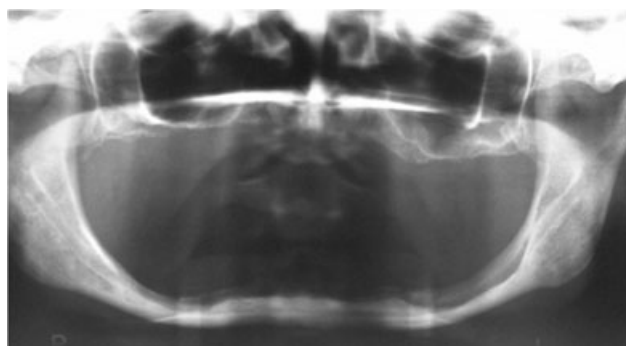


Figure 1 Presurgical orthopantomograph.

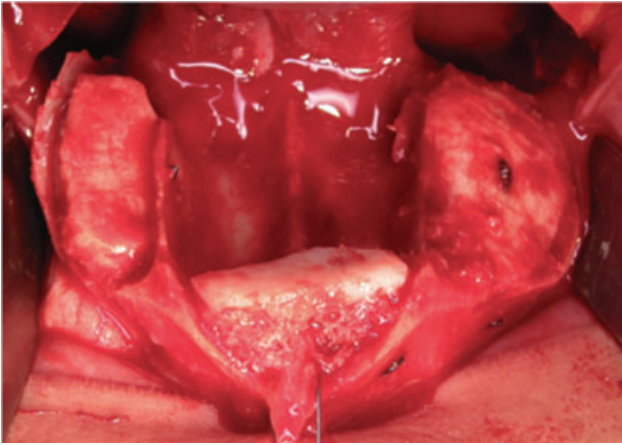


Figure 2 Le Fort I osteotomy and en block grafts insertion.

consumes alcohol; had localized radiation therapy of the oral cavity; had antitumor chemotherapy; liver, has blood, and kidney diseases; immunosuppressed patients; patients taking corticosteroids; pregnant women; and has inflammatory and autoimmune diseases of the oral cavity.

Implants

All implants were inserted in grafted sites. A total of 287 fixtures were inserted in 69 patients: 169 (58.9%) in the partially and 118 (41.1%) in totally edentulous patients. There were 82 double-etched (3i implants, Osseotite, Biomet Inc., Parsippany, NJ, USA); 26 SLA₁ (Astra implants, Astratech Inc., Waltham, MA, USA), 10 grit-blasted and acid-etched₁ (Frialit implants, Frialit, Dentsply Inc., York, PA, USA), 83 anodic oxidized (Nobel Biocare implants, TiUnite™, Nobelbiocare Inc., Yorba Linda, CA, USA), 61 CaPo₄ ceramic-blasted

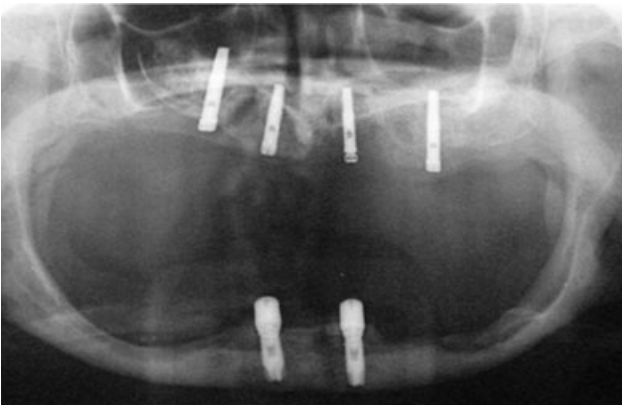


Figure 3 Implants installed in grafts.

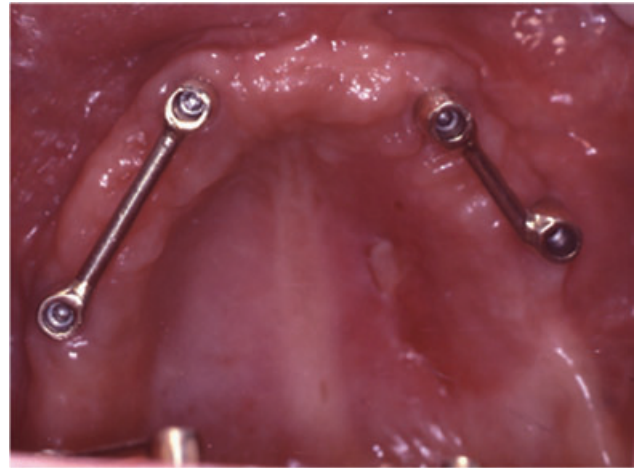


Figure 4 Two bars connecting two implants each supporting removable dentures.

(RBM implants, Lifecore Biomedical Inc., Chaska, MN, USA) 20 SLA₂ (Sweden & Martina implants, Sweden & Martina Spa, Due Carrare, Italy); and five other different types: two ITI (ITI Implants, Straumann Inc., Andover, MA, USA), two Pit-Easy (Oraltronic, Bremen, Germany), and one Biotech (Biotech, Povolaro di Dueville, Vicenza, Italy). Implant diameter and length ranged from 3.0 to 5.0 mm and from 8.0 to 16.0 mm, respectively. Implants were inserted to replace 16 incisors, 25 cuspids, 133 premolars, and 113 molars.

Implant Surgical and Prosthetic Technique

All patients underwent the same surgical protocol. An antimicrobial prophylaxis was administered with 500 mg amoxicillin twice daily for 5 days starting 1 hour before surgery. Local anesthesia was induced by infiltration with articaine/epinephrine and postsurgical analgesic treatment was performed with 100 mg Nimesulid twice daily for 3 days. Oral hygiene instructions were provided.

After making a crestal incision a mucoperiosteal flap was elevated. Implants were inserted according to the procedures recommended. The implant platform was positioned at the alveolar crest level. Sutures were removed 14 days after surgery. After 24 weeks from implant insertion, the provisional prosthesis was provided and the final restoration was usually delivered within an additional 8 weeks. The number of prosthetic units (ie, implant/crown ratio) was 0.8. All patients were included in a strict hygiene recall.

TABLE 1 Life Table Analysis According to the Number of Lost Implants

Time (year)	Number of Implants at the Beginning of the Time Interval	Number of Implants Lost from the Follow-Up in This Interval	Number of Terminal Events	Cumulative % Surviving at the End of the Time Interval
1	287	24	5	98
2	258	102	0	98
3	156	105	0	98
4	51	51	0	98

Data Collection

Before surgery, radiographic examinations were done with the use of orthopantomograph and computed tomography scans.

In each patient, peri-implant crestal bone levels were evaluated by a calibrated examination of orthopantomograph x-rays. Measurements were recorded before implant insertion, after surgery, and at the end of the follow-up period. The measurements were carried out mesially and distally to each implant, calculating the distance between the edge of the implant, and the most coronal point of contact between the bone and the implant. The bone level recorded just after the surgical insertion of the implant was the reference point for the following measurements. The measurement was rounded off to the nearest 0.1 mm. A peak Scale Loupe with a magnifying factor of seven times and a scale graduated in 0.1 mm was used (Peak Optics, Inc., Hacienda Heights, CA, USA).

The implant success rate (SCR) was evaluated according to the following criteria: (1) absence of persisting pain or dysesthesia; (2) absence of peri-implant infection with suppuration; (3) absence of mobility; and (4) absence of persisting peri-implant bone resorption greater than 1.5 mm during the first year of loading and 0.2 mm/years during the following years.¹⁰

Statistical Analysis

The differences between the implant abutment junction and the bone crestal level was defined as the implant abutment junction (IAJ) and calculated at the time of operation and during follow-up. The delta IAJ is the difference between the IAJ at the last check-up and the IAJ recorded just after the operation. Delta IAJ medians were stratified according to the variables of interest.

A life table analysis was performed to investigate SVR and SCR as well a Kaplan–Meier and Cox analysis.^{11,12}

RESULTS

The average residual maxillary native bone before grafting was 3 mm and the average high gain caused by the grafted bone was 17.6 mm. The average graft resorption (from the alveolar rest to the sinus floor) was 3.8, 3.5, 3.3, and 3.6 mm in patients with 1-, 2-, 3-, and 4-year follow-ups, respectively.

The mean follow-up of the implants was 26 months. Five implants were lost in the postoperative period (within 6 months) giving a SVR of 98.3% (Table 1). No implants were lost during clinical function. The cumulative SCR based on defined criteria was 96% in the first year but decreased to 40% at 4 years (Table 2).

The marginal bone resorption at the implants was small during the first year, 1.68 mm (SD = 0.44) but increased with time and was 1.85 mm (SD = 0.98) after 4 years. Table 3 reports the median delta IAJ (ie, mean peri-implant crestal bone resorption) according to the studied variables.

All five failures were 13-mm long implants with various surface treatments and placed in the first molar region (Table 4).

The Kaplan–Meier algorithm demonstrates that type of prosthetic restoration (log-rank test = 17.55, $df = 2$, $p = .001$) and edentulism type (log-rank test = 16.72, $df = 1$, $p = .001$) have an impact on SCR with a better outcome for removable dentures and total edentulism. Moreover, the outcomes were better in female than in male patients (Table 5). No differences were detected among diameters, lengths, and implant site in term of SCR.

TABLE 2 Life Table Analysis According to the Number of Implants Successfully in Place (ie, Bone Resorption <1.5 mm Within the First Year and <0.2 mm in the Subsequent Years)

Time (year)	Number of Implants at the Beginning of the Time Interval	Number of Implants Lost from the Follow-Up in This Interval	Number of Terminal Events	Cumulative % Surviving at the End of the Time Interval
1	282	13	11	96
2	258	57	45	77
3	156	80	25	60
4	51	41	10	41

Number of implants belonging to the time interval is the number of implants still in place (ie, not lost).

Number of implants lost from the follow-up in this interval are grouped within the first, second, third, and fourth year of observation.

Number of terminal events are the number of implants with more than 1.5, 1.7, 1.9, and 2.1 mm of bone resorption during the first, second, third, and fourth year of observation.

Cumulative % surviving at the end of the time interval is the percentage of implants with successful bone remodeling (ie, lower than the cutoff values).

DISCUSSION

In the present study peri-implant bone resorption was considered and not peri-implant probing as controversy still exists regarding the correlation between probing depth and implant SCRs.^{13,14}

The identification of guidelines for the long-term SVR and SCR (ie, good clinical, radiological, and esthetic outcome) are the main goals of the recent literature. Usually variables influencing the final result are grouped as: (1) surgery- ; (2) host- ; (3) implant- ; and (4) occlusion-related factors.¹⁵ The surgery-related factors comprise several variables such as an excess of

surgical trauma like thermal injury,¹⁶ bone preparation, drill sharpness, and design.¹⁷ Bone quality and quantity are the most important host-related factors,^{17,18} whereas design,^{19–21} surface coating,²² diameter, and length^{23–27} are the strongest implant-related factors. Finally, quality and quantity of force²⁸ and prosthetic design²⁹ are the variables of interest among the occlusion-related factors. All these variables are a matter of scientific investigation as they may affect the clinical outcome.

In general, length, diameter, and type are considered to be relevant fixture-related factors. In the present study length and diameter have had no impact on SCR. This

TABLE 3 Distribution of Series

Implant Site	Implant Length	Implant Diameter	Implant Surface	Prosthetic Type	Edentulism
Incisors	Length < 13 mm	Diameter < 3.75 mm	Double-etched	None	Partial
16 (2.5)	23 (1.7)	75 (2.0)	82 (1.9)	34 (1.7)	169 (2.0)
Cuspids	Length = 13 mm	Diameter = 3.75 mm	SLA ₁	Fixed prosthesis	Total
25 (1.9)	190 (2.0)	110 (1.8)	26 (3.2)	214 (2.0)	118 (1.9)
Premolars	Length > 13 mm	Diameter > 3.75 mm	Grit blasted and acid etched	Removable dentures	—
133 (1.9)	74 (2.0)	102 (2.1)	10 (5.1)	39 (1.8)	
Molars	—	—	Anodic oxidized	—	—
113 (2.0)			8.3 (1.7)		
—	—	—	CaPo ₄ ceramic-blasted	—	—
			61 (1.6)		
—	—	—	SLA ₂	—	—
			20 (1.2)		
—	—	—	Others	—	—
			5 (2.3)		

The number of cases is out of parentheses whereas the median delta implant abutment junction (ie, the mean peri-implant crestal bone resorption) is in parentheses.

TABLE 4 Failed Implants

Implant Diameter	Implant Length	Graft Site	Implant Site	Implant Type	Number of Months Post-implant Insertion	Prosthesis
3.5	13	Maxilla	26	Double etched	4	None
3.5	13	Maxilla	16	Double etched	4	None
3.5	13	Maxilla	26	Anodic oxidized	1	None
3.75	13	Maxilla	26	CaPo ₄ ceramic-blasted	6	None
4.3	13	Maxilla	26	Anodic oxidized	1	None

result is comparable with those of previous reports on different type of fixtures inserted into maxilla grafted with autologous iliac crest bone.²⁻⁶

Bone quality, a host-related factor, is believed to be one of the most important predictors of outcome and in grafted jaws has particular relevance. It is generally accepted that the mandible (especially the interforaminal region) has better bone quality than the maxilla, and this fact is probably the reason why several reports are available regarding critical occlusal procedure (ie, immediately loaded) of implants inserted into the mandible with a high SVR.³⁰⁻³² Here a high SVR and SCR was reported and no difference was detected as regards implant site. Life table analysis demonstrated a SVR of about 96% whereas cumulative SCR was 96% in the first year but decreased to 40% at 4 years. Thus, our data show that FFAB is an effective material to restore alveolar ridge volume as only five implants were lost. However, according to our data, more crestal bone resorption has to be expected over time.

Among the occlusal-related factors, no differences were detected as regards SVR. However, a better

outcome was detected for unloaded bone and removable dentures (see Table 3). The type of edentulism was also statistically significant for SCR, with better results for patients who had total edentulism. Partially edentulous patients, especially those with a history of chronic periodontitis, may exhibit significantly greater long-term probing pocket depth, peri-implant marginal bone loss, and incidence of peri-implantitis compared with periodontally healthy subjects. However, no conclusive data are available in the recent literature.³³

CONCLUSIONS

Implants placed in FFAB showed a high SVR similar to that reported in previous studies on maxillae grafted with autogenous iliac crest bone. Although our data point to more marginal bone loss in partially edentulous patients and for fixed prosthetic restorations, the use of FFAB for reconstruction of the atrophic jaw prior to implant placement can be considered as a reliable alternative to autogenous bone.

TABLE 5 Output of Cox Regression Reporting the Variables Associated Statistically with Delta Implant Abutment Junction (IAJ) by Evaluating Delta IAJ (ie, Success Rate). A Better Outcome is Detected for Female, Removable Dentures, and Total Edentulism

Variable	B	Standard Error	Significance ($p < .05$)	95% Confidence Interval	
				Lower	Upper
Age	-8.57E-05	0.0145	0.9953	0.9720	1.0287
Gender	-0.6598	0.2321	0.0045	0.3280	0.8146
Implant site	0.0074	0.1610	0.9634	0.7348	1.3812
Implant length	0.1522	0.2094	0.4673	0.7724	1.7553
Implant diameter	0.1795	0.1611	0.2651	0.8727	1.6409
Type of restoration	-1.1316	0.2410	0.0001	0.2011	0.5172
Type of edentulism	-0.9419	0.2418	0.0001	0.2427	0.6262

ACKNOWLEDGMENT

This work was supported by FAR from the University of Ferrara (F.C.), Ferrara, Italy.

REFERENCES

- Carinci F, Farina A, Zanetti U, et al. Autologous bone grafts and endosseous implants: complementary techniques. *J Oral Maxillofac Surg* 1996; 54:486–494.
- Nystrom E, Ahlqvist J, Gunne J, Kahnberg KE. 10-year follow-up of onlay bone grafts and implants in severely resorbed maxillae. *Oral Int J Maxillofac Surg* 2004; 33:258–262.
- Kahnberg KE, Vannas-Lofqvist L. Maxillary osteotomies with an interpositional bone graft and implants for reconstruction of the severely resorbed maxilla: a clinical report. *Int J Oral Maxillofac Implants* 2005; 20:938–945.
- Peleg M, Garg AK, Mazor Z. Predictability of simultaneous implant placement in the severely atrophic posterior maxilla: a 9-year longitudinal experience study of 2132 implants placed into 731 human sinus grafts. *Int J Oral Maxillofac Implants* 2006; 21:94–102.
- Sjostrom M, Sennerby L, Nilson H, Lundgren S. Reconstruction of the atrophic edentulous maxilla with free iliac crest grafts and implants: a 3-year report of a prospective clinical study. *Clin Implant Dent Relat Res* 2007; 9:46–59.
- Barone A, Covani U. Maxillary alveolar ridge reconstruction with nonvascularized autogenous block bone: clinical results. *J Oral Maxillofac Surg* 2007; 65:2039–2046.
- Hardin CK. Banked bone. *Otolaryngol Clin North Am* 1994; 27:911–925.
- Perrot DH. The use of fresh frozen allogenic bone for maxillary and mandibular reconstruction. *Int J Oral Maxillofac Surg* 1992; 21:260–265.
- Rochanawutanon S. Long term follow up of reconstruction of allogenic mandibular bone crib packed with autogenous particulate cancellous bone marrow. *Cell Tissue Bank* 2002; 3:183–197.
- Albrektsson T, Zarb GA. Determinants of correct clinical reporting. *Int J Prostodont* 1998; 11:517–521.
- Dawson-Saunders B, Trapp RG. Basic & clinical biostatistic. Norwalk: Appleton & Lange, 1994.
- Cox DR, Oakes D. Analysis of survival data. New York: Chapman & Hall, 1984.
- Quirynen M, van Steenberghe D, Jacobs R, Schotte A, Darius P. The reliability of pocket probing around screw-type implants. *Clin Oral Impl Res* 1991; 2:186–192.
- Quirynen M, Naert I, van Steenberghe D, Teerlinck J, Dekeyser C, Theuniers G. Periodontal aspects of osseointegrated fixtures supporting an overdenture. A 4-year retrospective study. *J Clin Periodontol* 1991; 18:719–728.
- Gapski R, Wang HL, Mascarenhas P, Lang NP. Critical review of immediate implant loading. *Clin Oral Impl Res* 2003; 14:515–527.
- Satomi K, Akagawa Y, Nikai H, Tsuru H. Bone-implant interface structures after nontapping and tapping insertion of screw-type titanium alloy endosseous implants. *J Prosthet Dent* 1988; 59:339–342.
- Eriksson AR, Albrektsson T, Albrektsson B. Heat caused by drilling cortical bone. Temperature measured in vivo in patients and animals. *Acta Orthop Scand* 1984; 55:629–631.
- Piattelli A, Paolantonio M, Corigliano M, Scarano A. Immediate loading of titanium plasma-sprayed screw-shaped implants in man: a clinical and histological report of two cases. *J Periodontol* 1997; 68:591–597.
- Skalak R. Aspects of biomechanical considerations. In: Branemark PI, Zarb G, Albrektsson T, eds. Tissue-integrated prosthesis: osseointegration in clinical dentistry. Chicago: Quintessence, 1985:117–128.
- Randow K, Ericsson I, Nilner K, Petersson A, Glantz PO. Immediate functional loading of Branemark dental implants. An 18-month clinical follow-up study. *Clin Oral Impl Res* 1999; 10:8–15.
- Misch CE. Implant design considerations for the posterior regions of the mouth. In: Misch CE, ed. Contemporary implant dentistry. Chicago: Mosby, 1999:376–386.
- Wennerberg A, Albrektsson T, Andersson B, Krol JJ. A histomorphometric and removal torque study of screw-shaped titanium implants with three different surface topographies. *Clin Oral Impl Res* 1995; 6:24–30.
- Vigolo P, Givani A. Clinical evaluation of single-tooth mini-implant restorations: a five-year retrospective study. *J Prosthet Dent* 2000; 84:50–54.
- Davarpanah M, Martinez H, Tecucianu JF, Celletti R, Lazzara R. Small-diameter implants: indications and contraindications. *J Esthet Dent* 2000; 12:186–194.
- Zinsli B, Sagesser T, Mericske E, Mericske-Stern R. Clinical evaluation of small-diameter ITI implants: a prospective study. *Int J Oral Maxillofac Implants* 2004; 19:92–99.
- Vigolo P, Givani A, Majzoub Z, Cordioli G. Clinical evaluation of small-diameter implants in single-tooth and multiple-implant restorations: a 7-year retrospective study. *Int J Oral Maxillofac Implants* 2004; 19:703–709.
- Comfort MB, Chu FC, Chai J, Wat PY, Chow TW. A 5-year prospective study on small diameter screw-shaped oral implants. *J Oral Rehabil* 2005; 32:341–345.
- Colomina LE. Immediate loading of implant-fixed mandibular prostheses: a prospective 18-month follow-up clinical study – preliminary report. *Implant Dent* 2001; 10:23–29.
- Salama H, Rose LF, Salama M, Betts NJ. Immediate loading of bilaterally splinted titanium root-form implants in fixed prosthodontics – a technique reexamined: two case reports. *Int J Periodontics Restorative Dent* 1995; 15:344–361.

30. Balshi TJ, Wolfinger GJ. Immediate loading of Branemark implants in edentulous mandibles: a preliminary report. *Implant Dent* 1997; 6:83–88.
31. Randow K, Ericsson I, Nilner K, Petersson A, Glantz PO. Immediate functional loading of Branemark dental implants. An 18-month clinical follow-up study. *Clin Oral Impl Res* 1999; 10:8–15.
32. Chow J, Hui E, Liu J, et al. The Hong Kong Bridge Protocol. Immediate loading of mandibular Branemark fixtures using a fixed provisional prosthesis: preliminary results. *Clin Impl Dent Relat Res* 2001; 3:166–174.
33. Karoussis IK, Kotsovilis S, Fourmoussis I. A comprehensive and critical review of dental implant prognosis in periodontally compromised partially edentulous patients. *Clin Oral Implants Res* 2007; 18:669–679.

Copyright of Clinical Implant Dentistry & Related Research is the property of Wiley-Blackwell and its content may not be copied or emailed to multiple sites or posted to a listserv without the copyright holder's express written permission. However, users may print, download, or email articles for individual use.