

The Effect of Platelet-Rich Plasma on Healing of Palatal Donor Site following Connective Tissue Harvesting: A Pilot Study in Dogs

Yadollah Soleimani Shayesteh, DDS;* Nosratollah Eshghyar, DDS;† Neda Moslemi, DDS;‡
Mohammad Mehdi Dehghan, DVM, PhD;§ Pouria Motahhary, DDS;|| Zahra Ghobadi, DMD;¶
Banafsheh Golestan, PhD#

ABSTRACT

Background: Peri-implant plastic surgery includes soft tissue enhancement by connective tissue grafting. The palatal donor site provides peri-implant keratinized mucosa and soft tissue height. Platelet-rich plasma (PRP) contains growth factors that may enhance early healing.

Purpose: The present animal study investigated the effect of PRP on wound healing of palatal donor site after connective tissue harvesting.

Materials and Methods: In 12 mongrel dogs, bilateral palatal connective tissues of 10 × 15 mm were harvested. At test site, PRP was applied into the wound, and the contralateral site served as control. The healing was evaluated clinically and histologically at 1 week, 2 weeks, and 4 weeks after surgeries. Exact binomial probability and Wilcoxon signed-rank test were used to compare the clinical and histologic measurements.

Results: No statistically significant differences between PRP and control sites were measured with regard to clinical healing ($p = 1.000$) and histologic variables, including inflammatory cells ($p = .750$), collagen fibers ($p = .375$), and granulation tissue ($p = .500$) at any time interval.

Conclusion: The addition of PRP to palatal mucosal wound sites did not accelerate wound healing.

KEY WORDS: connective tissue graft, histologic study, palatal donor site, platelet-rich plasma, soft tissue augmentation, wound healing

*Periodontist, associate professor, Department of Periodontics, Dental Research Center, Tehran University of Medical Sciences, Tehran, Iran; †oral pathologist, associate professor, Department of Oral and Maxillofacial Pathology, Tehran University of Medical Sciences, Tehran, Iran; ‡periodontist, assistant professor, Department of Periodontics, Dental Research Center, Tehran University of Medical Sciences, Tehran, Iran; §veterinary surgeon, associate professor, Department of Clinical Sciences, Faculty of Veterinary Medicine, University of Tehran, Tehran, Iran; ||oral pathologist, assistant professor, Department of Oral and Maxillofacial Pathology, Tehran University of Medical Sciences, Tehran, Iran; ¶dentist, private practice, Tehran, Iran; #statistician, assistant professor, Department of Epidemiology and Biostatistics, Tehran University of Medical Sciences, Tehran, Iran

Reprint requests: Dr. Neda Moslemi, DDS, Periodontist, Assistant Professor of Periodontics Department, Dental Research Center, Dental Faculty, Tehran University of Medical Sciences, Ghods Street, Enghelab Ave, Post Code: 14147, Tehran, Iran; e-mail: neda_moslemi@yahoo.com, nmoslemi@razi.tums.ac.ir

© 2010 Wiley Periodicals, Inc.

DOI 10.1111/j.1708-8208.2009.00263.x

INTRODUCTION

Peri-implant plastic surgery includes soft tissue enhancement by connective tissue grafting from the palatal donor site.¹ Although the connective tissue graft procedure is successful in the lateral and vertical augmentation of the peri-implant site, patient's discomfort during healing period of the donor site and delayed wound healing of palate² is a significant concern. The healing of the donor site is a complex process including three phases of cell migration (inflammatory phase), cell proliferation (proliferative phase), and matrix synthesis (remodeling phase). Each of these phases are controlled and regulated by different growth factors.³ During normal wound healing, the activated platelets release α -granules that are rich in platelet-derived growth factor, transforming growth factor- β , vascular endothelial growth factor, and platelet-derived angiogenic

factor.⁴⁻⁷ Platelet-rich plasma (PRP) is an autologous concentration of platelets in a small volume of plasma. It also contains the three proteins in blood known as cell adhesion molecules (fibrin, fibronectin, and vitronectin), which act as a matrix for connective tissue and epithelial migration.⁸ Increasing the wound concentration of platelets may improve and accelerate palatal soft tissue healing.⁹

The aim of the present randomized animal study was to evaluate the effect of PRP on soft tissue healing of palatal donor site after connective tissue harvesting.

MATERIALS AND METHODS

Experimental Design

Twelve adult male mongrel dogs, weighing approximately 21 kg (18–25 kg), were used in this study. The dog model has been identified as a good animal model for such investigations.¹⁰ The experimental protocol was approved by the Institutional Animal Care and Use Committee of Tehran University of Medical Sciences. Animals were determined to be healthy based on the results of physical examination and complete blood count. The dogs were housed individually in indoor cages. They were fed by commercial soft-maintenance diet (Friskies, Purina, Marne La Vallee, France) once a day, and water was offered *ad libitum*.

PRP Preparation

PRP was prepared using a technique described by Okuda and colleagues¹¹ briefly; 40 mL of autologous blood withdrawn from each dog was initially centrifuged at 2,400 rpm for 10 minutes to separate PRP and platelet-poor plasma (PPP) portions from the red blood cell fraction. The PRP and PPP portions were again centrifuged at 3,600 rpm for 15 minutes to separate PRP from PPP. The resulting pellet of platelets was resuspended in 1 mL of residual plasma. Platelet counts for the PRP were measured using an automatic cell counter (Hema-Screen 18, Hospitex Diagnostics, Florence, Italy). The PRP (0.5 mL) was activated just before application with a 10% calcium chloride solution and 5,000 units of bovine thrombin to form a gel.

Surgical Procedure

The dogs were premedicated with xylazine-HCl (xylazine 2%, Alfasan International BV, Woerden, The Netherlands) (2 mg/kg) intramuscularly. This was followed

by induction of general anesthesia with intravenous injection of the mixture of ketamin-HCl (ketamin 10%, Alfasan International BV) (10 mg/kg) and diazepam (ZEPADIC®, Caspian Tamin Pharmaceutical Co., Rasht, Iran) (0.5 mg/kg), and maintained by the same drugs. The general anesthesia was delivered and monitored under the supervision of a veterinary surgeon.

All surgical procedures were performed by a periodontist. A horizontal incision was made 2 mm from the palatal gingival margin at the mesial of the first molar and extending mesially by 15 mm. Vertical incisions of 10 mm were then made at both ends of the first incision. A 1-mm thick flap was raised, and incisions through the periosteum dissected and removed the contained tissue (Figure 1A). The same surgical design was executed in the contralateral site. The surgeon was unaware about the test and control sites that were randomly assigned by one who was not involved in the surgical procedures. The sham-surgery control site was sutured back to its original position. The test site was sutured back to its original position after the insertion of 0.5 mL of PRP (see Figure 1B). Because of jelly consistency of the PRP, there was not any concern about the displacement of PRP gel during or after surgery.

To reduce pain and discomfort, tramadol (MS Pharma, Washington, DC, USA) (5 mg/kg) was administered every 12 hours for 3 days after surgery. Cefazolin (Cefzolib, Jaber Ebne Hayyan Pharmaceutical Co., Tehran, Iran) (25 mg/kg) was given before surgery and continued twice daily for 3 days after the surgical procedure. The soft-diet regimen (Friskies, Purina) was continued until the end of the study period. The sutures were removed 1 week after surgery.

Sample Preparation and Histologic Analysis

Twelve animals were randomly assigned into three groups. There were four dogs in each group. The animals were sacrificed by an overdose of intravenous sodium thiopental at 1 week, 2 weeks, and 4 weeks after surgeries. Before histologic preparation, a photograph was taken from the area. Sharp incisions were made 2 mm from the defect borders. The tissue was separated from the bone using a periosteal elevator.

Samples were prepared for histologic evaluation according to small specimen preparation method.¹² Each sample was fixed in 10% formalin and then embedded in paraffin. The samples were prepared by routine histologic method for hematoxylin and eosin

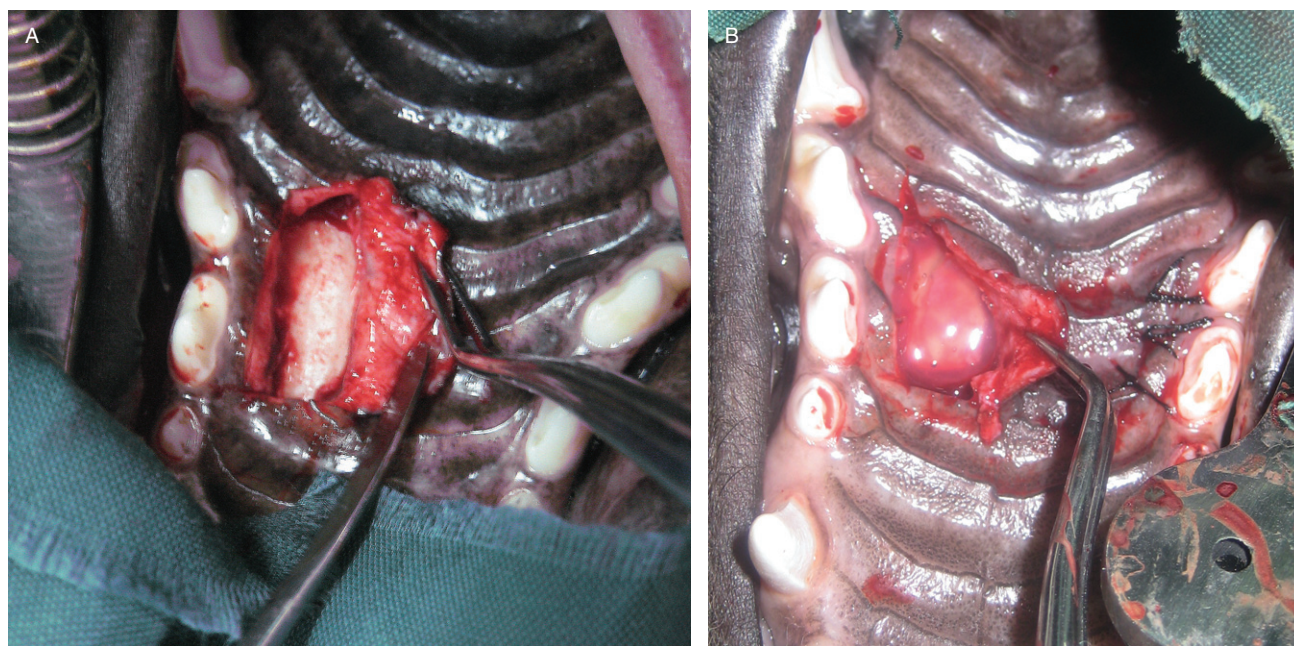


Figure 1 A, Photographs of surgical procedure at palatal site of dog. Palatal connective tissue including periosteum was removed. Sound bone is evident. 150 × 140 mm. B, Platelet-rich plasma has been applied in the experimental defect. 150 × 160 mm.

(H&E) staining. Sections with the thickness of 4 μ m were cut (perpendicular to the periosteum), stained with H&E, and examined under a light microscope (BX41, Olympus Co., Tokyo, Japan). The following criteria were examined in histologic sections by a masked examiner: *inflammatory cells (ICs)* were assessed based on IC counts under a high power field ($\times 40$) as follows: grade 0 (no IC), grade 1 (< 20 IC), grade 2 (20–50 IC), grade 3 (> 50 IC), and grade 4 (abscess). The relative amount of *collagen fibers* was compared and graded from 1 to 3. The presence or absence of *granulation tissue* was examined in the evaluated field.

Clinical Healing

A masked periodontist graded the clinical photos of the test and control sites based on color match, repigmentation of the surgical site, tissue texture, unity of the surgical site and the adjacent area, and the presence/absence of border necrosis. These criteria have been modified from the criteria suggested by Yen and colleagues.⁹

Statistical Analysis

The histologic differences of the test and control groups were measured via Wilcoxon signed-rank test. The

clinical differences were assessed using exact binomial probability. A p value of less than .05 was considered statistically significant.

RESULTS

Platelet Counts in PRP

The mean number of platelets in whole blood and PRP were 298.22×10^3 and $2,070.78 \times 10^3$, respectively. According to paired t -test, the difference of platelets in whole blood and PRP was statistically significant ($p = .004$).

Histologic Findings

The histologic comparison between the test and control sites showed no statistically significant difference in any time interval (Figure 2, Table 1): ICs ($p = .750$), collagen fibers ($p = .375$), and granulation tissue ($p = .500$) (Table 2).

Clinical Findings

All surgical sites healed well without evidence of infection. Overall, the clinical comparison of the test and control groups did not show a significant difference ($p = 1.000$) (Table 3).

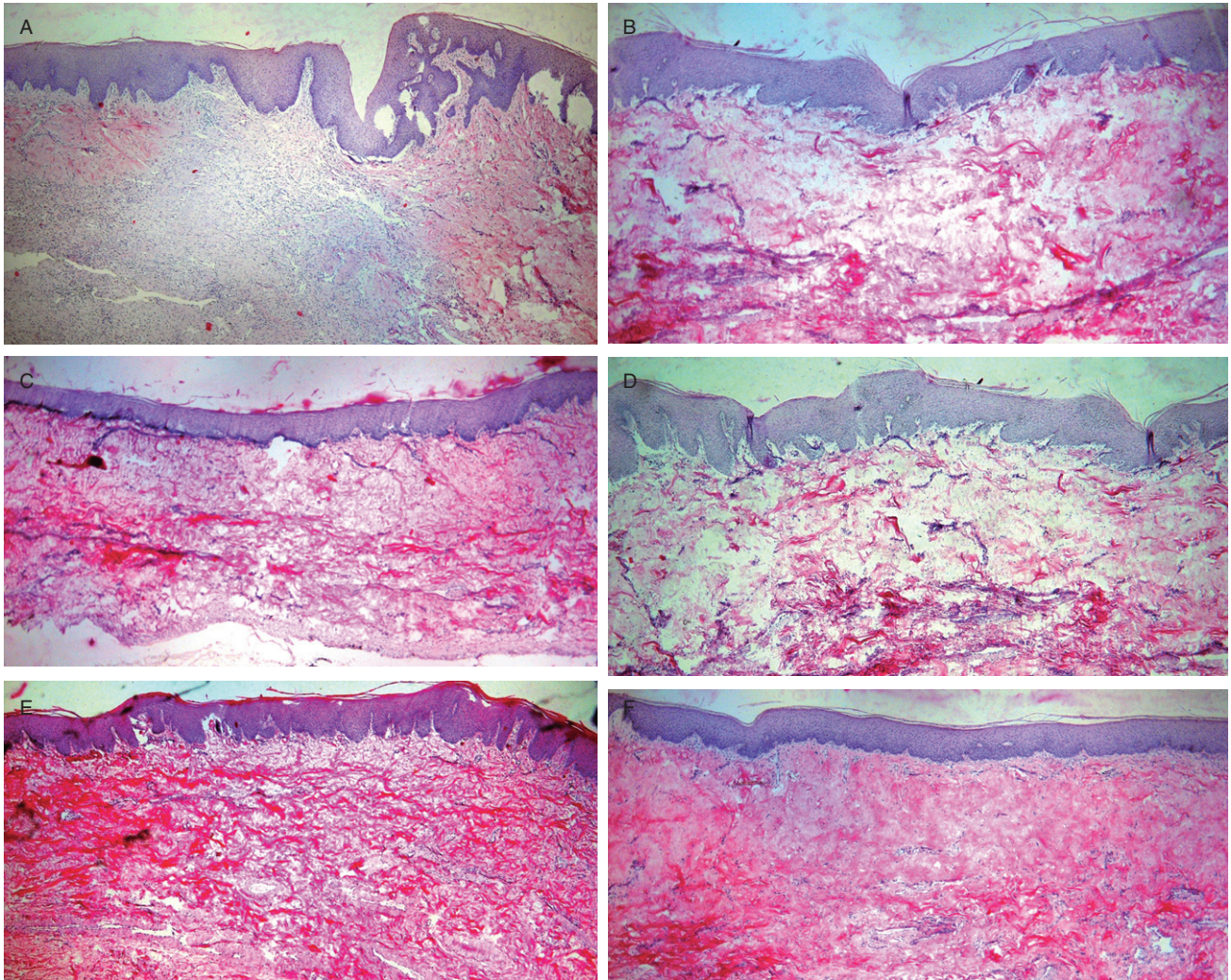


Figure 2 Photomicrographs of platelet-rich plasma (PRP) and control sites at first, second, and fourth weeks after surgery ($\times 40$). A, PRP site at first week after surgery, intact oral epithelium and obvious fibroblastic activity. B, Control site at first week after surgery, intact oral epithelium and start of collagen formation. C, PRP site at second week after surgery, collagen formation and fibrosis are evident. D, Control site at second week after surgery, collagen formation and fibrosis are similar to C. E, PRP site at fourth week after surgery, prominent collagen formation. F, Control site at fourth week after surgery, prominent collagen formation same as PRP site (hematoxylin and eosin stain, original magnification $\times 40$).

DISCUSSION

This split-mouth randomized clinical and histologic study investigated wound healing following application of PRP into palatal wound sites after connective tissue harvesting in dogs. The wound healing process was uneventful in all animals. The clinical and histologic evaluation did not reveal any evidence of statistically significant differences between wounds receiving the PRP preparation versus that of the sham-surgery control.

The PRP used in this study exhibited of significantly higher platelet counts than whole blood. The role of platelets in wound healing has been established.

However, lack of platelets in experimental animals has not shown to influence wound healing significantly.¹³ Possibly because of compensatory mechanisms, PRP may not exert a decisive role on wound healing.¹⁴

In the present study, at second and fourth weeks after surgery, more ICs were detected in sites receiving PRP compared with control; however, the differences were not statistically significant. In concert, using a rabbit model, Chandra and colleagues¹⁵ examined histologic differences in skin wounds closed with and without the application of an autologous platelet gel. The sites receiving the platelet gel showed more inflammation during the first 3 weeks after surgery. More inflammation in sites receiving platelet gel was

TABLE 1 Comparison of Histologic Parameters in Test and Control Groups over 4 Weeks

Time Interval	Histologic Parameter	PRP Site Mean (SD)	Control Site Mean (SD)	Mean Difference (SD)	p Value*
1 week	Inflammatory cells	2.25 (0.96)	2.25 (1.26)	0.00 (0.82)	1.00
	Collagen fibers	1.00 (0.00)	1.00 (0.82)	0.00 (0.82)	1.00
	Granulation tissue	1.00 (0.00)	0.75 (0.50)	0.25 (0.50)	1.00
2 weeks	Inflammatory cells	1.00 (0.82)	0.75 (0.96)	0.25 (0.50)	1.00
	Collagen fibers	2.25 (0.96)	2.50 (1.00)	−0.25 (0.50)	1.00
	Granulation tissue	0.25 (0.50)	0.25 (0.50)	0.00 (0.00)	1.00
4 weeks	Inflammatory cells	1.25 (1.50)	1.00 (1.41)	0.25 (1.25)	1.00
	Collagen fibers	2.00 (0.82)	2.50 (1.00)	−0.50 (0.58)	.50
	Granulation tissue	0.50 (0.58)	0.25 (0.50)	0.25 (0.50)	1.00

*Wilcoxon signed-rank test, exact significance.

PRP = platelet-rich plasma.

TABLE 2 Comparison of Histologic Parameters with Regard to Treatment Group over Time Intervals

Histologic Parameter	Group	1 Week Mean (SD)	2 Weeks Mean (SD)	4 Weeks Mean (SD)	p Value*
Inflammatory cells	PRP	2.25 (0.96)	1.00 (0.82)	1.25 (1.50)	.750
	Control	2.25 (1.26)	0.75 (0.96)	1.00 (1.41)	
Collagen fibers	PRP	1.00 (0.00)	2.25 (0.96)	2.00 (0.82)	.375
	Control	1.00 (0.82)	2.50 (1.00)	2.50 (1.00)	
Granulation tissue	PRP	1.00 (0.00)	0.25 (0.50)	0.50 (0.58)	.500
	Control	0.75 (0.50)	0.25 (0.50)	0.25 (0.50)	

*Marginal comparison between test and control groups (Wilcoxon signed-rank test, exact significance).

PRP, platelet-rich plasma.

attributed to the chemotactic effect of activated platelets.

Most studies evaluating the effect of PRP in intraoral soft tissue healing have focused on root coverage procedures.^{9,16–19} However, to the best of our knowledge, there was only one study that evaluated the effect

of PRP on palatal wound healing. In this placebo-controlled human study, collagen sponge was used as a placebo control.⁹ While PRP is a chemoattractant to ICs,^{15,20,21} lower concentration of ICs was reported in PRP sites. It was suggested that the exogenous collagen sponge used as placebo might stimulate more inflammatory response in comparison with autogenous PRP.⁹

According to the results of the present study, the addition of PRP had no significant influence on the amount of collagen fibers presented in palatal wound area. This is in accordance with the result of the study of Chandra and colleagues¹⁵ in which fibrosis did not differ between platelet gel-treated and control skin wounds. It can be assumed that natural clot within the wound area provides a favorable matrix and sufficient products for future tissue modeling, leading to collagen synthesis, and the addition of PRP does not seem to have any further benefit.

TABLE 3 Number of Animals with Better Clinical Healing at PRP or Control Sites in 1 Week, 2 Weeks, and 4 Weeks after Surgical Procedure

	1 Week	2 Weeks	4 Weeks
Better Clinical Healing			
At PRP site	2	1	1
At control site	1	2	2
At both sites	1	1	1
Total	4	4	4

PRP = platelet-rich plasma.

The histologic observations support the clinical findings, where no difference was found in healing of sites with and without PRP.

In healthy individuals, surgical wounds contain sufficient levels of growth factors. In contrast, an imbalance of cytokines has been found in chronic wounds²⁰ that might explain a PRP-associated healing improvement in chronic wounds.^{22,23} In healthy individuals, the development of the blood clot and optimal levels of growth factors released into the palatal surgical wound maybe compromised by the PRP preparation. The limited effect of PRP, if any, is certainly supported by a recent systematic review concluding that there was no benefit related to PRP when it is used into skin surgical wounds.²⁴

CONCLUSION

The present study does not support the use of PRP in accelerating palatal wound healing after connective tissue harvesting.

ACKNOWLEDGMENTS

This study was supported by a grant (code number: 87-02-69-7146) from the Dental Research Center of Tehran University of Medical Sciences. We gratefully acknowledge Professor Hessam Nowzari for editing the article, and Ms. Sholeh Mohammadi for the valuable assistance in the surgical procedures.

REFERENCES

- Palacci P, Nowzari H. Soft tissue enhancement around dental implants. *Periodontol 2000* 2008; 47:113–132.
- Nooh N, Graves DT. Healing is delayed in oral compared to dermal excisional wounds. *J Periodontol* 2003; 74:242–246.
- Bhanot S, Alex JC. Current applications of platelet gels in facial plastic surgery. *Facial Plast Surg* 2002; 18:27–33.
- Fréchette JP, Martineau I, Gagnon G. Platelet-rich plasmas: growth factor content and roles in wound healing. *J Dent Res* 2005; 84:434–439.
- Mehta S, Watson JT. Platelet rich concentrate: basic science and current clinical applications. *J Orthop Trauma* 2008; 22:432–438.
- Nikolidakis D, Jansen JA. The biology of platelet-rich plasma and its application in oral surgery: literature review. *Tissue Eng Part B Rev* 2008; 14:249–258.
- Jacobson M, Fufa D, Abreu EL, Kevy S, Murray MM. Platelets, but not erythrocytes, significantly affect cytokine release and scaffold contraction in a provisional scaffold model. *Wound Repair Regen* 2008; 16:370–378.
- Marx RE. Platelet-rich plasma: evidence to support its use. *J Oral Maxillofac Surg* 2004; 62:489–496.
- Yen CA, Griffin TJ, Cheung WS, Chen J. Effects of platelet concentrate on palatal wound healing after connective tissue graft harvesting. *J Periodontol* 2007; 78:601–610.
- Perenack J, Wood RJ, Block MS, Gardiner D. Determination of subepithelial connective tissue graft thickness in the dog. *J Oral Maxillofac Surg* 2002; 60:415–421.
- Okuda K, Kawase T, Momose M, et al. Platelet-rich plasma contains high levels of platelet-derived growth factor and transforming growth factor-beta and modulates the proliferation of periodontally related cells in vitro. *J Periodontol* 2003; 74:849–857.
- Kempson RL. Guidelines for handling of most common and important surgical specimens. In: Rosai J, ed. *Ackerman's surgical pathology*. St. Louis, MO: Mosby, 1996:2704.
- Szpaderska AM, Egozi EI, Gamelli RL, DiPietro LA. The effect of thrombocytopenia on dermal wound healing. *J Invest Dermatol* 2003; 120:1130–1137.
- Eppley BL, Pietrzak WS, Blanton M. Platelet-rich plasma: a review of biology and applications in plastic surgery. *Plast Reconstr Surg* 2006; 118:147e–159e.
- Chandra RK, Handorf C, West M, Kruger EA, Jackson S. Histologic effects of autologous platelet gel in skin flap healing. *Arch Facial Plast Surg* 2007; 9:260–263.
- Bashutski JD, Wang HL. Role of platelet-rich plasma in soft tissue root-coverage procedures: a review. *Quintessence Int* 2008; 39:473–483.
- Cheung WS, Griffin TJ. A comparative study of root coverage with connective tissue and platelet concentrate grafts: 8-month results. *J Periodontol* 2004; 75:1678–1687.
- Keceli HG, Sengun D, Berberoğlu A, Karabulut E. Use of platelet gel with connective tissue grafts for root coverage: a randomized-controlled trial. *J Clin Periodontol* 2008; 35:255–262.
- Suaid FF, Carvalho MD, Santamaria MP, et al. Platelet-rich plasma and connective tissue grafts in the treatment of gingival recessions: a histometric study in dogs. *J Periodontol* 2008; 79:888–895.
- Tarnuzzer RW, Schultz GS. Biochemical analysis of acute and chronic wound environments. *Wound Repair Regen* 1996; 4:321–325.
- Steed DL. Modifying the wound healing response with exogenous growth factors. *Clin Plast Surg* 1998; 25:397–405.
- Mazzucco L, Medici D, Serra M, et al. The use of autologous platelet gel to treat difficult-to-heal wounds: a pilot study. *Transfusion* 2004; 44:1013–1018.
- Pietramaggiore G, Scherer SS, Mathews JC, et al. Healing modulation induced by freeze-dried platelet-rich plasma and micronized allogenic dermis in a diabetic wound model. *Wound Repair Regen* 2008; 16:218–225.
- Martínez-Zapata MJ, Martí-Carvajal A, Solà I, et al. Efficacy and safety of the use of autologous plasma rich in platelets for tissue regeneration: a systematic review. *Transfusion* 2009; 49:44–56.

Copyright of Clinical Implant Dentistry & Related Research is the property of Wiley-Blackwell and its content may not be copied or emailed to multiple sites or posted to a listserv without the copyright holder's express written permission. However, users may print, download, or email articles for individual use.