

# A 1-Year Prospective Study on Co-Axis® Implants Immediately Loaded with a Full Ceramic Crown

Stefan Vandeweghe, DDS;\* Jan Cosyn, DDS, MSc, PhD;† Eric Thevissen, DDS, MSc;‡  
Linda Van den Berghe, DDS, MSc, PhD;§ Hugo De Bruyn, DDS, MSc, PhD¶

---

## ABSTRACT

**Introduction:** The Co-Axis® implant (Southern Implants®, Irene, South Africa) has a 12-degree angle in the implant neck to overcome angulation problems.

**Aim:** To examine bone loss, peri-implant health, and aesthetical outcome after 1-year follow-up.

**Materials and Methods:** Fifteen single implants were placed in 14 patients in the premaxilla and immediately loaded with a screw-retained full ceramic crown. Periapical radiographs and standardized photographs were taken to determine bone loss and soft tissue changes. Plaque and bleeding levels were assessed. Patients' satisfaction was measured using the Oral Health Impact Profile-14 questionnaire.

**Results:** After 1 year, all implants survived and mean bone loss was 1.20 mm, with no significant changes after 6 months. Plaque levels were low and no significant changes were observed. Bleeding levels decreased during the initial 3 months, but were constant thereafter. Before final torqueing was performed after 6 months, four cases of screw loosening occurred. Also, one crown had a piece of porcelain chipped off. Patients reported an overall increase in well-being. A mean midfacial recession of 0.37 mm was observed. The mesial papilla showed a slight increase of 0.14 mm, while the distal papilla decreased 0.35 mm.

**Conclusion:** With 100% survival and stable bone levels after 6 months, the Co-Axis implant showed a good clinical outcome when immediately loaded. The use of a full ceramic crown as a first and final restoration resulted in a good aesthetic outcome with few changes in papilla fill, although midfacial soft tissue was stable only after 1 year.

**KEY WORDS:** co-axis, dental implant, immediate loading, implant angulation, prosthetic complication, single implants, soft tissue changes, southern implant

---

## INTRODUCTION

The most important reason for tooth extraction is an endodontic complication, followed by tooth fracture,

trauma, periodontitis, and caries.<sup>1-4</sup> Single tooth replacement using implant therapy has proven to be predictable in short- and long-term studies with respect to implant survival.<sup>4-8</sup> Nevertheless, it is a challenge because the restorations do not rely on the surrounding dentition for support. In this way, it differs from other implant restorations like cross-arches and fixed partial dentures (FPDs) and may hold an increased risk.<sup>9</sup> Additionally, the outcome of single implant crowns depends on the aesthetic demand of the patient and prosthetic features, such as tooth shape, color, translucency, symmetry with the neighboring teeth, and the emergency profile. The latter is predominantly depending on proper implant location whereby the availability of bone and restoratively guided surgical placement are decisive factors. Especially in the aesthetic zone of the maxilla, a correct three-dimensional implant position is essential to enhance the emergency profile determining the natural appearance of the tooth. From a surgical point of view, this implies

---

\*Dentist, PhD student, Department of Periodontology & Oral Implantology, Faculty of Medicine and Health Sciences, University of Ghent, Ghent, Belgium; †periodontist, professor, Department of Periodontology & Oral Implantology, Faculty of Medicine and Health Sciences, University of Ghent, Ghent, Belgium; ‡periodontist, PhD student, Department of Periodontology & Oral Implantology, Faculty of Medicine and Health Sciences, University of Ghent, Ghent, Belgium; §prosthodontist, professor, Department of Periodontology & Oral Implantology, Faculty of Medicine and Health Sciences, University of Ghent, Ghent, Belgium; ¶periodontist, professor, chairman of the department, Department of Periodontology & Oral Implantology, Faculty of Medicine and Health Sciences, University of Ghent, Ghent, Belgium

Reprint requests: Professor Dr Hugo De Bruyn, Department of Periodontology & Oral Implantology, University Hospital of Ghent – P8, De Pintelaan 185, 9000 Ghent, Belgium; e-mail: hugo.debruyne@ugent.be

© 2011 Wiley Periodicals, Inc.

DOI 10.1111/j.1708-8208.2011.00391.x

enough circumferential bone volume to compensate for the peri-implant bone resorption after surgery and a prosthetically correct angulation.<sup>10–13</sup> A perfect prosthetic direction is sometimes impossible because of the morphology of the alveolar crest or the available bone volume. In a recent systematic review, the reduction of the alveolar crest after tooth extraction was calculated as being nearly 4 mm<sup>14</sup>, while only 1.5-mm crestal height reduction occurred. Hence, implants are often palatally positioned, which hampers not only the emergency profile but also phonetics. A buccally oriented implant angulation may be corrected prosthetically by using an individual custom-made abutment.

However, an angulated abutment can sometimes lead to soft tissue recessions due to the large space needed, and frequently involves additional costs. Furthermore, it often limits the possibility to screw-retain the restoration and consequently means the crown has to be cemented. This increases the risk for cement residues and may affect the peri-implant bone loss and implant survival.

To handle the aforementioned angulation problems, a novel implant design has been introduced (Co-Axis®, Southern Implants, Irene, South Africa). This allows a prosthetic anchorage in a 12-degree deviation from the implant axis. The angulation is located within the implant neck and does not interfere with the design of the suprastructure. Hence, a normal screw-retained prosthetic reconstruction using normal cylinder components on fixture level is possible.

Today, the need to replace a missing maxillary tooth as quickly as possible with a fixed appliance has a high priority for most patients. On the other hand, immediate loading of a single implant in the maxilla may expose the implant to an additional risk because of the lower bone quality and the nonaxially loading directions of a nonconnected implant.<sup>15</sup> Most studies, although predominantly with a rather short follow-up, report good results when loading single implants immediately after surgery.<sup>15–19</sup> The temporary crown can either be screw-retained on the implant or cemented on the final abutment. The use of a final abutment from the day of surgery has advantages: soft tissue healing is uneventful, it causes less disturbance of the peri-implant mucosa, and it may by itself prevent additional bone loss.<sup>20</sup> Immediate loading with a final crown not only offers the patient a shorter treatment time but also includes less treatment procedures

and a lower treatment cost by excluding the temporary restoration.<sup>19,21,22</sup>

The goal of this prospective study is to describe the clinical survival, implant success, peri-implant health, prosthetic outcome, aesthetics, and patient opinion of Co-Axis implants installed in healed bone and immediately functionally loaded with a final screw-retained ceramic crown.

## MATERIALS AND METHODS

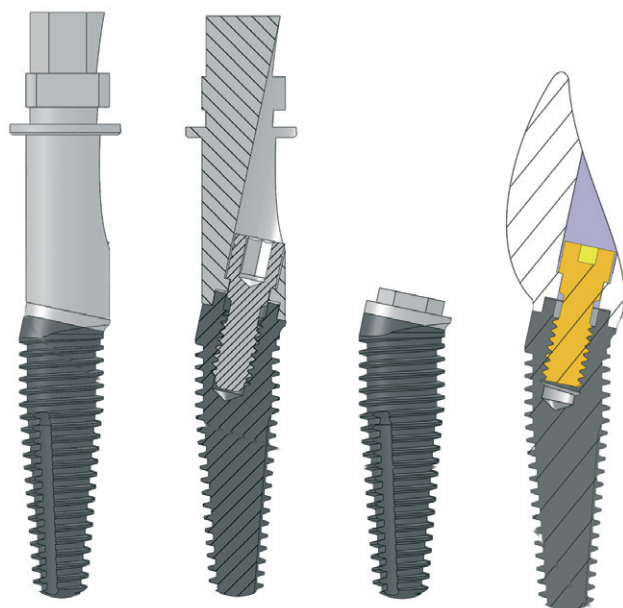
### Patient Selection

A total of 15 single implant cases were selected from the patients referred to the Department for Periodontology and Oral Implantology of the University Hospital in Ghent, Belgium. They had to be in good general health and treated for caries and periodontal disease, if present. Only implant sites with at least 2 months of healing were included. In addition, the single tooth gap was neighbored by two natural teeth in the premaxillary region (15–25). Bone dehiscences present after implant installation and requiring regenerative procedures, as well as insufficient primary implant stability (< 35 Ncm) requiring a two-stage approach, were excluded. All patients were selected by one examiner (SV), after a full mouth clinical and radiographical evaluation. The latter was based on standard periapical and/or panoramic radiographs. All subjects received detailed information on the study and signed a written consent according to the protocol approved by the Ethical Committee of the University Hospital (B67020072593).

### Implant Surgery and Restorative Procedure

All implants used in this study were Co-Axis Ø 4-mm or Ø 5-mm implants with a 12-degree angle between the prosthetic screw and the implant axis; they are tapered and have a sandblasted and acid-etched titanium surface with a turned 0.8-mm titanium collar and a thread pitch of 0.6 mm. Details of the implant design are depicted in Figure 1.

All implant surgeries were performed by the same experienced periodontist (ET). Following local anesthesia (Scandonest 2% Special, Septodont, Niederkassel, Germany), patients rinsed with a 0.2% chlorhexidine solution for 1 minute (Corsodyl, GlaxoSmithKline, London, United Kingdom). Sulcular incisions were made around the neighboring teeth and connected by a crestal incision (Figure 2). A full thickness flap was elevated to expose the bone. The preparation of the



**Figure 1** Example of the 12 degrees Co-Axis implant with the fixture mount connected, without the fixture mount, and with a crown.

implant bed was performed as described by the manufacturer. The drilling procedure consisted of consecutive drilling with a round bur to perforate the cortical bone, followed by a 2-mm parallel twist drill at full depth in the desired direction. A 12-degree direction indicator was used to control the implant direction with respect to the desired prosthetic position. For the 4-mm Co-Axis implant, a 4-mm tapered twist drill was used as final drill. For the 5-mm Co-Axis implant, an additional 5-mm tapered drill was used. All implants were installed at the level of the alveolar crest, and attention was paid to have the restorative screw angle correct. After implant positioning, the fixture mount was removed and replaced by an impression coping. A sterile rubber dam was placed around the impression coping to prevent leakage of impression material into the surgical site (Figure 3). An open tray impression was made using polyether impression material (Impregum, 3 M ESPE, St. Paul, MN, USA). Thereupon, a 4-mm healing abutment was placed and the flap was closed using resorbable sutures (Vicryl 4.0, Johnson&Johnson, New Brunswick, NJ, USA).

After surgery, the patient received analgesics (Ibuprofen 600 mg, three times a day) and instructions for oral hygiene and wound care. This included gentle brushing (TePe surgical, Malmö, Sweden) and chlorhexidine rinsing (Corsodyl 0.12%, GlaxoSmithKline) for 1 week.

Immediately after surgery, the impression was sent to the dental technician for fabrication of the crown. These were full ceramic crowns of porcelain fused to a prefabricated zirconium cylinder (CER-ZR45, Southern Implants®, Irene, South Africa). As it was a bone-level impression, the technician was instructed to position the contact points within 5 mm from the crest to allow a good papilla fill.<sup>13</sup> To enhance a proper mucosal attachment, the cervical 2 mm of the zirconium cylinder was left uncovered with porcelain<sup>23,24</sup> (Figure 3).

Within 24 hours after surgery, the patient returned for placement of the fixture level screw-retained crown. The crown was hand tightened onto the implant and adjusted for occlusion and articulation whenever required. The crowns were in full occlusion but care was taken to avoid contact during protrusion and excursion movements. After polishing, screw access holes were closed with a temporary filling material (Cavit, 3 M ESPE, St. Paul, MN, USA).

### Examined Parameters

*Peri-implant bone loss* radiographs were made using an x-ray holder and with the x-ray beam perpendicular to the film. After digitalizing the x-rays, bone loss was measured using DBSWIN 4.0 software (Dürr, Bietigheim-Bissingen, Germany), with the implant thread as a reference for calibration. For each implant, the mean bone loss was calculated from the mesial and distal values. Bone loss was evaluated from baseline (1 day after surgery) to 1, 2, 4, 6 weeks and 3, 6, 12 months, and calibrated on the thread pitch

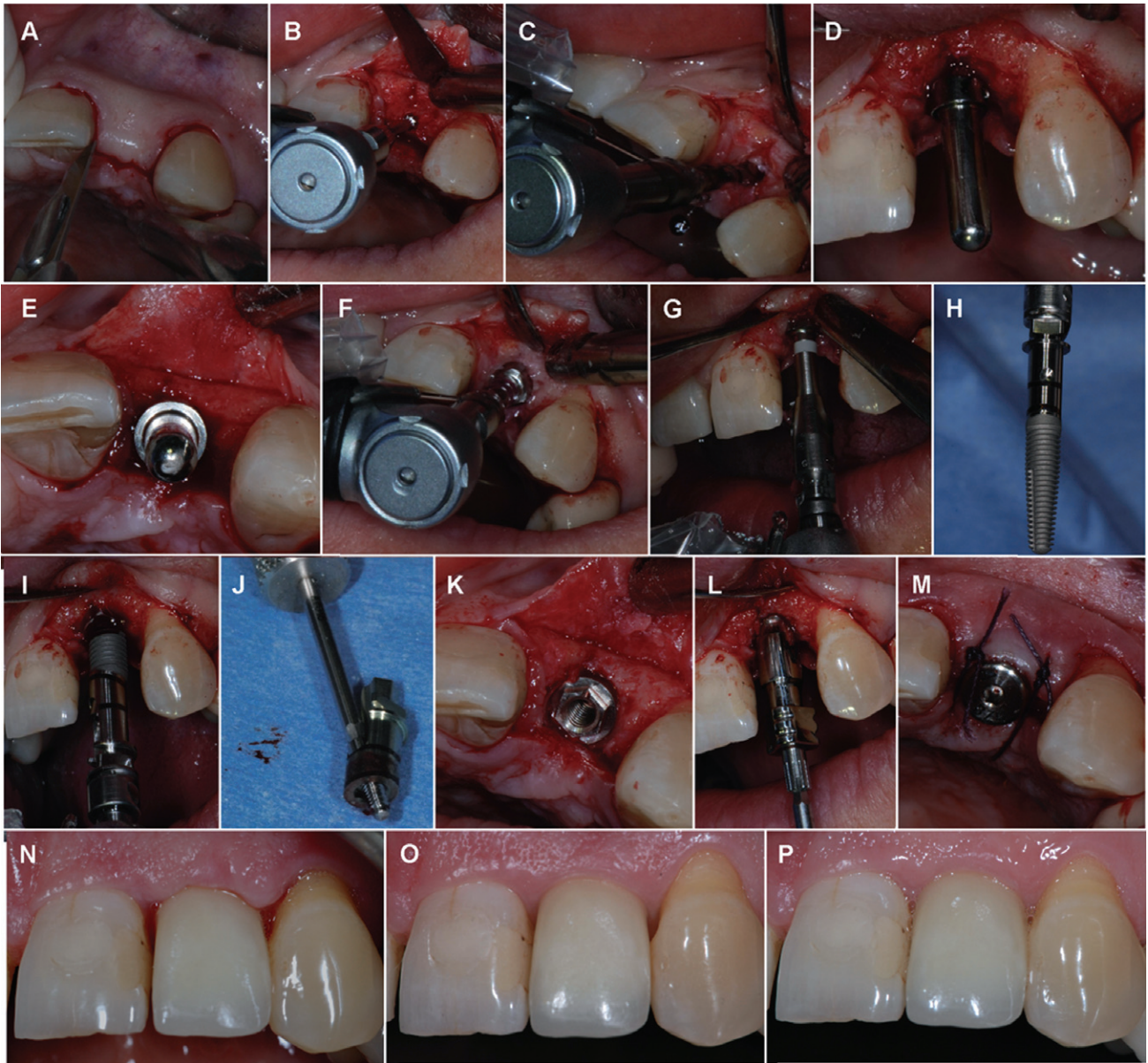
*Implant survival* – an implant was a survival if it was still in situ and successfully clinically osseointegrated with no signs of mobility, pain, or purulence at 1-year follow-up.

*Implant success* – based on the criteria by Albrektsson and Isidor<sup>25</sup> allowing 1.5-mm bone loss during the first year.

*Plaque and bleeding* – were assessed according to the modified plaque and bleeding index by Mombelli and colleagues<sup>26</sup> by running a probe across the gingival margin.

*Soft tissue changes* – were measured on clinical photographs by means of a computer assisted morphometry program (Figure 4). The procedure was standardized in terms of patient and camera positioning. An individualized bite-fork (Futar D, Kettenbach/Artex) was used to

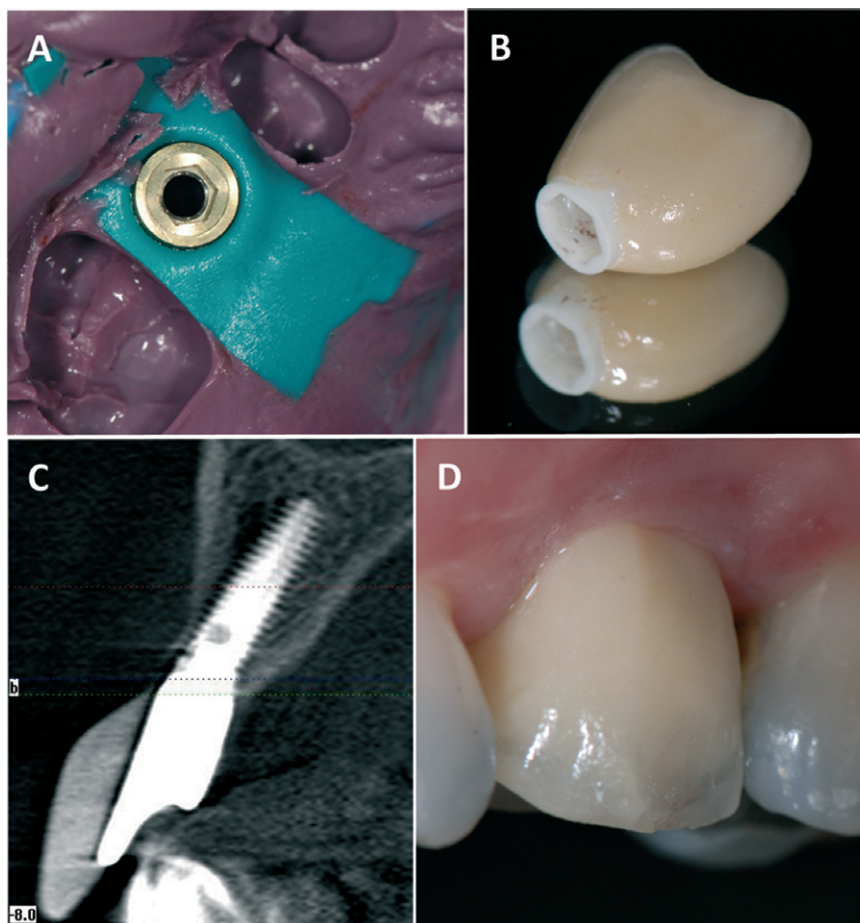




**Figure 2** Surgical and restorative procedure. (A) Sulcular and crestal incisions were made to elevate the flap. (B) A round drill was used to perforate the cortical bone. (C) The 2.0-mm twist drill was aimed on the incisal edge to correct for the 12-degree angle. (D,E) A 12-degree direction indicator was used to verify the correct inclination of the implant bed. (F) A first tapered twist drill followed by the second and final tapered twist drill (G) were used to create the implant bed. (H) The implant is a 13-mm diameter 4 Co-Axis® implant. (I,J) The implant mount corrects for the angulation and has a marker on the highest side to indicate the angle. (K) The implants are positioned equal with the crest. (L) An open tray impression coping was attached and a bone-level impression was made. (M) After implant impression, a healing abutment was placed, and the flap was sutured using Vicryl 4/0. The day after surgery, the full ceramic crown was screwed on the implant, and patients were asked to return regularly for follow-up. A soft tissue maturation was seen over time, e.g., after 2 weeks (N), 6 months (O) and 1 year (P).

position the patient in a reproducible manner in relation to the camera, which was in a fixed position. Morphometric analyses were done using Gingival Status 2009 v1.0.0.2 (Inspector BV, Baarn, The Netherlands). Pictures were calibrated, and three lines starting from a chosen reference point were used to measure the mesial and distal papilla and zenith. Changes over time were used for analyses.

*Patient satisfaction* – was measured using the Dutch version of the Oral Health Impact Profile (OHIP-14) questionnaire, a shortened version of the OHIP-49 questionnaire.<sup>27</sup> This questionnaire captures seven conceptually formulated dimensions in 14 questions that are based on Locker's theoretical model of oral health.<sup>28</sup> Two questions per domain reflect on functional limitation, physical disability, physical pain, psychological



**Figure 3** (A) Implant impression was taken using a sterile rubber dam to avoid contact with the bone. (B) The crown consisted out of a zirconium hexed cylinder, with porcelain on top. As can be seen in figure (C), this sometimes results in a large mass of unsupported porcelain, which may lead to porcelain chipping (D), as one patient experienced.

disability, psychological discomfort, social disability, and handicap. The questions are answered on a scale from 1 to 5. Five was defined as the maximal positive result indicative of total absence of problems; 1 corresponds to maximal negative answer or always a problem. Answers: 1 = “very often”; 2 = “fairly often”; 3 = “occasionally”; 4 = “hardly ever”; and 5 = “never”.

*Aesthetic outcome* – the aesthetic outcome was assessed using the pink esthetic score by Furhauser and colleagues<sup>33</sup> and the white esthetic score by Belser and colleagues.<sup>9</sup>

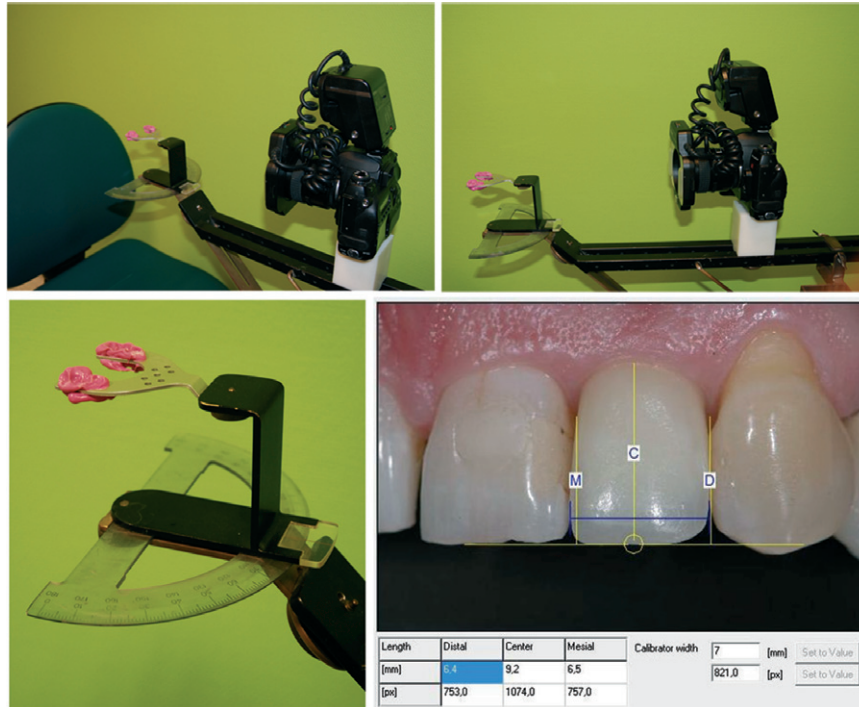
*Complications* were divided into biological complications (implant mobility, mucositis, fistula) or technical complications (porcelain chipping, screw loosening or fracture).

### Follow-Up Intervals

All patients were invited for reassessment at 1, 2, 4, 6 weeks and 3, 6, 12 months after surgery. During

these sessions, a periapical radiograph was taken to evaluate the interproximal bone level. Also, standardized clinical pictures were taken to evaluate soft tissue changes. Plaque and bleeding levels were scored after 1 week (= baseline), 3, 6, and 12 months.<sup>26</sup> The implant and crown were checked for signs of biological and/or technical complications. During the 6-month recall session, the patients were given the option to replace or modify the crown when aesthetically necessary. If not, the crown was secured at 32 Ncm, and the screw access hole was filled with cotton and composite (Herculite®, Kerr, Bioggio, Switzerland). During all sessions, oral hygiene was reinforced whenever necessary. One week prior to and 6 months after surgery, patients were asked to fill in the OHIP-14 questionnaire to rate their satisfaction. Finally, at the 1-year reassessment, the aesthetic outcome was scored using the pink esthetic score<sup>29</sup> and white esthetic score.<sup>30</sup>





**Figure 4** Photometric analyses of the soft tissue changes. The patient is positioned in front of the camera in a reproducible manner by biting into an individualized bite-fork. The camera has a fixed position, while the gradient can be adjusted by rotating the patient as to allow the photograph to be taken perpendicular to the implant crown. The angle on the protractor is registered for each patient to be able to put the patient in the same position every time. The morphometric analysis was done using computer software. Three lines perpendicular to a reference line are used to measure mesial (M) and distal (D) papilla, and the midfacial (C). Another line (in blue) was used to calibrate the photograph, based on the mesio-distal width of the crown as measured into the mouth.

## Statistical Analysis

The changes over time resulting in actual bone loss data from the time of implant placement were used for statistical analysis and examined by the Friedman test. If the Friedman test revealed an overall significant  $p$  value, time points were compared two-by-two using the Wilcoxon signed ranks test. The clinical data (plaque index, bleeding index, soft tissue changes) and OHIP-14 scores were examined likewise. The impact of the implant diameter and length on bone loss was evaluated using the Kruskal–Wallis test. If this test revealed an overall significant influence, pairwise Mann–Whitney tests were performed.

Intraexaminer repeatability and interexaminer reproducibility on study cast measurements and digital analyses were assessed using proportional agreement, Pearson correlation coefficients, and Wilcoxon signed ranks tests.

$p \leq .05$  was considered statistically significant.

## RESULTS

Fifteen single implants were installed in 14 patients (six male, eight female) with a mean age of 55 years (SD: 13,

range 31–80). The main reason for tooth loss was caries ( $n = 6$ ), followed by fractures of the root or crown ( $n = 3$ ), and periodontal disease ( $n = 2$ ). In four cases, the tooth was already lost for many years for unknown reason. Four implants were in lateral incisor position, one in cuspid position, and ten in premolar position.

Implants were 4 or 5 mm in diameter and 10, 13, or 15 mm in length (Table 1). All 15 implants survived at the 1-year examination.

There was no patient dropout at any of the scheduled recalls, as each and every patient participated in all parts of the investigation.

**TABLE 1** Overview of Implants according to Their Length and Diameter

	Implant Length			Total
	10 mm	13 mm	15 mm	
Implant diameter				
4 mm	3	6	2	11
5 mm	1	2	1	4
Total	4	8	3	15

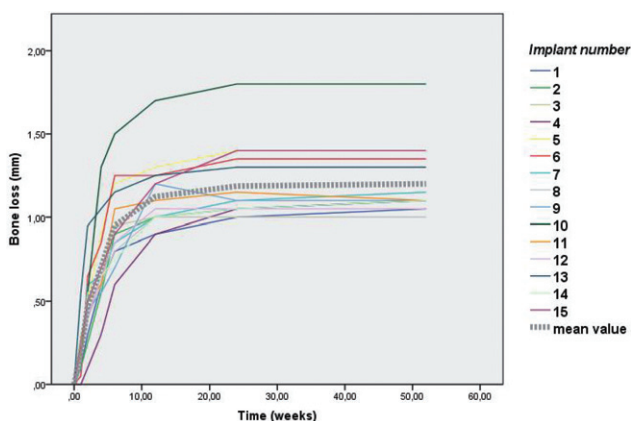
**TABLE 2 Overview of Mean and Median Bone Loss at Different Time Points, with the Corresponding Standard Deviation (SD), Range and *p* Values (Compared to Previous Interval)**

Time after Surgery	Mean	Median	SD	Range	<i>p</i> Value
1 week	0.19 mm	0.20	0.129	0.00–0.55	0.001*
2 weeks	0.47 mm	0.50	0.194	0.10–0.95	0.001*
4 weeks	0.70 mm	0.50	0.239	0.30–1.30	0.001*
6 weeks	0.95 mm	0.90	0.239	0.60–1.50	0.001*
3 months	1.12 mm	1.05	0.205	0.90–1.70	0.001*
6 months	1.19 mm	1.10	0.224	1.00–1.80	0.008*
12 months	1.20 mm	1.10	0.215	1.00–1.80	0.052

\*Statistically significant difference at 0.05 level.

## Bone Loss and Success

The mean peri-implant bone loss calculated from the day of surgery to 1 year was 1.20 mm (SD: 0.22, range 1.00–1.80). The intraexaminer repeatability on bone levels was high (95% agreement within 0.2 mm deviation; Pearson correlation coefficient: 0.923 –  $p < .001$ ; Wilcoxon signed ranks test:  $p = .114$ ), as was the interexaminer reproducibility (95% agreement within 0.2 mm deviation; Pearson correlation coefficient: 0.930 –  $p < .001$ ; Wilcoxon signed ranks test:  $p = .404$ ). No statistically significant changes in bone loss were observed after the first 6 months ( $p = .052$ ) (Table 2). Bone level changes at all intervals of all 15 implants are shown in Figure 5. According to the success criteria of Albrektsson and Isidor,<sup>4</sup> 14/15 implants were successful and demonstrated less than 1.5-mm bone loss after 1 year. Bone loss was independent of implant diameter ( $p = .112$ ) or length ( $p = .540$ ).



**Figure 5** Bone loss changes over time for all implants and the overall mean bone loss.

## Plaque and Bleeding

Plaque and bleeding are summarized in Table 3. No significant differences in the distribution of plaque levels were seen between the different time intervals ( $p = .757$ ). Significant differences in bleeding levels were observed ( $p < .001$ ), with a significant decrease in bleeding between 1 week and 3 months ( $p = .001$ ). After 3 months up to 1 year, no additional changes were observed ( $p = 1.000$ ).

## Complications

All complications were of technical nature, the most frequent being screw loosening. This occurred in four cases, all during the initial 6 months before the prosthetic screws were torqued at 32 Ncm.

One premolar crown had a piece of porcelain chipped off shortly before the 1-year control but was still in full occlusal load. A new crown was made for aesthetic reasons.

## Soft Tissue

A mean midfacial recession of 0.37 mm (SD: 0.93, range –0.60–1.00) was observed from the time of crown placement until 1 year post-op (Table 4). The intraexaminer repeatability on was high (93.3% agreement within 0.2 mm deviation; Pearson correlation coefficient: 0.985 –  $p < .001$ ; Wilcoxon signed ranks test:  $p = .720$ ), as was the interexaminer reproducibility (86.6% agreement within 0.2 mm deviation; Pearson correlation coefficient: 0.998 –  $p < .001$ ; Wilcoxon signed ranks test:  $p = .457$ ). Significant changes occurred between all intervals ( $p = .002$ ). The mesial papilla showed no

**TABLE 3** Frequency Distribution of Plaque and Bleeding Levels

Plaque levels	0 = No detection of plaque				
	1 = Plaque only recognized by running a probe				
	2 = Plaque can be seen by the naked eye				
	3 = Abundance of soft matter				
	Time	0	1	2	3
	1 week	12	3	0	0
	3 months	12	3	0	0
	6 months	14	1	0	0
Bleeding levels	1 year				
	13				
	2				
	0				
	0				
	0 = No bleeding				
	1 = Isolated bleeding spots visible.				
	2 = Blood forms a confluent red line on margin.				
	3 = Heavy or profuse bleeding				
	Time	0	1	2	3
	1 week	1	6	8	0
	3 months	15	0	0	0
	6 months	15	0	0	0
	1 year	15	0	0	0

significant differences in height ( $p = .467$ ), but the distal papilla showed some decrease in height over time ( $p = .023$ ).

#### OHIP-14 Patient Satisfaction

Based on the OHIP-14 questionnaire, there was a statistically significant overall improvement in satisfaction and well-being between the presurgical and 6 months postoperative condition ( $p = .002$ ) (Figure 6). More precisely, there was a significant improvement in speaking (Question 1:  $p = .020$ ), a reduction in pain (Question 3:  $p = .011$ ), eating comfort improved

(Question 4:  $p = .016$ ), patients felt less tensed (Question 5:  $p = .016$ ), could relax easier (Question 9:  $p = .026$ ), and were less embarrassed (Question 10:  $p = .026$ ).

#### Aesthetic Outcome

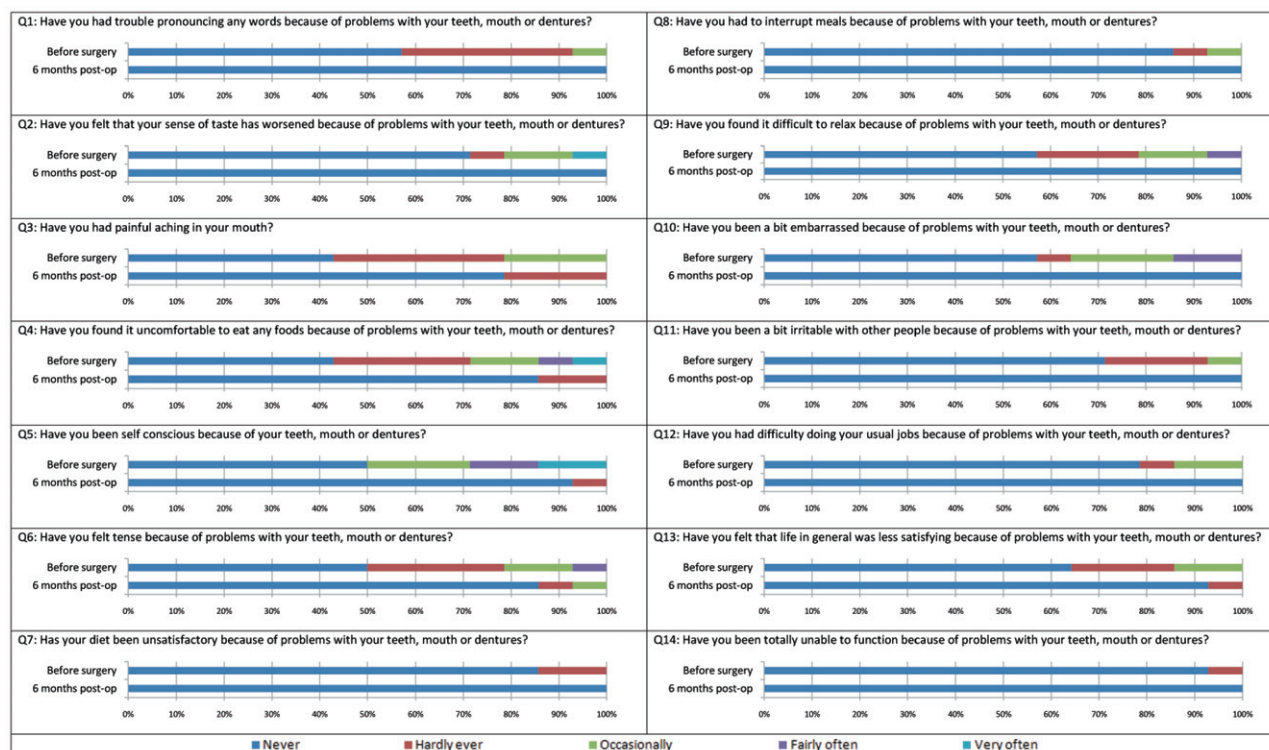
An overview of pink and white esthetic score can be seen in Table 5. After 1 year, the mean pink esthetic score was 8.53 (SD: 1.25, range 6–10), with 12/15 implants having at least the minimum clinical acceptable score of 8/14. The mean white esthetic score was 6.53 (SD: 1.46, range 4–9), with 10/15 having at least 6/10.

**TABLE 4** Soft Tissue Changes

	Time from Baseline	Soft Tissue Recession from Baseline	Standard Deviation, Range	$p$ Value from Baseline	$p$ Value within Time Intervals
Midfacial	3 months	0.30	SD 0.37, Range –0.50–0.80	0.012*	0.351 0.041*
	6 months	0.31	SD 0.42, Range –0.70–0.90	0.020*	
	1 year	0.37	SD 0.39, Range –0.60–1.00	0.007*	
Mesial Papilla	3 months	0.07	SD 0.72, Range –1.30–1.20	0.826	0.379 0.068
	6 months	–0.19	SD 0.98, Range –2.20–1.30	0.495	
	1 year	–0.14	SD 0.96, Range –2.10–1.30	0.670	
Distal Papilla	3 months	0.54	SD 1.09, Range –1.10–3.90	0.044*	0.247 0.482
	6 months	0.44	SD 1.20, Range –1.00–4.10	0.146	
	1 year	0.35	SD 0.93, Range –1.00–2.90	0.111	

\*Significant at 0.05 level, Wilcoxon Test.





**Figure 6** Values of OHIP-14 scores before surgery and 6 months after surgery and crown placement.

## DISCUSSION

The original two-stage healing protocol was intended to avoid micromovements, hereby essentially avoiding fibrous tissue encapsulation and failure.<sup>31</sup> Today, studies have proven that micromotions of 50 to 150  $\mu$  do not

negatively influence the osseointegration process and even may stimulate the healing process, resulting in a larger bone-to-implant contact.<sup>32,33</sup> Therefore, osseointegration can even occur when implants are loaded immediately.<sup>34–36</sup>

In the present study, all implants survived. Although the number of implants was limited, this fall within the range of 79–100% obtained by immediate functional loading of single implants.<sup>37–42</sup>

Most studies comparing immediate and delayed loading showed no significant differences in survival rate,<sup>43–45</sup> provided that primary stability was achieved.<sup>46,47</sup> Ottoni and colleagues<sup>48</sup> found that implant survival depends on insertion torque and recommended torque values of 32 Ncm.

The fact that the crowns were put into full occlusal contact did not negatively affect implant survival. This is in agreement with Lindeboom and colleagues<sup>18</sup> who compared the outcome of immediate functional and nonfunctional loading and found no significant differences. They suggested that the influence of tongue pressure, perioral musculature, and patient habits cannot be controlled for and may expose the implant to additional stress irrespective of direct contact or functional loading.

**TABLE 5** Pink and White Esthetic Score

	Major Discrepancy (Score 0)	Slight Discrepancy (Score 1)	Identical (Score 2)
<b>Pink Esthetic Score</b>			
Mesial papilla	5	9	1
Distal papilla	7	7	1
Midfacial level	1	7	7
Midfacial contour	1	6	8
Alveolar process	0	11	4
Soft tissue color	0	6	9
Soft tissue texture	1	6	8
<b>White Esthetic Score</b>			
Tooth form	1	13	1
Tooth Volume	1	11	3
Tooth color	1	7	7
Tooth texture	0	6	9
Translucency	1	7	7

A recent meta-analysis<sup>49</sup> shows an increased risk for implant failure when single implants are loaded immediately. This was not found in our study, although number of implants was very limited.

Good clinical outcomes with tilted implants were already reported by Malo and colleagues<sup>50</sup> using the all-on-four concept. The bone loss pattern in the latter did not differ significantly from axially loaded implants. This was also confirmed by Koutouzis and colleagues<sup>51</sup> in a 5-year follow-up study comparing tilted and straight implants. In the present study, the angulated position from the implant did not seem to have an adverse effect on the implant survival and success. As the angulation is subcrestally at the level of the implant neck, this correction does not interfere with the soft tissue contouring nor hampers the prosthetic design. As zirconia abutments are more prone to fracture, the implant allows the use of a straight zirconia abutment and therefore improves the strength of the crown.<sup>52</sup>

The amount of peri-implant bone loss after 1 year was 1.20 mm and is comparable with similar studies on immediate loading of single implants. Hall and colleagues<sup>45</sup> reported 0.63-mm bone loss for the first year, while Ottoni and colleagues<sup>48</sup> reported 1.36 mesially and 2.44 distally after the first year. Both studies also compared with a control group of delayed loaded implants and found no significant differences. In the present study, significant bone loss was observed up to 6 months after surgery, where after, the bone level stabilized. This was confirmed by earlier studies reporting a steady state after 6 months.<sup>53–55</sup>

Based on the success criteria by Albrektsson and Isidor,<sup>25</sup> 14/15 implants could be considered successful in this study. Although the number of cases was limited, this demonstrates the good success rate that can be obtained by immediate loading with single implants. Hall and colleagues<sup>45</sup> reported a survival rate of 92.3%, with one implant losing more bone than acceptable. Degidi and colleagues<sup>56</sup> reported an implant success of 97.2% after 5 years. Obviously, these data may differ depending on the definition of implant success.

The microbial film, correlated with the presence of plaque, is an etiologic factor for implant diseases and may induce bone loss.<sup>57</sup> Therefore, the presence of plaque can be a predictor for disease and for planning intervention.<sup>58</sup> All patients in the current study showed very low plaque levels during the period of the study. However, one should keep in mind that a Hawthorne

effect could have been present, possibly influencing oral hygiene habits.<sup>59</sup> Bleeding levels were also very low, though the importance of this variable is questionable. A longitudinal study showed weak correlation between gingival bleeding index and peri-implant bone loss.<sup>60</sup> Also, Lekholm and colleagues<sup>61</sup> found no correlation between bleeding-on-probing and histology, microbiology and radiographic changes, while others claim bleeding as an important indicator for disease.<sup>62,63</sup>

Technical complications occurred, most of them related to the loosening of the prosthetic gold screw, which was also reported by Lindeboom and colleagues.<sup>18</sup> This was due to the fact that the crowns were initially tightened manually in order to remove the crown if necessary (e.g., if recession occurred and the patient requested a new crown). Out of the 14 patients, 13 were satisfied with the overall result and only one patient requested crown replacement after porcelain chipping occurred. Nevertheless, the use of a torque driver to tighten the prosthetic screws at crown placement is mandatory to prevent screw loosening.<sup>64</sup> In addition, one should keep in mind that 1-year follow-up is rather short, and longer follow-up is needed to make a proper conclusion regarding the occurrence and nature of complications.

Although a massive amount of research on implant dentistry is available, only an estimated 2% reports patient's centered outcome.<sup>65</sup> The majority involves fully edentulous patients, who are known to profit significantly from dental implants.<sup>66,67</sup> Only very few single implant studies also have evaluated patient satisfaction. With a significant overall improvement and an increase in satisfaction for six questions, this study demonstrates clearly that even the rehabilitation of a single tooth can significantly improve patient's quality of life. Patients did not feel the loss of a tooth as a handicap or a social or physical disability. The present study indicates that placement of an implant-supported single crown improves the oral health-related quality of life, which is in agreement with Berretin-Felix and colleagues<sup>68</sup> and Jokstad.<sup>69</sup>

Most clinical studies focus on implant survival and success. The patient, however, is more concerned about the aesthetic result. Therefore, the use of a standardized index to score the appearance of the implant-supported tooth may be important to validate or reject certain treatment protocols. Fürhauser and colleagues<sup>29</sup> created an index to validate soft tissue aesthetics around single

implants. This protocol was later modified by Belser and colleagues<sup>30</sup> who added a comparable crown index. Their clinical study on early placed implants resulted in an overall score of 14.7/20, a pink esthetic score of 7.8/10, and a white esthetic score of 6.9/10.<sup>30</sup> Although these results seem better than those from the current study, one should keep in mind that most of our patients had a history of periodontitis, resulting in decreased bone volume, recession, and reduced or absent papilla at the start of the study. When soft tissue changes were measured, only small changes were observed. The mesial papilla showed a slight increase of 0.14 mm in height after 1 year, while the distal papilla showed a small recession of 0.35 mm. Kan and colleagues<sup>22</sup> reported recessions of the mesial and distal papillae of respectively 0.53 mm and 0.39 mm after 1 year when implants were immediately placed and loaded. De Rouck and colleagues<sup>70</sup> reported midfacial soft tissue recession and mesial/distal papilla shrinkage of 0.53, 0.41, and 0.31 mm, respectively. Donati and colleagues<sup>71</sup> found recessions of 0.43 mm for the mesial and 0.21 mm for the distal papilla. The mean midfacial recession of 0.37 mm was less than the 0.55 mm reported by Kan and colleagues,<sup>22</sup> but, although very small changes occurred after the initial 3 months, these were still statistically significant. Therefore, clinicians should be careful regarding the timing of abutment placement and the abutment design. The position of abutment margin should be positioned enough subgingivally, and pressure should be avoided once the soft tissues have stabilized.

## CONCLUSION

In the current study, the Co-Axis implant performed very well under immediate functional loading in the premaxilla, with no failures and stable bone remodeling after 1 year. The angulated implant neck eliminates most of the angulation problems, allowing the practitioner the maximal choice in implant prosthetics. The use of a full ceramic crown as the first and only restoration reduced the number of treatments, gave the patients an immediate result, and reduced the total costs. Patients did not require replacement of the “provisionals” for aesthetical purposes.

## ACKNOWLEDGMENT

Stefan Vandeweghe received a grant from Southern Implants® to conduct this study. The company provided all materials for the study.

## REFERENCES

1. Andersson B, Odman P, Carlsson GE. A study of 184 consecutive patients referred for single-tooth replacement. *Clin Oral Implants Res* 1995; 6:232–237.
2. Brägger U, Krenander P, Lang NP. Economic aspects of single-tooth replacement. *Clin Oral Implants Res* 2005; 16:335–341.
3. Mericske-Stern R, Grutter L, Rosch R, Mericske E. Clinical evaluation and prosthetic complications of single tooth replacements by non-submerged implants. *Clin Oral Implants Res* 2001; 12:309–318.
4. Priest G. Single-tooth implants and their role in preserving remaining teeth: a 10-year survival study. *Int J Oral Maxillofac Implants* 1999; 14:181–188.
5. Buser D, Mericske-Stern R, Bernard JP, et al. Long-term evaluation of non-submerged ITI implants. Part 1: 8-year life table analysis of a prospective multi-center study with 2359 implants. *Clin Oral Implants Res* 1997; 8:161–172.
6. Jemt T. Single implants in the anterior maxilla after 15 years of follow-up: comparison with central implants in the edentulous maxilla. *Int J Prosthodont* 2008; 21:400–408.
7. Jemt T. Cemented CeraOne and porcelain fused to TiAdapt abutment single-implant crown restorations: a 10-year comparative follow-up study. *Clin Implant Dent Relat Res* 2009; 11:303–310.
8. Wennstrom JL, Ekestubbe A, Grondahl K, Karlsson S, Lindhe J. Implant-supported single-tooth restorations: a 5-year prospective study. *J Clin Periodontol* 2005; 32:567–574.
9. Mayer TM, Hawley CE, Gunsolley JC, Feldman S. The single-tooth implant: a viable alternative for single-tooth replacement. *J Periodontol* 2002; 73:687–693.
10. Buser D, Martin W, Belser UC. Optimizing esthetics for implant restorations in the anterior maxilla: anatomic and surgical considerations. *Int J Oral Maxillofac Implants* 2004; 19 (Suppl 7):43–61.
11. Hermann JS, Buser D, Schenk RK, Schoolfield JD, Cochran DL. Biologic Width around one- and two-piece titanium implants. *Clin Oral Implants Res* 2001; 12:559–571.
12. Tarnow DP, Cho SC, Wallace SS. The effect of inter-implant distance on the height of inter-implant bone crest. *J Periodontol* 2000; 71:546–549.
13. Tarnow DP, Wagner AW, Fletcher P. The effect of the distance from the contact point to the crest of bone on the presence or absence of the interproximal dental papilla. *J Periodontol* 1992; 63:995–996.
14. Van der Weijden F, Dell’Acqua F, Slot DE. Alveolar bone dimensional changes of post-extraction sockets in humans: a systematic review. *J Clin Periodontol* 2009; 36:1048–1058.
15. Andersen E, Haanaes HR, Knutsen BM. Immediate loading of single-tooth ITI implants in the anterior maxilla: a prospective 5-year pilot study. *Clin Oral Implants Res* 2002; 13:281–287.



16. Drago CJ, Lazzara RJ. Immediate provisional restoration of Osseotite implants: a clinical report of 18-month results. *Int J Oral Maxillofac Implants* 2004; 19:534–541.
17. Glauser R, Sennerby L, Meredith N, et al. Resonance frequency analysis of implants subjected to immediate or early functional occlusal loading. Successful vs. failing implants. *Clin Oral Implants Res* 2004; 15:428–434.
18. Lindeboom JA, Frenken JW, Dubois L, Frank M, Abbink I, Kroon FH. Immediate loading versus immediate provisionalization of maxillary single-tooth replacements: a prospective randomized study with BioComp implants. *J Oral Maxillofac Surg* 2006; 64:936–942.
19. Norton MR. A short-term clinical evaluation of immediately restored maxillary TiOblast single-tooth implants. *Int J Oral Maxillofac Implants* 2004; 19:274–281.
20. Abrahamsson I, Berglundh T, Lindhe J. The mucosal barrier following abutment dis/reconnection. An experimental study in dogs. *J Clin Periodontol* 1997; 24:568–572.
21. Atieh MA, Payne AG, Duncan WJ, Cullinan MP. Immediate restoration/loading of immediately placed single implants: is it an effective bimodal approach? *Clin Oral Implants Res* 2009; 20:645–659.
22. Kan JY, Rungcharassaeng K, Lozada J. Immediate placement and provisionalization of maxillary anterior single implants: 1-year prospective study. *Int J Oral Maxillofac Implants* 2003; 18:31–39.
23. Abrahamsson I, Berglundh T, Glantz PO, Lindhe J. The mucosal attachment at different abutments. An experimental study in dogs. *J Clin Periodontol* 1998; 25:721–727.
24. Rompen E, Domken O, Degidi M, Pontes AE, Piattelli A. The effect of material characteristics, of surface topography and of implant components and connections on soft tissue integration: a literature review. *Clin Oral Implants Res* 2006; 17(Suppl 2):55–67.
25. Albrektsson T, Isidor F. Consensus report of session IV. London: Quintessence, 1993.
26. Mombelli A, van Oosten MA, Schurch E Jr, Land NP. The microbiota associated with successful or failing osseointegrated titanium implants. *Oral Microbiol Immunol* 1987; 2:145–151.
27. Slade GD. Derivation and validation of a short-form oral health impact profile. *Community Dent Oral Epidemiol* 1997; 25:284–290.
28. Locker D. Measuring oral health: a conceptual framework. *Community Dent Health* 1988; 5:3–18.
29. Furhauser R, Florescu D, Benesch T, Haas R, Mailath G, Watzek G. Evaluation of soft tissue around single-tooth implant crowns: the pink esthetic score. *Clin Oral Implants Res* 2005; 16:639–644.
30. Belser UC, Grutter L, Vailati F, Bornstein MM, Weber HP, Buser D. Outcome evaluation of early placed maxillary anterior single-tooth implants using objective esthetic criteria: a cross-sectional, retrospective study in 45 patients with a 2- to 4-year follow-up using pink and white esthetic scores. *J Periodontol* 2009; 80:140–151.
31. Branemark PI, Hansson BO, Adell R, et al. Osseointegrated implants in the treatment of the edentulous jaw. Experience from a 10-year period. *Scand J Plast Reconstr Surg Suppl* 1977; 16:1–132.
32. Piattelli A, Corigliano M, Scarano A, Costigliola G, Paolantonio M. Immediate loading of titanium plasma-sprayed implants: an histologic analysis in monkeys. *J Periodontol* 1998; 69:321–327.
33. Szmukler-Moncler S, Piattelli A, Favero GA, Dubrulle JH. Considerations preliminary to the application of early and immediate loading protocols in dental implantology. *Clin Oral Implants Res* 2000; 11:12–25.
34. Cooper LF, Rahman A, Moriarty J, Chaffee N, Sacco D. Immediate mandibular rehabilitation with endosseous implants: simultaneous extraction, implant placement, and loading. *Int J Oral Maxillofac Implants* 2002; 17:517–525.
35. Ibanez JC, Jalbout ZN. Immediate loading of osseotite implants: two-year results. *Implant Dent* 2002; 11:128–136.
36. Tarnow DP, Emtiaz S, Classi A. Immediate loading of threaded implants at stage 1 surgery in edentulous arches: ten consecutive case reports with 1- to 5-year data. *Int J Oral Maxillofac Implants* 1997; 12:319–324.
37. Calandriello R, Tomatis M, Rangert B. Immediate functional loading of Branemark System implants with enhanced initial stability: a prospective 1- to 2-year clinical and radiographic study. *Clin Implant Dent Relat Res* 2003; 5(Suppl 1):10–20.
38. Calandriello R, Tomatis M, Vallone R, Rangert B, Gottlow J. Immediate occlusal loading of single lower molars using Branemark System Wide-Platform TiUnite implants: an interim report of a prospective open-ended clinical multicenter study. *Clin Implant Dent Relat Res* 2003; 5(Suppl 1):74–80.
39. Chaushu G, Chaushu S, Tzohar A, Dayan D. Immediate loading of single-tooth implants: immediate versus non-immediate implantation. A clinical report. *Int J Oral Maxillofac Implants* 2001; 16:267–272.
40. Cornelini R, Cangini F, Covani U, Barone A, Buser D. Immediate restoration of single-tooth implants in mandibular molar sites: a 12-month preliminary report. *Int J Oral Maxillofac Implants* 2004; 19:855–860.
41. Glauser R, Ree A, Lundgren A, Gottlow J, Hammerle CH, Scharer P. Immediate occlusal loading of Branemark implants applied in various jawbone regions: a prospective, 1-year clinical study. *Clin Implant Dent Relat Res* 2001; 3:204–213.
42. Rocci A, Martignoni M, Gottlow J. Immediate loading in the maxilla using flapless surgery, implants placed in predetermined positions, and prefabricated provisional restorations: a retrospective 3-year clinical study. *Clin Implant Dent Relat Res* 2003; 5(Suppl 1):29–36.
43. Degidi M, Piattelli A, Carinci F. Parallel screw cylinder implants: comparative analysis between immediate loading

- and two-stage healing of 1,005 dental implants with a 2-year follow up. *Clin Implant Dent Relat Res* 2006; 8:151–160.
44. Ericsson I, Nilson H, Lindh T, Nilner K, Randow K. Immediate functional loading of Branemark single tooth implants. An 18 months' clinical pilot follow-up study. *Clin Oral Implants Res* 2000; 11:26–33.
  45. Hall JA, Payne AG, Purton DG, Torr B, Duncan WJ, De Silva RK. Immediately restored, single-tapered implants in the anterior maxilla: prosthodontic and aesthetic outcomes after 1 years. *Clin Implant Dent Relat Res* 2007; 9:34–45.
  46. Randow K, Ericsson I, Nilner K, Petersson A, Glantz PO. Immediate functional loading of Branemark dental implants. An 18-month clinical follow-up study. *Clin Oral Implants Res* 1999; 10:8–15.
  47. Schnitman PA, Wohrle PS, Rubenstein JE, DaSilva JD, Wang NH. Ten-year results for Branemark implants immediately loaded with fixed prostheses at implant placement. *Int J Oral Maxillofac Implants* 1997; 12:495–503.
  48. Ottoni JM, Oliveira ZF, Mansini R, Cabral AM. Correlation between placement torque and survival of single-tooth implants. *Int J Oral Maxillofac Implants* 2005; 20:769–776.
  49. Atieh MA, Atieh AH, Payne AG, Duncan WJ. Immediate loading with single implant crowns: a systematic review and meta-analysis. *Int J Prosthodont* 2009; 22:378–387.
  50. Agliardi E, Panigatti S, Clerico M, Villa C, Malo P. Immediate rehabilitation of the edentulous jaws with full fixed prostheses supported by four implants: interim results of a single cohort prospective study. *Clin Oral Implants Res* 2010; 21:459–465.
  51. Koutouzis T, Wennstrom JL. Bone level changes at axial- and non-axial-positioned implants supporting fixed partial dentures. A 5-year retrospective longitudinal study. *Clin Oral Implants Res* 2007; 18:585–590.
  52. Nothdurft FP, Doppler KE, Erdelt KJ, Knauber AW, Pospiech PR. Fracture behavior of straight or angulated zirconia implant abutments supporting anterior single crowns. *Clin Oral Investig* 2011; 15:157–163.
  53. Berglundh T, Abrahamsson I, Lindhe J. Bone reactions to longstanding functional load at implants: an experimental study in dogs. *J Clin Periodontol* 2005; 32:925–932.
  54. Collaert B, De Bruyn H. Immediate functional loading of TiOblast dental implants in full-arch edentulous maxillae: a 3-year prospective study. *Clin Oral Implants Res* 2008; 19:1254–1260.
  55. Cooper L, Felton DA, Kugelberg CF, et al. A multicenter 12-month evaluation of single-tooth implants restored 3 weeks after 1-stage surgery. *Int J Oral Maxillofac Implants* 2001; 16:182–192.
  56. Degidi M, Piattelli A, Gehrke P, Felice P, Carinci F. Five-year outcome of 111 immediate nonfunctional single restorations. *J Oral Implantol* 2006; 32:277–285.
  57. Lindquist LW, Rockler B, Carlsson GE. Bone resorption around fixtures in edentulous patients treated with mandibular fixed tissue-integrated prostheses. *J Prosthet Dent* 1988; 59:59–63.
  58. Salvi GE, Lang NP. Diagnostic parameters for monitoring peri-implant conditions. *Int J Oral Maxillofac Implants* 2004; 19(Suppl 7):116–127.
  59. Ulmer FC. The Hawthorne effect. *Educ Dir Dent Aux* 1976; 1:28.
  60. Chaytor DV, Zarb GA, Schmitt A, Lewis DW. The longitudinal effectiveness of osseointegrated dental implants. The Toronto Study: bone level changes. *Int J Periodontics Restorative Dent* 1991; 11:112–125.
  61. Lekholm U, Ericsson I, Adell R, Slots J. The condition of the soft tissues at tooth and fixture abutments supporting fixed bridges. A microbiological and histological study. *J Clin Periodontol* 1986; 13:558–562.
  62. Jepsen S, Ruhling A, Jepsen K, Ohlenbusch B, Albers HK. Progressive peri-implantitis. Incidence and prediction of peri-implant attachment loss. *Clin Oral Implants Res* 1996; 7:133–142.
  63. Lang NP, Wetzel AC, Stich H, Caffesse RG. Histologic probe penetration in healthy and inflamed peri-implant tissues. *Clin Oral Implants Res* 1994; 5:191–201.
  64. Cho SC, Small PN, Elian N, Tarnow D. Screw loosening for standard and wide diameter implants in partially edentulous cases: 3- to 7-year longitudinal data. *Implant Dent* 2004; 13:245–250.
  65. Pjetursson BE, Karoussis I, Burgin W, Bragger U, Lang NP. Patients' satisfaction following implant therapy. A 10-year prospective cohort study. *Clin Oral Implants Res* 2005; 16:185–193.
  66. de Bruyn H, Collaert B, Linden U, Bjorn AL. Patient's opinion and treatment outcome of fixed rehabilitation on Branemark implants. A 3-year follow-up study in private dental practices. *Clin Oral Implants Res* 1997; 8:265–271.
  67. Dierens M, Collaert B, Deschepper E, Browaeys H, Klinge B, De Bruyn H. Patient-centered outcome of immediately loaded implants in the rehabilitation of fully edentulous jaws. *Clin Oral Implants Res* 2009; 20:1070–1077.
  68. Berretin-Felix G, Nary Filho H, Padovani CR, Machado WM. A longitudinal study of quality of life of elderly with mandibular implant-supported fixed prostheses. *Clin Oral Implants Res* 2008; 19:704–708.
  69. Jokstad A. Implant retained or conventional dentures, which give more patients satisfaction? *Evid Based Dent* 2006; 7:96–97.
  70. De Rouck T, Collys K, Cosyn J. Immediate single-tooth implants in the anterior maxilla: a 1-year case cohort study on hard and soft tissue response. *J Clin Periodontol* 2008; 35:649–657.
  71. Donati M, La Scala V, Billi M, Di Dino B, Torrisi P, Berglundh T. Immediate functional loading of implants in single tooth replacement: a prospective clinical multicenter study. *Clin Oral Implants Res* 2008; 19:740–748.

Copyright of Clinical Implant Dentistry & Related Research is the property of Wiley-Blackwell and its content may not be copied or emailed to multiple sites or posted to a listserv without the copyright holder's express written permission. However, users may print, download, or email articles for individual use.