

Clinical Evaluation of Split-Crest Technique with Ultrasonic Bone Surgery for Narrow Ridge Expansion: Status of Soft and Hard Tissues and Implant Success

Eduardo Anitua, MS, DDS, PhD;* Leire Begoña, MSc;† Gorka Orive, PhD†

ABSTRACT

Purpose: The aim of this study was to evaluate the split-crest technique with ultrasonic bone surgery for implant placement in patients with narrow ridges, focusing on the status of soft and hard tissues and on implant success rate, at least 6 months after implant loading.

Materials and Methods: During September 2007 and November 2008, 15 patients received 37 implants (BTI implants) with split-crest surgical procedure using ultrasonic bone surgery. Plasma rich in growth factors (PRGF®) was applied during split crest procedure to promote tissue regeneration. Implant surfaces were humidified with PRGF to accelerate osseointegration. Patients were recalled for a final clinical evaluation at least 6 months after implant loading. Clinical assessment included the status of soft and hard tissues around implants, and implants' success rate.

Results: Thirty-seven implants in 15 patients were evaluated between July 2009 and January 2010. The status of soft tissues was very good, showing adequate plaque index, bleeding index, and probing depth values. Success rate of implants at the end of follow-up (between 11 and 28 months after insertion) was 100%. Bone ridge was measured and compared at final examination showing a mean ridge expansion of 3.35 mm (SD: 0.34).

Conclusions: Split-crest with ultrasonic bone surgery can be considered an effective and safe procedure for narrow ridge expansion.

KEY WORDS: bone ridge expansion, dental implants, hard tissues, implant success, piezoelectric surgery, PRGF, soft tissues, split-crest, ultrasonic bone surgery

*Private practice in implantology and oral rehabilitation in Vitoria, Spain; †Biotechnology Institute, Vitoria, Spain

Clinical relevance

Scientific rationale for study: Split-crest technique with ultrasonic bone surgery is a relatively new technique that shows clinical advantages over other procedures for ridge expansion. The present work is one of the fewest in the literature evaluating this technique.

Principal findings: The statuses of soft tissues, bone expansion level, and implant success rate at least 6 months after implant loading were successful using this procedure.

Practical implications: The data presented herein may contribute to provide clinical data on the efficacy and predictability of split-crest technique with ultrasonic bone-surgery in patients with narrow bone ridges.

Source of funding and conflict of interest

The study was self-funded by the authors and their institution. This study was financially supported by Biotechnology Institute (BTI), the manufacturer of the implant system used in this study. Dr. Orive and L.B. are employed by BTI. Dr. Anitua is scientific director of BTI.

INTRODUCTION

In the last few decades, the rehabilitation of maxillary and mandibular edentulous areas with dental implants has become common practice, with reliable long-term results.¹ In some situations, there is a lack of supporting bone as a result of atrophy, trauma, or surgical resection. As dental implants can only be placed if there is sufficient bone to adequately stabilize them, bone

Reprint requests: Dr. Eduardo Anitua, Instituto Eduardo Anitua; c/ Jose Maria Cagigal 19, 10005 Vitoria, Spain; e-mail: eduardoanitua@eduardoanitua.com

© 2011 Wiley Periodicals, Inc.

DOI 10.1111/j.1708-8208.2011.00340.x

augmentation procedures represent an effective treatment option for these patients. In the horizontal dimension, to achieve an adequate osseointegration and a good treatment outcome, the presence of at least 1 mm in width around the implant bone crest at the buccal and palatal plane is required.² In patients with long-standing edentulous arches, extreme bone resorptions (both vertically and horizontally) or combined defects are frequently presented. This fact leads inevitably to the use of additional techniques for augmentation of the local bone volume, including: osteoinduction, by the use of appropriate growth factors; osteoconduction, where a grafting material serves as a scaffold for new bone formation¹; distraction osteogenesis, by which a fracture is surgically induced and the two bone fragments are then slowly pulled apart; guided bone regeneration, which allows spaces maintained by barrier membranes to be filled with bone; revascularized bone grafts, where a vital bone segment is transferred; and techniques for crest expansion using bone expanders or osteotomes, or with the technique called "split-crest" performed with an ultrasound device or with conventional surgery.³⁻⁵

The "split-crest" technique consists of splitting the vestibular and buccal cortical,^{3,6} displacing the vestibular cortical bone both in maxillary or mandible and separating from the bone marrow, and creating a middle gap, which is usually occupied mostly by the inserted implants. The unoccupied space by the implants can be filled with biomaterials such as autologous bone grafts, particulate bone, or plasma derivatives as platelet-rich plasma.⁷ Classic ridge-split procedures involve razor-sharp bone chisels and rotating or oscillating saws. The use of bone chisel traumatizes and could stress the patient with annoying shocks during surgery. Rotating and oscillating instruments are time effective and less stressing for the patient, but present important limitations associated with the risk of encroaching the gingival, the lips or the tongue, limiting their accessibility and complicating the procedure.⁸

The use of ultrasonic bone surgery for osteotomy represents an advantageous alternative technique over conventional surgery using disks and chisels. The use of ultrasound devices for medical diagnosis was first investigated in the 1940s and 1950s, and became well established in the 1960s. Ultrasonic osteotomy preparation was studied following earlier works,^{9,10} but it is only in the last few years that ultrasonic devices for osteotomy

have become competitive with conventional instruments in certain contexts.¹¹⁻¹⁵

Ultrasound device consists of mechanical waves of frequencies greater than about 20 kHz, the upper limit of human hearing. Although vibrations of these frequencies can be produced by various means, most medical devices currently use the piezoelectric effect, discovered in 1880 by Jacques and Pierre Curie.¹⁶ Ultrasonic devices have the ability to cut mineralized hard tissues as teeth or bone in a very safe and precise way, with minor tissue damage.^{17,18} Soft tissues such as nerves, blood vessels, or the schneiderian membrane are not altered by the cutting tip because of their ability to oscillate at the same speed and amplitude as the cutting tip.¹⁹ Moreover, surgical accuracy is facilitated by good visibility in the surgical field.²⁰ Ultrasonic cuts have been reported also to be more precise and to cause less splintering at the margin of the incision. Last but not least, the ultrasonic osteotome allows curved cuts that are impossible with rotator or oscillating saws.²⁰

Few clinical studies have evaluated the clinical use of ultrasonic bone surgery in split expansion technique,^{8,21} with satisfactory results in most cases. The purpose of this study was to evaluate the use of the split-crest technique with ultrasonic device for dental implants insertion in patients with narrow bone ridges, focusing on the status of the soft and hard tissues surrounding the implants, and the success of inserted implants elapsed a time of at least 6 months after implant loading.

MATERIALS AND METHODS

The protocol followed national and international (International Conference on Harmonisation rules) policies on clinical studies. This study had a retrospective cohort design. Patient selection was based on the absence of any local or systemic diseases that might contraindicate the treatment. The clinical histories of all patients were carefully evaluated in order to obtain the necessary information on demographic anthropometric data and the clinical backgrounds of patients. Selected patients were recalled for a final clinical evaluation in an elapsed time of at least 6 months after implant loading.

The selection criteria of patients included patients of both genders, over 18 years, initial insufficiently bony ridge for implant placement, submitted to ridge expansion technique using ultrasonic device (split technique) for subsequent insertion of dental implants, and whose

implants were loaded at least 6 months before. Patients who underwent split into two phases were not included in the study.

Preinsertion Protocol and Medication

In all patients, the same protocol for surgery and implant insertion was followed. Subjects received oral hygiene treatment and instructions during the days prior to the intervention. Antibiotics (1 g of amoxicillin and 1 g of acetaminophen) were prescribed to each patient for 6 days, starting 30 minutes before implant installation. If necessary, one tablet of midazolam 7.5 mg was administered 20 minutes before the intervention to promote patient relaxation and facilitate his/her collaboration.

At the time prior to the intervention, 1-minute rinses with chlorhexidine digluconate 0.20% were recommended. Lips and perioral area were also cleaned with chlorhexidine. An infiltrative anesthesia (articaine 40 mg/mL and epinephrine 0.01 mg/mL) was applied to all patients from vestibular, lingual, or palatine. After the surgery, patients were encouraged to take, in case of pain, acetaminophen (1 g/8 hours) or ibuprofen (600 mg/8 hours). If the pain persisted, patients were also advised to come to the site for observation.

Ultrasonic Bone Surgery Device and SPLIT Surgical Technique Procedure

The split surgical technique procedure was made using the piezo-surgery device (BTI-Ultrasonic®, BTI Biotechnology Institute S.L., Vitoria, Spain). The latter allows operating between 25,000 and 35,000 cycles per second, with a new model handpiece that minimizes heat because of the design of the piezoelectric device.

The split surgical procedure involved the opening of a full thickness flap, after which a scaling with the ultrasonic spoon around the bone bed was performed with the aim of stimulating bone bleeding and thus facilitating the subsequent apposition of grafts on the bone surface. The starting drill was used to localize the sites where future implants will be placed. With the use of ultrasonic flat chisel, a side-to-side cut in the osseous crest was performed to connect the holes previously created (Figure 1A). At that point, the expansion was begun, using the different motorized expanders (BTI Biotechnology Institute S.L.) (Figure 1B). The expansion was continued by means of the necessary drills (BTI Biotechnology Institute S.L.), depending on bone width

and the type of implant to be placed. In the study, the drilling sequence was 1.8, 1.8 to 2.5, 2.5, and exceptionally 3-mm drills. Then, implants were placed (Figure 1C and D) and the “gap” on the ridge was overcorrected with autologous bone. Autologous bone was obtained from a low-speed drilling procedure.²² Additionally, porous bovine inorganic bone graft mixed with plasma rich in growth factors (PRGF) were also used to overcorrect (Figure 1E). Closure was made without tension (Figure 1F).

Implant Insertion

Two experienced surgeons following an adequate treatment plan performed all implant installations, and rehabilitations were carried out by three prosthodontists. The latter included careful evaluation of the patient's clinical history, a complete radiological evaluation (conventional x-ray and the BTI Scan® program), the elaboration of surgery guides, and the preparation of provisional and final prostheses adapted to each patient. All implants were installed without irrigation, using a low-speed drilling procedure (50–100 rpm).²² Before installation, all implants were carefully embedded in liquid PRGF® with the aim of bioactivating the implant surface.^{7,23,24} PRGF was prepared in 9-mL citrated tubes (BTI Biotechnology Institute S.L.) from patient's blood, by centrifugation at 580× g for 8 minutes at room temperature. The milliliter fraction just located above the sedimented red cells, but not including the buffy coat, was collected.²⁵ In general, healing was allowed for a minimum of 3 months, after which the surgical abutments were fixed. Shortly thereafter, the suprastructure was placed.

Clinical Assessments

Prior to the intervention, patients' general health and dental status were assessed. Once the intervention was conducted, patients were referred to a series of periodic evaluations, consisting normally in: one evaluation 2 to 3 days after intervention, at 1 month, at 3 months, at 6 months, and from this moment ahead, once a year.

A computed axial tomography scan (SCT) was carried out to patients before the intervention to assess bone quality and quantity, to quantify the ridge height and width of the supporting bone, and to locate major anatomical features. All these evidences will help the clinician to make a detailed study using specialized software (BTI Scan program) in implant surgery planning.

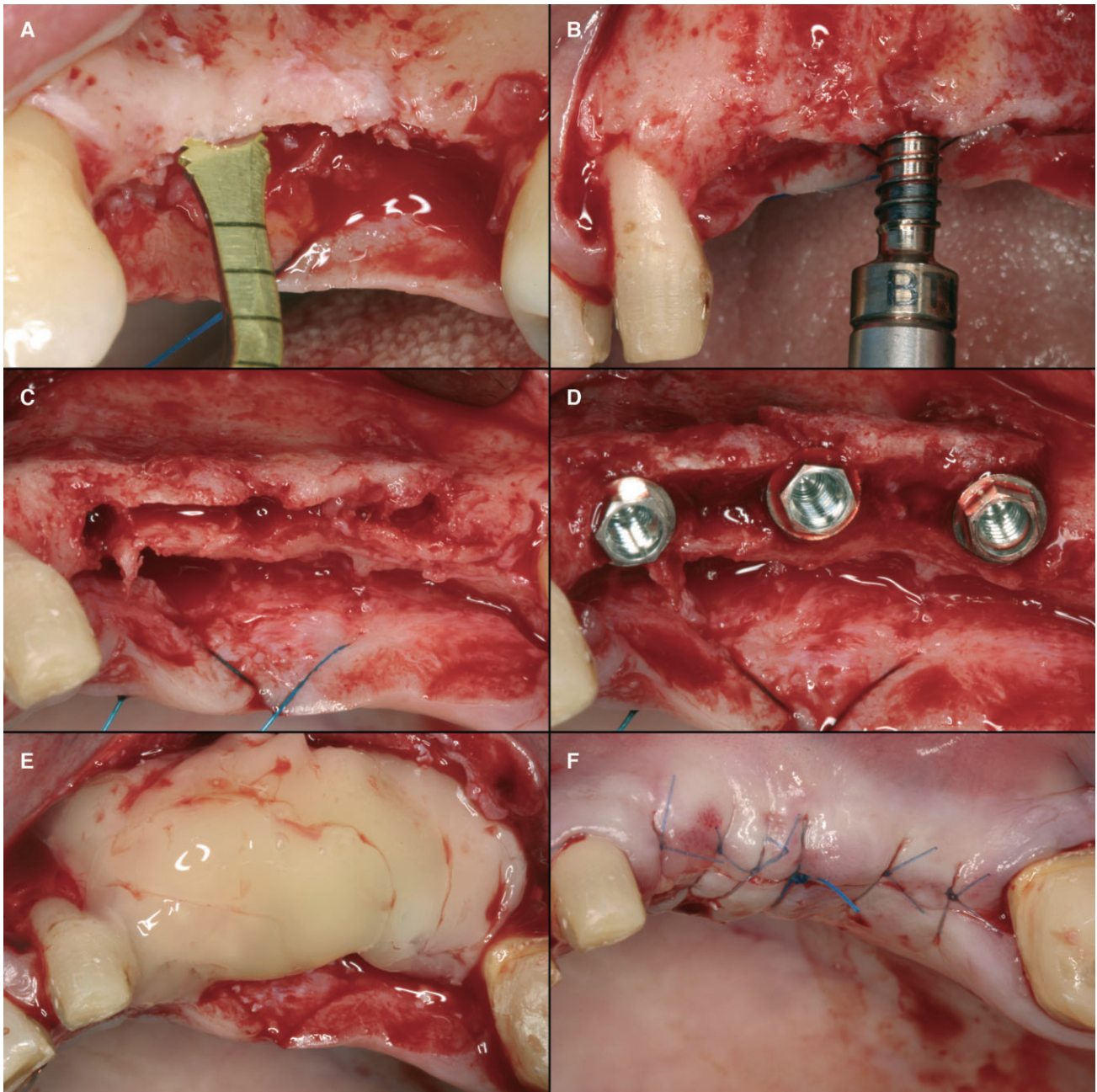


Figure 1 Description of the split-crest technique with ultrasonic bone surgery for narrow ridge expansion. (A) After using the starting drill, the ultrasonic flat chisel was employed to perform a side-to-side cut in the osseous crest in order to connect the holes previously created. (B) The expansion was begun using the different motorized expanders and continued by means of the necessary drills. (C,D) Implants were placed and the “gap” on the ridge was overcorrected with autologous bone. (E) Porous bovine inorganic bone graft mixed with plasma rich in growth factors were also used to overcorrect. (F) Closure was made without tension.

Just after the intervention, a panoramic radiograph was taken to verify the adequate placement of the implants. After intervention, periodic panoramic radiographs were carried out to evaluate the appropriate state of the implants in the follow-up period. Radiographies were repeated normally at least once a year.

Several items were used for data analysis. These variables include demographic items, clinical items, surgery-dependent items, and prosthetic variables:

- Patient age in years at surgery
- Gender

- Smoking habits (smoking ≥ 1 cigarette per day was classified as a smoker)
- Previous periodontal disease (Yes/No)
- Bruxism (Yes/No)
- Diabetes mellitus (Yes/No)
- Previous head–neck radiation (Yes/No)
- Maxilla pathology (Yes/No)
- Implant length–diameter
- Implant anatomical location
- Maxilla/Mandible
- Surgical phases (One/Two)
- Immediate loading (Yes/No)
- Immediate postextraction (Yes/No)
- Bone grafting (Yes/No)
- Prostheses (unitary/bridge/complete and cemented/screwed)

Final Evaluation

At least 6 months after loading of implants, patients were recalled in for final clinical evaluation. Between July 2009 and January 2010, 15 patients attended the final evaluation, which included the following clinical assessments:

- Smoke habits (cigarettes/day)
- Dental hygiene habits (number of brushings per day, use of dental floss, interdental brushes, mouthwash use)
- Implant status according to the following success criteria²⁶: (a) the implant does not cause any allergic reaction, toxic, or infectious local or systemic; (b) the implant offers support for a functional prosthesis; (c) the implant shows no signs of fracture or bend; (d) the implant shows no mobility when it is scanned manually or electronically; (e) the implant shows no signs of radiolucency with an intraoral radiograph; (f) the marginal bone loss (Rx intraoral) and/or attachment loss (probing depth + recession) should not impair the function of anchoring the implant or cause discomfort to the patient for 20 years
- Status of the soft tissue around each implant: (a) plaque index²⁷; (b) bleeding index²⁸; (c) probing depth (PD): measured at four sites per implant (mesial, distal, vestibular, lingual); and (d) suppuration (Yes/No)
- Status of bone tissue: Scanner and measuring of bone expansion achieved in comparison with the

scanner before surgery. The measurement of the width of the bony ridge for each implant was made at two points: one in the basal part of the crest and in a middle zone located at 8 mm from the first measurement

Statistical Analyses

Data collection and analysis were performed by two independent examiners (other than restorative dentists). Descriptive statistics considered the implant and the patient as a unit of analysis. Absolute and relative frequency distributions were calculated for qualitative variables and mean values and standard deviations for quantitative variables. Implant survival rate was calculated using a Kaplan–Meier analysis. SPSS v15.0 for Windows statistical software package (SPSS Inc., Chicago, IL, USA) was used.

RESULTS

A total of 20 patients were eligible for the study and were called for final clinical assessment. Two patients refused to come and an additional one did not attend the visit. In two patients, the implants were not loaded at the time of the visit, so they were not included in the study. Therefore, 15 patients receiving a total of 37 implants were finally included in the clinical study. BTI implants were inserted between September 2007 and November 2008 using the surgical technique for bone ridge expansion, with ultrasonic device called “Split-crest.” All implants were loaded between December 2007 and May 2009. The final evaluations were conducted between July 2009 and January 2010.

The mean age of the 15 patients at surgery was 53.67 years (SD: 12.25, range 19–72 years). All of them were females. Only one of the patients was a smoker (6.7%). Eight patients (53.3%) had previous periodontal disease, and one of them (6.7%) had bruxism. None of the patients had maxilla pathology or previous head–neck radiation.

The distribution of diameters and lengths of the inserted implants are described in Table 1. Regarding implant position, 28 implants were inserted in the upper jaw (75.6%), whereas nine were inserted in the lower jaw (24.3%). Figure 2 shows the anatomic distribution of the 37 inserted implants.

Considering the surgical approach, only one implant was installed using a one-stage surgery (2.7%), and the remaining implants (97.3%) followed a

TABLE 1 Characteristics of the Inserted Implants

		Diameter (mm)					Total
		2.50	3.00	3.30	3.50	3.75	
Length (mm)	8.5	0	1	0	2	0	3
	10.0	0	5	1	1	1	8
	11.5	0	1	2	0	0	3
	13.0	1	15	2	2	0	20
	15.0	0	1	1	1	0	3
Total		1	23	6	6	1	37

two-stage surgery approach. None of the implants followed either immediate postextraction approach or immediate loading. In all the cases except in one implant, bone grafting was used (97.3%). Rehabilitations included 28 bridges (75.7%), six complete dentures (16.2%), and three unitary prostheses (8.1%). Use of cemented prostheses was predominant (64.9%) and the remaining 13 prostheses were screwed (35.1%).

The mean follow-up period for the patients elapsed between insertion time and final examination was 16.73 months (SD: 4.03) (range, 11–28 months). In the case of the implants, the mean follow-up period elapsed between insertion time and final examination was 17.5 months (SD: 4.19) (range, 11–28 months). Table 2

shows pooled data from follow-up times of patients and implants. The mean time elapsed between the loading of the implants and the final evaluation was 11.46 months (SD: 3.59, range 6–25 months).

Regarding the data collected at the final patient evaluation, three patients referred some smoke habits at examination time (20%). Regarding hygienic habits, 14 out of 15 patients (93.3%) referred two to three brushings per day, 12 used dental floss (80%), eight used interdental brushes, and eight used a mouth rinse product at the examination moment. Regarding the assessment of the status of the soft tissues surrounding implants, most patients showed low rates of plaque index (97.3% of them showed values ≤ 2) and low values of bleeding index (94.6% of them showed values ≤ 1). Furthermore, none had drainage at the time of final assessment. In the assessment of the probing pocket depth measured in four sites of the implants, the mean value observed was 2.59 (SD: 0.69). All the data regarding soft tissues assessment is summarized in Tables 3 and 4.

Bone ridge width was measured and compared between baseline and final SCT of the patients. The initial mean bone ridge width was 4.29 mm (SD: 0.16, range 1.80–6.20 mm, median 4.20 mm), whereas the final measurement after split-crest technique was 7.63 mm (SD: 0.32, range 4.80–11.40 mm, median

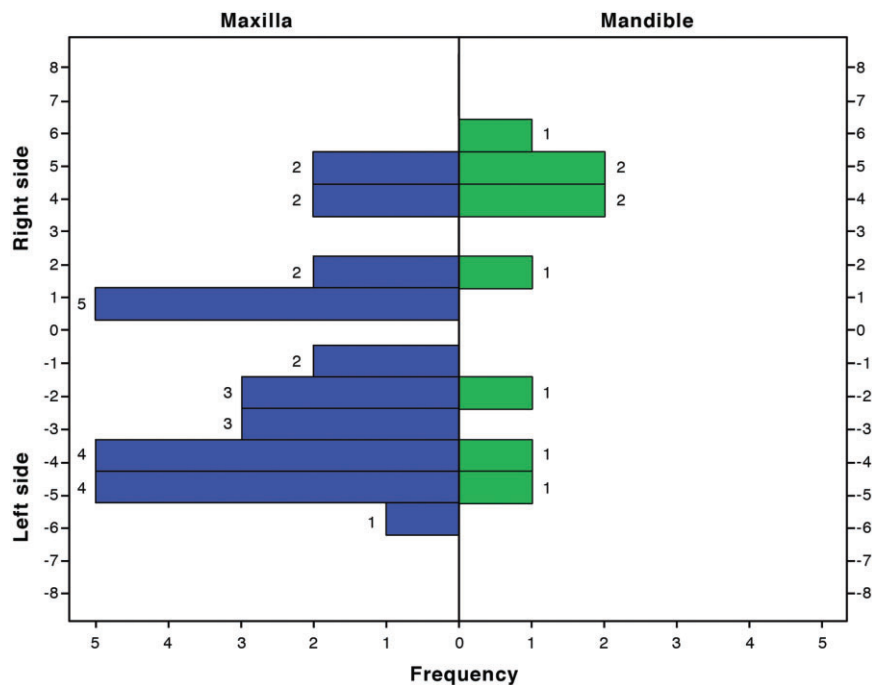


Figure 2 Anatomic distribution of the 37 inserted implants.

TABLE 2 Follow-Up Months of Patients and Implants

Follow-Up (Months)	Patients			Implants		
	<i>n</i>	%	Cumulative %	<i>n</i>	%	Cumulative %
11 to 18	11	73.3	73.3	26	70.3	70.3
>18 to 24	3	20.0	93.3	8	21.6	91.9
>24 to 28	1	6.7	100.0	3	8.1	100.0
Total	15	100.0		37	100.0	

6.90 mm) (Figure 3). Therefore, the mean expansion for the 37 inserted implants was 3.35 mm (SD: 0.34). When bone expansion was analyzed according to the initial ridge width, it was found that mean bone expansion for ridges ≥ 4 mm was 2.93 mm (SD: 0.42) while the expansion obtained for ridges < 4 mm reached 3.95 mm (SD: 0.56) (Figure 3).

Interestingly, no implants failed during the observation period, and all of them met the defined success criteria, showing a 100% success rate at the end of the follow-up period. Finally, Figure 4 shows the clinical situation of one patient involved in the study before and after split-crest technique and implant placement.

DISCUSSION

The results observed in this study support the use of ultrasonic bone surgery in split-crest technique for adequate implant placement in patients with narrow

bone ridges. Because implants evaluated herein had been loaded for at least 6 months and time elapsed since implant insertion was more than 11 months, the state of the implants (no implant failures) and the status of surrounding soft and hard tissues are indicative of the safety and effectiveness of the approach.

At the end of the evaluation period, patients showed generally good oral hygiene habits and the state of the soft tissue around the implants were very good. In fact, plaque index of 0 or 1 was observed in 69.2% of patients, bleeding index between 0 and 1 in 94.9% of patients, and no signs of suppuration were detected in the implants. Probing depth showed good values at all points of exploration, with a mean PD value in the four points of 2.61 mm. Using the split-crest approach described herein, a mean bone gain of 3.35 mm was obtained. Interestingly, for ridges ≥ 4 mm, the expansion obtained was close to 3 mm, whereas for ridges < 4 mm, it was close to 4 mm. Therefore, achieving an increased bone expansion in a predictable way is feasible, especially in those cases where the reduced ridge width is a limiting factor for implant placement. Last but not least, no complications related to the surgical procedure were reported in any case.

All implants were installed following BTI general guidelines for implant insertion, using a low-speed

TABLE 3 Plaque Index,²⁷ Bleeding Index,²⁸ and Suppuration Frequencies of Inserted Implants at Final Examination (Between 11 and 28 Months After Insertion)

		Number of Implants	%	Cumulative %
Plaque index	0	17	45.9	45.9
	1	9	24.3	70.3
	2	10	27.0	97.3
	3	1	2.7	100.0
	4	0	0	100.0
	5	0	0	100.0
Bleeding index	0	26	70.3	70.3
	1	9	24.3	94.6
	2	2	5.4	100.0
	3	0	0	100.0
Suppuration	Yes	0	0	0
	No	37	100	100

TABLE 4 PD (Probing Depth) Values of Inserted Implants at Final Examination (Between 11 and 28 Months After Insertion)

		Mean Value (mm)	SD
Probing depth	Mesial	2.68	0.71
	Distal	2.61	0.89
	Vestibular	2.70	1.76
	Lingual	2.43	0.84
PD average (4 points)		2.59	0.69

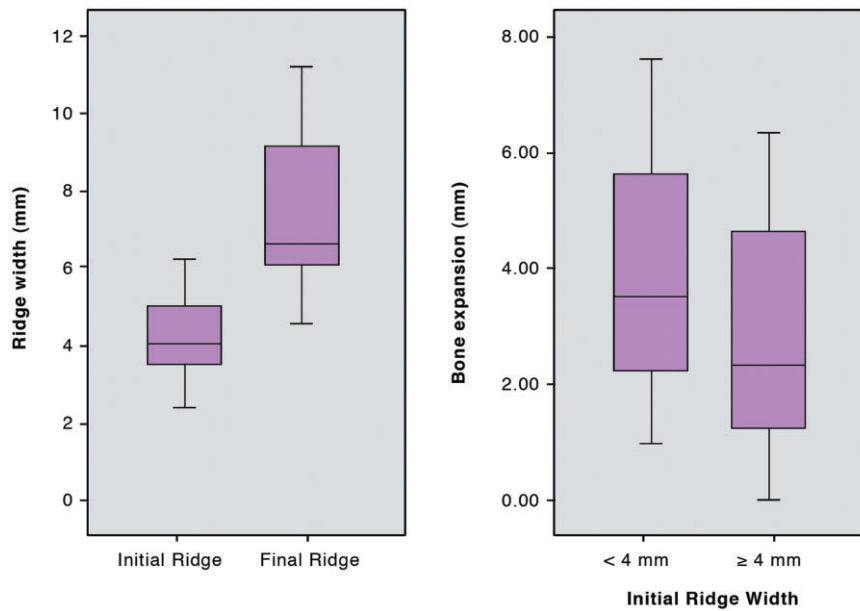


Figure 3 Left side: Box-Plot diagram showing the distribution of the width values (in mm) of initial and final bone ridges. Right side: Box-Plot diagram of bone expansion achieved in mm in both groups of implants regarding initial bone ridges width (<4 mm and ≥ 4 mm).

drilling procedure and without irrigation,²³ and were placed in different anatomical positions and using different types of prostheses. In addition, all implants were humidified with PRGF in order to bioactivate their surfaces by creating a protein layer that stimulated the mechanism of bone formation at the implant–bone interface, and promoted faster implant osseointegration.^{24,29} The latter consists on a limited volume of plasma enriched in platelets, which after activation with calcium, permits the release of a wide range of biologically active proteins. Some of these molecules including platelet derived growth factor, transforming growth factor (TGF- β), vascular endothelial growth factor, basic fibroblast growth factor, type-I insulin-like growth factor, and hepatocyte growth factor (HGF) regulate cell migration, proliferation and adhesion, driving the tissue regeneration process.²⁵ Last but not least, PRGF was also applied during the crest expansion procedure, mixed with bovine inorganic bone. The biologically active graft was used to overcorrect the defect and to promote bone regeneration through the subsequent release of growth factors.^{30,31}

Edentulous alveolar ridges of less than 5 mm in width are considered to require bone augmentation procedures before or after implant placement, to establish a bony wall of at least 1 mm around screw-type implants and thus provide a successful long-term function and

esthetics.^{32,33} In this study, a mean ridge expansion of 3.35 mm has been obtained after using the split-crest technique. The procedure reported herein has permitted a predictable implant treatment of clinical situations that otherwise would not have allowed the insertion of implants.

Interestingly, the use of ultrasonic device for bone cutting has showed clear advantages compared with other alternatives for bone cutting in different surgical procedures. Classic split-crest procedures involve razor-sharp bone chisels and rotating or oscillating saws. Chisels are driven into the bone by precise and gentle blows with a mallet. This is time consuming and requires a technical skill that is difficult to learn. Rotating saws are more rapid, but soft tissues such as the tongue, the cheek, or the lips can be affected during preparation for bony incisions, and adjacent teeth also make the operation difficult. The split-crest procedure with ultrasonic device produces much less noise and subjective sensation of vibration than the rotator instruments, which reduce the psychological stress on patients under local anesthesia,²⁰ and the technique is easier to master. There is no risk of injury to soft tissue, and any shaped horizontal or vertical bony incision can be made easily without damaging adjacent structures. The effect of cavitation cleans the working area and improves visibility.^{8,20}

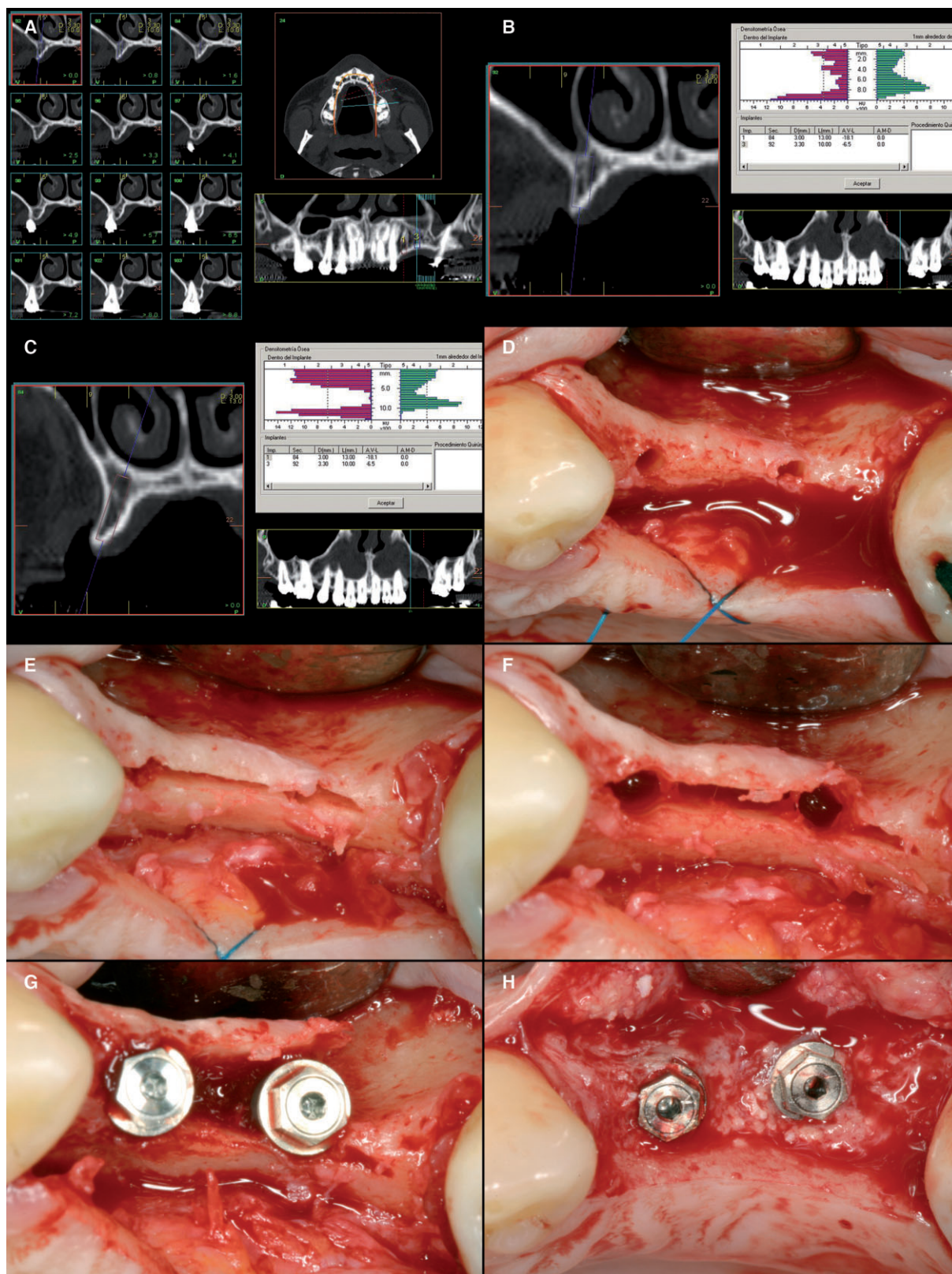


Figure 4 (A) Clinical situation of a 48-year-old woman involved in the study. (B) Maxilla with heavily reabsorbed pyramid-shaped ridge starting at 2.4 mm and widening out. (C) Very narrow ridge starting at 2.5 mm and widening out to 4 mm. (D) Image showing the ridge and markings made with the starter drill. (E) Note the mesial to distal out of the implants. (F) The expansion is performed with expander drills No. 1 and No. 2 up to the limit of the fracture. (G) The fracture is made with the implant. (H) Image showing the ridge regeneration from approximately 2.5 to 7 mm.

Of note is that the biological viability of bone treated by ultrasound is comparable with bone treated with other surgical techniques.^{10,34} The biological effects of mechanical instruments on the structure of bone and the viability of cells are important issues to be considered in regenerative surgery. Relatively high temperatures, applied even for a short time, are dangerous to cells and may cause bone necrosis. For example, bone harvested with a round bur on low- and high-speed handpieces, a spiral implant bur, or safe scrapers, is not suitable for grafting because of the absence of alive osteocytes and the predominance of nonvital bone.³⁵ On the contrary, several studies have reported the positive effects of piezoelectric surgery on bone viability.^{18,36} The effects of piezoelectric devices on chip morphology and the resulting cell viability when harvesting bone chips have been fully documented.^{34,37} In 2006, Stübinger and colleagues³⁸ showed that autologous bone from the zygomatic-maxillary region that had been harvested with a piezoelectric device could be used in augmentation for stable and aesthetic placements of oral implants after a 5-month healing. In another histomorphological study,³⁹ porous titanium implants were inserted into minipig tibias. The concentration of morphogenetic protein (BMP)-4, TGF- β 2, tumour necrosis factor alpha, and interleukin-1 β and -10 were evaluated in peri-implant osseous samples. The analyses showed that neo-osteogenesis was consistently more active in bony samples from implant sites that had been prepared using piezoelectric surgery, and there was an earlier increase in BMP-4 and TGF- β 2 proteins, and fewer proinflammatory cytokines in the bone around the implants.³⁹

In another intriguing study, Blus and Szmukler-Moncler⁸ reported the application of ultrasonic bone surgery to perform split-crest procedures on 57 patients over a period of three and a half years. The aim was to place 230 implants (78 in the mandible and 152 in the maxilla) to rehabilitate nine full arches, three hemiarches, 43 partial bridges, and 24 single crowns. The initial mean value of the ridge width was 3.2 mm, whereas at the end of the surgery the final mean width was 6 mm. Ninety-nine percent of the implants were placed and eight of them failed to osseointegrate at second stage surgery (96.5% success rate). After loading (at least 2 months for all implants), no implant failed, being the cumulative implant survival rate of 100%.

Another important use of the ultrasonic device is in the sinus lift procedure. Recently, we showed how the ultrasonic generator could be used to create the osteotomy in the lateral sinus lift approach.^{30,31} The ultrasounds generated at the active tip of the device facilitate the opening of the bone window. The osteotomy line can be easily made by cutting the osseous table in a progressive, precise, and controlled way.¹¹ The visualization of the surgical area is improved because of the cleaning effect of the irrigation liquid under the action of the ultrasounds. In fact, the latter transforms the liquid jet into a low-pressure aerosol that facilitates the cleaning of the area, reducing the risks of subcutaneous emphysema. However, one of the most important properties of the ultrasonic device is that it provides greater tactile control and minimizes the damage on surrounding soft tissues, reducing clearly the risks of perforating the schneiderian membrane.^{11,17,40} In fact, the latter happens in a frequency ranging from 16.7 to 44%, with an average of 28.6%.⁴¹ This complication can occur more frequently when doing an osteotomy with burs, or when the membrane is raised with manual elevators.²⁰ In an elegant study, ultrasonic bone surgery for sinus bone grafting was carried out in 34 patients over 5 years. During the sinus approach, only 2 of the 53 membranes (3.8%) were perforated, being the treatment a fibrin membrane made from platelet poor plasma. These data represent a considerably smaller membrane perforation percentage than those reported in the literature for this surgical procedure.⁴²

Several studies have reported less damage to soft tissues, particularly neurovascular tissue, when using a piezoelectric device compared with conventional methods.^{41,43} In addition, ultrasonic bone surgery seems to be more efficient in the first phases of bony healing; it induces an earlier increase in bone morphogenetic proteins, controls the inflammatory process better, and stimulates remodeling of bone earlier after treatment.³⁹

CONCLUSIONS

This study evaluates the clinical use of ultrasonic bone surgery in narrow ridges for implant placement after bone expansion. Results demonstrate a mean ridge expansion of 3.35 mm, being the latter greater in ridges <4 mm. The status of soft tissues was very good, showing adequate plaque index, bleeding index, and probing depth values. The success rate of implants at the end of follow-up (between 11 and 28 months after

insertion) was 100%. No complications related to the surgical procedure were reported. This procedure can be considered less invasive than other approaches because the risk of accidental damage to adjacent soft tissue structures is reduced, showing minimal patient morbidity and easy handling. In summary, ultrasonic bone surgery in split-crest technique for bone expansion can be considered a safe and effective procedure for adequate implant placement in patients with narrow bone ridges.

REFERENCES

- Chiapasco M, Ferrini F, Casentini P, Accardi S, Zaniboni M. Dental implants placed in expanded narrow edentulous ridges with the Extension Crest device. A 1-3-year multicenter follow-up study. *Clin Oral Implants Res* 2006; 17:265–272.
- Nedir R, Bischof M, Briaux JM, Beyer S, Szmukler-Moncler S, Bernard JP. A 7-year life table analysis from a prospective study on ITI implants with special emphasis on the use of short implants. Results from a private practice. *Clin Oral Implants Res* 2004; 15:150–157.
- Scipioni A, Bruschi GB, Calesini G. The edentulous ridge expansion technique: a five-year study. *Int J Periodontics Restorative Dent* 1994; 14:451–459.
- Chiapasco M, Zaniboni M, Rimondini L. Dental implants placed in grafted maxillary sinuses: a retrospective analysis of clinical outcome according to the initial clinical situation and a proposal of defect classification. *Clin Oral Implants Res* 2008; 19:416–428.
- Jensen SS, Terheyden H. Bone augmentation procedures in localized defects in the alveolar ridge: clinical results with different bone grafts and bone-substitute materials. *Int J Oral Maxillofac Implants* 2009; 24:218–236.
- Simion M, Baldoni M, Zaffe D. Jawbone enlargement using immediate implant placement associated with a split-crest technique and guided tissue regeneration. *Int J Periodontics Restorative Dent* 1992; 12:462–473.
- Anitua E, Andia I, Ardanza B, Nurden P, Nurden AT. Autologous platelets as a source of proteins for healing and tissue regeneration. *Thromb Haemost* 2004; 91:4–15.
- Blus C, Szmukler-Moncler S. Split-crest and immediate implant placement with ultra-sonic bone surgery: a 3-year life-table analysis with 230 treated sites. *Clin Oral Implants Res* 2006; 17:700–707.
- Horton JE, Tarpley TM Jr, Wood LD. The healing of surgical defects in alveolar bone produced with ultrasonic instrumentation, chisel, and rotary bur. *Oral Surg Oral Med Oral Pathol* 1975; 39:536–546.
- Horton JE, Tarpley TM Jr, Jacoway JR. Clinical applications of ultrasonic instrumentation in the surgical removal of bone. *Oral Surg Oral Med Oral Pathol* 1981; 51:236–242.
- Torrella F, Pitarch J, Cabanes G, Anitua E. Ultrasonic osteotomy for the surgical approach of the maxillary sinus: a technical note. *Int J Oral Maxillofac Implants* 1998; 23:697–700.
- Stubinger S, Kuttenger J, Filippi A, Sader R, Zeilhofer HF. Intraoral piezosurgery: preliminary results of a new technique. *J Oral Maxillofac Surg* 2005; 63:1283–1287.
- Kotrikova B, Wirtz R, Krempien R, et al. Piezosurgery – a new safe technique in cranial osteoplasty? *Int J Oral Maxillofac Surg* 2006; 35:461–465.
- Hoigne DJ, Stübinger S, Von Kaenel O, Shamdasani S, Hasenboehler P. Piezoelectric osteotomy in hand surgery: first experiences with a new technique. *BMC Musculoskelet Disord* 2006; 7:36.
- Salami A, Dellepiane M, Mora F, Crippa B, Mora R. Piezosurgery in the cochleostomy through multiple middle ear approaches. *Int J Pediatr Otorhinolaryngol* 2008; 72:653–657.
- Curie J, Curie P. Contractions et dilatations produites par des tensions dans les cristaux hémihédres à faces inclinées. *C R Acad Sci Gen* 1880; 93:1137–1140.
- Vercellotti T, De Paoli S, Nevins M. The piezoelectric bony window osteotomy and sinus membrane elevation: introduction of a new technique for simplification of the sinus augmentation procedure. *Int J Periodontics Restorative Dent* 2001; 21:561–567.
- Berengo M, Bacci C, Sartori M, Perini A, Della Barbera M, Valente M. Histomorphometric evaluation of bone grafts harvested by different methods. *Minerva Stomatol* 2006; 55:189–198.
- Harder S, Wolfart S, Mehl C, Kern M. Performance of ultrasonic devices for bone surgery and associated intraosseous temperature development. *Int J Oral Maxillofac Implants* 2009; 24:484–490.
- González-García A, Diniz-Freitas M, Somoza-Martín M, García-García A. Ultrasonic osteotomy in oral surgery and implantology. *Oral Surg Oral Med Oral Pathol Oral Radiol Endod* 2009; 108:360–367.
- Vercellotti T. Piezoelectric surgery in implantology: a case report – a new piezoelectric ridge expansion technique. *Int J Periodontics Restorative Dent* 2000; 20:358–365.
- Anitua E, Carda C, Andia I. A novel drilling procedure and subsequent bone autograft preparation: a technical note. *Int J Oral Maxillofac Implants* 2007; 22:138–145.
- Anitua EA. Enhancement of osseointegration by generating a dynamic implant surface. *J Oral Implantol* 2006; 32:72–76.
- Anitua E, Sánchez M, Orive G. Potential of endogenous regenerative technology for in situ regenerative medicine. *Adv Drug Deliv Rev* 2010; 62:741–752.
- Anitua E, Sánchez M, Orive G, Andia I. The potential impact of the preparation rich in growth factors (PRGF) in different medical fields. *Biomaterials* 2007; 28:4551–4560.

26. Van Steenberghe D, Quirynen M, Naert I. Survival and success rates with oral endosseous implants. In: Lang NP, Karring T, Lindhe J, eds. *Proceedings of the 3rd European Workshop of Periodontology. Implant dentistry*. Berlin: Quintessence, 1999:242–252.
27. Turesky S, Gilmore ND, Glickman I. Reduced plaque formation by the chloromethyl analogue of vitamin C. *J Periodontol* 1970; 41:41–43.
28. Mombelli A, Lang NP. Clinical parameters for the evaluation of dental implants. *Periodontol* 2000 1994; 4:81–86.
29. Anitua E, Orive G, Aguirre JJ, Andía I. Clinical outcome of immediately loaded dental implants bioactivated with plasma rich in growth factors: a 5-year retrospective study. *J Periodontol* 2008; 79:1168–1176.
30. Anitua E, Prado R, Orive G. A lateral approach for sinus elevation using PRGF technology. *Clin Implant Dent Relat Res* 2009; 11:23–31.
31. Anitua E, Orive G, Pla R, Roman P, Serrano V, Andía I. The effects of PRGF on bone regeneration and on titanium implant osseointegration in goats: a histologic and histomorphometric study. *J Biomed Mater Res A* 2009; 91:158–165.
32. Albrektsson T, Zarb G, Worthington P, Eriksson AR. The long-term efficacy of currently used dental implants: a review and proposed criteria of success. *Int J Oral Maxillofac Implants* 1986; 1:11–25.
33. Shulman LB. Surgical considerations in implant dentistry. *J Dent Educ* 1988; 52:712–720.
34. Chiriac G, Herten M, Schwarz F, Rothamel D, Becker J. Autogenous bone chips: influence of a new piezoelectric device (Piezosurgery) on chip morphology, cell viability and differentiation. *J Clin Periodontol* 2005; 32:994–999.
35. Labanca M, Azzola F, Vinci R, Rodella LF. Piezoelectric surgery: twenty years of use. *Br J Oral Maxillofac Surg* 2008; 46:265–269.
36. Sohn DS, Ahn MR, Lee WH, Yeo DS, Lim SY. Piezoelectric osteotomy for intraoral harvesting of bone blocks. *Int J Periodontics Restorative Dent* 2007; 27:127–131.
37. Vercellotti T, Nevins ML, Kim DM, et al. Osseous response following resective therapy with piezosurgery. *Int J Periodontics Restorative Dent* 2005; 25:543–549.
38. Stübinger S, Robertson A, Zimmerer KS, Leiggener C, Sader R, Kunz C. Piezoelectric harvesting of an autogenous bone graft from the zygomaticomaxillary region: case report. *Int J Periodontics Restorative Dent* 2006; 26:453–457.
39. Preti G, Martinasso G, Peirone B, et al. Cytokines and growth factors involved in the osseointegration of oral titanium implants positioned using piezoelectric bone surgery versus a drill technique: a pilot study in minipigs. *J Periodontol* 2007; 78:716–722.
40. Heiland M, Blessmann M, Pohlenz P, Li L, Schmelzle R, Blake F. Intraoral osteotomies using piezosurgery for distraction in an infant with Pierre-Robin sequence. *Clin Oral Investig* 2007; 11:303–306.
41. Metzger MC, Bormann KH, Schoen R, Gellrich NC, Schmelzeisen R. Inferior alveolar nerve transposition – an in vitro comparison between piezosurgery and conventional bur use. *J Oral Implantol* 2006; 32:19–25.
42. Blus C, Szmukler-Moncler S, Salama M, Salama H, Garber D. Sinus bone grafting procedures using ultrasonic bone surgery: 5-year experience. *Int J Periodontics Restorative Dent* 2008; 28:221–229.
43. Geha HJ, Gleizal AM, Nimeskern NJ, Beziat JL. Sensitivity of the inferior lip and chin following mandibular bilateral sagittal split osteotomy using Piezosurgery. *Plast Reconstr Surg* 2006; 118:1598–1607.

Copyright of Clinical Implant Dentistry & Related Research is the property of Wiley-Blackwell and its content may not be copied or emailed to multiple sites or posted to a listserv without the copyright holder's express written permission. However, users may print, download, or email articles for individual use.