

# Maxillary Sinus Floor Augmentation Surgery with Autogenous Bone Grafts as Ceiling: A Pilot Study and Test of Principle

Gerry M. Raghoobar, DDS, MD, PhD;\* Henny J.A. Meijer, DDS, PhD;† Gerdien Telleman, DDS;‡  
Arjan Vissink, DDS, MD, PhD§

---

---

## ABSTRACT

*Background:* Studies have pointed out that the mere elevation of the maxillary sinus membrane might suffice to allow for bone formation indicating the additional use of augmentation materials to be redundant.

*Purpose:* The purpose of this study was to assess whether elevation of the sinus mucosal lining combined with applying an autologous bone graft as a ceiling and placement of a short implant would allow for bone formation around the implant thus surpassing the need for applying augmentation materials around the installed implants.

*Materials and Methods:* Fourteen consecutive patients were subjected to maxillary sinus floor elevation surgery and simultaneous placement of an implant. Using the lateral bone-wall window technique, the membrane was exposed and elevated. Next, a bone graft taken from the zygomatic rim was placed as a ceiling above the inserted implant to ensure that the sinus membrane would not collapsed around a significant part of the implant. Finally, the bone window was returned in place. After connecting the healing abutment, the wound was closed.

*Results:* All implants were stable and no implants were lost. There were no complications after harvesting the bone graft. Radiographic evaluation showed a bone gain of  $3.2 \pm 0.9$  mm after 3 months and  $3.6 \pm 0.9$  mm after 1 year. Less than 6% of the implant was not covered by bone after 1 year.

*Conclusion:* Maxillary sinus membrane elevation and simultaneous placement of short endosseous implants with a bone graft as a ceiling on top of the implant result in predictable bone formation around the implant and good osseointegration on radiographs.

**KEY WORDS:** bone augmentation, bone formation, dental implant, maxillary sinus, maxillary sinus floor elevation surgery

---

---

\*Professor, Department of Oral and Maxillofacial Surgery, University Medical Center Groningen, University of Groningen, Groningen, the Netherlands; †professor, Department of Oral and Maxillofacial Surgery, University Medical Center Groningen, University of Groningen, Groningen, the Netherlands and Department of Fixed and Removable Prosthodontics, Dental School, University Medical Center Groningen, University of Groningen, Groningen, the Netherlands; ‡research fellow, Department of Oral and Maxillofacial Surgery, University Medical Center Groningen, Groningen, the Netherlands; §professor, Department of Oral and Maxillofacial Surgery, University Medical Center Groningen, University of Groningen, Groningen, the Netherlands

Reprint requests: Dr. Gerry M. Raghoobar, Department of Oral and Maxillofacial Surgery, University Medical Center Groningen, PO Box 30.001, 9700 RB Groningen, the Netherlands; e-mail: g.m.raghoobar@kchir.umcg.nl

© 2011 Wiley Periodicals, Inc.

DOI 10.1111/j.1708-8208.2011.00409.x

## INTRODUCTION

Dental implant therapy is a common, successful treatment to replace missing teeth with reliable long-term results. However, the posterior maxilla frequently represents a challenge for implant placement because of the lack of bone due to alveolar ridge resorption and maxillary sinus pneumatization. To overcome these problems, different solutions have been proposed over the years such as the use of short implants, tilted implants placed in the anterior maxilla, zygoma implants,<sup>1</sup> and maxillary sinus floor elevation combined with grafting procedures using autogenous bone, allografts, xenografts, or alloplastic materials.<sup>2-4</sup>

Regarding reconstruction of a resorbed posterior maxilla or a pneumatized maxillary sinus, a variety

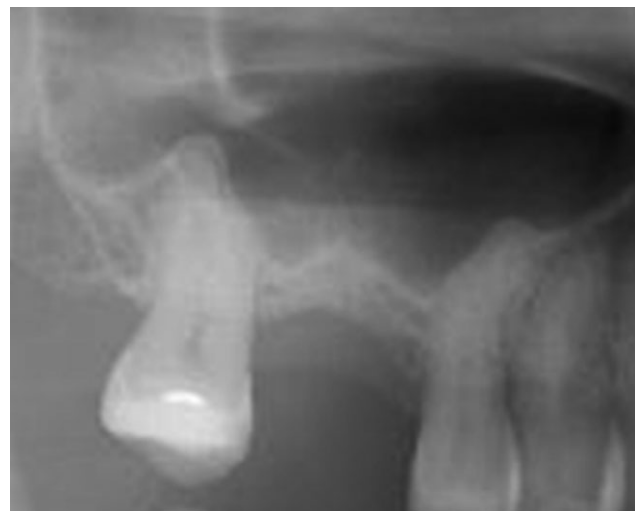of maxillary sinus floor augmentation techniques has been proposed for managing a shortage of bone volume in the posterior maxilla to allow for reliable implant placement.<sup>5,6</sup> Most techniques included grafting of the maxillary sinus, but there have been reports indicating that successful bone formation after sinus floor elevation surgery also can be obtained by simply elevating the maxillary sinus membrane using a lateral approach with or without replaceable bone window.<sup>7–12</sup> After the mere lifting of the sinus membrane, the void space filled with the blood clot was followed by formation of new bone. This phenomenon is in accordance with the principles of guided tissue regeneration. A recent animal experiment indeed proved that bone formation and implant integration occurred following sinus membrane elevation irrespective if a graft was used or not.<sup>13</sup> These authors hypothesized that the osteoinductive properties of the Schneiderian membrane and the blood clot in the secluded space below the maxillary sinus membrane can stimulate bone formation making the need for applying grafting materials into this space redundant. However, in another animal study, it was shown that blood clots do not have sufficient integrity to enable the sinus membrane to remain in an elevated position for therapeutically effective periods of time.<sup>14</sup> Thus, the sinus membrane is likely to collapse around the implant, like the implant being the post of a tent with no space left at the apical surface of the implant and the most open space at the basis of the implant. New bone formation is achieved in the space created by the sinus membrane tent, thus hardly at the apical surface and most at the basis of the implant. The same authors also showed that the maxillary sinus membrane collapsed more on the palatal side than on the buccal side, thereby leading to greater bone formation on the buccal side than on the palatal side.<sup>14</sup> From their results, these authors liked to conclude that for optimal bone formation in the complete space around the implant, there is a need to use graft materials or techniques holding the elevated membrane into position. This particularly might be the case when shorter implants are used as in such a case a collapse of the sinus membrane around a part of the implant surface would be followed by a significant part of the short implant not being covered by bone. Therefore, a method has been developed that guarantees the sinus membrane to be kept into position by the use of a small autogenous bone graft on top of the implant as

a ceiling. The treatment outcome of this modification of the sinus elevation surgery technique was assessed.

## MATERIALS AND METHODS

Fourteen consecutive patients (eight women, six men) with a mean age of  $42 \pm 12$  years (range 29–56 years) who needed implant treatment in the posterior maxilla were included between March 2007 and September 2008. The patients selected for this study had been referred to the Department of Oral and Maxillofacial Surgery (University Medical Center Groningen, University of Groningen, Groningen, the Netherlands) for implant therapy. All patients had to be 18 years or older. Written informed consent was obtained from all patients. Patients were selected on the basis of the following inclusion criteria:

- missing premolar or molar in the maxilla;
- adequate oral hygiene, that is, a modified plaque index score  $\leq 1$  and a modified sulcus bleeding index score  $\leq 1$ <sup>15</sup>;
- vertical occlusal dimensions allow creation of an anatomically formed crown;
- radiographic examination on panoramic radiographs and intraoral radiographs showed that the bone height beneath the maxillary sinus was between 2 and 5 mm (Figure 1);
- residual alveolar ridge width measured by ridge-mapping was at least 5 mm in the estimated implant position; and
- no signs of maxillary sinus pathology as judged from radiographic and clinical examination.



**Figure 1** Intraoral radiograph before treatment.

Exclusion criteria were:

- American Society of Anesthesiologists score  $\geq$ III;
- presence of clinically active clinical periodontal disease as expressed by probing pocket depths  $\geq$ 4 mm and bleeding on probing (index score  $>$ 1);
- presence of periapical lesions or any other abnormalities in the maxilla region as judged from radiographic and clinical examination;
- smoking;
- chronic medical disease or condition that would contraindicate surgical procedures (e.g., uncontrolled diabetes mellitus and the use of bisphosphonates or immunosuppressives); and
- history of radiotherapy to the head and neck region.

### Study Design

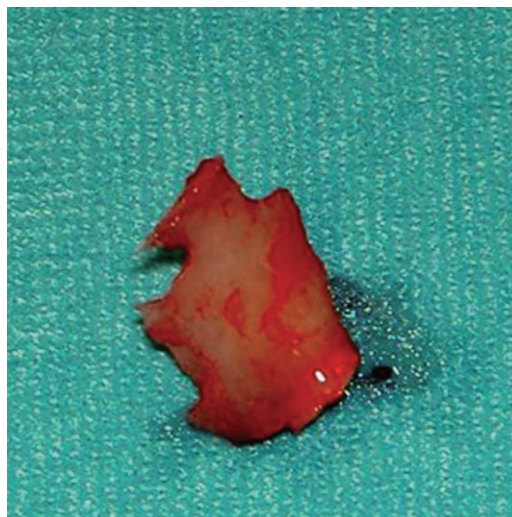
**Surgical and Prosthetic Procedures.** All patients were treated at the Department of Oral and Maxillofacial Surgery (University Medical Center Groningen, Groningen, the Netherlands). Preoperatively, diagnostic casts were made with a diagnostic arrangement representing the future restoration in the ideal prosthetic position. Next, this ideal prosthetic position was transformed into a surgical guide from transparent acrylic resin (Vertex Castapress, Vertex-Dental BV, Zeist, the Netherlands).

**Interventions.** One day before implant placement, the patients started using a 0.2% chlorhexidine mouthwash (Corsodyl, GlaxoSmithKline, Utrecht, the Netherlands). One hour before implant surgery, the patients started taking antibiotics (amoxicillin 500 mg three times daily for 7 days). The procedure was carried out under local anesthesia (Ultracaine D-S Forte, Aventis Pharma Deutschland GmbH, Frankfurt am Main, Germany). The implants used in this study were placed according to the procedure prescribed by the manufacturer.

A midcrestal mucoperiosteal incision and vertical releasing incisions were made, and a full-thickness flap was raised to provide a clear view on the surgery area. The extension of the bone window was marked with a small bur. The window was cut with a thin fissure bur. A tapered osteotomy was made to ensure the stability of the window when the window was replaced after surgery. The bone flap was dissected free from the sinus membrane with small sharp elevators and kept in saline. The Schneiderian membrane was gently elevated to

make sure there was sufficient space for implant placement and to create a secluded compartment for the implant. With a thin fissure bur on a straight handpiece, a bone graft was harvested from an area above the inferior border of the zygomatic rim and lateral from the maxillary sinus. Drilling was done under copious saline irrigation. The drill was kept at an angle of approximately 45 degrees to the occlusal plane to allow for easy removal of the bone graft from the zygomatic rim. The bone graft (at least  $5 \times 5$  mm) was removed from zygomatic rim with chisels (Figure 2).

After elevation of the maxillary sinus membrane, a hole for the implant was prepared in the residual subantral bone with a surgical template. To achieve implant stability in the cases of small remaining levels of vertical subantral bone, the drilling protocol was modified in its last preparation step. As the final bur, a bur was used with a diameter of 0.2–0.3 mm less than the diameter of the bur recommended by the manufacturer. Thus, a slightly smaller hole for the implant was prepared and the implant could be placed with better primary stability. Before insertion of the implant, the bone graft was put as a ceiling in cavity. Next, the implant was placed. Subsequently, the bone graft was positioned between the implant and membrane of the maxillary sinus in such a way that the membrane did not collapse around the implant. In particular, care was taken that the membrane was not in contact with the palatal surface of the implant; at least 1 mm space should be present between the membrane and the implant. All implants installed with torque controller adjusted to an insertion torque of



**Figure 2** Bone graft harvested from the zygomatic rim.

45 Ncm. In all cases, this torque was reached indicating a good primary stability of the implant. Bone particles were observed on the surface of the implants. The implant was placed without irrigating with saline and neither was the sinus cavity rinsed with saline after implant placement to prevent wash away of the bone particles on the implants and to disturb the formation of a coagulum in the sinus cavity and around the implants.

In total, 14 implants with a length of 8.5 mm (full Osseotite® Certain® Prevail™, Biomet 3i, Palm Beach Gardens, FL, USA) were inserted. The height of the exposed implant threads in the cavity from the residual bone to the top was recorded with a modified periodontal probe (a shortened periodontal probe to which a millimeter scale was added) on the mesial and distal site. Before closing the implants, it was checked whether the implants were surrounded by a blood clot. The cortical window was thereafter repositioned and glued with cyanoacrylate tissue glue (Histoacryl®, Braun, Tuttlingen, Germany). The healing abutment was placed on the implant. The wound was closed with slowly resorbable sutures (Vincyl & Johnson Health Care, Piscataway, NJ, USA).

For pain control, 600 mg ibuprofen (Brufen Bruis 600, Abott BV, Hoofddorp, the Netherlands) was prescribed, to be taken three times daily if needed. Patients were instructed not to blow their nose and to use nasal spray saline for 2 weeks after surgery. Removable partial dentures were not allowed for 2 weeks after surgery. Two weeks following implant surgery, the sutures were removed. Three months after implant placement, the prosthetic construction was made. The healing abutment was removed and a titanium individualized abutment (Encode, Biomet 3i, Valencia, Spain) was placed with 20 Ncm using a torque device and a large hex driver tip (Biomet 3i). The screw access hole was filled with a cotton pellet and a metal (Estetic concorde, Cendres+Metaux, Biel, Switzerland) ceramic (Ducergold Kiss, DeguDent, Hanau-Wolfgang, Germany) crown was cemented with a glass ionomer luting cement (GC Fuji 1, GC Europe NV, Leuven, Belgium).

*Outcome Measures.* The primary outcome measure of this study was apical bone level change proximal to the implant from implant placement to 15 months thereafter as measured on radiographs. Two weeks after surgery, 3 months after implant placement, and 12 months after fabrication of the definitive crown, stan-

dardized digital intraoral radiographs were taken with a long-cone paralleling technique. All measurements were done by one and the same examiner (HM). Full-screen analysis of the radiographs was performed using a specifically designed software for linear measurements. Radiographs were calibrated according to the known length of the implant. Absence of bone apical at the mesial and distal side of the implant was calculated. Reference points were marked mesially and distally at the neck of the implant, and a linear measurement was done mesially and distally along the implant axis to the first bone-to-implant contact in the apical region of the implant. This measurement was deducted from the known implant length, and the result was defined as absence of bone in the apical region. By comparing measurements on radiographs made at implant placement, after 3 months and after 1 year, apical bone level change was calculated.

Secondary outcome measures were implant survival, marginal bone level, and patient satisfaction. In addition, wound healing and implant loss were registered during follow-up.

*Patients' Satisfaction.* The patients were asked to mark their overall satisfaction on a 100 mm visual analog scale having end phrases "very dissatisfied" (0) on the left end and "very satisfied" (100) on the right end.

*Data Analysis.* In all analyses, a significant level of 0.05 was chosen. Data were analyzed using the Statistical Package for Social Sciences (SPSS) (version 16.0, SPSS Inc, Chicago, IL, USA).

## RESULTS

### Surgery

The height of the residual alveolar ridge was  $3.6 \pm 0.8$  mm (median 4 mm, range 2–5 mm). Small perforations of the sinus membrane occurred in two patients (diameter <3 mm). In both patients, it was possible to lift the membrane without further tearing. The perforation closed spontaneously by folding of the sinus membrane and was in both cases covered by the autogenous bone graft that was placed on top of the implant. The height of the exposed implant threads in the cavity from the residual bone to the top of the implant was on the mesial side  $4.4 \pm 0.6$  mm and on the distal site  $4.9 \pm 0.9$  mm.

The procedure was well tolerated by the patients, and wound healing was without complications. No nasal bleeding occurred. Two weeks after surgery, there were no signs of edema and pain. The average healing time of the implants before starting with the fabrication of the prosthetic construction was  $15 \pm 1$  week. No implants were lost. All patients attended all follow-up visits.

### Radiographic Findings

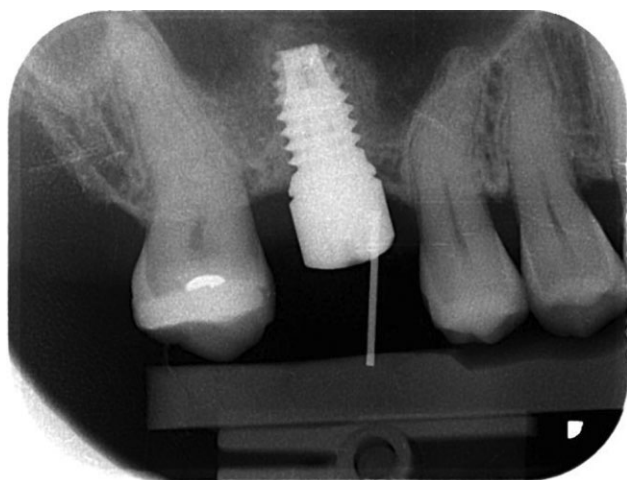
The height of the exposed implant threads, which were not covered by bone in the maxillary sinus, as assessed on radiographs taken 2 weeks after surgery was  $4.0 \pm 0.9$  mm. After 3 months,  $0.8 \pm 1$  mm (9.4%;  $p < .001$ ) of the apical part of the implant was not covered by bone (Figure 3). After 1 year of loading, even less of the implant was not covered by bone, namely,  $0.5 \pm 0.5$  mm (5.9%;  $p < .001$ ) (Figure 4). Thus, the gain of new bone as measured on radiographs was  $3.2 \pm 0.9$  mm and  $3.6 \pm 0.9$  mm after 3 months and 1 year, respectively. The mean marginal bone loss after 12 months after fabrication of the crown was  $0.23 \pm 0.61$  mm.

### Patients' Satisfaction

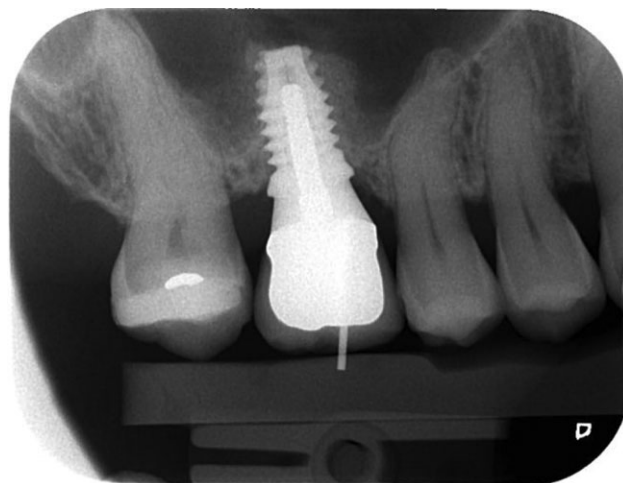
Overall, the patients were very satisfied with the surgical procedure performed ( $8.6 \pm 0.7$ , range 8–9.5).

### DISCUSSION

The present study describes a method for maxillary augmentation using an autologous bone graft as a ceiling to prevent the membrane of the maxillary sinus floor to



**Figure 3** Intraoral radiograph 12 weeks after insertion of the implant.



**Figure 4** Intraoral radiograph after 1 year. The surface of the implant is covered by bone.

collapse around the implant. The technique applied resembles the technique previously described by Lundgren and colleagues,<sup>7</sup> where in the maxillary sinus the membrane was elevated and the bone was spontaneously formed in the blood clot around implants, which had been simultaneously placed in the residual alveolar bone. As there is currently a tendency to place shorter implants in the posterior area, it is even more important that the space created around the implants placed in the space created by elevation of the sinus membrane does not collapse over a too long trajectory, thus allowing for formation of new bone covering most of the surface of the implant. When rather long implants are used, this aspect is relatively less important as in these cases, still a sufficient large proportion of the implant is covered by bone.

In human studies, bone gain was radiographically assessed by intraoral radiographs,<sup>7,9,10,12,16,17</sup> but actually, this approach only allowed for bone height measurements on the mesial and distal side of the implants. Furthermore, it has to be noted that measurements of bone height on radiographs are hampered by the phenomenon that a certain level of mineralization of the newly formed bone is needed to allow for measurement that bone on radiographs, which might lead to an underreporting of the amount of newly formed bone. Other factors that might affect proper detection of formation of new bone are the high distortion of the film related to the palatal anatomy, as well as the apical part of the implant is not always on the film.<sup>16</sup> The latter point was no problem in our study because 8.5 mm

implants were used. In an animal study, it was reported that the maxillary sinus membrane could collapse more on the palatal side than on the buccal side, thereby leading to more bone formation on the buccal side than on the palatal side.<sup>14</sup> Particularly, in case of a wide maxillary sinus, the risk of collapse of the sinus membrane onto the implant on the palatal side is higher than on the buccal side. If a short implant is placed, this could be a problem if not enough bone formation occur.

The ideal space-making device to keep the sinus membrane in place in order to allow for bone formation in the created space should be stable and should ensure a maintained connection between the membrane and the secluded space.<sup>18</sup> When first design of such a device was used, at most, minor signs of bone formation were observed after 6 months of healing, while membrane elevation and simultaneous implant placement was followed by bone formation along the implant surface.<sup>18</sup> Considering the evidence that the sinus membrane exhibits osteoinductive properties, they modified the design of their device in such a way that it became permeable for cell and fluid exchange between the inner compartment of the sinus and the membrane.<sup>19</sup> As a result, they now observed bone formation in contact with both the Schneiderian membrane and the device, in most cases. However, the modified device had a lack of stabilization. In another study, new bone formation in the maxillary sinus was observed when using just absorbable gelatin sponge as the graft material.<sup>17</sup> The gelatin sponge was placed anterior, posterior, and directly above the implant site. The adsorbable gelatin sponge prevented a collapse of the sinus membrane around the surface of the implant, thus allowing for formation of new bone.

There are many reports presenting predictable clinical outcomes from sinus lift techniques irrespective of the type of bone grafting material used.<sup>2-4</sup> This may be explained by the fact that the maxillary sinus has a great potential for bone formation, as also can be deduced from the "spontaneous" bone formation observed in the present patients. In other words, applying a grafting material in the space created beneath the sinus membrane is not a prerequisite for predictable bone formation. Recently, Ferrigno and colleagues<sup>20</sup> reported that a new bone was generated in the maxillary sinus from both the lateral wall and the floor of the sinus after membrane elevation using an osteotome technique. With osteotomes, the Schneiderian

membrane is elevated through a crestal approach immediately followed by insertion of the implant. Furthermore, Lai and colleagues<sup>21</sup> observed that the formation of a new bone in elevated spaces was irrespective of whether they had grafted that space or not. Finally, Nedir and colleagues<sup>22</sup> showed in their study that in spaces at least 3 mm, there was no need to use a grafting material. Thus, although the mechanisms are not fully understood, it is obvious that the controlled trauma when lifting the sinus membrane can result in the formation of a blood clot and subsequent bone formation.<sup>13</sup> In fact, again a kind of tent is created that is filled with blood. The displacement of the membrane probably triggers a series of events, including blood and fibrin clot formation, cellular migration and differentiation, angiogenesis, and osteogenesis. Here, the role of the sinus membrane itself is unclear, but a recent study in primates indicated the presence of a potential of mesenchymal cells in the sinus membrane that might allow for bone formation.<sup>13</sup> On the contrary, Scala and colleagues<sup>23</sup> found no evidence in their study of monkeys that the Schneiderian membrane participated in the new bone formation during the early phase of healing. The latter authors showed that the newly formed bone originated from the sinus walls and septa. They postulated that the coagulum that filled the void distal to the implant gave rise to newly formed bone. However, the void occupied by the coagulum shrank substantially. Shrinkage of the coagulum was also noted by Xu and colleagues<sup>24</sup> on basis of which finding they concluded that the blood clot was unstable during the early phase of healing and thus was an unreliable source for adequate peri-implant bone formation. Furthermore, repositioning of the removed lateral bone window may contribute to create a closed compartment similar to a barrier membrane.<sup>16</sup> After 30 days, the window access appeared to be closed by a layer of newly formed trabecular bone.<sup>23</sup>

No serious complications were reported during the follow-up period when the sinus was augmented with the described procedure neither were complications observed resulting from harvesting zygomatic bone. The zygomatic crest is also suitable for treatment of bone defects at one or two implant sites, covering exposed implant surfaces, and an additional source of bone together with other intraoral donor sites.<sup>25</sup> Surgical access to the zygoma is fairly simple and can be performed using local anesthesia.

During the installation of implants, osteogenic bone particles were translocated along the surface. These particles may contribute to peri-implant bone healing. Based on this phenomenon, it is hypothesized that implants placed with undersized drilling, besides showing higher primary implant stability, also enhance the amount and osteogenic responses of these bone particles. In our study, the implants were placed with undersized drilling. It was shown that the undersized surgical technique not only resulted in higher primary implant stability but also induces more translocated bone particles, thus having a positive influence on the osteogenic response.<sup>26</sup> These bone particles can form bones.

From this study, it can be concluded that maxillary sinus membrane elevation and simultaneous placement of short implants with a bone graft placed as a ceiling will result in predictable bone formation around the implants observed on radiographs even when the implants, as was done in this study, were placed as a one-stage approach. The preliminary results from this study are encouraging as the results are comparable with the results achieved with traditional augmentation using autogenous bone or bone substitutes. Further, histologic studies are needed to prove whether the new bone formation as presumed to have occurred around the implants on radiographs is indeed bone and indeed has contributed to osseointegration.

## REFERENCES

- Block MS, Haggerty CJ, Fisher GR. Nongrafting implant options for restoration of the edentulous maxilla. *J Oral Maxillofac Surg* 2009; 67:872–881.
- Raghoobar GM, Timmenga NM, Reintsema H, Stegenga B, Vissink A. Maxillary bone grafting for the insertion of endosseous implants: results after 12–124 months. *Clin Oral Implants Res* 2001; 12:279–286.
- Chiapasco M, Zaniboni M. Methods to treat the edentulous posterior maxilla: implants with sinus grafting. *J Oral Maxillofac Surg* 2009; 67:867–871.
- Zijderveld SA, Schulten EA, Aartman IH, ten Bruggenkate CM. Long-term changes in graft height after maxillary sinus floor elevation with different grafting materials: radiographic evaluation with a minimum follow-up of 4.5 years. *Clin Oral Implants Res* 2009; 20:691–700.
- Tatum H. Maxillary and sinus reconstructions. *Dent Clin North Am* 1986; 30:207–229.
- Summers RB. A new concept in maxillary implant surgery: the osteotome technique. *Compend Contin Educ Dent* 1994; 15:152–162.
- Lundgren S, Andersson S, Gualini F, Sennerby L. Bone reformation with sinus membrane elevation: a new surgical technique for maxillary sinus floor augmentation. *Clin Implant Dent Relat Res* 2004; 6:165–173.
- Ellegaard B, Baelum V, Kølsen-Petersen J. Non-grafted sinus implants in periodontally compromised patients: a time-to-event analysis. *Clin Oral Implants Res* 2006; 17:156–164.
- Thor A, Sennerby L, Hirsch JM, Rasmusson L. Bone formation at the maxillary sinus floor following simultaneous elevation of the mucosal lining and implant installation without graft material: an evaluation of 20 patients treated with 44 Astra Tech implants. *J Oral Maxillofac Surg* 2007; 65:64–72.
- Hatano N, Sennerby L, Lundgren S. Maxillary sinus augmentation using sinus membrane elevation and peripheral venous blood for implant-supported rehabilitation of the atrophic posterior maxilla: case series. *Clin Implant Dent Relat Res* 2007; 9:150–155.
- Lundgren S, Cricchio G, Palma VC, Salata LA, Sennerby L. Sinus membrane elevation and simultaneous insertion of dental implants: a new surgical technique in maxillary sinus floor augmentation. *Periodontol* 2000 2008; 47:193–205.
- Borges FL, Dias RO, Piattelli A, et al. Simultaneous sinus membrane elevation and dental implant placement without bone graft: a 6-month follow-up study. *J Periodontol* 2011; 82:403–412.
- Palma VC, Magro-Filho O, Oliveira JA, Lundgren S, Salata LA, Sennerby L. Bone reformation and implant integration following maxillary sinus membrane elevation: an experimental study in primates. *Clin Implant Dent Relat Res* 2006; 8:11–24.
- Kim HR, Choi BH, Xuan F, Jeong SM. The use of autologous venous blood for maxillary sinus floor augmentation in conjunction with sinus membrane elevation: an experimental study. *Clin Oral Implants Res* 2010; 21:346–349.
- Mombelli A, van Oosten MA, Schurch E Jr, Land NP. The microbiota associated with successful or failing osseointegrated titanium implants. *Oral Microbiol Immunol* 1987; 2:145–151.
- Cricchio G, Sennerby L, Lundgren S. Sinus bone formation and implant survival after sinus membrane elevation and implant placement: a 1- to 6-year follow-up study. *Clin Oral Implants Res* 2011; 22:1200–1212.
- Sohn DS, Moon JW, Moon KN, Cho SC, Kang PS. New bone formation in the maxillary sinus using only absorbable gelatin sponge. *J Oral Maxillofac Surg* 2010; 68:1327–1333.
- Cricchio G, Palma VC, Faria PEP, et al. Histological findings following the use of a space-making device for bone reformation and implant integration in the maxillary sinus of primates. *Clin Implant Dent Relat Res* 2009; 11:14–22.

19. Cricchio G, Palma VC, Faria PEP, et al. Histological outcomes on the development of new space-making devices for maxillary sinus floor augmentation. *Clin Implant Dent Relat Res* 2011; 13:224–230.
20. Ferrigno N, Laureti M, Fanali S. Dental implants placement in conjunction with osteotome sinus floor elevation: a 12-year life-table analysis from a prospective study on 585 ITI implants. *Clin Oral Implants Res* 2006; 17:194–205.
21. Lai HC, Zhuang LF, Lv XF, Zhang ZY, Zhang YX, Zhang ZY. Osteotome sinus floor elevation with or without grafting: a preliminary clinical trial. *Clin Oral Implants Res* 2010; 21:520–526.
22. Nedir R, Nurdin N, Vazquez L, Szmukler-Moncler S, Bischof M, Bernard JP. Osteotome sinus floor elevation technique without grafting: a 5-year prospective study. *J Clin Periodontol* 2010; 37:1023–1028.
23. Scala A, Botticelli D, Rangel IG Jr, de Oliveira JA, Okamoto R, Lang NP. Early healing after elevation of the maxillary sinus floor applying a lateral access: a histological study in monkeys. *Clin Oral Implants Res* 2010; 21:1320–1326.
24. Xu H, Shimizu Y, Ooya K. Histomorphometric study of the stability of newly formed bone after elevation of the floor of the maxillary sinus. *Br J Oral Maxillofac Surg* 2005; 43:493–499.
25. Kainulainen VT, Sandor GKB, Oikarinen KS, Clokie CML. Zygomatic bone: an additional donor site for alveolar bone reconstruction. Technical note. *Int J Oral Maxillofac Implants* 2002; 17:723–728.
26. Tabassum A, Walboomers XF, Wolke JG, Meijer GJ, Jansen JA. Bone particles and the undersized surgical technique. *J Dent Res* 2010; 89:581–586.



Copyright of Clinical Implant Dentistry & Related Research is the property of Wiley-Blackwell and its content may not be copied or emailed to multiple sites or posted to a listserv without the copyright holder's express written permission. However, users may print, download, or email articles for individual use.