

# Electrical Mallet Provides Essential Advantages in Maxillary Bone Condensing. A Prospective Clinical Study

Roberto Crespi, MD, MS;\* Paolo Capparè, MD;† Enrico Gherlone, MD, DMD, PhD‡

---

## ABSTRACT

**Purpose:** The aim of this study was to compare the use of hand mallet versus electrical mallet (magnetic mallet, Meta-Ergonomica, Turbigo, Milan, Italy) in osteotome-assisted surgery for condensing bone procedure in edentulous molar and premolar maxillary regions.

**Materials and Methods:** Patients edentulous in maxillary premolar and molar regions with type 3 or 4 bone were enrolled in this prospective clinical study. The patients were randomly divided in two groups: in the test group, the implant site was prepared with osteotomes pushed by magnetic mallet, while in the control group, the implant site was performed with osteotomes pressed by hand mallet. Intraoral digital radiographic measurements were reported at 6, 12, and 24 months.

**Results:** Thirty-six patients were enrolled in the study. Eighteen patients (21 women and 15 men) were included in the test group and 18 patients in the control group. The mean patient age was 56.1 years (range 41–71 years). Fifty dental implants were placed. In 10 cases, five in control and five in test group, sinus elevation was performed. After 24 months follow-up, a survival rate of 96.0% was reported. In the control group, two patients claimed benign paroxysmal positional vertigo following the use of osteotomes with hand hammer. Marginal bone levels remained stable over time for both groups, and not statistically significant differences were found. After 12 months, the bone height incremented in both groups and, at 24 months, was stable. Statistical analysis reported not statistically significant differences between test and control group.

**Conclusions:** These results demonstrated a stable marginal bone levels over time and a significant increase in bone height between 6 and 12 months in osteotome technique (not sinus elevation). The use of magnetic mallet provided some essential clinical advantages during surgical procedure in comparison with hand mallet.

**KEY WORDS:** bone condensing, osteotome, sinus floor elevation, surgery mallet

---

## INTRODUCTION

Primary stability has been identified as an important prerequisite in achieving osseointegration, as it may be a useful predictor for osseointegration.<sup>1</sup>

Quality of bone represents an important factor for implant stability because dental implants placed in dense bone (types 1 and 2) usually show better initial strength than those placed in poorer quality bone (types 3 and 4).<sup>2</sup>

Bone is a biological tissue that can be modeled and compacted toward the desired location and shape by use of osteotomes,<sup>3</sup> but this procedure requires the practitioner to be extremely aware of bone quality.<sup>4</sup>

Types 3 and 4 bone are best suited for trabecular compaction as in premolar and molar maxilla region, and this surgical procedure offers several significant advantages over the traditional surgical drills. When adequate quantities of dense bone are available,

---

\*Clinical professor, Department of Dentistry, Vita Salute University, San Raffaele Hospital, Milan, Italy; †clinician, MD, Department of Dentistry, Vita Salute University, San Raffaele Hospital, Milan, Italy; ‡full professor and chairman, Department of Dentistry, Vita Salute University, San Raffaele Hospital, Milan, Italy

Reprint requests: Dr. Roberto Crespi, Department of Dentistry, Vita Salute University, San Raffaele Hospital, Via Olgettina N.48, 20132 Milano, Italy; e-mail: robcresp@libero.it

Conflict of interest statement: We certify that we have no affiliation with or financial involvement in any organization or entity with direct financial interest in the subject matter or materials discussed in the manuscript and that the material is original and has not been published elsewhere.

removing bone by drills is not a problem. But when the alveolar bone is soft or when the ridge has resorbed enough to compromise implant placement, the ability to preserve and improve existing bone, it becomes mandatory. Osteotomes take advantage of the fact that bone is viscoelastic<sup>5</sup>; it can often be compressed and manipulated. Additionally, the osteotome technique generates no heat, an advantage because heat is a major detriment to osseointegration.

In the posterior maxilla, osteotomes present much more visibility than a rotating drill with irrigation stream. Furthermore, osteotomes allow for greater tactile sensitivity, making them more appropriate than drills for probing.<sup>6</sup>

With osteotomes, type 4 bone can be changed into type 3, and type 3 bone can generally be compacted to resemble type 2.<sup>7,8</sup>

All these studies were carried out by hand mallet method that may provoke benign paroxysmal positional vertigo (BPPV),<sup>9</sup> which has been described as a consequence of working the implant bed with osteotomes. During the placement of maxillary dental implants using the osteotome technique, the trauma induced by percussion with the surgical hammer, along with hyperextension of the neck during the operation, can displace otoliths and induce BPPV.<sup>10–12</sup>

The aim of this prospective study was to compare electrical versus hand mallet in maxillary bone condensing, by assessing implant survival, marginal bone loss, alveolar bone height, and clinical incidence of BPPV.

## MATERIALS AND METHODS

The prospective clinical study was composed of a population of patients presenting to the Department of Dentistry, San Raffaele Hospital, Milan, Italy, for evaluation and management of posterior maxillary edentulism between January 2007 and February 2009.

The following inclusion criteria were adopted:

- edentulism in maxillary molar and/or premolar regions with types 3 or 4 bone;
- good general health;
- non-smokers.

The exclusion criteria were:

- presence of chronic systemic diseases;
- presence of acute or chronic sinus problems;

- alcohol or drug abuse;
- history of vertigo.

The local ethical committee approved the study, and all patients signed an informed consent form. The diagnosis was made clinically and radiographically. The patients were treated by one oral surgeon and one prosthodontist at the Department of Dentistry, San Raffaele Hospital, Milan, Italy.

## Surgical Protocol

One hour prior to surgery, the patients received 1 g amoxicillin and 1 g twice a day for a week after surgical procedure. Surgery was performed under local anesthesia (optocaine [Molteni Dental, Scandicci (Fi), Italy] 20 mg/mL with adrenaline 1:80,000).

Patients were randomly divided in two groups by lots in closed envelopes. In the test group (TG), the implant site was prepared with osteotomes pressed by electrical mallet (magnetic mallet, Meta-Ergonomica, Turbigo, Milan, Italy), while in the control group (CG), the implant site was performed with osteotomes pressed by hand mallet.

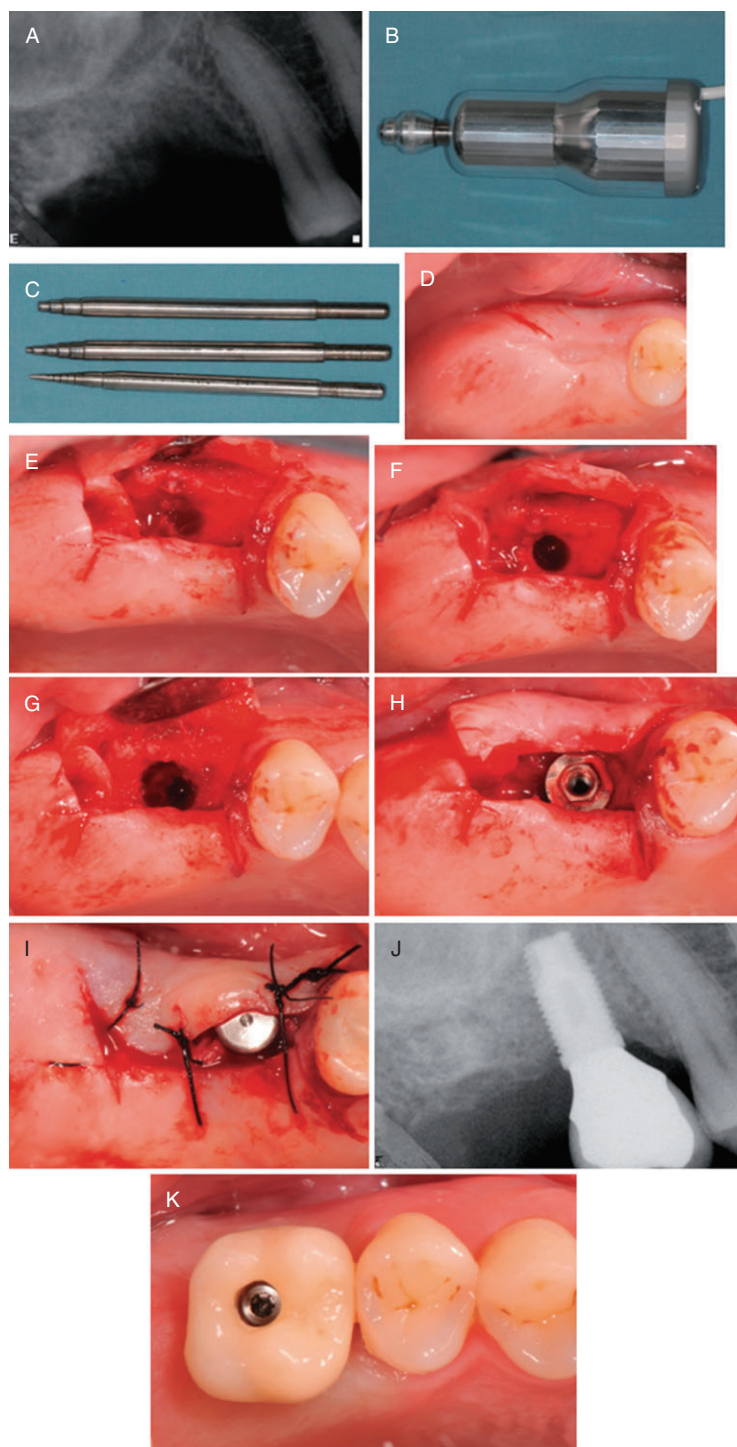
Both in TG and CG, Titanium Plasma Spray implants (Outlink, Sweden & Martina, Due Carrare, Padova, Italy), with a machined neck for 0.8 mm and a rough surface body with a progressive thread design with external hexagon as implant/abutment junctions, were positioned.

According to the prosthetic treatment planning, the location for implant placement was established; likewise, the residual bone height at such locations was first measured on periapical radiographs as the distance from the bone crest to the sinus floor (Figure 1).

The same oral surgeon (R.C.) performed all surgical procedures.

The bone crest that needed implant was exposed with a modified partial thickness flap with the tip of the no. 64 Beaver blade (Becton Dickinson Acute Care, Franklin Lakes, NJ, USA). The edentulous bone crest was covered by the preserved suprabony connective tissue and the underlying periosteum. The proposed implant site was first clearly marked with a 2.0-mm round drill followed by a 2.0-mm twist drill.

The degree of resistance encountered in this initial drilling procedure will enable the operator to confirm the density of the bone at the site, because bone in the posterior maxilla is generally spongy (types 3 and 4).



**Figure 1** The distance between the ridge crest and the floor of the sinus is measured on a preoperative periapical radiograph (A). Magnetic mallet and osteotomes (B and C). Clinical photograph showing the edentulous ridge of the posterior maxilla before surgery (D). When all the occlusal portion of the edentulous crest was marked the tip of the corresponding, in size, bone expander was used. A progressive in diameter bone expander starting from smallest instruments were inserted in the previous osteotomy site created with the small surgical bur; the bone expanders are pushed deep in the bone by magnetic mallet forces (E–G). The clinical aspect of implant placement (H). The buccal flap was apically repositioned and stabilized with sutures tied to the margin of the lingual/palatal flap and anchored buccally with a loose loop to the periosteum at the level of the alveolar mucosa (I). Periapical radiograph performed at 2 years after surgery (J). Five months later, final metal ceramic restoration was delivered (K).

CG expansion of the osteotomy was carried out with a combination of drills and concave-tipped osteotomes pushed by hand mallet.

The implant site was created expanding the bone tissue both laterally against the preexisting lateral walls and apically moving up and compressing with hand mallet a progressive series of bone expanders<sup>13</sup> (Sweden & Martina). An axial force was applied.

The osteotomy was gradually expanded in 0.5-mm increments using osteotomes inserted to the working depth. The final diameter of the osteotomy was 1.2 mm less than the anticipated implant diameter, depending on local bone density.

TG expansion of the osteotomy was carried out following the same procedure reported in CG with similar osteotome, but they were directly attached and pushed by electrical mallet.

The electrical mallet (magnetic mallet) is a magneto-dynamical instrument assembled into a hand-piece energized by a power control device, delivering forces by timing of application (see Figure 1B). The osteotomes are attached to the handpiece that pushes a shock wave on their tip. The magnetic wave and the subsequent shock wave are calibrated regarding the timing of application of the force and induce axial and radial movements applied on the tip of osteotome with a fast force of 90 daN/8  $\mu$ s.

The magnetic mallet imparted to osteotomes a longitudinal movement along central axis, moving up and down toward pilot bone hole, providing a driving mechanism of longitudinal movements.

Such mechanical sequence of osteotomes progressively condensed internal bone wall of initial hole radially outward with respect to central axis to create high density bone tissue along substantial portion of length of implant site preparation. If needed, sinus elevation was performed using the technique reported by Cavicchia and colleagues.<sup>14</sup>

In these cases, the final osteotome punched out the cortical plate of the sinus floor with the adherent membrane. Immediately after fracture, the implant site was tested for perforation of the sinus membrane by the Valsalva maneuver. A minimum insertion torque of 30 Ncm was considered. Subsequently, the soft tissues were sutured.

The buccal flap was apically repositioned and stabilized with sutures tied to the margin of the palatal flap and anchored buccally with a loose loop to the perios-

teum at the level of the alveolar mucosa. This suture design avoided tissue traction in the repositioned buccal flap. The gap between the superficial margin of the buccally repositioned tissue and the lower part of the palatal tissue was healed by secondary intention in order to increase the size of keratinized mucosa (see Figure 1).

## Radiographic Assessments

Intraoral digital radiographic examinations (Schick CDR, Schick Technologies, Long Island City, NY, USA) were made at baseline, 6, 12, and 24 months after implant placement. The periapical radiographs were taken perpendicularly to the long axis of the implant with a long-cone parallel technique using an occlusal template. A blinded radiologist measured the changes in marginal bone height over time.

The marginal bone level was considered from the reference point represented by more coronal portion of the implant in contact with the bone, to the point where the bone tissue met the implant surface at the mesial and distal sites. The difference of bone level was measured by the software included (Schick CDR).

In 10 cases in which sinus lift procedure was performed, the following parameters were assessed:

- A presurgical distance from the alveolar crest to the floor of the maxillary sinus (see Figure 1A);
- The amount of new radiopacity between the sinus floor and alveolar crest measured from the mesial and distal surfaces of each dental implant surface (see Figure 1J).

A mean for initial and gained alveolar bone height was obtained from these readings by a specific software (Schick CDR) and evaluated at 12 and 24 months of healing from implant placement.

## Prosthetic Protocol

Three months after implant placement, temporary restorations were performed. Transfer copings was inserted into the external hex of the implant with a seating instrument and secured with abutment screws. Impressions were taken with a silicon material using a customized impression tray. All temporary crowns were in full contact in centric occlusion. Two months later, final metal ceramic restorations were delivered. The occlusion was checked using 8- $\mu$ m foil (Shimstock, Hanel, Germany), which was to resist withdrawal only under maximal clenching.



**TABLE 1 Predictor Variable versus Study Variables**

Technique	Patients, <i>n</i>	Sex	Mean Age (Years $\pm$ SD)	Patients Needing Sinus Lift, <i>n</i>	Baseline Bone Levels (mm)
Electrical mallet (test group)	18	11 F; 7 M	58.6 $\pm$ 19.1	5	6.50 $\pm$ 1.58 mm
Hand mallet (control group)	18	10 F; 8 M	51.3 $\pm$ 18.2	5	6.83 $\pm$ 1.41 mm
<i>p</i> Value	—	—	NS = .5306	—	NS = .6889

NS, not significant.

## Follow-Up Evaluation

The following clinical parameters were checked: pain, occlusion, and prosthetic mobility. Criteria for implant survival were accepted as presence of implant stability, absence of radiolucent zone around the implants, no soft tissue suppuration, and no pain. Follow-up examinations were performed at baseline, 6, 12, and 24 months. Probing depths (PDs) were determined on the mesial, distal, buccal, and palatal surfaces of the implants with a periodontal probe (Hu-Friedy PGF-GFS, Hu-Friedy, Chicago, IL, USA).

## Assessments and Statistical Analysis

In the present study, the predictor variable is the surgical technique (different device) for bone condensing, while outcome variables were marginal bone loss (primary outcome), gained alveolar bone height, implant survival, and occurrence of BPPV (secondary outcomes). A specific software was used for all statistical calculations (SPSS 11.5.0, SPSS Inc., Chicago, IL, USA). Data are presented as mean  $\pm$  standard deviation. Comparisons between mean values of bone height and marginal bone loss at different time points (baseline, 12, and 24 months) and comparisons between test and CG, were performed by a two-tailed *t*-test (*p* < .05 was considered the threshold for statistical significance). Statistical power calculations showed that the minimal sample size was 13, with an alpha value of 0.05 and 80% power (primary outcome variable was used to estimate the sample size). The multivariate analysis of variance was used in adjusting multiple comparisons over time. The significance level was set at  $\alpha = 0.05$ .

## RESULTS

Thirty-six patients were enrolled in this clinical study, they were randomly divided in two groups (*n* = 18 per group) by lots in closed envelopes. The mean patient age (21 women and 15 men) was 56.1 years (range 41–71

years). Fifty Titanium Plasma Spray implants were positioned (25 in TG and 25 in CG). Twelve implants had a diameter of 5 mm with a 13 mm length, 12 implants had a diameter of 5 mm with a 10 mm length, 8 implants had a diameter of 4.2 mm with a 13 mm length, and 18 implants had a diameter of 4.2 mm with a 10 mm length. In 10 cases, five in CG and five in TG, sinus elevation was performed (Table 1). In both groups, all implants were located with a minimum insertion torque of 30 Ncm.

## Surgical and Prosthetic Procedure

After 24 months follow-up, a survival rate of 96.0% was reported. Two implant failures occurred within 1 month from implant placement (one implant in TG and one in CG, not in sinus lift procedures – for both groups, a survival rate of 96.0% was reported). Their dimensions were both 5  $\times$  13 mm, their position were 1.6. These implants were replaced 2 months later.

Among 10 cases of sinus elevation, no sinus membrane perforation was performed. No pain or final prosthesis mobility was recorded. There was a suitable wound healing around temporary crowns. Minor swelling of gingival mucosa was present in the first days after surgical procedures, no mucositis, implant mobility, or flap dehiscence with suppuration were found.

In CG, two patients developed BPPV following the use of osteotomes and percussion with a hand hammer (incidence of BPPV in CG = 8.00%).

On sitting up after surgery, one patient experienced intense vertigo, with dizziness and disorientation accompanied by distress, nausea, and vomiting, and the sensation of objects moving around her. The vertigo remitted spontaneously after 1 day.

The patients in TG presented no symptoms of BPPV. The surgical procedure was faster in TG, and the implant bed preparation was more precise with magnetic mallet.

## Clinical Parameters

The mean PD was obtained from averaging PD measurements on the mesial, distal, buccal, and palatal surfaces of the implants; the mean values were  $1.53 \pm 0.49$  mm and  $2.08 \pm 0.52$  mm at baseline and 24 months, respectively.

## Radiographic Evaluation

Radiographic results were reported at 6, 12, and 24 Months from implant placement (Table 2).

In TG at 12 months, a mean mesial bone loss of  $0.81 \pm 0.41$  mm and a mean distal bone loss of  $0.85 \pm 0.54$  mm (mean bone loss:  $0.83 \pm 0.47$  mm) were reported (see Table 2). At 24 months, a mean mesial bone loss of  $0.80 \pm 0.48$  mm and a mean distal bone loss of  $0.84 \pm 0.58$  mm (mean bone loss:  $0.82 \pm 0.53$  mm) were measured (see Table 2).

In CG at 12 months, a mean mesial bone loss of  $0.83 \pm 0.40$  mm and a mean distal bone loss of  $0.87 \pm 0.52$  mm (mean bone loss:  $0.85 \pm 0.46$  mm) were reported (see Table 2). At 24 months, a mean mesial bone loss of  $0.84 \pm 0.52$  mm and a mean distal bone loss of  $0.91 \pm 0.58$  mm (mean bone loss:  $0.88 \pm 0.55$  mm) were measured (see Table 2).

Not statistically significant differences were found between two groups for values obtained at 6, 12, and 24 months from implant placement ( $p > .05$ ; see Table 2).

Multiple comparisons over time reported not statistically significant differences ( $p > .05$ ).

In 10 cases in which sinus lift procedure was performed, baseline bone levels (initial alveolar bone height) were  $6.50 \pm 1.58$  mm for TG and  $6.83 \pm 1.41$  mm for CG (see Table 1).

The alveolar bone gain following 6 months of healing, evaluated as the presence of radiopacity around exposed mesial and distal implant surfaces within the created space at the floor of the maxillary sinus, resulted in a mean value of  $2.62 \pm 1.23$  mm for TG and  $2.75 \pm 1.40$  mm for CG.

Successively, after 12 months, the radiopacity around exposed mesial and distal implant surfaces incremented in a similar trend for both groups (Table 3).

At 24 months from implant placement the mean bone height measurements were stable ( $4.13 \pm 1.12$  mm TG and  $4.19 \pm 1.58$  mm CG) (see Table 3).

Statistical analysis reported not statistically significant differences between TG and CG. However, a statis-

tically significant difference ( $p < .05$ ) between 6 and 12 months values for both groups was reported, whereas not statistically significant differences between 12 and 24 months values were found.

These results demonstrated a significant increase in bone height between 6 and 12 months, then stable bone levels with a 2-year follow-up.

## DISCUSSION

In this prospective clinical study, the aim was to compare the use of hand mallet versus electrical mallet (magnetic mallet) in osteotome-assisted surgery for condensing bone procedure in edentulous molar and premolar maxillary regions.

In spongy bone, osteotomes change the density of the bone around the osteotomy site for implant placement.<sup>3</sup>

As reported in this clinical study, the implant site was prepared by use of osteotomes,<sup>15-19</sup> which compressed the native bone as reported by literature, for vertical bone expansion and cortical sinus floor elevation, obtaining a survival rate of 96% for all placed implants at 24 months follow-up.

With a series of gradual widening tapered instruments, the trabecular bone is compressed laterally in order to improve the quality and density of the implant osteotomy. Lateral bone compression during site preparation can improve the quality of type 3 bone to seem more like type 2 bone, so that implants may also be placed, with good success, in type 4 bone compressed to type 3 bone as can be found in the maxillary molar region, especially when the bone width and height are insufficient.

This surgical procedure is supported by data from several experimental studies in animals showing that insertion of implants by means of osteotomes resulted in faster and greater bone apposition compared with implants inserted in a conventional way.<sup>20</sup>

The results of that study revealed that the benefit of the osteotome technique is an increased bone-implant contact ratio in the early phase after the implant placement providing an enhanced primary stability.

Primary stability is an essential factor for osseointegration process because it increases the success rate of dental implants in type 4 bone.<sup>20</sup>

It has been claimed that implant placement by the osteotome technique not only improves primary stability but leads to accelerated bone healing compared with

TABLE 2 Predictor Variable versus Primary Outcome Variable (Marginal Bone Levels)

	6-Months Follow-Up			12-Months Follow-Up			24-Months Follow-Up		
	Mesial Bone Loss (mm)	Distal Bone Loss (mm)	Mean Bone Loss (mm)	Mesial Bone Loss (mm)	Distal Bone Loss (mm)	Mean Bone Loss (mm)	Mesial Bone Loss (mm)	Distal Bone Loss (mm)	Mean Bone Loss (mm)
Test group	0.95 ± 0.29	1.01 ± 0.25	0.98 ± 0.27	0.81 ± 0.41	0.85 ± 0.54	0.83 ± 0.47	0.80 ± 0.48	0.84 ± 0.58	0.82 ± 0.53
Control group	0.98 ± 0.36	1.04 ± 0.32	1.01 ± 0.34	0.83 ± 0.40	0.87 ± 0.52	0.85 ± 0.46	0.84 ± 0.52	0.91 ± 0.58	0.88 ± 0.55
p Value	.3356	.4692	.5560	.5118	.6001	.6073	.4247	.5149	.2956

conventional implant placement in trabecular bone, as can be found, for example, in the human posterior maxilla.<sup>21</sup>

A statistically significant correlation between the cutting torque resistance of the implant penetrating the crestal portion of the compacted implant site and resonance frequency analysis has been demonstrated.<sup>21</sup>

However, tapping of the expansion osteotomies with the hand mallet represents the greatest inconvenience of the technique, and in some cases, it may induce BPPV in patients who have experienced no previous episodes of this form of vertigo.<sup>9,22</sup>

In this study, two patients suffered vertigo when trying to sit up immediately after surgery and were diagnosed with BPPV.

Furthermore, incidence of this complication may have been higher. Because implant treatment is increasing in older patients, and because of the widespread use of the bone expansion technique with osteotomes, incidence of BPPV can be expected to increase.

The low force of bending waves produced by the hand hammer (40 daN/2 ms) were found to depend on the density, area moment of inertia, and density-dependent elastic constants of bone.<sup>22</sup> It is important to account for the changes of these parameters along the bone, and along with hyperextension of the neck during the operation, because these practices can displace otoliths.

In the patients of TG, no symptoms and no distress were noted. The probable explanation may be represented by the magnetic wave and the subsequent shock wave, as they are calibrated by the timing of application of the force, inducing axial and radial movements applied on the tip of osteotome with a fast energy of 90 daN/8  $\mu$ s. With this procedure, the trauma to the craniofacial bones is minimized as much as possible, reducing the forces only to the target area.

As reported in this study, the use of magnetic mallet provided essential advantages both for operator and patient in comparison with hand mallet. During surgical procedure, magnetic mallet delivered a more precise control of osteotome of the entry direction (or directionality) of the tip into the bone. This is an important concept because bone is generally formed of parts with different density and that the expander tends to be deflected when it moves from a bone part with a specific density to another bone part with a different density. The handling of the device is very simple because the

**TABLE 3 Predictor Variable versus Gained Alveolar Bone Height**

Technique	Mean Gained Alveolar Bone Height (mm)		
	6-Months Follow-Up	12-Months Follow-Up	24-Months Follow-Up
Electrical mallet (test group)	2.62 ± 1.23	4.11 ± 1.37	4.13 ± 1.12
Hand mallet (control group)	2.75 ± 1.40	4.18 ± 1.19	4.19 ± 1.58
<i>p</i> Value	.1888	.5564	.6078

mechanical oscillations transmitted to the osteotome are transmitted without difficulties to the bone.

Furthermore, this procedure improved the patient comfort avoiding BPPV.

However, further clinical trials are mandatory to evaluate the efficiency of the electrical mallet for osteotome procedure, but these results are encouraging to develop and continue in this methodology.

## REFERENCES

- Javed F, Romanos GE. The role of primary stability for successful immediate loading of dental implants. A literature review. *J Dent* 2010; 38:612–620.
- Turkylmaz I, Tumer C, Ozbek EN, Tozum TF. Relations between the bone density values from computerized tomography, and implant stability parameters: a clinical study of 230 regular platform implants. *J Clin Periodontol* 2007; 34:716–722.
- Saadoun AP, Le Gall MG. Implant site preparation with osteotomes: principles and clinical application. *Pract Periodontics Aesthet Dent* 1996; 8:453–483.
- Basa S, Varol A, Turker N. Alternative bone expansion technique for immediate placement of implants in the edentulous posterior mandibular ridge: a clinical report. *Int J Oral Maxillofac Implants* 2004; 19:554–558.
- Hahn J. Clinical uses of osteotomies. *J Oral Implantol* 1999; 1:23–29.
- Silverstein L, Kurtzman GM, Moskowitz E, Kurtzman D, Hahn J. Aesthetic enhancement of anterior dental implants with the use of tapered osteotomies and soft-tissue manipulation. *J Oral Implantol* 1999; 25:18–22.
- Summers RB. A new concept in maxillary implant surgery: the osteotome technique. *Compendium* 1994; 15:152–160.
- Summers RB. The osteotome technique: part 2 – the ridge expansion osteotomy (REO) procedure. *Compendium* 1994; 15:422–434.
- Peñarrocha-Diogo M, Rambla-Ferrer J, Perez V, Pérez-Garrigues H. Benign paroxysmal vertigo secondary to placement of maxillary implants using the alveolar expansion technique with osteotomes: a study of 4 cases. *Int J Oral Maxillofac Implants* 2008; 23:129–132.
- Saker M, Ogle O. Benign paroxysmal positional vertigo subsequent to sinus lift via closed technique. *J Oral Maxillofac Surg* 2005; 63:1385–1387.
- Peñarrocha M, Pérez H, García A, Guarinos J. Benign paroxysmal positional vertigo as a complication of osteotome expansion of the maxillary alveolar ridge. *J Oral Maxillofac Surg* 2001; 59:106–107.
- Di Girolamo M, Napolitano B, Arullani CA, Bruno E, Di Girolamo S. Paroxysmal positional vertigo as a complication of osteotome sinus floor elevation. *Eur Arch Otorhinolaryngol* 2005; 262:631–633.
- Nedir R, Bischof M, Vazquez L, Nurdin N, Szmukler-Moncler S, Bernard JP. Osteotome sinus floor elevation technique without grafting material: 3-year results of a prospective pilot study. *Clin Oral Implants Res* 2009; 20:701–707.
- Cavicchia F, Bravi F, Petrelli G. Localized augmentation of the maxillary sinus floor through a coronal approach for the placement of implants. *Int J Periodontics Restorative Dent* 2001; 21:475–485.
- Rosen PS, Summers R, Mellado JR, Salkin LM, Shanaman RH, Marks MH. The bone-added osteotome sinus floor elevation technique: multicenter retrospective report of consecutively treated patients. *Int J Oral Maxillofac Implants* 1999; 14:853–858.
- Summers RB. Sinus floor elevation with osteotomes. *J Esthet Dent* 1998; 10:164–171.
- Leonetti JA, Rambo HM, Thronsdon RR. Osteotome sinus elevation and implant placement with narrow size bioactive glass. *Implant Dent* 2000; 9:177–182.
- Bragger U, Gerber C, Joss A, et al. Patterns of tissue remodeling after placement of ITI dental implants using an osteotome technique: a longitudinal radiographic case cohort study. *Clin Oral Implants Res* 2004; 15:158–166.
- Nkenke E, Kloss F, Schultze-Mosgau S, Radespiel-Troger M, Loos K, Neukam FW. Histomorphometric and fluorescence microscopic analysis of bone remodelling after installation of implants using an osteotome technique. *Clin Oral Implants Res* 2002; 13:595–602.
- de Oliveira RR, Novaes AB Jr, Taba M Jr, de Souza SLS, Papalexou V. The effect of bone condensation and crestal preparation on the bone response to implants



- designed for immediate loading: a histomorphometric study in dogs. *Int J Oral Maxillofac Implants* 2007; 22:63–71.
21. Friberg B, Sennerby L, Meredith N, Lekholm U. A comparison between cutting torque and resonance frequency measurements of maxillary implants. A 20-month clinical study. *Int J Oral Maxillofac Surg* 1999; 28:297–303.
22. Cheng S, Timonen J, Suominen H. Elastic wave propagation in bone in vivo: methodology. *J Biomech* 1995; 28:471–478.

Copyright of Clinical Implant Dentistry & Related Research is the property of Wiley-Blackwell and its content may not be copied or emailed to multiple sites or posted to a listserv without the copyright holder's express written permission. However, users may print, download, or email articles for individual use.