

Plasma Rich in Growth Factors Improves Patients' Postoperative Quality of Life in Maxillary Sinus Floor Augmentation: Preliminary Results of a Randomized Clinical Study

Massimo Del Fabbro, BSc, PhD;* Stefano Corbella, DDS, PhD;† Valentina Ceresoli, MSc;‡ Caterina Ceci, MSc;§ Silvio Taschieri, MD, DDS§

ABSTRACT

Purpose: The control of postoperative discomfort may improve the patient's quality of life as well as treatment acceptance. The aim of the present preliminary report was to assess if the use of autologous platelet concentrate during maxillary sinus augmentation may have a favorable impact on pain and other factors related to patient's quality of life in the first week after surgery.

Materials and Methods: This is an interim report of a randomized single-blind study. Fifteen patients with atrophic edentulous posterior maxilla underwent maxillary sinus augmentation using deproteinized bovine bone matrix (DBBM) as the grafting material (control group). In other 15 patients (test group), autologous plasma rich in growth factors (P-PRP) was added to DBBM, then a P-PRP clot was applied to covering the graft before suturing and finally P-PRP was placed over the suture in liquid form. During the first week postsurgery, all patients filled in a questionnaire for evaluation of main symptoms and daily activities. The outcomes of the questionnaires of the two groups were statistically compared.

Results: In the first days postsurgery, the group using P-PRP reported significantly less pain, swelling, and hematoma, and improved functional activities with respect to the control group.

Conclusions: The adjunct of P-PRP to the maxillary sinus augmentation procedure produced a beneficial effect to patients' quality of life in the early postsurgical phase.

KEY WORDS: growth factors, maxillary sinus augmentation, platelet concentrate, quality of life, sinus grafting

*Academic researcher, Department of Biomedical, Surgical and Dental Sciences, Università degli Studi di Milano, Milan, Italy; Dental Clinic, IRCCS Istituto Ortopedico Galeazzi, Milan, Italy; and director of Research Center in Oral Health, Università degli Studi di Milano, Milan, Italy; †visiting professor, Department of Biomedical, Surgical and Dental Sciences, Università degli Studi di Milano, Milan, Italy, and Dental Clinic, IRCCS Istituto Ortopedico Galeazzi, Milan, Italy; ‡PhD student, Department of Biomedical, Surgical and Dental Sciences, Università degli Studi di Milano, Milan, Italy, and Dental Clinic, IRCCS Istituto Ortopedico Galeazzi, Milan, Italy; §PhD student, Department of Biomedical, Surgical and Dental Sciences, Università degli Studi di Milano, Milan, Italy; Dental Clinic, IRCCS Istituto Ortopedico Galeazzi, Milan, Italy; and Research Center in Oral Health, Università degli Studi di Milano, Milan, Italy

Reprint requests: Dr. Massimo Del Fabbro, IRCCS Istituto Ortopedico Galeazzi, Via Riccardo Galeazzi, 4, 20161 – Milan, Italy; e-mail: massimo.delfabbro@unimi.it

© 2013 Wiley Periodicals, Inc.

DOI 10.1111/cid.12171

The maxillary sinus floor augmentation is an oral surgical procedure that allows to extend implant-supported rehabilitation to patients with atrophic posterior maxilla. Autogenous bone has long been considered the gold standard grafting material because of its osteoinductive, osteogenic, and osteoconductive properties. Over the years, several modifications to the original protocol have been carried out in order to improve the predictability of clinical outcomes and, at the same time, to reduce donor site morbidity. In fact, many bone substitutes have been introduced in order to provide a scaffold for optimal bone growth and to limit the need for a second surgical site, saving the patients from demanding harvesting procedures.^{1–7}

In particular, various types of allografts, xenografts, and alloplastic materials have been used, alone or in combination with autogenous bone, to simplify the

grafting phase and to minimize the patient's discomfort.^{1,4,5} Independent of the surgical procedure or the graft material, various types of complications may occur during and after the sinus elevation procedure with lateral approach. Schneiderian membrane perforation, infection-related sequelae, nose bleeding, postoperative pain, swelling, and hematoma can have a severe impact on patients' quality of life and could be considered as drawbacks for this treatment.⁸⁻¹³

The use of platelet concentrates as an aid to soft and hard tissue regeneration procedures, due to the massive release of growth factors contained in the platelet granules, is becoming popular in oral and maxillofacial surgery. Several clinical studies in the dental literature claimed the efficacy of platelet concentrates in enhancing healing of bone and soft tissues.¹⁴⁻¹⁷ However, some studies on sinus augmentation reported no significant effect of platelet concentrates on bone graft healing, while suggesting that, due to their mechanical and cohesive properties, they can be beneficial to graft handling, to sinus membrane elevation procedure, to the management of sinus membrane perforation, as well as to improve soft tissue healing and to reduce patient's postoperative discomfort.¹⁵⁻¹⁸

A recent literature review showed that a clear advantage of platelet concentrates in accelerating graft healing in maxillary sinus augmentation procedure could not be evidenced and claimed for a standardization in the experimental design in order to detect the true effect of platelet concentrates, especially regarding postoperative quality of life.¹⁸ In fact, as evidenced by such review, reduced pain and swelling, as well as improved soft tissue healing and less formation of hematoma and other typical postoperative signs were sporadically reported but not systematically assessed.¹⁸

Perioperative pain management is fundamental in any surgical procedure for preserving the patient's psychological welfare. Reducing pain-related discomfort in the immediate postoperative period may significantly enhance the quality of life of the patient and increase treatment acceptance.¹⁹

A recent randomized clinical trial on endodontic surgery showed that autologous leukocyte-poor platelet-rich plasma (P-PRP) may have a beneficial effect on pain, swelling, and other common postoperative signs and symptoms in the postoperative stage.²⁰

The aim of this clinical trial was to assess if the use of plasma rich in growth factors associated with

xenogenic bone grafting during maxillary sinus augmentation procedures may have a favorable impact on the quality of life of the patients in the postoperative period.

MATERIALS AND METHODS

The study was approved by the Review Board of the IRCCS Istituto Ortopedico Galeazzi, Milan, Italy. The study was conducted following the principles embodied in the Helsinki Declaration of 1975 for biomedical research involving human subjects as revised in 2000.²¹ All patients were informed about the study protocol and signed an informed consent form before beginning the study.

Patients were selected from those attending the Dental Clinic of the IRCCS Istituto Ortopedico Galeazzi in Milan, Italy.

Inclusion criteria for the study were:

- absence of systemic conditions that represent a relative or absolute contraindication to surgical intervention (American Society of Anesthesiologists ASA-1 or ASA-2)
- presence of atrophic edentulous posterior maxilla with a residual bone height <5 mm at the intended implant site.
- nonsmokers or mild smokers (less than 10 cigarettes per day)
- able to understand and sign the informed consent

Exclusion criteria for the study were:

- patients with acute or chronic sinusitis
- any systemic condition or chronic pharmacological therapy that may interfere with the healing process
- inability or unwillingness to regularly attend the scheduled follow-up visits
- inability or unwillingness to maintain a proper oral hygiene regimen throughout the study

A total of 30 patients meeting the inclusion criteria were recruited for the present interim evaluation. All patients underwent maxillary sinus floor elevation by using the lateral approach from March 2011 to December 2012. A single experienced surgeon (S.T.) performed all surgical operations.

General Study Design and Hypothesis

Through computer-aided randomization, the subjects were allocated to two groups of the same size. In the test

group, the graft was composed of a combination of deproteinized bovine bone and plasma rich in growth factors (P-PRP), while in the control group only deproteinized bovine bone was used. Six to eight months after sinus surgery, the patients underwent a second surgical step, in which dental implants with a length of 10 mm or more were placed. The prosthetic rehabilitation occurred 4 months after implant placement.

The null hypothesis of the study was of no difference in clinical and radiographic outcomes up to 5 years of function as well as in postoperative quality of life and general patient satisfaction between the two groups. The present report aims at assessing the null hypothesis of no difference in the postoperative quality of life between groups. Based on sample size calculation and assuming a 10% dropout rate, it was planned to enroll at least 15 patients for each treatment group, in order to detect a 10% difference between the two groups in postoperative pain (that was considered the most important symptom affecting quality of life), with a power of 0.8 and a significance level equal to 0.05. It was assumed that the 10% difference between groups had to be evident in the first 2 days after surgery, when usually there is the peak of postoperative pain.

Treatment Protocol

Presurgical assessment through clinical and radiological investigations by computed tomography (CT) scans served to evaluate the presence of edentulous posterior maxilla atrophy that had to fit with the inclusion criteria (less than 5 mm of residual bone height). All patients were prescribed to rinse with 0.2 chlorhexidine solution (10 mL) for 1 minute, twice a day, for 3 days before surgical intervention.

Local anesthesia was administered with the use of articaine 4% and epinephrine 1:100,000. A trapezoidal flap was elevated with one horizontal incision in the middle portion of edentulous mucosa of posterior maxilla and two vestibular vertical incisions extending beneath the mucogingival junction. A periosteal incision was performed if needed to reduce tensile stresses to the flap. After the elevation of the full-thickness mucoperiosteal flap, the lateral sinus wall was exposed and its extension detected referring to previously taken CT scans.

An elliptic window in the sinus wall was created with the use of a piezoelectric device through careful

abrasion of bone wall. Then, the initial detachment of the Schneiderian membrane started from the mesial wall and then from the distal one using specific sinus membrane elevators. The procedure continued until the membrane detachment was sufficient to place the grafting material.

In the *test group* deproteinized bovine bone matrix (DBBM) (Bio-Oss®, Geistlich Pharma, Wolhusen, Switzerland) combined with activated liquid fraction of leukocyte-poor platelet-rich plasma (P-PRP) was used to fill in the cavity. A clot of P-PRP was used to cover and protect the window created in the sinus wall. The preparation of P-PRP was described elsewhere.^{20,22} Briefly, P-PRP was prepared in 9 mL citrated tubes from patient's blood, by centrifugation at 580 g for 8 minutes at room temperature, according to the manufacturer's instructions (Plasma Rich in Growth Factors, PRGF-Endoret®, BTI Biotechnology Institute, Vitoria, Spain). The milliliter fraction located just above the sedimented red cells, but not including the buffy coat, was collected and then activated with CaCl a few minutes before use.^{16,17,20}

In the *control group*, only DBBM was used to fill in the cavity. No membranes were placed over the graft. Afterwards, the flap was repositioned and sutured. Patients were instructed to avoid any activity that will abruptly raise or lower pressure in the sinus cavity for 10 days postsurgery as: sneeze with mouth closed, blow the nose, fly on an airplane, suck through a straw, go swimming, do diving, blow up balloons or play a wind instrument for 10 days.

Furthermore, patients were instructed to avoid vigorous mouth rinsing, hard and hot food, strenuous exertion, smoking and touching the gums for at least 3 days following surgery.

Patients were instructed to gently rinse with a 0.2% chlorhexidine digluconate solution twice a day for 10 days for plaque control. All patients were prescribed nonsteroidal analgesics for pain relief and swelling control to be self-administered in case of need (ibuprofen 600 mg twice/day). Antibiotic therapy with amoxicillin 1 g twice a day for 6 days was prescribed to all patients.

Parameters Evaluation

An ad hoc-prepared questionnaire was given to the patients with a minimum set of instructions on how to fill it up, in order to minimize the effect of the operator

opinions and wills. The questionnaire was similar to that adopted in previous studies.^{20,23} It evaluated postoperative limitations in daily functions (mouth opening, chewing, speaking, sleeping, daily routine, and missed work/school) as well as pain and other symptoms (swelling, bleeding, nausea, bad taste/breath). Pain was assessed adopting a visual analogue scale (VAS) from 0 (no pain) to 100 (the worst possible pain), as in previous studies.^{20,23} For the other items the answers were based on a 5-point Likert-type scale, ranging from 0 (none) to 4 (very much). Patients also had to declare whether they had taken any analgesics on each postoperative day. Patients were asked to fill out the questionnaire daily, starting from the day of surgery, for 1 week. In order not to influence the compilation of the questionnaire, patients were not informed of the possible effect of the platelet concentrate regarding pain and swelling control. Questionnaires were returned at the visit for suture removal, 1 week after surgery. Each questionnaire was blind-coded and progressively numbered, so that the patient's name did not appear. Only the principal investigator (M.D.F.) was aware of the relationship between codes and patients.

Statistical Analysis

The statistician was blinded to groups. The Fisher's exact test was used to evaluate the difference between groups for analgesics taken and for any variable related to function (e.g., chewing, sleeping, speaking) and symptoms (e.g., swelling, nausea, bad taste/breath) on each postoperative day. Regarding pain experience, the Shapiro-Wilk test was used to assess normality of the VAS scores distribution. The Friedman test was used to assess within-group differences in pain scores over time. The between-group difference for pain on each day postsurgery was evaluated by using the Kolmogorov-Smirnov test. The patient was the unit of analysis. The level of significance was set at a probability of $p = .05$. The software OriginPro 8.5.1 (OriginLab Corporation, Northampton, MA, USA) was used for statistical analysis.

RESULTS

A total of 30 patients (18 females and 12 males) were included in the study, 15 in the test group and 15 in the control group. The mean age was 52.3 ± 11.6 years (range 37–66 years). There was no significant difference in age and gender distribution between the two groups.

Two patients in the test group and two in the control group were smokers (mean 5.6 cigarettes/day). No significant effect of such variable was found on the postoperative outcomes. All patients duly returned the questionnaire. The residual ridge height was similar in the two groups being 3.9 ± 1.3 mm and 4.1 ± 1.1 mm in the test and control group, respectively.

One Schneiderian membrane perforation occurred intrasurgically in patients of the test group and two in the control group. The perforations were less than 5 mm large. In the case belonging to the test group, the perforation was managed using a P-PRP membrane, with a technique described previously.²² In the two other cases, it was managed by further detaching and folding the sinus membrane. In all cases, the surgical procedure was successfully completed and no postoperative consequences were observed in the three patients. The questionnaire scores of the patients with a perforation were perfectly in line with the others of the same group. No further intrasurgical or postsurgical complication occurred.

The distribution of VAS scores for pain assessment was Gaussian for both groups. Figure 1 shows the levels of reported pain over time, represented by mean VAS scores of the two groups. The use of P-PRP resulted in significant reduction of the perceived pain during the second and third postoperative day as compared with the control group. From day 4, the mean VAS scores of the two groups were similar.

Table 1 summarizes the results of the assessment of symptoms and other daily activities in each group. For simplifying table reading, the scores "little" and "none" have been aggregated, although for the statistical evaluation they were kept separated. Significant differences have been evidenced using a gray background. As can be seen, the patients of the group treated with the adjunct of P-PRP reported consistently less swelling, less hematoma, and less discomfort regarding chewing and speaking throughout the evaluation period. For other parameters like mouth opening and sleeping, the use of P-PRP produced a clear benefit in the first 3 to 4 days; thereafter, no relevant discomfort was present in both groups for such parameters. Regarding missed work, no difference between groups was detected. Bleeding was significantly lower in the first 2 days in the group using P-PRP ($p = .01$). In fact, nine patients in the test group against four control patients reported no bleeding at all during the first 24 hours postsurgery. Significantly less

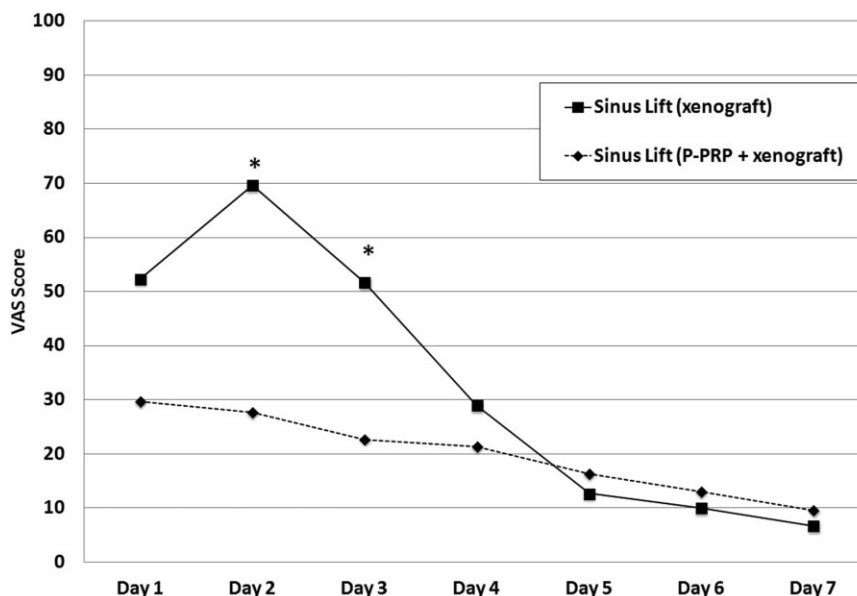


Figure 1 Pain levels during the first week postsurgery in the two groups. The asterisks indicate significant difference ($p < .05$). VAS = visual analogue scale.

patients took analgesics in the P-PRP group as compared with control in the first three days.

DISCUSSION

A number of postoperative early and delayed adverse sequelae have been described and classified for maxillary sinus augmentation procedure.^{8,24} The most common surgery-related adverse events, which often occur in the first days postsurgery and may adversely affect postoperative quality of life and daily activities are: pain at the surgical site, tissue swelling, infection, bleeding, the presence of hematoma that may spread well beyond the zone involved from surgery, difficulty in chewing, sleeping and opening the mouth.

This study evaluated if the use of an autologous platelet concentrate during maxillary sinus surgery could have an effect on patients' reported postoperative quality of life, based on the assessment of the aforementioned adverse events. The results are suggestive of a beneficial effect of the platelet concentrate, as significant improvement in most parameters related to quality of life was observed in the group using platelet concentrates as compared with the control group.

In the past 20 years, the use of autologous platelet concentrates has become popular in a number of medical fields such as dentistry, oral and maxillofacial surgery, orthopedics, sports medicine, dermatology, ophthalmology, cosmetic and plastic surgery. The

rationale for their use stems from the fact that platelets store and release, upon activation, growth factors such as platelet-derived growth factor (PDGF), transforming growth factor-beta, epidermal growth factor, vascular endothelial growth factor, insulin-like growth factor-1, basic fibroblast growth factor, hepatocyte growth factor, as well as other molecules that modulate the wound healing response in both hard and soft tissues.¹⁴⁻¹⁷

A lot of studies on various oral surgical procedures evidenced the beneficial effects of platelet concentrates on the very early stages of soft tissue healing, suggesting that they could markedly decrease postoperative inflammation and pain, with consistent advantages on the postoperative quality of life.^{16-18,25-33} Such effect, however, has rarely been assessed systematically and with an evidence-based approach.

The findings of the present study are in line with a previous randomized study²⁰ that has reported a positive effect of P-PRP in lowering the pain perception and decrease the quantity of analgesics taken and the prevalence of adverse sequelae such as swelling, leading to a lower incidence on patients' normal activities in the first week after endodontic surgery. Though the latter surgical procedure is not as demanding for the patient as the maxillary sinus augmentation, the pain levels observed in the patients of the control groups of the present and the above study are rather comparable.

TABLE 1 Quality of Life Questionnaire Responses during the First Week after Surgery (Test vs Control Group)

	Day 1		Day 2		Day 3		Day 4		Day 5		Day 6		Day 7	
	C	T	C	T	C	T	C	T	C	T	C	T	C	T
<i>Mouth opening</i>	*		*											
Very much	4	1	3	1	0	0	0	0	0	0	0	0	0	0
Quite a bit	2	0	3	1	6	1	0	0	0	0	0	0	0	0
Some	6	4	0	0	0	0	6	1	1	0	1	0	0	0
Little/None	3	10	9	13	9	14	9	14	14	15	14	15	15	15
<i>Chewing</i>	*		*		*		*		*		*		*	
Very much	9	1	9	1	5	0	2	0	2	0	2	0	2	0
Quite a bit	6	3	6	2	8	2	7	0	6	0	5	0	1	0
Some	0	7	0	4	2	3	4	3	5	2	5	1	7	1
Little/none	0	4	0	8	0	10	2	12	2	13	3	14	5	14
<i>Speaking</i>	*		*											
Very much	2	0	1	0	0	0	0	0	0	0	0	0	0	0
Quite a bit	3	0	6	0	1	0	0	0	0	0	0	0	0	0
Some	8	3	1	2	4	1	3	1	1	1	1	1	1	1
Little/None	2	12	7	13	10	14	12	14	14	14	14	14	14	14
<i>Sleeping</i>	*		*		*									
Very much	0	0	0	1	0	1	0	0	0	0	0	0	0	0
Quite a bit	1	2	1	0	0	0	0	0	0	0	0	0	0	0
Some	14	0	9	0	5	0	3	0	3	0	3	0	3	0
Little/None	0	13	5	14	10	14	12	15	12	15	12	15	12	15
<i>Missed work</i>														
Yes	13	9	10	7	7	6	7	3	4	2	0	2	0	2
No	2	6	5	8	8	9	8	12	11	13	15	13	15	13
<i>Daily activities</i>	*		*											
Very much	0	0	0	0	0	0	0	0	0	0	0	0	0	0
Quite a bit	5	4	2	2	0	0	0	0	0	0	0	0	0	0
Some	10	3	10	3	9	6	2	0	2	0	2	0	2	0
Little/none	0	8	3	10	6	9	13	15	13	15	13	15	13	15
<i>Swelling</i>	*		*		*		*		*		*		*	
Very much	2	2	9	1	7	2	2	1	2	0	0	0	0	0
Quite a bit	9	6	3	5	5	3	6	1	5	1	3	0	2	0
Some	2	3	1	5	1	3	5	2	5	1	8	2	2	0
Little/None	2	4	2	4	2	7	2	11	3	13	4	13	11	15
<i>Bad taste/breath</i>														
Very much	0	0	0	0	0	0	0	0	0	0	0	0	0	0
Quite a bit	0	0	2	1	2	1	0	0	0	0	0	0	0	0
Some	2	0	0	0	0	0	2	0	0	1	0	1	0	0
Little/None	13	15	13	14	13	14	13	15	15	14	15	14	15	15
<i>Bleeding</i>	*													
Very much	0	0	0	0	0	0	0	0	0	0	0	0	0	0
Quite a bit	0	1	0	0	0	0	0	0	0	0	0	0	0	0
Some	2	2	1	2	0	0	0	0	0	0	0	0	0	0
Little/None	13	12	14	13	15	15	15	15	15	15	15	15	15	15
<i>Hematoma</i>	*		*		*		*		*		*		*	
Very much	0	0	5	1	7	1	4	0	0	0	0	0	0	0
Quite a bit	5	3	4	2	3	3	5	0	5	0	4	0	4	0
Some	4	1	6	0	3	0	1	5	3	1	4	2	2	1
Little/None	6	11	0	12	2	11	5	10	7	14	7	13	9	14
<i>Analgesics</i>	*													
Yes	15	9	15	10	13	8	4	1	2	0	2	0	2	0
No	0	6	0	5	2	7	11	14	13	15	13	15	13	15

The shaded areas indicate significant difference between groups ($p < .05$).

* indicates that the difference was highly significant ($p < .01$).

The use of the platelet concentrate in the present study produced a marked beneficial effect regarding the formation of a hematoma and tissue swelling, which are rather boring events, both for the patient's functional limitations and for the esthetic appearance.

In the present study, a leukocyte-poor autologous platelet rich plasma was used, also defined PRGF (plasma rich in growth factors). There is a controversial debate regarding the presence or absence of the leukocytes in the platelet concentrates.^{34–37} Some authors emphasize that leukocytes may be beneficial to preserve the surgical site from infection as they synthesize interleukins involved in the nonspecific immune response.^{38,39} Others state that the battery of hydrolytic enzymes produced by leukocytes might cause an excessive tissue destruction, especially in the early stages of surgery-induced inflammation.⁴⁰ Therefore, some protocols for the preparation of platelet concentrates are designed to leave out the leukocytes, with the intent of avoiding an excess of pro-inflammatory mediators. The protocol adopted in the present study for the preparation of PRGF specifically recommends avoiding contamination with the buffy coat when separating the supernatant fractions after centrifugation. This step aims at obtaining a product with a nonrelevant leukocyte content, thus reducing the presence of cells that might cause a strong immune reaction. This might be related with the attenuated postsurgical symptoms observed in the test group. Furthermore, some of the biological substances released by platelet granules, such as the lysophospholipid sphingosine-1-phosphate, have the property of modulating the permeability of microvessels, which could explain the modest tissue swelling observed in the present study.^{41–43} A protective role of PDGF-BB against tissue edema formation has also been found in an experimental study due to its property of strengthening the link between tissue collagen and fibroblasts.⁴⁴ In addition, a number of clinical and in vitro antibacterial effect of human platelet concentrates have been reported against various bacterial species, which could further contribute to their beneficial effect by protecting tissues against infection, which is not infrequent in the postoperative stage.^{45–54}

The adoption of a questionnaire based on patient's judgment might be debatable due to limited objective evaluation. However, in the last years there has been a widespread agreement on the need of including the patient-reported assessments of their oral health condi-

tion and of the treatment effects in dental research and practice. Such assessments mainly regard the evaluation of the impact of treatments on daily activities and quality of life. A recent systematic review found an increasing use of patient-reported outcome measures in dental implant research for a number of prosthetic treatments.⁵⁵ Such review, however, underlined the failure to adopt standardized outcome assessment methods, which reduces the understanding of the true benefit of implant therapy from patients' perspectives. The present questionnaire, specifically developed by the authors and based on the most common quality of life questionnaire used in oral health research which is OHIP-14,⁵⁶ was similar to that used in previous studies,^{20,23} and considers the main signs and symptoms whose impairment in the postsurgical period may affect patient's welfare.

CONCLUSION

The use of P-PRP during maxillary sinus augmentation procedure improves symptoms and daily activities in the early postsurgical period. This can have a beneficial effect on the patients' quality of life and treatment acceptance. A longer follow-up will allow evaluation if P-PRP may also have a beneficial role on the graft healing and treatment success.

ACKNOWLEDGMENTS

The authors wish to thank Dr. Monica Bortolin and Dr. Alessandra Lolato for their technical help in the preparation of platelet concentrates, as well as Dr. Massimo Saita and Dr. Martina Venegoni for their valuable assistance in clinical procedures.

REFERENCES

1. Del Fabbro M, Testori T, Francetti L, Weinstein R. Systematic review of survival rates for implants placed in grafted maxillary sinus. *Int J Periodont Restorative Dent* 2004; 24: 565–577.
2. Graziani F, Donos N, Needleman I, Gabriele M, Tonetti M. Comparison of implant survival following sinus floor augmentation procedures with implants placed in pristine posterior maxillary bone: a systematic review. *Clin Oral Impl Res* 2004; 15:677–682.
3. Pjetursson BE, Tan WC, Zwahlen M, Lang NP. A systematic review of the success of sinus floor elevation and survival of implants inserted in combination with sinus floor elevation. Part I: lateral approach. *J Clin Periodontol* 2008; 35(Suppl. 8): 216–224.

4. Del Fabbro M, Rosano G, Taschieri S. Implant survival rates after maxillary sinus augmentation. *Eur J Oral Sci* 2008; 116:497–506.
5. Nkenke E, Stelzle F. Clinical outcomes of sinus floor augmentation for implant placement using autogenous bone or bone substitutes: a systematic review. *Clin Oral Implants Res* 2009; 20(Suppl. 4):124–133.
6. Esposito M, Grusovin MG, Rees J, et al. Effectiveness of sinus lift procedures for dental implant rehabilitation: a Cochrane systematic review. *Eur J Oral Implantol* 2010; 3:7–26.
7. Del Fabbro M, Wallace SS, Testori T. Long-term implant survival in the grafted maxillary sinus. A systematic review. *Int J Periodontics Restorative Dent* 2013. (In press).
8. Katranji A, Fotek P, Wang HL. Sinus augmentation complications: etiology and treatment. *Implant Dent* 2008; 17: 339–349.
9. Peleg M, Mazor Z, Garg AK. Augmentation grafting of the maxillary sinus and simultaneous implant placement in patients with 3 to 5 mm of residual alveolar bone height. *Int J Oral Maxillofac Implants* 1999; 14:549–556.
10. Cho-Lee GY, Naval-Gias L, Castrejon-Castrejon S, et al. A 12-year retrospective analytic study of the implant survival rate in 177 consecutive maxillary sinus augmentation procedures. *Int J Oral Maxillofac Implants* 2010; 25:1019–1027.
11. Levin L, Herzberg R, Dolev E, Schwartz-Arad D. Smoking and complications of onlay bone grafts and sinus lift operations. *Int J Oral Maxillofac Implants* 2004; 19:369–373.
12. Rosano G, Taschieri S, Gaudy JF, Lesmes D, Del Fabbro M. Maxillary sinus septa: a cadaveric study. *J Oral Maxillofac Surg* 2010; 68:1360–1364.
13. Rosano G, Taschieri S, Gaudy JF, Weinstein T, Del Fabbro M. Maxillary sinus vascular anatomy and its relation to sinus lift surgery. *Clin Oral Implants Res* 2011; 22:711–715.
14. Marx RE, Carlson ER, Eichstaedt RM, Schimmele SR, Strauss JE, Georgeff KR. Platelet-rich plasma: growth factor enhancement for bone grafts. *Oral Surg Oral Med Oral Pathol Oral Radiol Endod* 1998; 85:638–646.
15. Marx RE. Platelet concentrate: a strategy for accelerating and improving bone regeneration. In: Davies JE, ed. *Bone engineering*. Toronto: Em Squared Inc, 2001:447–453.
16. Anitua E. The use of plasma-rich growth factors (PRGF) in oral surgery. *Pract Proced Aesthet Dent* 2001; 13:487–493.
17. Anitua E, Andia I, Ardanza B, Nurden P, Nurden AT. Autologous platelets as a source of proteins for healing and tissue regeneration. *Thromb Haemost* 2004; 91:4–15.
18. Del Fabbro M, Bortolin M, Taschieri S, Weinstein RL. Effect of autologous growth factors in maxillary sinus augmentation: a systematic review. *Clin Implant Dent Relat Res* 2013; 15:205–216.
19. Iqbal MK, Kratchman SI, Guess GM, Karabucak B, Kim S. Microscopic periradicular surgery: perioperative predictors for postoperative clinical outcomes and quality of life assessment. *J Endod* 2007; 33:239–244.
20. Del Fabbro M, Ceresoli V, Lolato A, Taschieri S. Effect of platelet concentrate on quality of life after periradicular surgery: a randomized clinical study. *J Endod* 2012; 38:733–739.
21. World Medical Association Declaration of Helsinki: ethical principles for medical research involving human subjects. *JAMA* 2000; 284:3043–3045.
22. Taschieri S, Corbella S, Del Fabbro M. Use of plasma rich in growth factor for schneiderian membrane management during maxillary sinus augmentation procedure. *J Oral Implantol* 2012; 38:621–627.
23. Del Fabbro M, Taschieri S, Weinstein R. Quality of life after microscopic periradicular surgery using two different incision techniques: a randomized clinical study. *Int Endod J* 2009; 42:360–367.
24. Li J, Wang HL. Common implant-related advanced bone grafting complications: classification, etiology, and management. *Implant Dent* 2008; 17:389–401.
25. Mozzati M, Martinasso G, Pol R, et al. The impact of plasma rich in growth factors on clinical and biological factors involved in healing processes after third molar extraction. *J Biomed Mater Res A* 2010; 95:741–746.
26. Del Fabbro M, Bortolin M, Taschieri S. Is autologous platelet concentrate beneficial for post-extraction socket healing? A systematic review. *Int J Oral Maxillofac Surg* 2011; 40: 891–900.
27. Cheung WS, Griffin TJ. A comparative study of root coverage with connective tissue and platelet concentrate grafts: 8-month results. *J Periodontol* 2004; 75:1678–1687.
28. El-Sharkawy H, Kantarci A, Deady J, et al. Platelet-rich plasma: growth factors and pro- and anti-inflammatory properties. *J Periodontol* 2007; 78:661–669.
29. Lee CY, David T, Nishime M. Use of platelet-rich plasma in the management of oral bisphosphonate-associated osteonecrosis of the jaw: a report of 2 cases. *J Oral Implantol* 2007; 33:371–382.
30. Rutkowski JL, Fennell JW, Kern JC, Madison DE, Johnson DA. Inhibition of alveolar osteitis in mandibular tooth extraction sites using platelet-rich plasma. *J Oral Implantol* 2007; 33:116–121.
31. Rutkowski JL, Johnson DA, Radio NM, Fennell JW. Platelet rich plasma to facilitate wound healing following tooth extraction. *J Oral Implantol* 2010; 36:11–23.
32. Simon D, Manuel S, Geetha V, Naik BR. Potential for osseous regeneration of platelet-rich plasma—a comparative study in mandibular third molar sockets. *Indian J Dent Res* 2004; 15:133–136.
33. Yen CA, Griffin TJ, Cheung WS, Chen J. Effects of platelet concentrate on palatal wound healing after connective tissue graft harvesting. *J Periodontol* 2007; 78:601–610.
34. Dohan Ehrenfest DM, Rasmusson L, Albrektsson T. Classification of platelet concentrates: from pure platelet-rich plasma (P-PRP) to leucocyte- and platelet-rich fibrin (L-PRF). *Trends Biotechnol* 2009; 27:158–167.

35. Anitua E, Sanchez M, Orive G, Andia I. Shedding light in the controversial terminology for platelet rich products. *J Biomed Mater Res A* 2009; 90:1262–1263.
36. Dohan DM, Choukroun J. PRP, cPRP, PRF, PRG, PRGF, FC. How to find your way in the jungle of platelet concentrates? *Oral Surg Oral Med Oral Pathol Oral Radiol Endod* 2007; 103:305–306.
37. Dohan Ehrenfest DM, Bielecki T, Del Corso M, Inchingolo F, Sammartino G. Shedding light in the controversial terminology for platelet-rich products: platelet-rich plasma (PRP), platelet-rich fibrin (PRF), platelet-leukocyte gel (PLG), preparation rich in growth factors (PRGF), classification and commercialism. *J Biomed Mat Res A* 2010; 95A:1280–1282.
38. Bhanot S, Alex JC. Current applications of platelet gels in facial plastic surgery. *Facial Plast Surg* 2002; 18:27–33.
39. Wrotniak M, Bielecki T, Gazdzik TS. Current opinion about using the platelet-rich gel in orthopaedics and trauma surgery. *Orthop Traumatol Rehabil* 2007; 9:227–238.
40. McCarrel TM, Minas T, Fortier LA. Optimization of Leukocyte concentration in platelet-rich plasma for the treatment of tendinopathy. *J Bone Joint Surg* 2012; 94:e143(1–8). doi: 10.2106/JBJS.L.00019.
41. Nixon GE. Sphingolipids in inflammation: pathological implications and potential therapeutic targets. *Br J Pharmacol* 2009; 158:982–993.
42. Morris AJ, Panchatcharam M, Cheng HY, et al. Regulation of vascular cell function by bioactive lysophospholipids. *J Thromb Haemost* 2009; 7(Suppl. 1):38–43.
43. Adamson RH, Sarai RK, Altangerel A, Thirkill TL, Clark JF, Curry F-RE. Sphingosine-1-phosphate modulation of basal permeability and acute inflammatory responses in rat venular microvessels. *Cardiovasc Res* 2010; 88:344–351.
44. Rodt SÅ, Åhlén K, Berg A, Rubin K, Reed RK. A novel physiological function for platelet-derived growth factor-BB in rat dermis. *J Physiol* 1996; 495:193–200.
45. Cieslik-Bielecka A, Bielecki T, Gazdzik TS, Arendt J, Krol W, Szczepanski T. Autologous platelets and leukocytes can improve healing of infected high-energy soft tissue injury. *Transfus Apher Sci* 2009; 41:9–12.
46. Everts PA, Devilee RJ, Brown Mahoney C, et al. Platelet gel and fibrin sealant reduce allogeneic blood transfusions in total knee arthroplasty. *Acta Anaesthesiol Scand* 2006; 50: 593–599.
47. Trowbridge CC, Stammers AH, Woods E, Yen BR, Klayman M, Gilbert C. Use of platelet gel and its effects on infection in cardiac surgery. *J Extra Corpor Technol* 2005; 37:381–386.
48. Yuan T, Zhang CQ, Zeng BF. Treatment of chronic femoral osteomyelitis with platelet-rich plasma (PRP): a case report. *Transfus Apher Sci* 2008; 38:167–170.
49. Anitua E, Alonso R, Girbau C, Aguirre JJ, Murozabal F, Orive G. Antibacterial effect of plasma rich in growth factors (PRGF-Endoret) against *Staphylococcus aureus* and *Staphylococcus epidermidis* strains. *Clin Exp Dermatol* 2012; 37: 652–657.
50. Álvarez ME, López C, Giraldo CE, Samudio I, Carmona JU. In vitro bactericidal activity of equine platelet concentrates, platelet poor plasma, and plasma against methicillin-resistant *Staphylococcus aureus*. *Arch Med Vet* 2011; 43: 155–161.
51. Bielecki TM, Gazdzik TS, Arendt J, Szczepanski T, Krol W, Wielkoszynski T. Antibacterial effect of autologous platelet gel enriched with growth factors and other active substances: an in vitro study. *J Bone Joint Surg Br* 2007; 89:417–420.
52. Burnouf T, Chou ML, Wu YW, Su CY, Lee LW. Antimicrobial activity of platelet (PLT)-poor plasma, PLT-rich plasma, PLT gel, and solvent/detergent-treated PLT lysate biomaterials against wound bacteria. *Transfusion* 2013; 53:138–146.
53. Moojen DJ, Everts PA, Schure RM, et al. Antimicrobial activity of platelet-leukocyte gel against *Staphylococcus aureus*. *J Orthop Res* 2008; 26:404–410.
54. Drago L, Bortolin M, Vassena C, Taschieri S, Del Fabbro M. Antimicrobial activity of pure platelet-rich plasma against microorganisms isolated from oral cavity. *BMC Microbiol* 2013; 13:47.
55. McGrath C, Lam O, Lang N. An evidence-based review of patient-reported outcome measures in dental implant research among dentate subjects. *J Clin Periodontol* 2012; 39(Suppl. 12):193–201.
56. Slade GD. Derivation and validation of a short-form oral health impact profile. *Community Dent Oral Epidemiol* 1997; 25:284–290.

Copyright of Clinical Implant Dentistry & Related Research is the property of Wiley-Blackwell and its content may not be copied or emailed to multiple sites or posted to a listserv without the copyright holder's express written permission. However, users may print, download, or email articles for individual use.