

Preliminary Report on the Outcome of Tilted Implants with Longer Lengths (20–25 mm) in Low-Density Bone: One-Year Follow-Up of a Prospective Cohort Study

Paulo Maló, DDS, PhD;* Miguel de Araújo Nobre, RDH, MSc Epi;† Armando Lopes, DDS;* Rolando Rodrigues, DDS‡

ABSTRACT

Purpose: The aim of this preliminary study was to report on the short-term outcome of tilted implants with 20 to 25 mm of length in immediate function with bicortical anchorage for prosthetic rehabilitation of complete edentulous jaws with low-density bone.

Material and Methods: Sixteen patients (with 25 study implants and 43 nonstudy implants) presenting low-density bone were included in a prospective single cohort study to evaluate the short-term outcome of partial and complete edentulous rehabilitations using implants with 20 to 25 mm of length (NobelSpeedy Groovy, Nobel Biocare AB, Gothenburg, Sweden) in immediate function with bicortical anchorage (maxilla: alveolar ridge and nasal corticals; mandible: mandibular corticals). The patients were followed between 6 and 26 months (average of 14 months). Outcome measures were implant survival, marginal bone remodeling, biological and mechanical complications assessed at 10 days, 2, 4, and 6 months, 1-year posttreatment, and thereafter every 6 months.

Results: Two patients with four implants were lost to follow-up after 6 and 11 months. There were no implant failures, rendering a cumulative implant survival rate of 100%. The average marginal bone remodeling was 0.50 mm (SD = 0.34 mm) and 0.86 mm (SD = 0.46 mm), after 6 months and 1 year, respectively. There was one mechanical complication in one patient (abutment loosening) 1 month post-surgery.

Conclusion: Within the limitations of this study, the short-term outcome of prosthetic rehabilitations of patients with low-density bone using implants of 20 to 25 mm in length in immediate function with bicortical anchorage is viable judging by the high implant survival rate, low marginal bone remodeling, and low incidence of complications. Long-term evaluation of these implants through studies using a prospective design is mandatory.

KEY WORDS: edentulous maxilla, immediate function, implant design

INTRODUCTION

During many years, healing periods of 3 to 6 months combined with two-stage procedures were considered essential for osseointegration of dental implants.

However, the evolution of implant surfaces and designs,¹ and modified surgical and loading protocols have demonstrated similar outcomes over time.² Taking into consideration the loading regimen,³ no statistically significant differences were found for prosthesis success, implant success and marginal bone levels between different loading regimens. Regarding one versus two stage implant surgical approach, especially in fully edentulous patients, the findings of Esposito and colleagues (2009)⁴ states that the one-stage approach might even be preferable since it avoids one surgical intervention and shortens treatment times, although more studies are needed to make a consistent statement. Furthermore, it

*Oral Surgery Department, Malo Clinic, Lisbon, Portugal; †Research and Development Department, Malo Clinic Lisbon, Portugal; ‡Prosthodontics Department, Malo Clinic Lisbon, Portugal

Reprint requests: Professor Paulo Maló, Malo Clinic, Avenida dos Combatentes, 43, Lisbon 1600-042, Portugal; e-mail: research@maloclinics.com

© 2013 Wiley Periodicals, Inc.

DOI 10.1111/cid.12144

was also stated that in the case of implant initial stability with more than 32 Ncm of torque, one-stage or immediate loading protocols are considered safe approaches for rehabilitation.⁴

Still, the question remains unanswered when less bone quality, less bone quantity and the anatomic localization of the implant is unfavorable, since higher implant failure rates are associated.⁵

Numerous approaches (including bone substitute materials and techniques such as the sinus lift) have been tested to overcome the challenge of rehabilitating areas affected by limited quantity and low-density bone.^{6–8} However, the results do not fully support these therapeutic options, even if they remain largely used among dental practitioners.⁹ Therefore, other rehabilitation approaches less invasive to the patient have been used to avoid the surgical elevation of the sinus and proved to be good solution.^{10–13} When rehabilitating the maxilla, studies comparing the outcome of using shorter implant lengths or diameters versus sinus lift and bone graft followed by longer implants, demonstrated that bone augmentation procedures are technically more demanding and with the similar or even lower implant success rates.^{9,13,14}

However, it should be taken into consideration that the crestal portion of the implant body load-bearing capacity, the pattern of distribution of prosthetic loads to the bone-implant interface, the poor bone density of the atrophic jawbone, and the restorations' augmented crown height associated to the use of short implants may represent important risk factors for long-term survival.^{15–17}

The relationship between implant length and success rates is yet unclear.^{18–20} Nevertheless it was observed that an increased implant length results in stress reduction on the implant in both immediate and delayed loading and that increasing the implant length from 10 mm to 14 mm results in strain reduction on bone tissue during immediate and delayed implant loading.¹⁸ In these situations, the maximum stress concentration occurred at the abutment-implant interface. These biomechanical results find parallel in the literature, where Kinsel and Liss¹⁹ reported reduced implant length as a predictor for implant failure. The findings of Renouard and Nisan²⁰ support the need for further studies to investigate the relationships between bone density, implant length, diameter, and survival rates that are more dependent of a learning curve and adapted surgical protocols.

The use of tilted implants is described in the literature as an alternative approach for rehabilitation of atrophic jaws. The technique for placement of tilted implants is described when rehabilitating patients with partial²¹ and total edentulism in the maxilla.^{21–24}

The tilting of the posterior implants allows placement of longer implants, enhancing the area of contact between bone and implant, and thus enhancing the primary anchorage; the implant support is moved posteriorly; the desired position of the implants is determined under the prosthetic point of view; a greater distance between implants, allowing the elimination or decreasing of cantilevers in the prosthesis, resulting in a better load distribution; a favorable interimplant distance; and the placement of implants in residual bone, avoiding more complex techniques of bone graft and/or sinus lift.^{21,22,24,25}

When rehabilitating the edentulous jaws using implants in immediate function, the bone density plays an important role. Frequently, poor bone quality is cited as cause for dental implant failure.^{26,27} An alternative to maximize the success of the rehabilitation could be to insert the implants between two cortical layers (maxillary and nasal cortical layers, or the inferior mandibular basal layer) using implant tilting. However, in the majority of situations, the insertion of posterior implants through this technique is not possible due to the limited length of the implants, even with 18 mm of length.

The aim of this preliminary study was to report on the short-term outcome of standard implants with 20 to 25 mm of length in immediate function with bicortical anchorage for prosthetic rehabilitation of complete edentulous jaws with low-density bone.

MATERIAL AND METHODS

This study was approved by a local Ethical Committee (Approval n°017/2010). In this prospective cohort study, 18 patients (9 male and 7 female) with an average age of 62 years (age range: 33 to 82 years) with complete edentulous arches ($n = 17$) with low-density bone that were consecutively included and treated in a private practice (Malo Clinic, Lisbon, Portugal), considered the patients consent to participate in the study. Inclusion criteria were need of a complete edentulous fixed prosthetic rehabilitation, supported by implants in immediate function; a low bone density determined preoperatively; and a bone atrophy that made it mandatory to use tilted implants of longer length to be able to install

TABLE 1 Implant Characteristics and Positions

	Implant Position							
	15	16	17	24	25	26	45	Total
Diameter and Length								
4 mm × 20 mm	5	2	0	0	5	4	0	16
4 mm × 22 mm	2	0	1	0	2	1	1	7
4 mm × 25 mm	1	0	0	0	0	0	0	1
5 mm × 25 mm	0	0	0	1	0	0	0	1
Total	8	2	1	1	7	5	1	25

the most posterior implant using bicortical anchorage. The medical history and clinical observations were recorded and panoramic radiographs and cone beam computerized tomography (Kodak 9500, New York, NY, USA) were examined. From the 18 patients, 8 presented a compromised situation (6 patients with cardiovascular problems, 1 patient with osteoporosis, and 1 patient was immune compromised).

A total of 25 implants (NobelSpeedy Groovy; Nobel Biocare AB, Gothenburg, Sweden) with 20 to 25 mm of length and an oxidized surface (TiUnite; Nobel Biocare AB) were placed between September 2010 and December 2011 and were followed between 6 months and 26 months (average of 14 months). Twenty-four implants were placed in the maxilla and one implant in the mandible, supporting 17 fixed prostheses (16 complete edentulous restorations in the maxilla and 1 complete edentulous restoration in the mandible). The complete edentulous rehabilitations featured one posterior tilted implant with 20 to 25 mm of length (study implant) and three nonstudy implants ($n = 8$ patients with 9 rehabilitations), or two posterior tilted implants with 20 to 25 mm of length (study implants) and two anterior nonstudy implants ($n = 8$ patients and rehabilitations). The opposing dentitions were implant supported prosthesis ($n = 4$ patients), natural teeth ($n = 2$ patients), or a combination of both ($n = 10$). Implant positions and characteristics are described in Table 1.

Surgical Protocol

The surgical procedures were performed by two surgeons (P.M. and A.L.) under local anesthesia: articaine chlorhydrate (72 mg/1.8 ml) with epinephrine (0.018 mg/1.8 ml) 1:100,000 (Artinibsa® 2%, Inibsa Laboratory, Barcelona, Spain). All patients were sedated with diazepam (Valium® 10 mg, Roche, Amadora, Portugal) prior to surgery. Antibiotics (amoxicillin

875 mg + clavulanic acid 125 mg, Labesfal, Campo de Besteiros, Portugal) were given 1 hour prior to surgery and daily for 6 days thereafter (thrice daily in the first 3 days and twice a day on the remaining days). Cortisone medication (prednisone 5 mg, Meticorten®, Schering-Plough Farma, Agualva-Cacem, Portugal) was given daily in a regression mode (15 mg to 5 mg) from the day of surgery until 4 days postoperatively (15 mg on the day of surgery, 10 mg on days 1 and 2 post-surgery, and 5 mg on days 3 and 4 post-surgery). Anti-inflammatory medication (ibuprofen 600 mg twice a day, Ratiopharm, Carnaxide, Portugal) was administered for 4 days postoperatively starting on day 4. Analgesics (clonixine 300 mg, Clonix®, Janssen-Cilag Farmaceutica, Barcarena, Portugal) were given on the day of surgery and postoperatively for the first 3 days if needed. Antacid medication (Omeprazole, 20 mg once a day, Lisbon, Portugal) was given on the day of surgery and daily for 6 days postoperatively.

A mucoperiosteal flap was raised at the ridge crest with relieving incisions on the buccal aspect in the molar area for the total rehabilitations.

For the maxillary rehabilitations, a small window was opened to the sinus using a round bur for identification of the exact position of the anterior sinus wall. The implants and abutments were placed in one position at a time, starting always with the posterior ones. A special guide (edentulous guide, Nobel Biocare AB) was used to assist implant and abutment placement. This guide was placed into a 2 mm osteotomy made at the midline of the jaw and the titanium band was bent so that the occlusal centerline of the opposing jaw was followed.

The insertion of the implants followed standard procedures, except that under-preparation was used to achieve an insertion torque of at least 35 Ncm before final seating of the implant. The preparation was

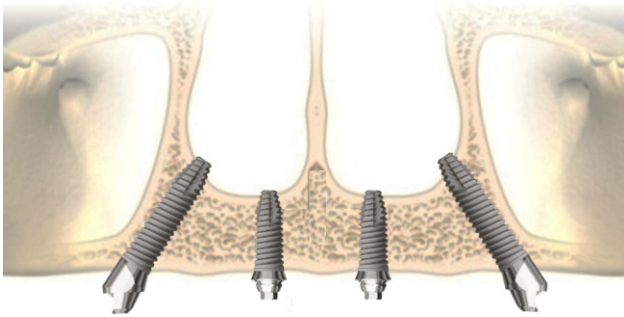


Figure 1 Establishing a bicortical anchorage at implant insertion using the maxillary and nasal corticals.

typically performed by full drill depth with a 2 mm twist drill followed by twist/step drills according to the manufacturer's protocol.²³ The implant head (NobelSpeedy Groovy implants) was aimed to be positioned at bone level, and bicortical anchorage was established in both arches, using the maxilla and nasal corticals to anchor the implant in the upper jaw (Figure 1).

The long implants had 4 mm diameter, their length ranged from 20 to 25 mm and were tilted distally following the anterior sinus wall or anterior to the mental foramen up to 45 degrees of inclination. Thirty-degree angulated abutments (Multi-unit abutments, Nobel Biocare AB) were connected to the implant correcting the inclination to a maximum of 15 degrees. Tilting the posterior implant made it possible to position the implant head in the second premolar/first molar region instead of in the canine/first premolar region in the case of a vertically placed posterior implant.

The axial implants were oriented vertically by a guide pin, and care was taken in the selection of the anterior implant length and positions to not come in conflict with the apex of the tilted posterior implants,

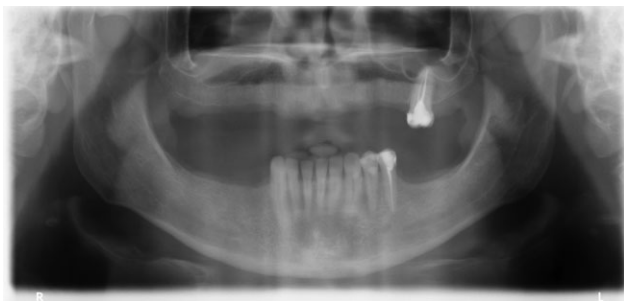

Figure 2 Preoperative orthopantomography of a complete edentulous maxillary rehabilitation using NobelSpeedy implants with 20 to 25 mm of length.

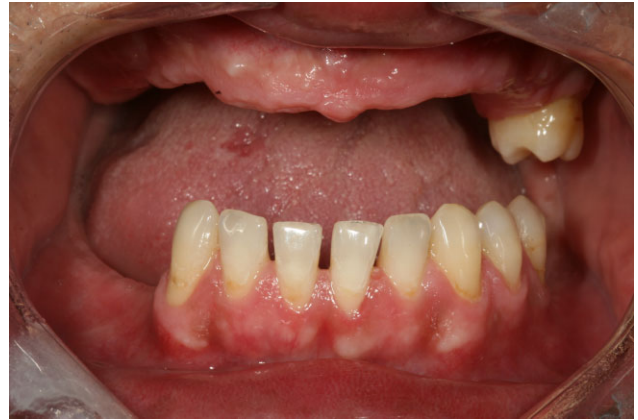

Figure 3 Preoperative Intraoral photograph of a complete edentulous maxillary rehabilitation using NobelSpeedy implants with 20 to 25 mm of length.

which normally reached the canine area. The anterior implants (nonstudy) diameter was 3.3 mm ($n = 2$), 4 mm ($n = 30$), or 5 mm ($n = 2$); while the tilted implants (nonstudy) were 4 mm diameter ($n = 9$). All conventional nonstudy implants were NobelSpeedy Groovy. A clinical situation is described in Figures 2–8. On partial rehabilitations, the anterior implants were typically placed in the canine or first premolar positions. This implant arrangement resulted in support at both ends of the fixed partial denture, avoiding cantilevers. After closing and suturing the flap with 4-0 and 3-0 non-resorbable sutures (Braun Silkam non-absorbable 4-0, Aesculap, Tuttlingen, Germany), the abutments were accessed by means of a punch if needed and impression copings were placed.

Immediate Prosthetic Protocol

Before implant surgery, with the removable prosthesis in the mouth, two marks were made on the patient's

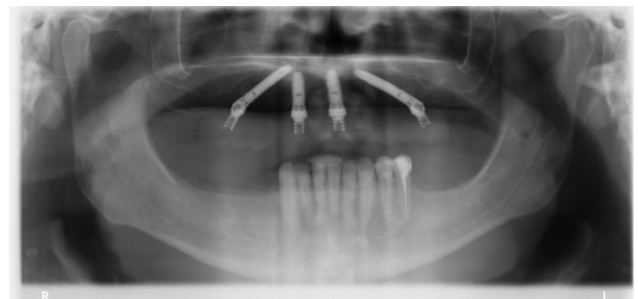


Figure 4 Postoperative orthopantomography of a complete edentulous maxillary rehabilitation using NobelSpeedy implants with 20 to 25 mm of length (implants on positions #16 and #26).

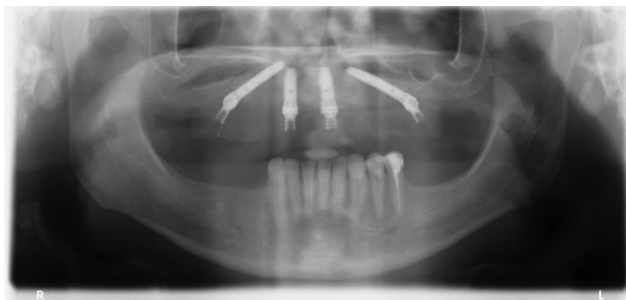

Figure 5 Orthopantomography of a complete edentulous maxillary rehabilitation using NobelSpeedy implants with 20 to 25 mm of length (implants on positions #16 and #26) after 1 year of follow-up.

chin and nose tip using a surgical marker. The distance between these marks represented the reference that allowed for maintaining or increasing the occlusion vertical dimension when the immediate bridge was placed. Full arch acrylic resin (Heraeus Kulzer, Hanau, Germany) prostheses were inserted on the day of surgery ($n = 16$). The fabrication of the implant supported prosthesis followed standard procedures.²² After suturing, an impression with putty material (Elite HD+ Putty Soft Fast; Zhermack, Badia Polesine, Italy) was made in a custom open tray. After tray removal, healing caps (Nobel Biocare AB) were placed to support the peri-implant mucosa during the fabrication of the prosthesis. High-density acrylic resin (PalaXpress Ultra; Heraeus Kulzer) prosthesis with titanium cylinders (Temporary coping Multi-unit, Nobel Biocare AB) was manufactured at the dental laboratory, and inserted on the same day usually 2 to 3 hours post-surgically. Anterior occlusal contacts from canine to canine and canine guidance during lateral movements were preferred in the provisional prosthesis. Protrusion incisal guidance

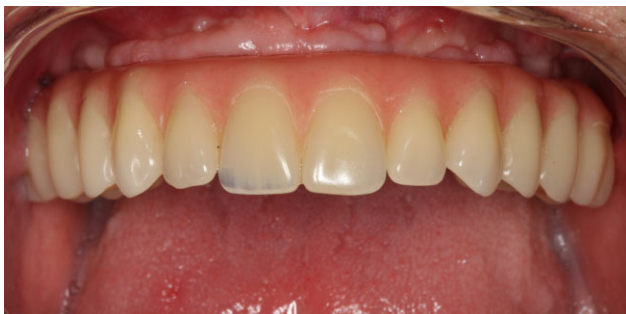

Figure 6 Intraoral photograph of a complete edentulous maxillary rehabilitation using NobelSpeedy implants with 20 to 25 mm of length after 1 year of follow-up.

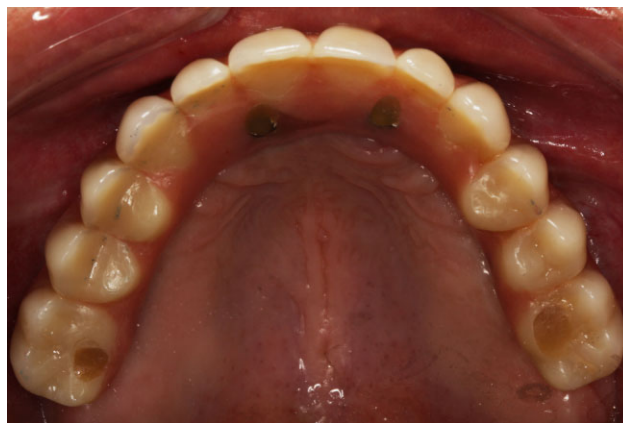

Figure 7 Intraoral photograph (occlusal view) of a complete edentulous maxillary rehabilitation using NobelSpeedy implants with 20 to 25 mm of length after 1 year of follow-up.

was also preferred and no cantilevers were used during the osseointegration period.

Final Prosthetic Protocol

Considering patient preferences, a metal-ceramic implant-supported fixed prosthesis with a titanium framework scanned and read by the Procera software (Nobel Biocare AB), with the data digitally transferred to a milling machine for fabrication of the framework, and all-ceramic crowns (NobelProcera titanium framework, Zirconia crowns, Nobel Rondo ceramics, Nobel Biocare AB), and acrylic resin replicating gingival tissues (PalaXpress Ultra);²⁸ or a metal-acrylic resin implant supported fixed prosthesis with a titanium framework (NobelProcera titanium framework) and acrylic resin prosthetic teeth (Heraeus Kulzer) was used to replace the

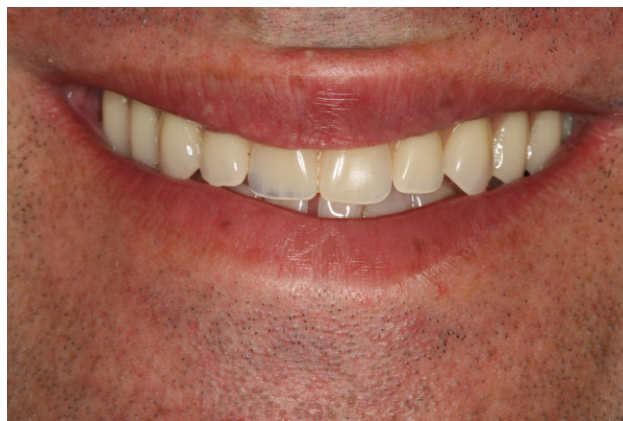

Figure 8 Patient smiling with a complete edentulous maxillary rehabilitation using NobelSpeedy implants with 20 to 25 mm of length after 1 year of follow-up.

provisional prosthesis. If an adjustment of the angulated abutment was needed for better positioning of the screw access hole, the impression for the final prosthesis was taken at implant level. The abutment position was then chosen at the laboratory and was adjusted in the patient's mouth. In this final prosthesis, the occlusion mimicked natural dentition. The final prosthesis was typically delivered 6 months post-surgically.

Follow-Up

Follow-up examinations were performed at 10 days, 2, 4, 6 months, 1 year after implant placement, and thereafter every 6 months. Intraoral radiographic examinations were performed at baseline (10 days post-surgery), 6-month, and 1-year follow-up. For the intraoral technique, a conventional radiograph holder was used, the position of which was adjusted manually to ensure orthogonal film positioning. A blinded operator examined all radiographs of the implants for marginal bone remodeling (reflecting the remodeling due to the surgical and prosthetic procedures). Each periapical radiograph was scanned at 300 dpi with a scanner (HP Scanjet 4890, HP Portugal, Paço de Arcos, Portugal), and the marginal bone level was assessed with image analysis software (Image J version 1.40 g for Windows; National Institutes of Health, Bethesda, MD, USA). The reference point for the reading was the implant platform (the horizontal interface between the implant and the abutment), and marginal bone remodeling was defined as the difference in marginal bone level relative to the bone level at time of surgery. The radiographs were accepted or rejected for evaluation based on the clarity of the implant threads; a clear thread guarantees both sharpness and an orthogonal direction of the radiographic beam toward the implant axis.

Primary and Secondary Outcome Measures

The primary outcome measures were prosthesis and implant survival. The prosthesis survival was judged in terms of function. A prosthesis was considered a failure if it needed to be replaced by an alternative prosthesis. Implant survival was classified according to the Malo Clinic survival criteria:²³ (1) it fulfilled its purported function as a support for reconstruction; (2) it was stable when individually and manually tested (prosthesis removed and implants individually checked at every follow-up appointment); (3) no signs of pain or infection were observed (fistulae, abscess or infection with

bone loss exceeding the middle third of the implant's length); (4) no radiolucent areas around the implants; (5) demonstrated a good aesthetic outcome (both patient and prosthodontist responsible for the rehabilitation agreed the aesthetics were good); and (6) allowed construction of the implant-supported fixed prosthesis, which provided patient comfort and good hygiene maintenance. Implants that did not meet the survival criteria were considered failures. The secondary outcome measures were marginal bone remodeling and the incidence of mechanical and biological complications. The following mechanical complication factors were assessed: fracture or loosening of mechanical and prosthetic components. The following biological complication parameters were assessed: fistula formation, pain or peri-implant pathology, and soft-tissue inflammation (registered as present or absent).

Success was computed using life table analysis. Descriptive statistics were computed for the variables of interest (incidence of complications).

RESULTS

Two patients (12.5% of the sample; $n = 4$ study implants and 2 nonstudy anterior implants) supporting two complete edentulous rehabilitations were lost to follow-up after 6 and 11 months. There were no implant failures, rendering a cumulative implant survival rate of 100% (Table 2). All prostheses were in function during the follow-up of the study.

At baseline, radiographs were available from 15 of the 16 patients and 23 of the 24 implants (93.8% and 95.8% for patient and implant levels, respectively); at 6 months, radiographs were available from 15 of the 16 patients and from 24 of the 25 implants (93.8% and 96.0% for patient and implant levels, respectively); at 1 year, radiographs were available from 13 of the 14 patients and from 20 of the 21 implants (92.9% and 95.2% for patient and implant levels, respectively).

The average marginal bone remodeling was 0.58 mm (SD = 0.42 mm) and 0.85 mm (SD = 0.45 mm), after 6 months and 1 year, respectively (Table 3). There was one mechanical complication in one patient (abutment loosening) 1 month post-surgery. The problem was amended by retightening the abutment and correcting the occlusion. No further mechanical complications occurred during the follow-up of the study. There were no biological complications registered during the follow-up of the study.

TABLE 2 Life Table Analysis for the Implants with 20 to 25 mm of Length

Time	Implants				Proportion Surviving Rate (%)	Cumulative Survival Rate (%)
	Number Entering Interval	Withdraws	Failure	Follow-Up Interval Not Yet Completed		
0–6 months	25	0	0	0	100	100
6–12 months	25	4	0	0	100	100
12–18 months	21	0	0	16	100	100
18–24 months	5	0	0	3	100	100

DISCUSSION

The preliminary results for the use of longer implants in a tilted position in the rehabilitation of complete edentulous situations in both jaws are comparable to short-term outcomes of conventional implants used in similar situations.²³ Several studies using the same implant design reported survival rates on the short-term outcome between 97.6% and 100%,^{23,29,30} and a marginal bone remodeling between 0.9 mm and 1.6 mm. Using the same implant design and rehabilitation procedures through immediate function, Maló and colleagues²⁹ in the first study reporting the short-term outcome of NobelSpeedy implants (Nobel Biocare AB) in the complete edentulous maxillary rehabilitations, registered a survival rate of 98.9% and a marginal bone remodeling of 1.2 mm after 1 year of follow-up. Georgiopoulos and colleagues¹⁸ in a two-dimensional finite element analysis was used to evaluate the effects of implant length and diameter on the stress distribution, observed that an increased implant length results in stress reduction on the implant in both immediate and delayed loading

and that increasing the implant length from 10 mm to 14 mm results in strain reduction on bone tissue during immediate and delayed implant loading, a situation that was confirmed clinically.¹⁹

It may be hypothesized that the use of these longer implants may be more advantageous as a larger implant-bone contact surface is achieved, with an increased bone support for these types of implants. This situation may be of extreme importance from the biomechanical standpoint (with the insertion of short-implants, combined with the poor bone quality and exposure to high occlusal loads),^{31–33} and from the clinical standpoint (when rehabilitating edentulous arches with low-density bone, which represents a frequently cited cause of dental implant failure).^{26,27}

An important aspect to overcome this situation was achieving a bicortical anchorage using the maxilla and nasal corticals for that effect. This was possible due to the implants length, with the implant's head anchored on the maxilla cortical positioned on the 1st/2nd premolar and the implant apex anchored on the nasal

TABLE 3 Marginal Bone Remodeling (MBR) for the Study Implants after 6 Months and 1 Year of Follow-Up Using the Patient as Unit of Analysis

Baseline Bone Level			MBR 6 Months		MBR 1 Year	
Average (mm)	0.32		0.50		0.86	
Standard deviation (mm)	0.24		0.34		0.46	
Number	16		15		13	
Frequencies	N	%	N	%	N	%
0	1	6.3	1	5.9	0	0
–0.1 to –1.0	15	93.8	12	80.0	8	61.5
–1.1 to –2.0	0	0	2	13.3	5	38.5
–2.1 to –3.0	0	0	0	0	0	0
>–3.0	0	0	0	0	0	0

At baseline, one implant from one patient was not possible to analyze from the radiograph. At 6 months, one implant from one patient was not possible to analyze from the radiograph. At 1 year, one implant from one patient was not possible to analyze from the radiograph.

cortical. With this implant positioning, the authors aim at a bicortical anchorage, which in turn represents an advantage for implant-supported immediate function rehabilitations performed in less dense bone. Bicortical anchorage has its own advantages and disadvantages. The disadvantage that, submitted to the same load, long implants may take a larger load share owing to their stiffer anchorage whereas short implants may be subjected to lower stress and a lower risk of screw loosening and/or component fracture, owing to the greater flexion in bone.³⁴ Despite these higher stresses measured in long bicortical implants compared with short implants, these situations occur in detriment of the transmission of larger stress to the bone and consequent higher risk of implant failures registered in short implants,³⁵ which may constitute a potential advantage for long implants inserted with bicortical anchorage.

The limitations of this study are the short follow-up, the small sample size, and only one clinical center involved.

Future research should focus on the medium- and long-term outcomes of these implants with larger sample sizes so to evaluate in depth the clinical performance of these implants.

CONCLUSION

Within the limitations of this study, it is possible to use longer implants (20–25 mm) in immediate function with bicortical anchorage for support of partial or complete edentulous fixed prosthetic rehabilitations performed in patients with low-density bone. Further studies should be conducted to test the long-term outcome of these implants.

ACKNOWLEDGMENTS

This study was supported by a grant from Nobel Biocare (Grant 2012-1091). Professor Paulo Maló serves currently as a consultant for Nobel Biocare. The authors would like to thank Mr. Sandro Catarino and Miss Andreia de Araújo for all the help in data collection.

REFERENCES

1. Pessoa R, Coelho P, Muraru L, et al. Influence of implant design on the biomechanical environment of immediately placed implants: computed tomography-based nonlinear three-dimensional finite element analysis. *Int J Oral Maxillofac Implants* 2011; 26:1279–1287.
2. Weber HP, Morton DO, Gallucci G, Rocuzzo M, Cordaro L, Grütter L. Consensus statements and recommended clinical procedures regarding loading protocols. *Int J Oral Maxillofac Implants* 2009; 24:S180–S183.
3. Esposito M, Gabriella Grusovin M, Coulthard P, V Worthington H. Different loading strategies of dental implants: a Cochrane systematic review of randomised controlled clinical trials. *Eur J Oral Implantol* 2008; 1:259–276.
4. Esposito M, Gabriella Grusovin M, Shane Chew Y, Coulthard P, V Worthington H. One-stage versus two-stage implant placement. A Cochrane systematic review of randomised controlled clinical trials. *Eur J Oral Implantol* 2009; 2:91–99.
5. Ekfeldt A, Christiansson U, Ericksson T, et al. A retrospective analysis of factors associated with multiple implant failures in maxillae. *Clin Oral Implants Res* 2001; 12:462–467.
6. Sivoella S, Bressan E, Gnocco E, Berengo M, Favero GA. Maxillary sinus augmentation with bovine bone and simultaneous dental implant placement in conditions of severe alveolar atrophy: a retrospective analysis of a consecutively treated case series. *Quintessence Int* 2011; 42:851–862.
7. Stavropoulos A, Becker J, Capsius B, Açil Y, Wagner W, Terheyden H. Histological evaluation of maxillary sinus floor augmentation with recombinant human growth and differentiation factor-5-coated β -tricalcium phosphate: results of a multicenter randomized clinical trial. *J Clin Periodontol* 2011; 38:966–974.
8. Simonpieri A, Choukroun J, Del Corso M, Sammartino G, Dohan Ehrenfest DM. Simultaneous sinus-lift and implantation using microthreaded implants and leukocyte- and platelet-rich fibrin as sole grafting material: a six-year experience. *Implant Dent* 2011; 20:2–12.
9. Esposito M, Gabriella Grusovin M, Rees J, et al. Effectiveness of sinus lift procedures for dental implant rehabilitation: a Cochrane systematic review. *Eur J Oral Implantol* 2010; 3: 7–26.
10. Maló P, de Araújo Nobre M, Rangert Bo. Short implants placed one-stage in maxillae and mandibles: a retrospective clinical study with 1 to 9 years of follow-up. *Clin Implant Dent Relat Res* 2007; 9:15–22.
11. Maló P, Nobre M, Lopes A. Short implants in posterior jaws. A prospective 1-year study. *Eur J Oral Implantol* 2011; 4: 47–53.
12. Atieh M, Payne A, Warwick J, Duncan W, de Silva R, Cullinan M. Immediate placement or immediate restoration/loading of single implants for molar tooth replacement: a systematic review and meta-analysis. *Int J Oral Maxillofac Implants* 2010; 25:401–415.
13. Annibali S, Cristalli MP, Dell'Aquila D, Bignozzi I, Monaca G, Pilloni A. Short dental implants: a systematic review. *J Dent Res* 2012; 91:25–32.
14. Felice P, Soardi E, Pellegrino G, et al. Treatment of the atrophic edentulous maxilla: short implants versus bone

- augmentation for placing longer implants. Five-month post-loading results of a pilot randomised controlled trial. *Eur J Oral Implantol* 2011; 4:191–202.
15. Hasan I, Heinemann F, Aitlahrach M. Bourauel Biomechanical finite element analysis of small diameter and short dental implant. *Biomed Tech* 2010; 55:341–350.
 16. Degidi M, Piattelli A, Iezzi G, Carinci F. Immediately loaded short implants: analysis of a case series of 133 implants. *Quintessence Int* 2007; 38:193–201.
 17. Van Assche N, Michels S, Quirynen M, Naert I. Extra short dental implants supporting an overdenture in the edentulous maxilla: a proof of concept. *Clin Oral Implants Res* 2011; 4:525–537.
 18. Georgiopoulos B, Kalioras K, Provatidis C, Manda M, Koidis P. The effects of implant length and diameter prior to and after osseointegration: a 2-D finite element analysis. *J Oral Implantol* 2007; 31:243–256.
 19. Kinsel RP, Liss M. Retrospective analysis of 56 edentulous dental arches restored with 344 single-stage implants using an immediate loading fixed provisional protocol: statistical predictors of implant failure. *Int J Oral Maxillofac Implants* 2007; 22:823–830.
 20. Renouard F, Nisan D. Impact of implant length and diameter on survival rate. *Clin Oral Implants Res* 2006; 17:35–51.
 21. Krekmanov L, Kahn M, Rangert B, Lindstrom H. Tilting of posterior mandibular and maxillary implants for improved prosthesis support. *Int J Oral Maxillofac Implants* 2000; 15: 405–414.
 22. Maló P, Rangert B, Nobre M. All-on-4 immediate-function concept with Brånemark system implants for completely edentulous maxillae: a 1-year retrospective clinical study. *Clin Implant Dent Relat Res* 2005; 7:S88–S94.
 23. Maló P, De Araújo Nobre M, Lopes A. The rehabilitation of completely edentulous maxillae with different degrees of resorption with four or more immediately loaded implants: a 5-year retrospective study and a new classification. *Eur J Oral Implantol* 2011; 4:227–243.
 24. Fortin Y, Sullivan RM, Rangert B. The Marius implant bridge: surgical and prosthetic rehabilitation for the completely edentulous upper jaw with moderate to severe resorption: a 5-year retrospective clinical study. *Clin Implant Dent Relat Res* 2002; 4:69–77.
 25. Maló P, Rangert B, Nobre M. “All-on-4” immediate-function concept with Branemark system implants for completely edentulous mandibles: a retrospective clinical study. *Clin Implant Dent Relat Res* 2003; 5:S2–S9.
 26. Van Steenberghe D, Jacobs R, Desnyder M, Maffei G, Quirynen M. The relative impact of local and endogenous patient-related factors on implant failure up to the abutment stage. *Clin Oral Implants Res* 2002; 13:617–622.
 27. Stach RM, Kohles SS. A meta-analysis examining the clinical survivability of machined-surface and osseotite implants in poor-quality bone. *Implant Dent* 2003; 12:87–96.
 28. Maló P, de Araújo Nobre M, Borges J, Almeida R. Retrievable metal ceramic implant-supported fixed prostheses with milled titanium frameworks and all-ceramic crowns: retrospective clinical study with up to 10 years of follow-up. *J Prosthodont* 2012; 21:256–264. DOI: 10.1111/j.1532-849X.2011.00824.x
 29. Maló P, Nobre Mde A, Petersson U, Wigren S. A pilot study of complete edentulous rehabilitation with immediate function using a new implant design: case series. *Clin Implant Dent Relat Res* 2006; 8:223–232.
 30. Maló P, Nobre M. Flap vs. flapless surgical techniques at immediate implant function in predominantly soft bone for rehabilitation of partial edentulism: a prospective cohort study with follow-up of 1 year. *Eur J Oral Implantol* 2008; 1:293–304.
 31. Swanberg DF, Henry MD. Avoiding implant overload. *Implant Soc* 1995; 6:12–14.
 32. Piattelli A, Piattelli M, Scarano A, Montesani L. Light and scanning electron microscopic report of four fractured implants. *Int J Oral Maxillofac Implants* 1998; 13:561–564.
 33. Rangert B, Sennnerby L, Nilson H. Load factor analysis for implants in the resorbed posterior maxilla. In: Jensen OT, ed. *The sinus bone graft*. Chicago, IL: Quintessence Publishing, 1999:167–177.
 34. Pierrisnard L, Renouard F, Renault P, Barquins M. Influence of implant length and bicortical anchorage on implant stress distribution. *Clin Implant Dent Relat Res* 2003; 5:254–262.
 35. Maló P, de Araújo Nobre M, Rangert B. Short implants placed one-stage in maxillae and mandibles: a retrospective clinical study with 1 to 9 years of follow-up. *Clin Implant Dent Relat Res* 2007; 9:15–21.

Copyright of Clinical Implant Dentistry & Related Research is the property of Wiley-Blackwell and its content may not be copied or emailed to multiple sites or posted to a listserv without the copyright holder's express written permission. However, users may print, download, or email articles for individual use.