

Immediate Implants Placed in Infected and Noninfected Sites after Atraumatic Tooth Extraction and Placement with Ultrasonic Bone Surgery

Cornelio Blus, MD, DDS;* Serge Szmukler-Moncler, DDS, PhD;† Paul Khoury, DDS;‡ Germano Orrù, PhD§

ABSTRACT

Background: Only a few reports deal with implants placed in infected postextraction sites.

Purpose: Survival rates of a cohort of immediate implants cases placed in acute and chronically infected sites were compared with a cohort of noninfected ones while (1) tooth extraction and osteotomy sites were prepared with a piezosurgery device and (2) ultrasonication was applied to abate the bacterial charge at infected sites.

Materials and Methods: Eighty-six patients received 168 immediate implants distributed into three groups: noninfected (85), acute (36), and chronically (47) infected sites. Atraumatic extraction and implant osteotomy were performed with an ultrasonic surgery device without flap elevation. All sites received the same medication and surgical protocol; infected sites were ultrasonicated during 30 seconds at 72 W. Kaplan–Meyer survival rates were calculated at 1 year.

Results: The 1-year survival rates of the noninfected, chronically, and acute infected groups were 98.8, 100, and 94.4%, respectively. The differences were not statistically significant. No implant was lost after loading. All teeth and roots could be extracted in one piece. Drilling at extraction sockets was uncomplicated, without skidding.

Conclusions: Implant survival rates might be similar in infected and noninfected sites when infected sites receive standard medical and surgical treatment and are ultrasonicated. Atraumatic tooth/root extraction and implant placement can be reliably performed with piezoelectric surgery.

KEY WORDS: atraumatic extraction, immediate implant, piezo-surgery, root extraction, tooth extraction, ultrasonic surgery

INTRODUCTION

It is traditionally accepted that implantation sites should be infection free.^{1,2} This might explain why the fate of

immediate implants placed in infected sites has been scarcely documented.^{3,4}

In the late 1990s, some cases have been reported;^{5,6} lately, a few more clinical studies have been added to the topic.^{7–15} Animal studies have also been conducted.^{16–18} All those studies are suggesting that implants placed in infected sites might be more predictable than anticipated. Nevertheless, before the dental community can accept placing implants in infected sites as an acceptable routine treatment, more clinical documentation issued by various research groups is warranted. More specifically, it should detail (1) the kind of pathology that is involved in the socket, for example, chronic or acute; (2) the specific cleaning methods of the infected sites, medical, and/or surgical; and (3) the medical treatment implemented before and after implantation.

*Professor ac, Oral Biotechnology Laboratory, Department of Surgical Sciences, University of Cagliari, Cagliari, Italy, and private practice, Torino, Italy; †professor ac, Oral Biotechnology Laboratory, Department of Surgical Sciences, University of Cagliari, Cagliari, Italy; ‡fellow dentist; Ardentis Vevey, Swiss Dental Clinics Group, Vevey, Switzerland; §assistant professor, Oral Biotechnology Laboratory, Department of Surgical Sciences, University of Cagliari, Cagliari, Italy

Reprint requests: Dr. Cornelio Blus, Corso Francia, 7, I-10138 Torino, Italy; e-mail: corblus@hotmail.com

No conflict of interest.

© 2013 Wiley Periodicals, Inc.

DOI 10.1111/cid.12126

Analysis of the implant literature dealing with implants placed in infected postextraction sites shows that a variety of pathologies and treatment protocols is involved. The published reports are dealing with either chronic periodontal pathologies,^{5,9,11,13} acute,¹⁰ or both.^{7-9,14} Careful local debridement and granulation tissue removal are consistently performed, but flap elevation with bone grafting has been either included^{5,7,9,10,12,14,15} or excluded^{8,11,12} from the surgical procedure.

Per-operatively, infected sites have been handled with implemented antibiotics,⁷ cortisone application,^{8,11} profuse irrigation with chlorhexidine,¹⁴ plasma rich in growth factors,¹³ or large excisions of bone with burs.¹⁰ The start of antibiotic therapy also varied prior to surgery; it was 3 days,¹⁴ 2 days,^{7,9} 24 hours,⁸ or 1 hour.¹¹⁻¹³ After surgery, it extended up to 4 days,¹¹ 5 days,^{7,8,12,15} 7 days,¹⁴ 10 days,¹⁰ or even 21 days.⁵

Of the few reports published of this issue, only two studies^{9,12} involved test and control groups; they comprised 25⁹ and 17¹² patients. In one study, the test group consisted of solely chronically infected sites, and implants were left to heal in a submerged way.⁹ In the other study, both chronic and acute infected sites were treated; implants healed in a semisubmerged fashion.¹² Flaps were equally reclined in these studies, and the sites were treated with autologous bone⁹ or bone substitute;¹² a resorbable membrane was always used. Therefore, any additional data comparing the survival rates of implants placed in infected and noninfected sites should be welcomed as far as the detailed treatment protocol is provided.³

In all the above-mentioned papers, tooth and root extraction was performed with conventional forceps; implant osteotomies beyond the extraction sockets were prepared with rotary instruments. Lately, a new family of surgical tools has been developed to perform tooth/root extraction and implant placement.¹⁹ It consists of ultrasonically moved tips connected to a piezosurgery device. Relevance of this novel technique has been previously addressed.¹⁹

Recently, our group identified that the powerful cavitation generated by the ultrasonically moved tips can have an effective bactericide action on bacteria.²⁰ It was then suggested that cavitation might be clinically relevant to challenge the bacterial burden at infected sites, in the same way it did for the diabetic foot.²¹

The aim of the present report was therefore to document the survival rates of a cohort of immediate implant

cases placed in infected, chronic, and acute sites. It was eventually compared with the survival rates of a simultaneously treated cohort of cases in which implants were placed in noninfected extraction sites. More specifically, the same medical and surgical protocols were applied to the infected and noninfected sites. The only difference was that infected sites were ultrasonicated with the vibrating tips of a powerful piezoelectric bone surgery device in order to take advantage of the evidenced bactericide effect.

MATERIALS AND METHODS

Ultrasonic Bone Surgery Device

The UBS ultrasonic bone surgery device (Resista, Omegna, Italy) was used to extract the teeth and the roots as well as to prepare the implant osteotomies. It works in the 20–32 kHz range; its maximum ultrasound power is 90 W.^{19,20,22} The tips are made of titanium alloy.

Extraction Tips

Six different tips (Figure 1) were available to adapt to the various clinical situations. The first one is arrow like and sharp on both sides (Figure 1); it was used to penetrate into the periodontal ligament (PDL) at the coronal part and start sectioning the fibers of the PDL. To deeper section the PDL fibers in the apical direction, four



Figure 1 Vibrating tips to cut the periodontal ligament (PDL) fibers. From left to right: arrow-like tip, syndesmotome with teeth perpendicular and parallel to the handpiece long axis, left- and right-angled 45° syndesmotome without teeth, right-angled 45°, large syndesmotome with teeth.



Figure 2 Vibrating osteotomy tips for extraction sockets. From left to right: two cylindrical pilot tips, conical tips of increasing diameter.

syndesmotomes were further used; two of them are straight with teeth; their cutting direction is parallel and perpendicular to the long axis of the tip (Figure 1). The two other items are 45° angled, one to the right and one to the left (Figure 1), in order to better adapt to the socket geometry. The last one, with teeth, was indicated to extract ankylosed teeth (Figure 1).

Implant Osteotomy Preparation Tips

Six different vibrating tips were available, two pilot cylindrical tips and four conical ones (Figure 2), to adjust to the various implant diameters. All were laser-marked at 8, 10, 13, and 15 mm. The pilot drills were Ø 1.8 and 2.2 mm; the conical drills at the 13 mm laser-marking were Ø 2.8, Ø 3.2, Ø 3.8, and Ø 4.5 mm to place implants of Ø 3.75, Ø 4.2, and Ø 5 mm, respectively. The working surface is located at the apical extremity to prevent alteration of the thin buccal table during preparation of the implant bed. The

conical shape of the vibrating tips is designed to mechanically condense the bone of the osteotomy site beyond the socket.

PATIENT DATA

Inclusion/Exclusion Criteria

Patients that needed tooth extraction and immediate implant placement constituted the present cohort of cases. Integrity of the socket walls was explored with a periodontal probe. Absence of the buccal wall at the treated sites was an exclusion criterion. When the buccal wall was found missing over 3–5 mm below the marginal gingiva, a biomaterial (BioOss, Geistlich, Wollhusen, Switzerland) was added.

In addition, these consecutively placed implants had to be in place for at least 1 year.

According to the situation of the socket, extraction sites were distributed into three distinct groups: (1) non infected sites; (2) sites with chronic infection; and (3) sites with acute infection. The treatment was explained to the patients expected to receive implants in the infected sites; an informed consent was signed.

The noninfected group was characterized by the following: (1) extracted teeth did not show clinical or radiographic signs of infection at the apex; (2) teeth were not involved in a periodontal disease. Reasons for extraction are given in Table 1.

Infection was considered chronic when the following conditions were met: (1) periapical granuloma cyst; (2) asymptomatic periapical granuloma, both detected on radiographs; or (3) tooth mobility with Miller index >1. These sites were also characterized by absence of pain, fistula, pus, and active periodontal disease. Reasons for extraction are given in Table 1.

TABLE 1 Reasons for Extraction

| Non infected group | Nonfunctional root | Tooth fracture | Tooth mobility | Tooth ankylosis | Orthodontic traction | Total |
|-------------------------|-------------------------------|-----------------------|--------------------|-------------------|----------------------|-------|
| | 30 | 7 | 8 | 17 | 23 | 85 |
| Chronic infection group | Nonactive periodontal disease | Perioapical granuloma | Endo-perio disease | | | Total |
| | 15 | 5 | 27 | | | 47 |
| Acute infection group | Failed endodontic treatment | Active periodontal | Granuloma and pus | Infected fracture | | Total |
| | 2 | 7 | 10 | 17 | | 36 |

Infection was considered acute when the following criteria were met: (1) presence of pain; (2) presence of pus or fistula for periodontally involved sites; (3) presence of pus at the apex of endodontically involved sites, even when still collected in a periapical cyst. Reasons for extraction are also given in Table 1.

Surgical Procedure

All patients received the same antibiotic treatment, whatever the reason for extraction was. Amoxicillin with Clavulanic acid (Augmentin, GlaxoSmithKline, Verona, Italy), 2×1 g/day was given for 5 days, starting 6–12 hours before extraction (i.e., either on the evening before surgery or on the morning of the surgery day).

No periodontal flap was raised. Extraction was performed with the tips of the extraction kit (Figure 1) at 66 W (power 5 on the UBS device).^{19,20} The arrow-like tip was brought into the sulcus over a 4–5 mm depth all around the teeth, without previously separating the gingiva from the teeth. The straight or angled syndesmotomes were then utilized to achieve a deeper cut of the PDL fibers, up to 10 mm. After sectioning the PDL fibers, the teeth were mobilized with a Claude Bernard syndesmotome and then removed from the socket. At ankylosed teeth, the vibrating syndesmotomes with teeth were used to detach the root from the surrounding attached bone. Infected sites were carefully curetted to remove the granulation tissue and were ultrasonicated during 30 seconds at 72 W (power 6)²⁰ with the straight round bur of Ø 2.2 mm.

The osteotomy tips were used at power 6 to prepare the implant bed beyond the apex of the socket. The pilot tip was placed against the palatal wall to notch the socket at its apical third; angulation of the tip took into account a palatal shift of approximately 5° from the tooth axis. The notch was created with the correct angulation without any uncontrolled motion. It was extended into a 3–5 mm deep channel, apical to the alveolus apex. Enlargement of the osteotomy took place with the other tips of increasing diameter. Beyond the extraction socket, the osteotomy was conical in shape. Figures 3–5 illustrate a case taken from each group.

Demographic Data

One hundred sixty-eight implants rehabilitated the missing teeth of 53 women and 33 men; patients were 26 to 77 years old.

Implants were placed in noninfected (85 implants/43 patients) and infected (83 implants/57 patients) extraction sites. Infected sites were divided into sockets with chronic (47 sites/28 patients) or acute (36 sites/29 patients) infection according to the previously described inclusion criteria.

A total of 30 (17.9%) roots and 138 teeth was extracted; 17 showed ankylosis. Out of 99 extraction sockets in the maxilla, 58 (34.5%) belonged to the anterior maxilla; 22 teeth were biradicular (Table 2). Reasons for extraction have been listed in Table 1.

Implants from two manufacturers (Leader, Milano, Italy; Bioner, Barcelona, Spain) were placed; 64 implants (38.1%) belonged to the latter manufacturer. Implant characteristics are given on Table 3a and b.

All implants were placed according to a one-stage procedure. The different healing protocols are given in Table 4. At completion of healing, implant mobility was tested and the classical steps for prosthetic rehabilitation were undertaken.

Follow-Up and Success Criteria

Implants were controlled at the end of the corresponding healing period, at 3, 6, and 12 months, then annually and for the purpose of the present report. The survival criteria proposed by Buser and colleagues²³ and Cochran and colleagues²⁴ were followed, they were: (1) implant stability at each control; (2) absence of pain or any subjective sensation; (3) absence of recurrent peri-implant infection; and (4) absence of continuous radiolucency around the implant.

Statistical Analysis

The Kaplan–Meier survival estimate method was used to compare implant survival of the groups during the first year of implantation. This constraint to the first year allowed meeting the assumption of linear hazard over time because implants undergoing a deviation from a standard protocol are expected to have a higher failure rate during the osseointegration period but not afterwards. The threshold value for statistical significance was set at $p < .05$.

RESULTS

Brittle endodontically treated teeth or roots were all removed in one piece. They would have been fractured into pieces if extracted otherwise than with the vibrating tips. Ankylosed teeth were also taken in one piece; invasive surgery was avoided.

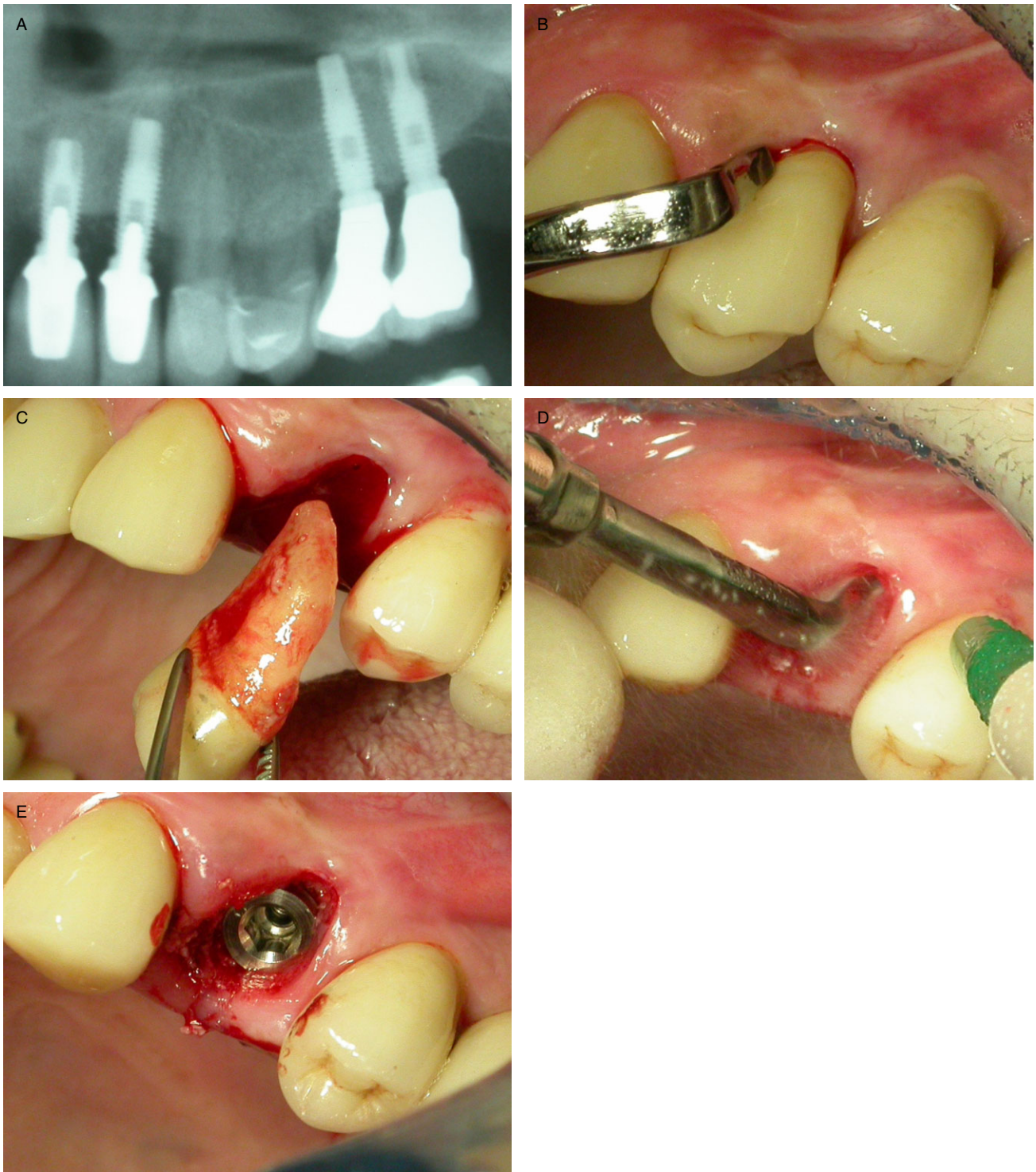


Figure 3 Treatment of a noninfected site with an immediate implant. *A*, Radiograph of the noninfected tooth to be extracted. *B*, Cutting the periodontal ligament (PDL) fibers with the arrow-like tip on the mesial side of the tooth. *C*, Extraction of the noninfected tooth. *D*, Preparation of the implant osteotomy with the vibrating tips. *E*, Immediate implant placed.

Notching the apical third of the palatal cortical table during implant placement in the anterior maxilla or preparing the thin inter-radicular bridge of premolars was uncomplicated, without skidding. Deepening the

osteotomy beyond the apex of the socket and enlarging it with the tips of increasing diameter were effortless. Implant placement was performed in the usual way. All implants achieved primary stability.

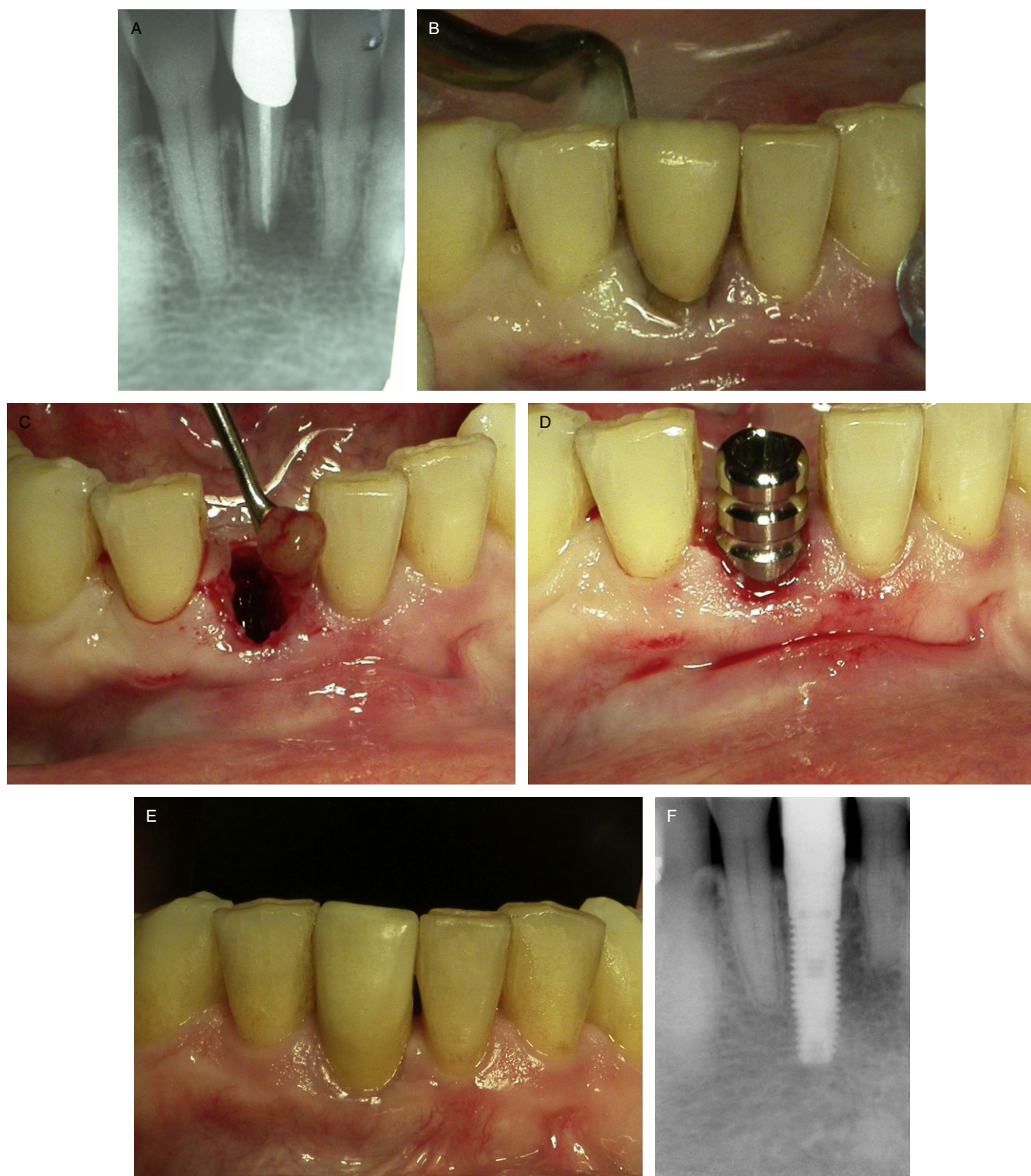


Figure 4 Treatment of an acute infected site with an immediate implant. *A*, Radiograph of the acute infected tooth that needs extraction. *B*, Cutting the periodontal ligament (PDL) fibers with the arrow-like tip on the lingual side. *C*, Pus cleaning of the acute infected site. *D*, Immediate implant placed. *E*, Clinical view at the 2-year control. *F*, Radiograph of the immediate implant at the 2-year control.

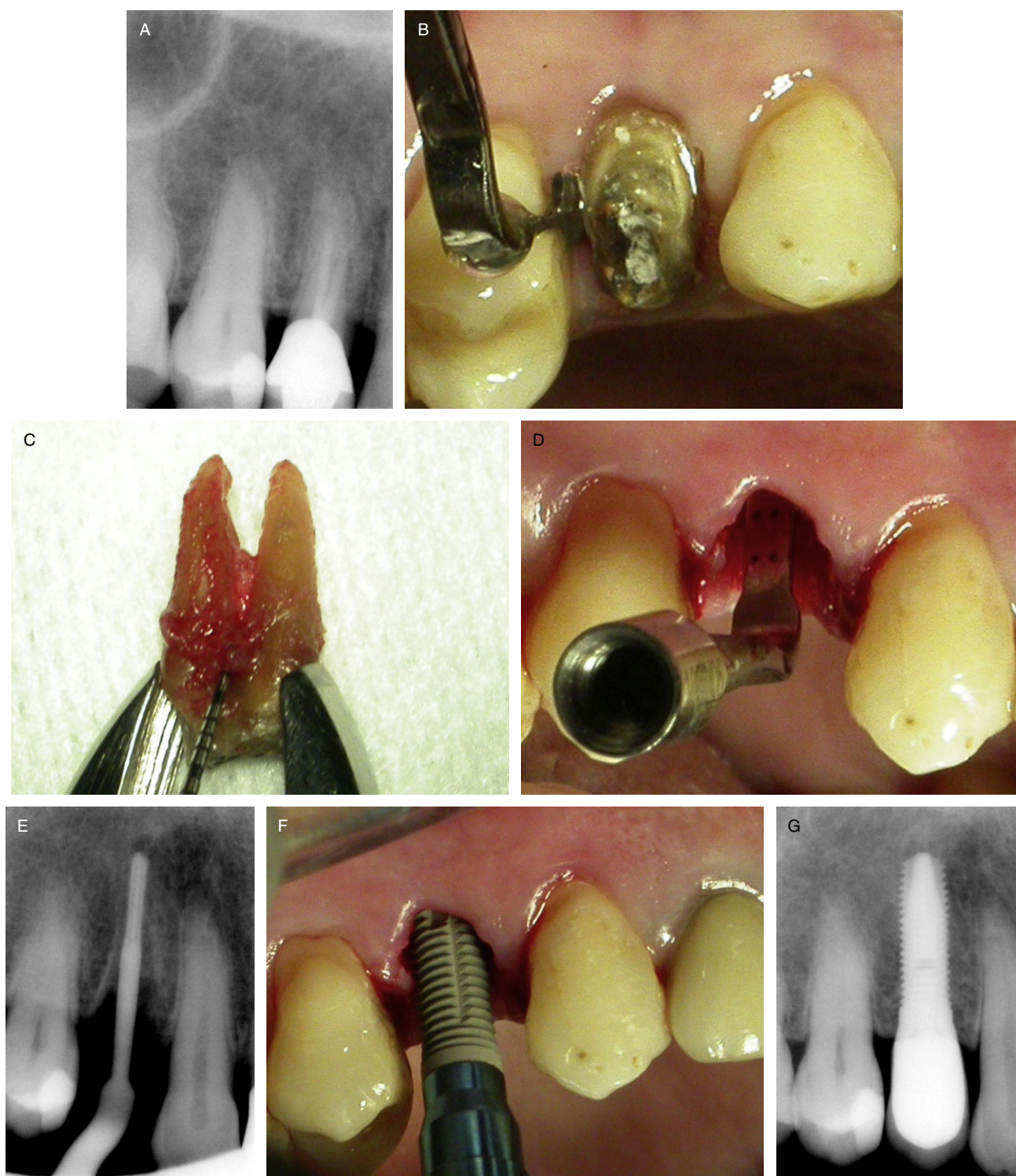

Figure 5 Treatment of a chronically infected site with an immediate implant. *A*, Radiograph of the infected tooth to be extracted. *B*, Cutting the periodontal ligament (PDL) fibers with the arrow-like tip on the distal side of the tooth. *C*, Chronically infected tooth after extraction. *D*, Vibrating tip placed in the osteotomy showing direction of the implant to be placed. *E*, Radiograph of the vibrating tip during preparation of the osteotomy. *F*, Immediate implant placed. *G*, Radiograph at the 2-year control.

TABLE 2 Details of the Treated Sites for Each Group

| | All Sites | Mandible | Maxilla | Anterior Maxilla | Posterior Maxilla | Biradicular Premolar | Monoradicular Premolar | Teeth | Roots |
|-------------------|-----------|----------|---------|------------------|-------------------|----------------------|------------------------|-------|-------|
| No infection | 85 | 38 | 47 | 25 | 22 | 10 | 20 | 76 | 9 |
| Chronic infection | 47 | 20 | 27 | 16 | 31 | 7 | 11 | 36 | 11 |
| Acute infection | 36 | 11 | 25 | 17 | 19 | 5 | 10 | 26 | 10 |
| Total | 168 | 69 | 99 | 58 | 72 | 22 | 41 | 138 | 30 |

Three implants failed. One (1.2%) belonged to the noninfected group; it failed after 3 weeks of healing. Two (5.5%) were part of the acute infection group; one failed after 2 months of healing, and the other one was immediately loaded and failed after 1 month of function. No implant failed in the chronically infected implant group. The 1-year survival rates of the noninfected, the acute infected, and the chronically infected implant groups were 98.8, 94.4, 100%, respectively. No statistically

significant differences were found between the failures rates of the various groups ($p = .14$), between the infected and non-infected groups ($p = .53$), or between the acute and chronically infected groups ($p = .10$). At the 2-year control, the survival rates remained unchanged.

DISCUSSION

Studies dealing with implants placed in infected sites are limited in number, but unanticipated high survival rates have been reported.^{5,7-15} To meet this unconventional situation, the standard protocols of implant placement have been altered. The deviations consisted into specific administration of medication before,^{7-9,14} during,^{8,11,13} or after^{5,10} surgery; flap raising was introduced to get access to the infected sites,^{5,7-10,12,14,15} and extensive bone removal with bone grafting was carried out.¹⁰

The present protocol differs from all previously published ones because the infected and noninfected sites underwent the same medical and surgical treatment (i.e., without specific medication, without flap elevation, or selective bone removal). Only, to abate the infection risk, the infected sockets were ultrasonicated during 30 seconds at 72 W with the vibrating round tips of the UBS device, implementing the strong cavitation effect. The aim was thought to achieve a local bactericide effect. Such an effect on microorganisms has been described in vitro by Thacker²⁵ on yeast and by Blus and colleagues²⁰ on two distinct bacteria, *E. coli* and *B. subtilis*. The latter authors²⁰ reported that 20 seconds of ultrasonication at 72 W could reduce by 50% the number of active colonies of *E. coli*.

Clinically, a bactericide effect would suit the positive healing response to cavitation while treating the diabetic foot²¹ and patients affected by bisphosphonate-related osteonecrosis of the jaws.²⁶

The clinical effect of this local cleansing method cannot be asserted with certainty, but it might have

TABLE 3 Details of the Placed Implants according to Implant Diameter and Length

| a. Implant Diameter | | | | | |
|---------------------|------|------|-----|-----|-------|
| Ø (mm) | 3.75 | 3.8 | 4.0 | 4.5 | Total |
| Noninfected | 46 | 3 | 9 | 27 | 85 |
| Chronic | 14 | 5 | 3 | 25 | 47 |
| Acute | 11 | 1 | 5 | 19 | 36 |
| | 71 | 9 | 17 | 71 | 168 |
| b. Implant Length | | | | | |
| Length (mm) | 10 | 11.5 | 13 | | Total |
| Noninfected | 10 | 30 | 45 | | 85 |
| Chronic | 4 | 12 | 31 | | 47 |
| Acute | 3 | 12 | 21 | | 36 |
| | 17 | 54 | 97 | | 168 |

TABLE 4 Details of the Placed Implants according to the Healing-Loading Protocol

| | Immed. Loading (<1 w) | Early Loading (1 w-3m) | Standard Loading (>3 m) | Total |
|-------------|-----------------------|------------------------|-------------------------|-------|
| Noninfected | 1 | 32 | 52 | 85 |
| Chronic | 4 | 25 | 18 | 47 |
| Acute | 2 | 4 | 30 | 36 |
| Total | 7 | 61 | 100 | 168 |

been useful because none of the previously mentioned specific protocol alterations have been implemented in the infected sites. Experimental studies should be performed to investigate if infected sites can heal without any specific treatment.

The survival rates of the infected sites compared well with the noninfected; this is in line with all previous reports.^{6–13} A 3-year multicenter study showed that immediate implants placed in sites with periapical lesions could not be assessed as a risk factor of implant failure.⁶ However, a more recent paper found that the reason for extraction could affect the survival rates of immediate implants.²⁷ At 1 year, sites with an endo-periodontal disease failed significantly more than sites with a periodontal disease only, 87.0% versus 95.9% ($p = .009$).

The present report should be viewed as a further contribution to the growing corpus of reports focusing on immediate implants placed in infected sites. In addition, it may suggest, for the first time, that ultrasonication through strong cavitation can affect similarly acute and chronic sites when it is used as a deviation step from standard protocols.

Because of the potential risk for implant failure, the fate of implants placed in infected sites has not been extensively documented.^{3,4} The reason is that the principles of evidence-based dentistry²⁸ are preventing clinicians to treat this indication. With more clinical reports supporting high survival rates, this approach might evolve the same way it did for immediate loading protocols, which are now considered acceptable practice in the hands of trained clinicians.²⁹

The esthetic follow-up is presently lacking because implant survival was the sole variable to be investigated. It would have been relevant to record all esthetic landmarks and check the way soft and hard tissues compare. Obviously, consistent esthetic results must be demonstrated before implant placement in infected sites could be considered as a suitable indication for implant therapy.

We previously documented that atraumatic extraction and implant placement with ultrasonic surgery tips can be a predictable surgical technique; this was achieved by following 40 sites over at least a 1-year period.¹⁹ With the present additional data, the advantages that have been previously identified could be confirmed on a larger scale, on 168 implants. They are the following: (1) by cutting the PDL fibers at the coronal

level of the socket instead of severing them with forceps, the dental community might have here the less traumatic extraction method presently at hand; (2) brittle teeth or roots or ankylosed teeth can be predictably extracted in one piece; (3) skidding and uncontrolled motion can be avoided when notching is performed at the apical third of the palatal table of extraction sites in the anterior maxilla;^{30,31} and (4) condensation of the apical part of osteotomy can be easily achieved as it increases implant primary stability³² and accelerates osseointegration.³³

CONCLUSION

This clinical report suggests that the survival rate of implants placed in infected sites, chronic or acute, may be similar to implants placed in noninfected sites. It suggests also that treatment of infected sites may remain medically nonspecific and surgically noninvasive. For the first time, ultrasonication with a powerful commercially available piezoelectric bone surgery device was used in order to abate the bacterial charge of infected postextraction sites. However, the relevance of this method needs to be further investigated and asserted. Limitation of this study is that esthetic results in terms of hard and soft tissue landmarks were not addressed.

More studies are warranted to identify what are the best clinical protocols to efficiently handle infected postextraction sockets with a minimally invasive approach.

ACKNOWLEDGMENTS

Authors are grateful to the daily efficient assistance of Ornella Costa and Maura Madeddu.

CONFLICT OF INTEREST DECLARATION

C. Blus owns patents on the vibrating tips. He has no commercial interest; the same applies to all other authors.

REFERENCES

1. Schwartz-Arad D, Chaushu G. The ways and wherefores of immediate placement of implants into fresh extraction sites: a literature review. *J Periodontol* 1997; 68:915–923.
2. Schropp L, Isidor F. Timing of implant placement relative to tooth extraction. *J Oral Rehabil* 2008; 35(Suppl 1): 33–43.
3. Waasdorp JA, Evian CI, Mandracchia M. Immediate placement of implants into infected sites: a systematic review of the literature. *J Periodontol* 2010; 81:801–808.

4. Palmer R. Evidence for survival of implants placed into infected sites is limited. *J Evid Based Dent Pract* 2012; 12(Suppl):187–188.
5. Novaes Jr AB, Novaes AB. Immediate implants placed into infected sites: a clinical report. *Int J Oral Maxillofac Implants* 1995; 10:609–613.
6. Grunder U, Polizzi G, Goené R, et al. A 3-year prospective multicenter follow-up report on the immediate and delayed-immediate placement of implants. *Int J Oral Maxillofac Implants* 1999; 14:210–216.
7. Villa R, Rangert B. Early loading of interforaminal implants immediately installed after extraction of teeth presenting endodontic and periodontal lesions. *Clin Implant Dent Relat Res* 2005; 7(Suppl 1):S28–S35.
8. Villa R, Rangert B. Immediate and early function of implants placed in extraction sockets of maxillary infected teeth: a pilot study. *J Prosthet Dent* 2007; 97(6 Suppl):S96–S108.
9. Lindeboom JA, Tjiook Y, Kroon FH. Immediate placement of implants in periapical infected sites: a prospective randomized study in 50 patients. *Oral Surg Oral Med Oral Pathol Oral Radiol Endod* 2006; 101:705–710.
10. Casap N, Zeltser C, Wexler A, Tarazi E, Zeltser R. Immediate placement of dental implants into debrided infected dento-alveolar sockets. *J Oral Maxillofac Surg* 2007; 65:384–392.
11. Malo P, de Araujo Nobre M, Rangert B. Implants placed in immediate function in periodontally compromised sites: a five-year retrospective and one-year prospective study. *J Prosthet Dent* 2007; 97(Suppl):S86–S95.
12. Siegenthaler DW, Jung RE, Holderegger C, Roos M, Hämmerle CH. Replacement of teeth exhibiting periapical pathology by immediate implants: a prospective, controlled clinical trial. *Clin Oral Implants Res* 2007; 18:727–737.
13. Del Fabbro M, Boggian C, Taschieri S. Immediate implant placement into fresh extraction sites with chronic periapical pathologic features combined with plasma rich in growth factors: preliminary results of single-cohort study. *J Oral Maxillofac Surg* 2009; 67:2476–2478.
14. Jofre J, Valenzuela D, Quintana P, Asenjo-Lobos C. Protocol for immediate implant replacement of infected teeth. *Implant Dent* 2012; 21:287–294.
15. Marconcini S, Barone A, Gelpi F, Briguglio F, Covani U. Immediate implant placement in infected sites: a case series. *J Periodontol* 2013; 84:196–202.
16. Novaes Júnior AB, Vidigal Júnior GM, Novaes AB, Grisi MF, Polloni S, Rosa A. Immediate implants placed into infected sites: a histomorphometric study in dogs. *Int J Oral Maxillofac Implants* 1998; 13:422–427.
17. Novaes AB Jr, Marcaccini AM, Souza SL, Taba M Jr, Grisi MF. Immediate placement of implants into periodontally infected sites in dogs: a histomorphometric study of bone-implant contact. *Int J Oral Maxillofac Implants* 2003; 18:391–398.
18. Marcaccini AM, Novaes AB Jr, Souza SL, Taba M Jr, Grisi MF. Immediate placement of implants into periodontally infected sites in dogs. Part 2: a fluorescence microscopy study. *Int J Oral Maxillofac Implants* 2003; 18:812–819.
19. Blus C, Szmukler-Moncler S. Atraumatic tooth extraction and immediate implant placement with piezosurgery (ultra-sonic surgery). Evaluation of 40 sites after at least 1-year of loading. *Int J Periodontics Restorative Dent* 2010; 30:355–363.
20. Blus C, Szmukler-Moncler S, Orru G, Denotti G, Piras A, Piras V. Bactericide effect of vibrating ultra-sonic (piezosurgery) tips. An in vitro study. *Clin Oral Implants Res* 2009; 20:905. (Abstr).
21. Blus C, Szmukler-Moncler S, La Rosa A, Moia R. Ultra-sonic debridement. A novel approach of scar debridement. Proceedings of the 2nd Congress of the World Union Wound Healing Societies, 2004, July 8–13, Paris, France, p 184.
22. Blus C, Szmukler-Moncler S, Salama M, Salama H, Garber D. Sinus bone grafting procedures using ultrasonic bone surgery: 5-year experience. *Int J Periodontics Restorative Dent* 2008; 28:221–229.
23. Buser D, Mericske-Stern R, Bernard JP, et al. Long-term evaluation of non-submerged ITI implants. Part 1: 8-year life table analysis of a prospective multi-center study with 2359 implants. *Clin Oral Implants Res* 1997; 8:161–172.
24. Cochran DL, Buser D, ten Bruggenkate C, et al. The use of reduced healing times on ITIs implants with a sandblasted and etched (SLA) surface: early results from clinical trials on ITI SLA implants. *Clin Oral Implants Res* 2002; 13:144–153.
25. Thacker J. An approach to the mechanism of killing of cells in suspension by ultrasound. *Biochim Biophys Acta* 1973; 304:240–248.
26. Blus C, Szmukler-Moncler S, Gianelli G, Denotti G, Orru G. Use of piezosurgery (ultra-sonic surgery) to treat bisphosphonate-related osteonecrosis of the jaws (BRONJ). *J Open Dent* (In press).
27. Testori T, Zuffetti F, Capelli M, Galli F, Weinstein RL, Del Fabbro M. Immediate versus conventional loading of post-extraction implants in the edentulous jaws. *Clin Implant Dent Relat Res* 2013; doi:10.1111/cid.12055
28. Richards D, Lawrence A. Evidence-based dentistry. *Br Dent J* 1995; 179:270–273.
29. Davarpanah M, Szmukler-Moncler S. Immediate loading of dental implants. Theory and Practice, Chicago, IL: Quintessence Publishing, 2008.
30. Saadoun AP, LeGall MG, Touati B. Current Trends in Implantology. Part 1. Biological response, implant stability and implant design. *Pract Proced Aesthet Dent* 2004; 17:529–535.

31. Testori T, Bianchi F, Del Fabbro M, et al. Implant aesthetic score for evaluating the outcome: immediate loading in the aesthetic zone. *Pract Proced Aesthet Dent* 2005; 17:123–130.
32. Nkenke E, Hahn M, Weinzierl K, Radespiel-Troger M, Neukam FW, Engelke K. Implant stability and histomorphometry: a correlation study in human cadavers using stepped cylinder implants. *Clin Oral Implants Res* 2003; 14:601–609.
33. Schlegel KA, Kloss FR, Kessler P, Schultze-Mosgau S, Nkenke E, Wiltfang J. Bone conditioning to enhance implant osseointegration: an experimental study in pigs. *Int J Oral Maxillofac Implants* 2003; 18:505–511.

Copyright of Clinical Implant Dentistry & Related Research is the property of Wiley-Blackwell and its content may not be copied or emailed to multiple sites or posted to a listserv without the copyright holder's express written permission. However, users may print, download, or email articles for individual use.