

# Root resorption of the maxillary lateral incisor caused by impacted canine: a literature review

A. Alqerban · R. Jacobs · P. Lambrechts · G. Loozen · G. Willems

Received: 10 June 2008 / Accepted: 25 February 2009 / Published online: 11 March 2009  
© Springer-Verlag 2009

**Abstract** Root resorption of maxillary lateral incisors caused by erupting canines is well known and a relatively common phenomenon. However, much debate and conflicting evidence exists with regard to the actual resorption trigger and potential etiological factors involved. Consequently, there are no obvious clinical clues concerning prevention and diagnosis as well as subsequent treatment decisions. The introduction of cone beam computer tomography has recently allowed drawing a new and much more documented light on the diagnostic and therapeutic strategies. However, no investigations have determined that this new information may result in another and better diagnostic approach and an improved treatment outcome. Therefore, the present review will attempt to summarize the existing evidence on two- and three-dimensional images and try to link the radiological observations to any further preventive, diagnostic, and/or therapeutic measures. Detection thresholds, accuracy, and reliability of impacted canine localization and neighboring root resorption risks will also

be considered. This review demonstrates how adding a third-dimension to the radiographic information may notably alter the prevalence of root resorptions and descriptions of this prevalence. In any case, further investigation is needed to determine resorption detection thresholds in various two-dimensional and three-dimensional imaging techniques, as well as to determine therapeutic thresholds and criteria for strategic tooth extraction based on radiographic manifest and not manageable resorption lesions.

**Keywords** Tooth impaction · Root resorption · Canine · Incisor · Cone beam CT

## Introduction

Root resorption is defined as a condition of dental complication associated with either a physiological or pathological activity of the tooth resorbing cells, which results in loss of cementum and /or dentine [55]. Root resorption is very difficult to treat and usually requires extraction of the affected tooth. Impaction is defined as a failure of tooth eruption at its appropriate site in the dental arch within the normal period of growth based on clinical and radiographic assessment [53]. Permanent maxillary canines are the second most frequently impacted teeth after the third molars [53]. At the same time, maxillary canines are important esthetically and functionally [23]. An impacted canine is usually diagnosed on routine examination, and if so, this can cause additional problems during the development and eruption of the impacted tooth and the neighboring teeth. The process of permanent tooth eruption and movement into final functional position is complicated and comprises a series of events. The maxillary canines

---

A. Alqerban · G. Willems (✉)  
Department of Orthodontics, Faculty of Medicine,  
School of Dentistry, Oral Pathology and Maxillo-Facial Surgery,  
Katholieke Universiteit Leuven,  
Kapucijnenvoer 7,  
3000 Leuven, Belgium  
e-mail: guy.willems@med.kuleuven.be

R. Jacobs  
Oral Imaging Center, School of Dentistry, Oral Pathology  
and Maxillo-Facial Surgery, Katholieke Universiteit Leuven,  
Leuven, Belgium

P. Lambrechts · G. Loozen  
Leuven BIOMAT Research Cluster, Department of Conservative  
Dentistry, School of Dentistry, Oral Pathology and Maxillo-Facial  
Surgery, Katholieke Universiteit Leuven,  
Leuven, Belgium

develop relatively late and emerge into the oral cavity after the neighboring incisors have erupted. The germ of the canine is situated high in the maxilla of 3-year-old children, and the crown is mesially and palatally directed [15]. When the canine migrates down and forward toward the occlusal plane, the tooth gradually becomes more upright until it reaches the distal aspect of the lateral incisor root and mesial aspect of the root apex of deciduous canine [11, 13, 15]. If this process does not follow such a trajectory, the canine becomes more impacted. Unfortunately, the potential occurrence of impacted maxillary cuspids has an effect on neighboring structures, and likewise, its prevention and treatment approach remain a matter of debate. The present review attempts to address those issues, making a state-of-the-art report including the potential role of cone beam computed tomography (CBCT) imaging as an improved approach to determine canine impaction-associated root resorption of adjacent teeth.

### Etiology of the ectopic canine

The exact etiology of impacted maxillary cuspids is unknown. However, two common theories may explain the phenomenon of the palatally impacted canine: the guidance theory and the genetic theory. The “guidance theory of palatal canine displacement” suggests that this anomaly is a result of local predisposing factors such as congenitally missing lateral incisors, supernumerary teeth, odontomas, transposition of teeth, and other mechanical determinants that all interfere with the eruption path of the canine [8, 25, 54]. The second theory for canine impaction is “the genetic theory”. In addition, there are some factors that are thought to cause canine impaction such as obstruction, abnormal position of tooth bud, lack of guidance along the root of the lateral incisor, dental crowding, long and complicated path of eruption, late eruption date, early loss of deciduous canine, prolonged retention of the deciduous teeth, and systemic disease [4, 10, 16, 20, 27]. Palatally impacted maxillary cuspids are often present along with some dental abnormalities including tooth size, shape, number, and structure which have a hereditary background [7]. These

factors are associated with such anomalies as hypoplastic enamel, infra-occluded primary molars, and aplastic second bicuspid [3]. Inadequate arch space and a vertical developmental position are often associated with buccal canine impactions [43].

### Incidence of canine impaction

The incidence of impacted maxillary canines varies from 1% to 3% [14, 54]. The incidence of palatally displaced canines in the Caucasian population is approximately 2% [40] and 1.2% in African-Americans [31]. Canine impactions are most frequently buccally located in the Asian populations [33, 39]. The reported percentage of palatally impacted canines also varies widely among studies. For instance, in a study of 44 patients, Stivaros and Mandall [51] reported canine impaction with a palatal location in 61% of patients and a labial location in 5% patients, while the remaining 34% were located in line with the arch. Rimes et al. [44] reported 26 patients with 32 impacted canines of which 14 were located palatally, 12 buccally, and six in line with the arch. Szarmach et al. [52] found 102 impacted canines ( $n=82$  patients) with distributions of 67%, 20%, and 13%, respectively. Ericson and Kurol [18] reported that 20% of impacted canines were buccally placed, and 80% were either palatal or distal to the lateral incisors, with an estimated 8% of these being bilateral impactions. In a CT study, Bjerklin and Ericson [6] found even more buccally placed canines, with respective numbers of 42% (palatal), 40% (buccal), and 18% (in line with the arch) for 113 impacted canines. The incidence of detecting impaction may increase through the utilization of three-dimensional imaging techniques, such as CBCT for dentomaxillofacial applications, resulting in similar percentages to those indicated during CT studies. Indeed, Liu et al. [33] found in 210 patients utilizing CBCT that impacted canines were located palatally in 41%, labially in 45%, and midalveolus in 14% of cases. A CBCT study by Walker et al. [56] found that 25 of 27 impactions ( $n=19$  patient) were located palatally, and two were located labially (Table 1). The detectability and diagnostic

**Table 1** Relative position of impacted canines in maxilla according to various studies

Authors reporting impacted canines	Palatally (%)	Buccally (%)	In line with the arch (%)
Stivaros and Mandall [51]	61	5	34
Rimes et al. [44]	44	38	19
Szarmach [52]	67	20	13
Ericson and Kurol [18]	80	20	–
Bjerklin and Ericson [6]	42	40	18
Liu et al. [33]	41	45	14
Walker et al. [56]	93	7	–

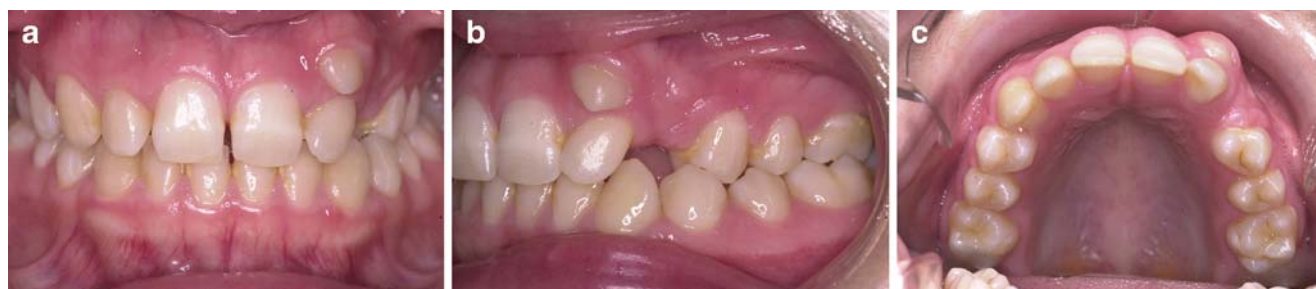methods used, gender, biological group, and skeletal jaw may influence the incidence of impactions. These data demonstrated that randomized controlled trials using CBCT imaging are necessary to evaluate the true effect of the aforementioned variables and, therefore, be capable of controlling for those variables during prognosis in a specific patient population.

### Sequela of maxillary canine impaction

Untreated partially erupted or impacted canines may result in several complications like displacement and loss of vitality of the adjacent incisors, shortening of the dental arch, formation of follicular cysts, canine ankylosis, recurrent infections, recurrent pain, internal resorption, external resorption of the canine and the adjacent teeth, or combinations of the these factors [50]. The external resorption of the adjacent teeth is a major concern, and the most common sequela of impacted canines can potentially result in tooth loss. The proper diagnosis and early intervention may surely influence any further treatment strategy or final outcome. This process often remains asymptomatic. Furthermore, once root resorption is clinically diagnosed, the process may already be at an advanced stage that is not treatable [57]. The etiology of the resorption is unclear and a complex biological process that is not well understood. The reason behind the resorption of some incisor roots due to the pressure of erupting, and the lack of this effect in other incisors, is unknown [10]. Several possible etiologic factors for root resorption have been identified, such as genetic, trauma, and particular habits, but no clear causal relationship has been established [21, 28]. Most studies have focused on root resorption caused by palatal canines, although buccal canines can also cause incisor resorption [28, 33, 44] (Figs. 1, 2, 3). Nevertheless, one also should bear in mind that canine teeth can cause root resorption of neighboring maxillary premolars [13, 56].

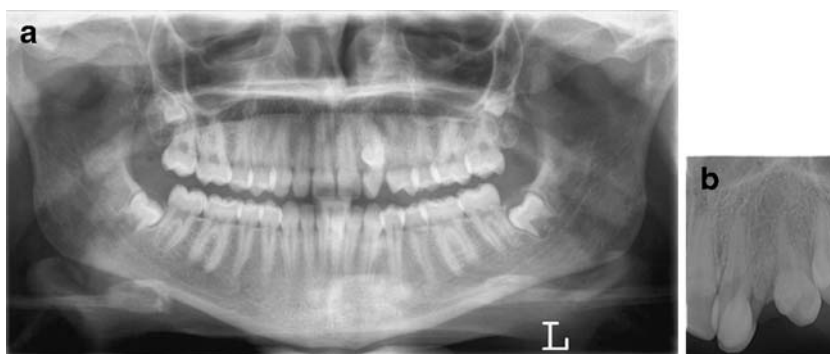### Diagnosis of canine impaction

Diagnostic methods that may allow for the early detection and prevention of canine impaction could reduce treatment time, complexity, complications, and costs. This method should include family history, visual inspection, and tactile clinical examinations by the age of 9–10-year old [16]. Patients with deep bite, missing lateral incisors, prolonged retention of deciduous canine, or peg-shaped upper lateral incisors need further investigation [27]. Palatally erupting canines have been indicated to frequently correct themselves with early removal of the primary canines, which has been recommended as the treatment of choice in appropriate patients [17]. A radiographic examination is an essential part of the diagnostic process in case of an impacted canine. Until recently, 2D radiological imaging was the standard method of choice due to the relatively low emitted radiation dose and availability of this procedure in the standard dental office. Several 2D radiographic techniques have been used for differential diagnosis of root resorption, including periapical, occlusal, panoramic, and cephalometric radiographs or a combination of these approaches [35, 36]. In 2D images, many structures overlap as complex 3D structures are projected onto plain film. The panoramic radiograph is user-friendly and noninvasive, and it provides helpful information regarding the dental age, symmetry, number of teeth present, sequence of dental eruption, and presence of pathology or variations with respect to the norm and treatment results. However, it might be useful in detecting the intra-alveolar location of malpositioned and unerupted canines. For instance, the canine occasionally becomes palatally impacted when the canine cusp tip is located mesial to the long axis of the erupted lateral incisor, or the canine occasionally becomes palatally impacted when the canine cusp tip overlays the distal half of the lateral incisor root [32]. Moreover, structures closer to the X-ray source appear more magnified than those closer to the detector [23]. Tooth distortion and superimposition should be taken into consideration as factors that reduce the



**Fig. 1** Clinical intraoral photographs of a 20-year-old female patient showing an impacted upper left canine: **a** frontal view, **b** sagittal view, **c** occlusal view

**Fig. 2** A series of 2D images taken as a routine procedure for orthodontic treatment reveals an impacted upper left canine with no sign of resorption in lateral incisor tooth #22. **a** Panoramic image confirming the impacted canine position, **b** Intraoral periapical film showing the relative position of the impacted canine with intact root contour and no resorption is visible in tooth #22



diagnostic accuracy of panoramic radiograph. In addition, using panoramic radiography for the detection of root resorption has a restricted diagnostic value because the accuracy of assessing palatal or buccal root resorption of the lateral incisor is limited, particularly in early or mild resorption cases [18, 22, 24, 42]. Furthermore, conventional radiological imaging techniques, such as panoramic imaging, have been found inadequate for the diagnosis of root resorption in the maxillary incisors with impacted canines [23] (Figs. 1, 2).

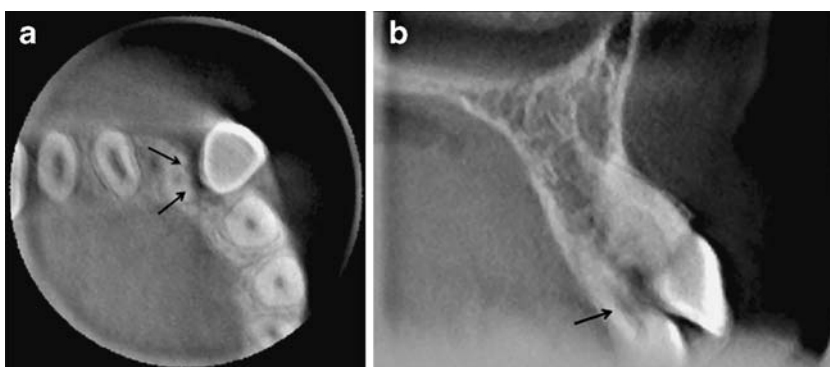
Assessing root resorption and changes in the root surface typically requires 3D information. Therefore, the utilization of three-dimensional images has been suggested, especially when the root of the canine is suspected to become ankylosed or when the lateral incisor root is likely to exhibit resorption lesions [19]. CT can detect the position of the impacted canine as well as the extent and exact location of the lateral incisor root resorption, which could not be detected by classic radiographic approaches [20]. CT scans should be performed whenever suspicion arises that the roots could be moderately to severely resorbed [47]. A major disadvantage of CT is the high radiation dose, particularly for young children that are assumed to carry the incurred radiation burden for a longer period of time and since developing organs of children are more sensitive to radiation effects than adults [24, 49]. Recently, the CBCT units with reduced radiation exposure and 3D imaging of the dental structures were introduced. Various CBCT devices have been brought to the market in the last

years. The different devices vary in field of volume and resolution of the area of interest. All CBCT systems use the same technology with slight difference in the detector type. Cone beam machines emit a conical-shaped X-ray beam [49]. Voxels are isotropic and can be as small as 0.125 mm. The size of voxels determines the image resolution [49]. CBCT makes it possible to reconstruct the area of interest in three dimensions. Furthermore, the digital data presentation allows further export to dedicated software for advanced analysis and even preoperative treatment planning. Compared with conventional 2D images, CBCT images provide applicable diagnostic information of dental structures overlap-free in sagittal, axial, and coronal planes. Dentomaxillofacial CBCT provides an alternative to traditional CT systems using significantly less radiation dose and shorter acquisition scan times, and it provides invaluable information regarding impacted canines with submillimeter spatial resolution images of high diagnostic quality to better understand and improve treatment at lower cost [24, 30, 49, 56] (Fig. 3). CBCT has been proven to be superior to other radiographic methods in visualizing the maxillofacial region among which diagnosing position and complications of ectopically erupting teeth [12, 30, 33, 56].

#### The role of the dental follicle of impacted canines

In many studies, there appears to be no association between enlarged canine follicles and resorption [18, 26]. Ericson

**Fig. 3** A CBCT image shows an impacted upper left canine and severe resorption in the cervical third of the lateral incisor tooth #22 (arrows) in 3D Radiographs CBCT from Accuitomo 3D (Accuitomo, Morita, Kyoto, Japan). **a** Axial view, **b** cross-sectional view at the level of the vestibular root resorption lesion





and Kurol [18] reported an incidence of enlarged follicle in 23%. They also compared the resorption group to a control group with ectopically positioned canines that did not develop incisor root resorption and found that the incidence of follicular enlargement was not significantly different to the resorption group from which they concluded that follicular enlargement was not a factor in the etiology [17]. Indeed, such follicle may prevent direct tooth contact between canine enamel and incisor root cementum. Morphological and histological studies have shown that the dental follicle of the canine will often expose the root of the adjacent incisor during eruption without resorbing any of the hard tissues of the root provided that eruption proceeds normally [17–19]. In a CT study by Ericson and Bjerklín [15] ( $n=107$  children), it was confirmed that the dental follicle of ectopically erupting canine does not cause resorption of the adjacent permanent incisor, and the resorption seemed unrelated to follicular width and shape. In the same study, the follicle seemed to cause resorption of the periodontal contour of the lateral incisor during eruption and resorption of the root of the adjacent deciduous canine [15]. However, the retaining or resorption of the deciduous canine cannot be linked to incisor root resorption [17]. On the other hand, once direct tooth contact is present, the risk for root resorption may be increased.

### Incidence of lateral incisors root resorption

In the past, 2D imaging techniques, such as the combination of panoramic and occlusal images, were most often used to study impacted canines and potentially related tooth impaction. Many studies have found incisor resorption to be more common in females, with the female/male ratio varying between 2:1 [6, 9, 21, 44], 3:1 [20], 4:1 [17, 56], and 10:1 [2]. No gender differences have been found either in the severity or location of root resorption [17]. The maxillary lateral incisor root is the area most commonly affected by ectopic eruption of the canine, with several reasons for this association: (1) the root has a conical shape, (2) demonstrates the highest rate of abnormal root shapes, (3) has developmental anomalies like dens invaginatus, (4) the roots are more susceptible to resorption during their developing stage, (5) the apex is deeply located in the palate where impacted canines often develop, and (6) is the third most commonly missing tooth after third molars and lower second premolars [2, 45, 46]. Brin et al. [9] found that if there was a deviation in the canine eruption path, then the tooth would be more likely to hit and resorb incisors with normal tooth size than a small peg shape or small mesiodistal width tooth. Moreover, Kook et al. [29] found that the pattern of external root resorption for peg-shaped lateral incisors and small lateral incisors was not at

great risk with orthodontic treatment. Even so, several authors have shown that roots with abnormal shape have a higher susceptibility of apical root resorption during orthodontic movement [38]. Sameshima and Sinclair [46] reported in 860 cases that dilacerated lateral incisor and pointed teeth have greater root resorption. One report found that small roots resorbed in orthodontic treatment almost twice as much as all other root forms [38]. However, many studies found no differences between adults and children for external apical root resorption during orthodontic treatment [1, 37, 38, 46].

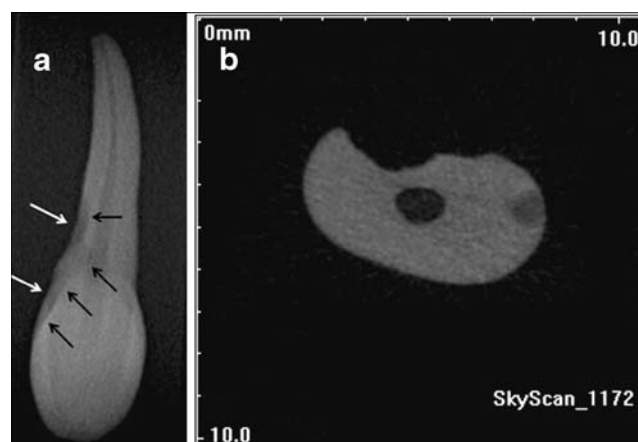
The central incisors can also be affected by the impacted canine [28, 44]. Resorption can be unilateral or bilateral and can affect all upper incisors. Sasakura [48] had only one patient with three incisors resorbed and none with all four incisors resorbed from a group of 11 patients. Ericson and Kurol [17] had no cases with resorption of all four incisors. Only three children had bilateral resorption of the lateral incisors in their study of 41 patients. Rimes et al. [44] studied 26 patients with root resorption of 26 lateral incisors and nine central incisors of which eight were affected bilaterally, and no patient had all four incisors resorbed. However, Szarmach et al. [52] found in 82 patients with impacted canines only five with lateral incisor resorption, four bilaterally, and one patient unilaterally. Tomography was acknowledged to diagnose resorption reliably [21]. Even using CT, Ericson and Kurol [22] found that only seven out of 156 canines caused resorption of both central and lateral incisors. In a study of consecutive cases of unerupted maxillary canines, resorptions were not found before 10 years of age, which indicates that canine position should be evaluated at no later than 10 to 11 years of age [17]. According to Ericson and Kurol [18], radiographic investigation of the upper canines is generally unnecessary before 10 years of age. This study determined that 8% of children over 10 years of age require a supplementary radiographic investigation to reveal the exact position of the canine. After such an investigation, 1.5% of canines were shown to be impacted. The complication of incisor root resorption due to impacted maxillary canines has been underestimated because of the difficulty in identifying the affected teeth. The reported prevalence of root resorptions of the maxillary incisors clearly depended on the diagnostic procedure and the imaging technique. Superimposition of the incisor roots and the crown of an impacted canine on intraoral radiographs obscured the root morphology in 45% of cases [18]. Resorption was consistently found in patients in whom the cusp of the maxillary canine was positioned medially to the midline of the lateral incisor in panoramic and periapical films [20].

Cross-sectional and three-dimensional imaging may overcome this problem, allowing for more accurate diag-

nosis of root resorption. When using tomography and intraoral radiographs, incisor root resorption was found to be associated with 12.5% of impacted canines [18]. This is twice the frequency detected when intraoral radiographs were only used. CT provides highly detailed images of impacted canine location and root resorption [19, 21]. Using stepwise radiographs, Ericson and Kurol [17, 18] found that lateral incisor root resorption occurred in approximately 12% of the impacted maxillary canine population. Later on, with CT of the maxilla, they found resorption occurring in 38% of maxillary lateral incisors and 9% of central incisor roots in a population of 107 children with ectopically erupting canines [22]. Ericson and Kurol [21] found a high correlation in the diagnosis of root resorption between the CT and clinical findings of extracted teeth. They found resorptions were similar in depth and pulpal involvement of the extracted teeth. Resorption was associated with approximately 48% of impacted maxillary canines [21]. In another study, Bjerklin and Ericson [6] found that 49% of the patients exhibited root resorption in a group of 80 patients. CBCT in 210 ectopically impacted maxillary canines showed incisor root resorption in 27% of lateral incisors and 23% of central incisors [33]. Walker et al. [56] reviewed 27 cases of impacted canines with CBCT and found lateral incisor root resorption and central incisor root resorption in 18 and 3 of those cases respectively. (Table 2; Fig. 4). Compared with conventional radiographic methods such as intraoral and panoramic radiographs, the amount of resorption detected by CT scanning was approximately 50% higher [18, 20, 22].

### Degree of root resorption

Various clinically applicable scoring methods have been developed to determine the degree or severity of the resorption lesion. Malmgren et al. [34] established a method based on scoring the degree of root resorption on the mesial and distal aspect as follows: first degree of resorption as an irregular root contour, second degree of resorption as less than 2 mm of the assessed original root length, third degree of resorption between 2 mm and one third of the assessed original root length, and fourth degree root resorption



**Fig. 4** **a** Periapical film showing the extent of resorption in cervical third of the upper left lateral incisor after extraction (arrows); **b** a cross-sectional view of a Micro CT image shows the upper left lateral incisor after extraction with severe resorption in cervical third of the root (SkyScan 1172 high resolution Micro CT, Kontich, Belgium)

exceeding one third of the assessed original root length. Peene et al. [41] established three degrees of root resorption that can be determined with CT. In the “degree=0,” there is close contact between the roots of adjacent teeth, and the cross-sectional outline has a normal appearance. In degree 1, root resorption is present without involvement of the pulpal canal and in “degree=2,” the resorption reaches the pulpal canal with complete breakdown of the cementodentine line. However, many studies use the Ericson and Kurol [21, 22] classification of root resorption severity. The resorptions are graded in the following four categories: (1) no resorption, intact root surfaces and the cementum layer may be lost; (2) slight resorption, resorption up to half of the dentine thickness to the pulp; (3) moderate resorption, resorption midway to the pulp or more, the pulp lining being unbroken; (4) severe resorption, the pulp is exposed by the resorption.

### Location of lateral incisor root resorption

The apical and middle thirds of the incisor roots are most commonly resorbed. Ericson and Kurol [17] found that 82% of the laterals were resorbed in the middle third and 13% apically, with the remainder cervically resorbed. Half of the resorbed lateral incisors and one out of the six resorbed central incisors showed resorption reaching the pulp. In this study, 33% of the lateral incisors with root resorption appeared normal on conventional dental periapical radiographs. Medial inclination of the ectopically erupting canine, overlapping more than 50% of the lateral incisor, and the impacted canines with well-developed roots presented the greatest risks to cause resorption of the lateral incisors [18]. Rimes et al. [44] found that 60% were

**Table 2** Incidence of resorption of lateral and central incisors caused by maxillary impacted canine

Authors reporting incidence of resorption of lateral and central incisors	Lateral incisor (%)	Central incisor (%)
Ericson and Kurol in CT study[22]	38	9
Liu et al. [33]	27	23
Walker et al. [56]	67	11

resorbed in the apical and middle thirds, 31% apically resorbed, and 9% were resorbed in the cervical third with or without the middle third. Interesting to know is that 30 of the 35 resorbed incisors used in this study had resorption into the pulp [44]. Brin et al. [9] found lateral incisors were resorbed by at least one third of the original root length in 60% of cases. Most interestingly, even with pulpal involvement, lateral incisors with root resorption did not have clinical symptoms. Using CT, Ericson and Kurol [22] reported that maxillary incisor resorption occurred most commonly in the middle third of the roots, on the labial or lingual surfaces, with 60% of the resorbed lateral incisors and 43% of the resorbed central incisors having pulpal involvement (Table 3).

### Treatment strategies

Impacted maxillary canines are routinely seen in orthodontic practice. Orthodontists are typically using different approaches in terms of treatment of impacted canines. The primary issue to consider when setting up the treatment plan for impacted maxillary canines is to rule out if root resorption is present on the adjacent teeth and if so, to establish the severity of the diagnosed resorption. The diagnosis of lateral incisor root resorption can then modify the treatment plan. In cases of severe root resorption, the risk of losing the tooth should be considered during or after the treatment. In patients with lack of space, extraction of severely resorbed lateral incisor may be a better option than removing intact premolars [6]. Bjerklin and Ericson [6] compared treatment plans of 80 children with impacted maxillary canines before and after information gained from a CT examination. The result showed the information obtained from the CT images modified the treatment plans for 44% of the 80 children and 54% of those children showed incisor root resorption. Consequently, with conventional radiography 11 patients with undiagnosed severe root resorption, would have received a treatment plan with premolar removal rather than extraction of the affected incisors. In this study [6], CT imaging brought new and valuable information regarding the location of impacted canines and resorption of

adjacent incisors. A recent study on clinical management of ectopic canines by Bjerklin and Bondemark [5] found that orthodontists adopted their approach to treatment when supplementary CT information was available on the extent of root resorption present on the maxillary lateral incisors, especially when resorption was diagnosed half-way between external dentin surface and pulp or more. In those cases, treatment planning changed drastically. Instead of keeping the lateral incisor in the arch, this tooth was now extracted based on the amount of root resorption visualized on CT.

CBCT adds useful information regarding the condition of the adjacent root and is valuable in the detection of root resorption associated with impacted canines [33, 56]. A routine panoramic radiograph could impossibly show that detailed information because of its 2D limitations, inherent deformation, and low resolution. Another advantage of the CBCT information gain is the exact 3D position of the impacted canine and the correct interpretation of its possible eruption path. This positional information allows the surgeon to more accurately expose the impacted canine in a minimally invasive procedure when the treatment plan incorporates the open or closed eruption technique. Furthermore, complete 3D morphological information on the canine allows diagnosis of apical deformations possibly slowing down guided or open eruption techniques.

Preventive measures could also be taken with an early diagnosis of an impacted canine when 3D information would predict an unfavorable eruption pathway for the canine. As CBCT image data could localize the canine and its eruption path, a potential direct contact between the canine enamel and the lateral incisor's root cementum might be predicted, thus creating a risk for incisor root resorption. In such cases, some treatment steps might be reversed. Rather than opting to start opening a space for canine eruption by an orthodontic correction with fixed appliances, one could then consider to primarily go for a premature removal of the deciduous canine allowing for a partial or full normalization of the canine eruption.

### Conclusion

Resorption of the incisors is very difficult to diagnose. Early diagnosis of impacted canine and root resorption might have further reduced complications during treatment and the presence or absence of root resorption will determine the treatment plan. The risk of root resorption in children with displaced canines must not be neglected. If there is no evidence of primary canine root resorption the displaced or impacted maxillary canine should be suspected. Every dentist should palpate the maxillary permanent canines by 9 to 10 years of age or earlier and take radiographs as needed. The severity of lateral incisor

**Table 3** Location of the root resorption of the lateral incisors

Authors describing impacted canine related resorption	Apical tip (%)	Apical third (%)	Middle third (%)	Cervical third (%)
Rimes et al [44]	–	31	60	9
Ericson and Kurol [21]	–	13	82	5
Ericson and Kurol in CT [22]	31	43	21	5

root resorption cannot be accurately judged from two-dimensional radiographs alone. Two-dimensional radiographs are easy to use and provide useful information, although these images fail to detect the exact localization of the canines or any potential root resorption, especially with early or mild root resorption. Moreover, CBCT has a smaller radiation dose compared to CT and overcomes the limitations of conventional radiography. Therefore, CBCT is a useful method for diagnosing the position, inclination, distance from adjacent structures, complications of impacted canines, and detection of lateral incisors root resorption. Furthermore, this method may have a significant impact on diagnostic and therapeutic interventions.

**Conflict of interest** The authors declare that they have no conflict of interest.

## References

1. Amlani MS, Inocencio F, Hatibovic-Kofman S (2007) Lateral incisor root resorption and active orthodontic treatment in the early mixed dentition. *Eur J Paediatr Dent* 8:188–192
2. Arens DE (1995) An alternative treatment for severely resorbed maxillary lateral incisor: a sequela of ectopic eruption. *J Endod* 21:95–100
3. Baccetti T (1998) A controlled study of associated dental anomalies. *Angle Orthod* 68:267–274
4. Bishara SE (1992) Impacted maxillary canines: a review. *Am J Orthod Dentofacial Orthop* 101:159–171
5. Bjerklin K, Bondemark L (2008) Management of ectopic maxillary canines: variations among orthodontists. *Angle Orthod* 78:852–859
6. Bjerklin K, Ericson S (2006) How a computerized tomography examination changed the treatment plans of 80 children with retained and ectopically positioned maxillary canines. *Angle Orthod* 76:43–51
7. Bjerklin K, Kurol J, Valentin J (1992) Ectopic eruption of maxillary first permanent molars and association with other tooth and developmental disturbances. *Eur J Orthod* 14:369–375
8. Brin I, Becker A, Shalhav M (1986) Position of the maxillary permanent canine in relation to anomalous or missing lateral incisors: a population study. *Eur J Orthod* 8:12–16
9. Brin I, Becker A, Zilberman Y (1998) Resorbed lateral incisors adjacent to impacted canines have normal crown size. *Am J Orthod Dentofacial Orthop* 104:60–66
10. Brin I, Solomon Y, Zilberman Y (1993) Trauma as a possible etiologic factor in maxillary canine impaction. *Am J Orthod Dentofacial Orthop* 104:132–137
11. Burdi AE, Moyers RE (1988) Development of the dentition and the occlusion. *Handbook of Orthodontics*. 4th ed Chicago, Ill: Year Book Medical Publishers Inc 140
12. Chen Y, Duan P, Meng Y et al (2006) Three-dimensional spiral computed tomographic imaging: a new approach to the diagnosis and treatment planning of impacted teeth. *Am J Orthod Dentofacial Orthop* 130:112–116
13. Cooke ME, Nute SJ (2005) Maxillary premolar resorption by canines: three case reports. *Int J of Paed Dent* 15:210–212
14. Dachi SF, Howell FV (1961) A survey of 3, 874 routine full mouth radiographs. *Oral Surg Oral Med and Oral Pathol* 14:1165–1169
15. Ericson S, Bjerklin K (2002) Does the Canine Dental Follicle Cause Resorption of Permanent Incisor Roots? A Computed Tomographic Study of Erupting Maxillary Canines. *Angle Orthod* 72:95–104
16. Ericson S, Kurol J (1986) Radiographic assessment of maxillary canine eruption in children with clinical signs of eruption disturbance. *Eur J Orthod* 8:133–140
17. Ericson S, Kurol J (1987) Incisor resorption caused by maxillary cuspids: a radiographic study. *Angle Orthod* 57:332–346
18. Ericson S, Kurol J (1987) Radiographic examination of ectopically erupting maxillary canines. *Am J Orthod Dentofacial Orthop* 91:483–492
19. Ericson S, Kurol J (1988) CT diagnosis of ectopically erupting maxillary canines - a case report. *Eur J of Orthod* 10:115–121
20. Ericson S, Kurol J (1988) Resorption of maxillary lateral incisors caused by ectopic eruption of the canines. A clinical and radiographic analysis of predisposing factors. *Am J Orthod Dentofacial Orthop* 94:503–513
21. Ericson S, Kurol J (2000) Incisor root resorptions due to ectopic maxillary canines imaged by computerised tomography: a comparative study in extracted teeth. *Angle Orthod* 70:276–283
22. Ericson S, Kurol J (2000) Resorption of incisors after ectopic eruption of maxillary canines: a CT study. *Angle Orthod* 70:415–423
23. Freisfeld M, Dahl IA, Jäger A et al (1999) X-ray diagnosis of impacted upper canines in panoramic radiographs and computed tomographs. *J Orofac Orthop* 60:177–184
24. Heimisdottir K, Bosshardt D, Ruf S (2005) Can the severity of root resorption be accurately judged by means of radiographs? A case report with histology. *Am J Orthod Dentofacial Orthop* 128:106–109
25. Hitchin AD (1951) The impacted maxillary canine. *Dent Pract Dent Rec* 2:100–103
26. Howard RD (1970/1971) The displaced maxillary canine: positional variations associated with incisor resorption. *Trans Br Soc Study Orthod* 57:149–157
27. Jacoby H (1983) The etiology of maxillary canine impactions. *Am J Orthod* 84:125–132
28. Knight H (1987) Tooth resorption associated with the eruption of maxillary canines. *Br J Orthod* 14:21–31
29. Kook YA, Park S, Sameshima GT (2003) Peg-shaped and small lateral incisors not at higher risk for root resorption. *Am J Orthod Dentofacial Orthop* 123:253–258
30. Korbmacher H, Kahl-Nieke B, Schöllchen M et al (2007) Value of two cone-beam computed tomography systems from an orthodontic point of view. *J Orofac Orthop* 68:278–289
31. Kramer RM, Williams AC (1970) The incidence of impacted teeth. A survey at Harlem hospital. *Oral Surg Oral Med Oral Pathol* 29:237–241
32. Lindauer SJ, Rubenstein LK, Hang WM et al (1992) Canine impaction identified early with panoramic radiographs. *J Am Dent Assoc* 123:91–97
33. Liu DG, Zhang WL, Zang ZY et al (2008) Localization of impacted maxillary canines and observation of adjacent incisor resorption with cone-beam computed tomography. *Oral Surg Oral Med Oral Pathol Oral Radiol Endod* 105:91–98
34. Malmgren O, Goldson L, Hill C et al (1982) Root resorption after orthodontic treatment of traumatized teeth. *Am J Orthod* 82:487–491
35. Mason C, Papadakou P, Roberts GJ (2003) The radiographic localization of impacted canines: a comparison of methods. *Eur J Orthod* 23:25–34



36. Maverna R, Gracco A (2007) Different diagnostic tools for the localization of impacted maxillary canines: clinical considerations. *Prog Orthod* 8:28–44
37. Mirabella AD, Artun J (1995) Prevalence and severity of apical root resorption of maxillary anterior teeth in adult orthodontic patients. *Eur J Orthod* 17:93–99
38. Nigul K, Jagomagi T (2006) Factors related to apical root resorption of maxillary incisors in orthodontic patients. *Stomatologija* 8:76–79
39. Oliver RG, Mannion JE, Robinson JM (1989) Morphology of the lateral incisor in cases of unilateral impaction of maxillary canine. *Br J Orthod* 19:9–16
40. Peck S, Peck L, Kataja M (1994) The palatally displaced canine as a dental anomaly of genetic origin. *Angle Orthod* 64:249–256
41. Peene P, Lamoral Y, Plas H et al (1990) Resorption of the lateral maxillary incisor: assessment by CT. *J Comput Assist Tomogr* 14:427–429
42. Preda L, La Fianza A, Di Maggio EM et al (1997) The use of spiral computed tomography in the localization of impacted maxillary canines. *Dentomaxillofac Radiol* 26:236–241
43. Rayne J (1969) The unerupted maxillary canine. *Dent Pract Dent Rec* 19:194–204
44. Rimes RJ, Mitchell CN, Willmot DR (1997) Maxillary incisor resorption in relation to the ectopic canine: a review of 26 patients. *Eur J of Orthod* 19:79–84
45. Saldarriaga JR, Patiño MC (2003) Ectopic eruption and severe root resorption. *Am J Orthod Dentofacial Orthop* 123:259–265
46. Sameshima GT, Sinclair PM (2001) Predicting and preventing root resorption: Part I. Diagnostic factors. *Am J Orthod Dentofacial Orthop* 119:505–510
47. Sameshima GT, Sinclair PM (2001) Predicting and preventing root resorption: Part II. Treatment factors. *Am J Orthod Dentofacial Orthop* 119:511–515
48. Sasakura H, Yoshida T, Murayama S et al (1984) Root resorption of upper permanent incisor caused by impacted canine. An analysis of 23 cases. *Int J Oral Surg* 13:299–306
49. Scarfe WC, Farman AG, Sukovic P (2006) Clinical applications of cone-beam computed tomography in dental practice. *J Can Dent Assoc* 72:75–80
50. Shafer WG, Hine MK, Levy BM (1984) A textbook of oral pathology, 4th edn. W.B. Saunders, Philadelphia
51. Stivaros N, Mandall NA (2000) Radiographic factors affecting the management of impacted upper permanent canines. *J Orthod* 27:169–173
52. Szarmach JJ, Szarmach J, Waszkiel D (2006) Complications in the course of surgical-orthodontic treatment of impacted maxillary canines. *Adv Med Sci* 51(Suppl 1):217–220
53. Thilander B, Jakobsson SO (1968) Local factors in impaction of maxillary canines. *Acta Odontol Scand* 26:145–168
54. Thilander B, Myrberg N (1973) The prevalence of malocclusion in Swedish schoolchildren. *Scand J Dent Res* 81:12–21
55. Tronstad L (1988) Root resorption - etiology, terminology and clinical manifestations. *Endodont Dent Traumatol* 4:241–252
56. Walker L, Enciso R, Mah J (2005) Three-dimensional localization of maxillary canines with cone-beam computed tomography. *Am J Orthod Dentofacial Orthop* 128:418–423
57. Westphalen VP, Gomes de Moraes I, Westphalen FH et al (2004) Conventional and digital radiographic methods in the detection of simulated external root resorptions: a comparative study. *Dentomaxillofac Radiol* 33:233–235

Copyright of Clinical Oral Investigations is the property of Springer Science & Business Media B.V. and its content may not be copied or emailed to multiple sites or posted to a listserv without the copyright holder's express written permission. However, users may print, download, or email articles for individual use.