

Toluidine blue color perception in identification of oral mucosal lesions

Pelin Güneri · Joel B. Epstein · Selin Ergün · Hayal Boyacıoğlu

Received: 12 October 2009 / Accepted: 18 February 2010 / Published online: 25 March 2010
© Springer-Verlag 2010

Abstract The objective of this study is to examine observer agreement on the rank of the color tones after toluidine blue staining of a mucosal lesion. Cohort study with repeated measures is the design of the study. Twenty observers ranked and scored 8 specified areas on the color images of a lesion before and after toluidine blue application in two sessions. Inter and intra-observer variations were analyzed with Cohen's kappa. The L* (the black-white axis), a* (red-green axis), and b* (yellow-blue axis) values were measured and set as the gold standards. Intra and inter-observer agreements were $\kappa=0.86$ and $\kappa=0.854$. All color parameters were effective on the color ranking order ($pL^*=0.00$, $pa^*=0.007$, $pb^*=0.00$), although L* and b* were more effective on the ranking of the samples than a*. Areas that appeared pale blue visually had a significant blue component, but the observers were confused with the effect of whiteness of the area in clinical decision making.

Keywords Color perception · Oral cancer · Tolonium chloride

Introduction

Visual identification of any oral lesion is necessary in order that subsequent steps for diagnosis may occur [1]. Clinical experience is needed to detect minimal oral mucosal color and texture changes that are necessary for identification of oral mucosal lesions [2, 3]. Color is a critical characteristic of the assessment and identification of oral mucosal lesions [4]. Oral premalignant lesions (OPLs) and squamous cell carcinoma (SCC) may be preceded by red lesions, mixed red and white lesions, or white plaques [5–8]. In some cases, co-existing white and/or red changes may be observed adjacent to SCC which implies origin in an OPL [3]. Diagnostic pitfalls may be due to cognitive errors and variation in perception that may affect the decisions of the clinicians [1, 9, 10]. Human color perception is considered “subjective” [11] because alterations in perception of color can occur as a result of numerous uncontrolled factors including aging [12, 13], fatigue, length of exposure of the specimen to eye, and previous exposure of the eye [13]. Moreover, systemic diseases such as diabetes, leukemia, Addison's disease, Parkinson disease, anemia, multiple sclerosis, psychiatric disorders, alcoholism, and medications including analgesics, antibiotics, antihypertensives, and oral contraceptives may affect color perception and discrimination [14–19].

It is possible to quantify and to achieve objective measurements of color by using instrumental measurements expressed in the coordinates of a color order system [11]. CIELAB is a color space defined by the International Commission on Illumination (*Commission Internationale d'Eclairage*) and is accepted as the most complete color

P. Güneri (✉) · S. Ergün
School of Dentistry, Department of Oral Diagnosis and Radiology,
Ege University,
Bornova,
35100 İzmir, Turkey
e-mail: peleen_2000@yahoo.com

J. B. Epstein
Department of Oral Medicine and Diagnostic Sciences,
College of Dentistry, University of Illinois,
Chicago, IL, USA

J. B. Epstein
Department of Otolaryngology/Head and Neck Surgery,
Chicago Cancer Center, College of Medicine, University of Illinois,
Chicago, IL, USA

H. Boyacıoğlu
Faculty of Science, Department of Statistics, Ege University,
İzmir, Turkey

space that describes all colors visible to the human eye. Since 1931, CIELAB units have been used for color quantification [20]. In this system, the color space consists of three coordinates L^* , a^* , and b^* . The L^* refers to the lightness coordinate, and its value ranges from 0 for perfect black to 100 for perfect white. The a^* and b^* are chromaticity coordinates in the red-green axis and yellow-blue axis, respectively. Positive a^* values reflect the red color range and negative values indicate green color range. Similarly, positive b^* values indicate yellow color range while negative values indicate the blue color range [21]. Whilst the red/green and yellow/blue opponent channels are computed as differences of lightness transformations of human eye's cone responses, CIELAB is defined as a chromatic value color space.

Digital color analysis has been established using L^* , a^* , and b^* values of the test materials on digital images [22, 23]. This method was advocated by the American Dental Association to measure the color variations [24], and it has been used not only to measure lightness and color changes of the tooth [25–27], but also to identify the pathology [28–31], to establish the clinical parameters [28, 29, 32, 33], and to quantitatively evaluate the course of the lesion progression and response to treatment [28–30].

Toluidine blue is a cationic metachromatic dye that may selectively bind to free anionic groups such as sulfate, phosphate, and carboxylate radicals of large molecules [5, 34]. When evaluated as a part of the clinical examination, toluidine blue staining may provide additional information. In vivo, toluidine blue stains deoxyribonucleic acid and/or may be retained in intracellular spaces of dysplastic epithelium and clinically appear as royal blue areas [8, 35–38]. Toluidine blue may bind to dysplastic and malignant tissues at sites of loss of tumor suppressor genes that predict progression of OPLs to oral SCC (OSCC) or may represent OSCC at diagnosis [39–43]. Zhang et al. [43] suggested that staining intensity may provide important data due to binding of toluidine blue at sites of molecular changes that predict malignant risk, and it is reported that even weakly stained areas had significantly increased molecular alterations compared to toluidine blue negative samples [40, 43].

The correlation between the intensity of blue staining and the severity of dysplasia has been discussed in reporting of toluidine blue staining patterns in different studies. Some reported only “a royal blue” intense stain as positive, while others reported any staining as positive [38]. Gandolfo et al. [44] reported that all OSCC stained toluidine blue positive and that none of the OSCC lesions stained pale blue. However, Gray et al. [5] and Missmann et al. [37] showed that when equivocal staining was included with positive stain, the sensitivity of toluidine blue staining was as low as 40% and as high as 100%. If equivocal stained lesions were considered negative, the sensitivity

varied from 100% to 81% [5]. In another study, when equivocal staining was accepted as positive, the specificity of toluidine blue in OPLs was reported from 31–<50% [5, 39, 45, 46] and as high as 93% [5, 37, 39]. On the other hand, accepting pale blue staining as negative increased the specificity significantly in some studies [5, 39]. These reports suggest the importance of classification of toluidine blue staining intensity as negative or positive (with malignant potential) prior to determination of the need to biopsy and to guide biopsy site selection [47].

The purpose of this study was to investigate observer agreement on the rank of the color tones reported in different areas of a toluidine blue-stained lesion and normal mucosa and to determine if their ranking orders may cause inter- and intra-observer variations in decision making.

Materials and methods

A patient referred for evaluation of a mass in the left buccal mucosa extending onto the retromolar alveolar region was assessed (Fig. 1). Informed consent was obtained prior to photographing the lesion.

After thorough interview and clinical examination, the lesion was evaluated following toluidine blue application. Toluidine blue solution was prepared by compounding laboratory grade powder (1 g toluidine chloride powder, 10 ml acetic acid, 4.19 ml absolute alcohol, and 86 ml distilled water) and was applied after 1% acetic acid oral rinse, as suggested in the literature [48, 49]. Before and after staining, a color image of the lesion was obtained by a professional photographer using a high resolution digital camera (6.31 mega pixel resolution, 23.7×15.5 mm sensor size, automatic focus function; Olympus Camedia C-2500-L; Melville, NY, USA). A 5-mm diameter disk was placed

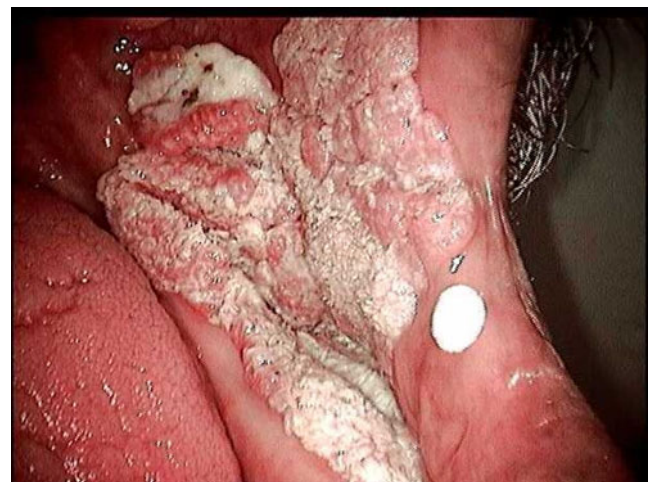

Fig. 1 Clinical photograph of buccal mucosal lesion

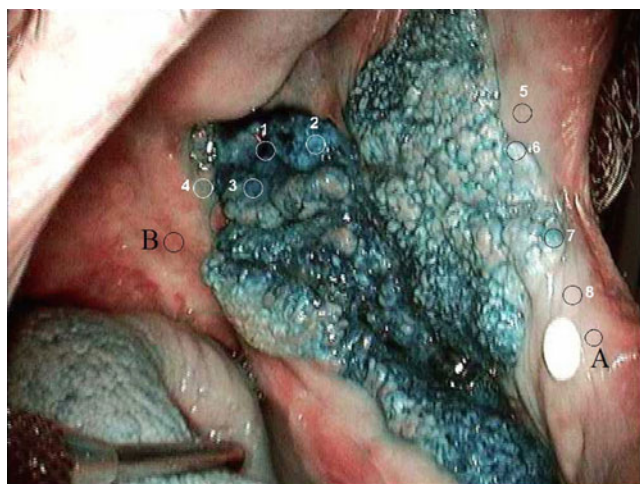

Fig. 2 Clinical photograph of lesion following toluidine blue application

adjacent to the lesion during photographing in order to balance the lightness between the images. The image was transferred to a personal computer (2.6 GHz Pentium IV CPU, 12 megabyte RAM, 40 gigabyte hard disk) and saved as Tagged Image File Format.

Adobe Photoshop CS2 version 9.0.2 (Adobe Systems Inc., San Jose, CA, USA) was used to work with the image. On the image, eight circular areas, each in 50×50 pixel size, were selected within the image using elliptical marquee tool. Two sample areas from the normal appearing oral mucosa were selected as well. One of these was from the pale colored area (A), the other was from the dark area (B). One of the investigators, experienced in toluidine blue staining (P.G.) determined the areas to be selected according to the blue color variations within the lesion (Fig. 2).

In order to determine the total color change or relative perceptual differences between colors in the L^* , a^* , b^* system (ΔE^*_{ab}), the differences in the lightness and chromaticity coordinates (ΔL^* , Δa^* , Δb^*) as a result of UV light exposure are determined first, and then, the total color change can be calculated using the relationship: $\Delta E^*_{ab} = (\Delta L^{*2} + \Delta a^{*2} + \Delta b^{*2})^{1/2}$ [11, 50]. In this formula, each color is treated as a point in a three dimensional space with three components (L^* , a^* , b^*) and the Euclidean

distance between these points is calculated [19]. The L^* , a^* and b^* values of each circular areas, unstained adjacent oral mucosa samples (A and B) and the white calibration material were measured using the histogram function of the software (Fig. 3).

Three measurements were performed for each parameter and the mean values were calculated (Fig. 4). These values obtained with computer image analysis were accepted as the gold standards.

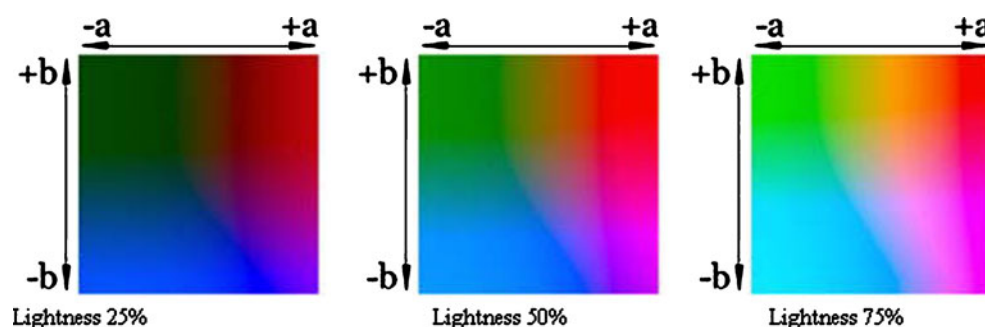
In order to investigate the correspondence of clinical color interpretation with gold standards, 20 clinicians who had experience in evaluation of oral mucosal lesions, examined the image and were asked to rate the eight identified areas on the image according to the intensity of blue stain. Each observer had a separate blinded session, all evaluated the image on the same computer screen. The observers rated these areas and scored the most pale area as 1 and darkest blue as 8. To assess intra-observer variability, each observer re-evaluated the image 2 weeks after their initial readings.

Statistical analyses were performed using Statistical Package for the Social Sciences 2000 (SPSS) 10.0 (SPSS Inc., Chicago, IL, USA) and Minitab 13 software (Minitab Statistical Software 2000; Minitab Inc., State College, PA, USA). In order to investigate the effects of L^* , a^* , and b^* on the ranking order, each rank was granted a score: the darkest sample received 8, the next was provided with 7, and the palest sample received a score of 1. The effects of L^* , a^* , and b^* on scores were then analyzed using regression analysis. Cohen's kappa was used to establish the inter- and intra-observer agreement, and independent sample t test was utilized to examine the effect of clinical experience on the ranking of the observers. Chi-square test was used to to examine differences with categorical variables. In the evaluation of the analysis “ α ” was taken into account as 0.05.

Results

The observers ratings obtained in two separate readings are presented in Table 1, and the L^* , a^* , and b^* values of eight

Fig. 3 The effect of lightness on the color. (http://www.optics.arizona.edu/opti588/reading/CIE_Lab_color_space.pdf; Jan 28, 2009)



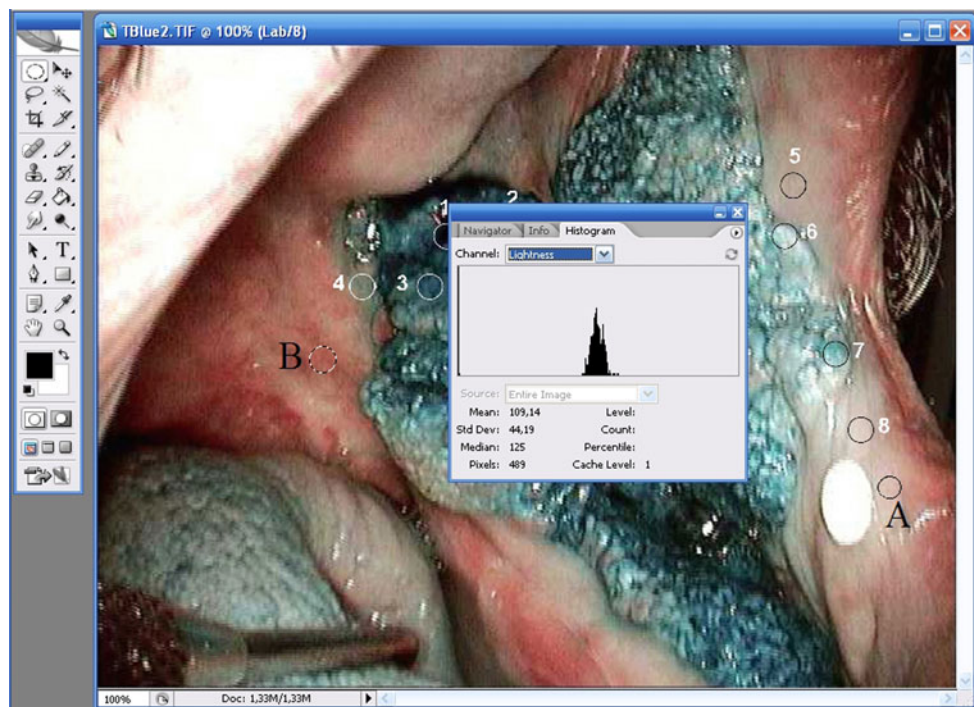


Fig. 4 Measurement of the L*, a*, and b* values of each selected area using histogram function of the software

sites, two mucosal areas, and the white calibration material are shown in Table 2.

No other areas of mucosal change were seen within the oral cavity with visual examination and after staining with toluidine blue. Following the study photographs, the lesion was surgically excised. In the histological specimen, a papillomatous proliferation of the squamous epithelium with acanthosis, hyperpara- and orthokeratosis, and blunt epithelial ridges which were infiltrated with polymorphonuclear leukocytes, especially eosinophilic granulocytes were observed. The histological diagnosis was verrucous carcinoma with benign mucosa at the surgical margins.

The age of the observers ranged between 26 and 58 (mean: 38.4 years \pm 9.93) years and their experience in oral mucosal lesion diagnosis varied between 2 and 34 years (mean: 15.2 years \pm 10.04). The intra-observer agreement was $\kappa=0.86$, and likewise, the inter-observer agreement was $\kappa=0.854$ ($p<0.01$).

The general agreement between the observers' first and second "site ranking according to the blueness of each circular area" was 87.5%, indicating that in 140 out of 160 observations, clinicians ranked the same sites with the same order in both sessions. They tended to rank the specimen sites which were coded as 1, 3, and 2 as the darkest blue areas, in decreasing order. The intra-observer agreement was 100% for the samples which were coded as 1, 3, and 2. On the other hand, specimen sites 5 and 8 were ranked as the palest blue areas, in

decreasing order. The intra-observer agreement was 100% for the sample 8 and 95% for the sample 5.

The ranking order of all other specimen sites varied between first and second sessions: During the first observation, 19 out of 20 observers (95%) recorded the site 7 as the fourth darkest blue area, 14 out of 20 observers (70%) declared sample 4 as the fifth darkest blue area whereas 15 observers (75%) asserted specimen site 6 as the sixth darkest blue area.

In the second session, 17 clinicians (85%) stated the specimen site 7 as the fourth darkest blue sample, 15 observers (75%) stated the site 4 for the fifth darkest area, whereas, 3 clinicians (15%) preferred site 7 as the fifth darkest blue area.

In first and second sessions, eight observers (40%) ranked sites 4 and 6 interchangeably. The site 4 was also confused with the site 7. Most of the observers (73%) had preferred to rank the sites as 7-4-6, whereas 18% of the observers' ranking order was 7-6-4. The least preferred (0.8%) ranking order was 4-7-6. These values revealed that the most preferred rank order was 7-4-6, and the probability of the observers' preference to rank the sites as 7-4-6 was statistically significant, ($p=0.06<0.01$).

The experience of the clinicians ranged between 2 and 34 years of practice, and half of the observers had less than 17 years of experience. Statistical analysis of the results did not reveal a significant difference between the decisions of the clinicians who have less or more than 17 years of experience ($p>0.05$). The more

Table 1 Ranking of color intensity of clinical case

Observer	Age	Exp*	First ranking								Second ranking								Kappa
O1	44	22	1	3	2	7	4	6	5	8	1	3	2	7	4	6	5	8	1.000
O2	40	17	1	3	2	7	6	4	5	8	1	3	2	7	4	6	5	8	0.714
O3	28	5	1	3	2	7	6	4	5	8	1	3	2	7	4	6	5	8	0.714
O4	55	33	1	3	2	4	7	6	5	8	1	3	2	4	7	6	5	8	1.000
O5	31	9	1	3	2	7	4	6	5	8	1	3	2	7	6	4	5	8	0.714
O6	58	34	1	3	2	7	4	6	5	8	1	3	2	7	4	6	5	8	1.000
O7	47	25	1	3	2	7	6	4	5	8	1	3	2	7	4	6	5	8	0.714
O8	48	25	1	3	2	7	4	6	5	8	1	3	2	4	7	5	6	8	0.429
O9	49	26	1	3	2	7	4	6	5	8	1	3	2	7	4	6	5	8	1.000
O10	26	3	1	3	2	7	6	4	5	8	1	3	2	7	4	6	5	8	0.714
O11	26	2	1	3	2	7	4	6	5	8	1	3	2	7	4	6	5	8	1.000
O12	31	7	1	3	2	7	4	6	5	8	1	3	2	7	6	4	5	8	0.714
O13	27	3	1	3	2	7	4	6	5	8	1	3	2	7	4	6	5	8	1.000
O14	41	18	1	3	2	7	4	6	5	8	1	3	2	7	4	6	5	8	1.000
O15	43	18	1	3	2	7	4	6	5	8	1	3	2	7	4	6	5	8	1.000
O16	40	17	1	3	2	7	4	6	5	8	1	3	2	7	4	6	5	8	1.000
O17	27	4	1	3	2	7	4	6	5	8	1	3	2	7	4	6	5	8	1.000
O18	34	12	1	3	2	7	4	6	5	8	1	3	2	4	7	6	5	8	0.714
O19	42	16	1	3	2	7	6	4	5	8	1	3	2	7	4	6	5	8	0.714
O20	31	8	1	3	2	7	4	6	5	8	1	3	2	7	4	6	5	8	1.000

Exp* dental experience in years

experienced group had 90% general agreement, whereas the less experienced clinicians' agreement was 85% ($p=0.532$).

As stated earlier, in CIELAB color space, the higher the L^* value, the brighter the image. The color parameters of pure white reference are $L^*:255$, $a^*:128$, and $b^*:128$. The calibration material we have used in our image had almost the same values, showing that the incandescent examination light had not affected the colors of the image.

The sites which received the lowest scores and were ranked as the lightest areas were 5 and 8; both had high L^* values (mean $L^*=176.807$ and 213.213 , respectively). Even though site 6 had higher L^* value (212.083) than site 5, its a^* and b^* values (120.100 and 126.700) were lower than those of site 5 ($a^*=133.237$, $b^*=138.467$; Table 2).

L^* , a^* and b^* values of the the darkest 3 areas (sites 1, 3, and 2) were $L_1:17.843$, $a_1:126.903$, $b_1:123.110$; $L_3:75.470$, $a_3:118.153$, $b_3:116.417$; $L_2:121.930$, $a_2:111.080$, $b_2:113.280$, respectively. These results showed that even though the L^* value increased among these samples, the decrease of the b^* value darkened the sample image area.

The examination of the mean L^* , a^* , and b^* values revealed that a^* and b^* values of eight sites were close to each other, but mean L^* values differed significantly (Table 2, Fig. 5). Site number 6 had almost the same blueness (mean $b^*=126.7$) as number 7 (mean $b^*=123.64$), but the observers scored it as “more pale blue” than the latter. The L^*

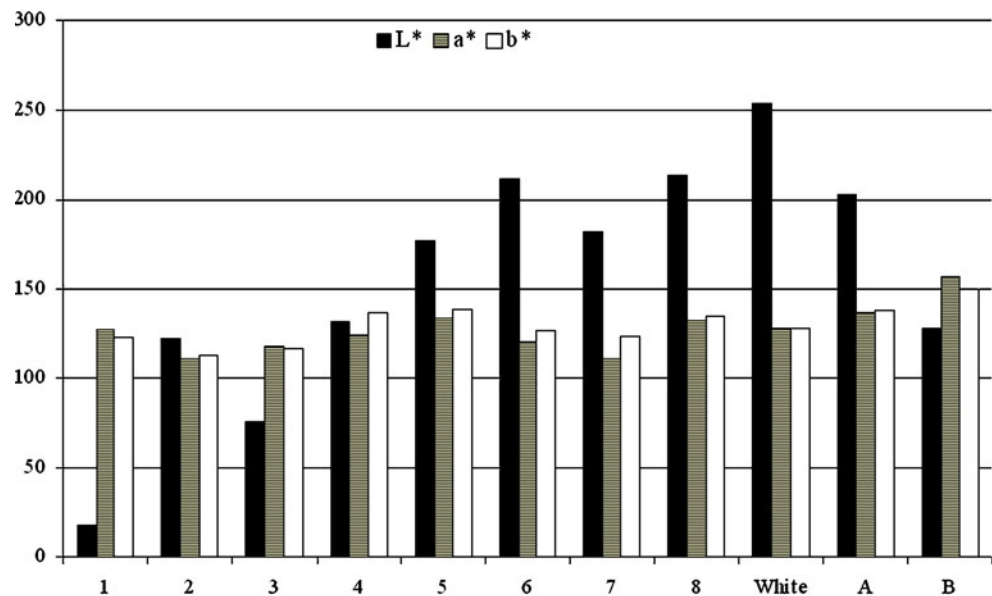
values differences were important in these two areas (mean $L^*_7=181.633$; mean $L^*_6=212.083$). Thus, it may be speculated that the variations in color perception of these areas would be affected by the whiteness component rather than the blueness or redness of the area. Supporting this speculation, the major difference between the pale and dark samples of normal appearing mucosa originated from the L^*

Table 2 Ranking of CIELAB color values of toluidine blue stained image

Areas	L^*	a^*	b^*
1	17.843	126.903	123.110
3	75.470	118.153	116.417
2	121.930	111.080	113.280
7	181.633	111.140	123.640
4	131.260	124.337	136.540
6	212.083	120.100	126.700
5	176.807	133.237	138.467
8	213.213	132.300	135.003
White	253.933	127.853	128.317
A*	202.273	136.557	137.820
B*	128.267	157.287	150.247

A* normal-appearing mucosa (pale); B* normal-appearing mucosa (dark)

Fig. 5 Mean L*, a*, and b* values of all samples



values rather than the a* and b* values of the areas (Table 2, Fig. 5).

The effects of L*, a*, and b* on scores were investigated with regression analysis. The determination coefficient of L* was $R^2=0.74$, a* was $R^2=0.29$, and b* was $R^2=0.65$. All color parameters were effective on the color ranking order provided by the observers ($pL^*=0.00$, $pa^*=0.007$, and $pb^*=0.00$, respectively). However, L* and b* appeared to be more effective on the ranking of the samples than a*.

Discussion

Color is a complex concept that involves optical, physiological, and psychological constituents. Color perception requires illumination of the object with light of varying wavelengths and intensities; the object absorbs and reflects the light waves in different ways depending on the frequency of the waves; light is reflected to the eye of the observer, processed and finally, perceived as color [11]. The eye is more sensitive to green and least sensitive to blue; and when the dominant wavelength of the light is in the upper end of the visible spectrum, it is perceived as red and if in the lower end, it is defined as blue. However, the wavelength of light is not the sole determinant of the color: the eye-brain interaction determines the color, but also “creates” one, as well: for example, magenta is not a component of the rainbow/prism, rather is a fabrication of the eye-brain system [51].

Even though the human visual system is capable of distinguishing almost 35,000 colors [51], color perception may be altered by factors such as the size of the object [51], the type of the illuminant [19, 52], and the color of the background [11]. Furthermore, different sections of the reflective spectrum may have higher values under disparate

forms of light [11]. When the reflective spectra are not identical, different tristimulus values and ultimately, different shades of color may be apparent [11]. This phenomenon may result with differentiation between the color perception and definition among the clinicians in different examination settings. In order to overcome this problem, assessing a control material to calibrate the differences in photographing and processing has become a standard procedure in digital data analysis [24], and a white photographic paper was applied in the present study to meet this requirement.

We assessed color analysis following toluidine blue application because of the utility of toluidine blue in clinical examination of OPLs and OSCC [7, 42–44, 53–55], and because of the variable inclusion or exclusion of ambiguous toluidine blue retention as either positive, negative, or equivocal in prior studies [7, 42, 44, 46–49, 55–57]. The findings of the present study have a number of clinical implications: the observers successfully ranked the darkest and the palest samples visually; however, they had more difficulty in the areas of transition. This finding is important in toluidine blue staining procedures of suspicious lesions, because the malignant potential of an oral mucosal lesion is based on the color of the stained lesion, even though clinical appraisal is coupled with the non-stained appearance of the texture of the lesion and its location. It is known that differences in adjacent tissue in lightness or color intensity and relative differences in appearance impact the perception of color difference, and that difference may be of assistance in detection and in margin delineation in clinical examination and following toluidine blue application.

In long-term clinical observations, even though all clinical examination settings were kept standard, differences due to personal evaluation variations may lead to

very important consequences [11]. OPLs have a wide range of potential to progress into malignant lesions [5, 45, 55] and the staining of these lesions with toluidine blue predicts progression of even benign lesions or lesions with mild dysplasia to cancer in a longitudinal study [40, 43]. Determination of lesion color via the assistance of an objective method may provide additional ability to detect and to predict OPLs at risk of progression to cancer.

The association between the visual color perception and spectrophotometric analysis has been documented [58, 59]. Spectrophotometric color match of dental crowns with natural teeth was better than the color match provided by the observers [58]. In addition, spectrophotometric analyses revealed highly significant color differences between the dental ceramics which were not identified by the observers [59].

Quantitative color analysis was used to describe the chromo-endoscopic findings more objectively and reproducibly for early diagnosis of esophageal SCC [29]. In the study of Ishihara et al. [29], quantitative assessment of the pink color sign, which was an indicator of malignancy, resulted in a high sensitivity (88%) and high specificity (95%) for diagnosing high grade intra-epithelial neoplasias and cancers. Jönsson et al. [32] investigated the value of computerized image analysis to measure the extravasated plasma albumin marked with Evans blue in a tissue exposed to a standardized burn injury. They showed that the values from image analysis correlated with invasive measurements from spectrophotometric analysis and subjective decisions made by the naked eye. An increase in blue values and a corresponding decrease in redness were observed, while green values remained virtually the same [32].

It is already known that the hyperkeratotic areas of a lesion do not stain with toluidine blue and this was observed in our case as well. In the present study, the computer analysis revealed that the areas that appeared pale blue visually had a blue component like the rest of the test specimens, but this difference was not reported by the observers. This finding suggests that these areas' white appearance influenced the clinical impression of the intensity of blue color. Some authors recorded pale blue stained areas as "negative" [36, 48, 60], however, our findings suggest that blue color is affected by whiteness of the area and recommended that any site of retention should be assessed cautiously. Toluidine blue has been shown to assist in detection of mucosa with molecular changes that are associated with OPLs or OSCC, in assessment of margins of OPLs/OSCC and biopsy sites selection [36, 38, 40–43, 46, 57, 61] and in screening for second primary oral cancers or recurrences [34, 54, 62]. Furthermore, Guo et al. [40] and Zhang et al. [43] have reported that the stained oral mucosal areas with benign

histology and mild dysplasia and normal margins harbor clonal changes with risk of progression to malignant lesions. Therefore, our findings support Patton et al. [38] who suggested that any staining with toluidine blue should elevate the index of suspicion, and as Zhang et al. [43] have stated that any lesion with toluidine blue staining should be considered a candidate for further evaluation.

In the present study, the observers' judgement of the darkest and palest areas of toluidine blue stain correlated with the computer analysis, but these areas either had low whiteness, or high blueness parameters, rather than a significantly different blue component. On condition that toluidine blue staining would result with blueness of the area, the effect of whiteness was not anticipated. Moreover, considering the intermediary areas of light blue, the observers were confused with the effect of whiteness of the area. Joiner et al. [63] have reported that the tint of a material's color is as important as the illuminant. The shades that deviate far from the white point are deemed to be less white than those of the same luminance. Human visual perception has a preference for "bluish" white and when the bluish tint of a sample is increased, it will cease to be described as "white" [63]. Therefore, we suggest that this may have an influence on the observers rank orders in this study.

In our case, pale area adjacent to the lesion was located near to the labial commissure and dark area was closer to the pharynx. The dark and pale oral mucosal areas had different L^* values when compared to their a^* and b^* values; the dark area had lower L^* (more black), but higher a^* (more red) and b^* (more blue) values. Considering that investigation of the color parameters of human gingiva was not the aim of this study and we utilized the color photograph of only one patient, we cannot present a findings of the color components of healthy appearing oral mucosa. However, the intraoral location of the lesion may affect color interpretation; for example, the pharyngeal area has more prominent vascularity and may influence the darkness or redness of the lesion as opposed to the commissural site that may appear paler in color [64, 65]. The results of this study should be interpreted with caution as the analysis is based upon a single lesion, and a lesion that had color and surface verrucous-like changes, making the lesion easily detectable in the oral cavity. Further validation of application of digital color analysis to toluidine blue staining is suggested.

A systematic literature review recommended use of toluidine blue in high-risk patients by experienced providers [38]. We observed that toluidine blue stained areas' color perception was a multifaceted phenomenon, and the redness-greenness did not affect the decisions of the observers. Even though blueness-yellowness influenced the clinical judgement, its impact was limited when

compared to that of whiteness-blackness. Patel et al. [66] have stated that in order to assist the clinical decision process, computer-assisted decision support technologies may be applied to conventional decision making means. However, we suggest that any staining with toluidine blue should elevate the index of suspicion and these stained lesions shall require further clinical/histological evaluation.

Conflict of interest We declare no conflict of interest.

References

- Braga JC, Scope A, Klaz I, Mecca P, Spencer P, Marghoob AA (2008) Melanoma mimicking seborrheic keratosis: an error of perception precluding correct dermoscopic diagnosis. *J Am Acad Dermatol* 58:875–880
- Scully C, Felix DH (2005) Oral medicine—update for the dental practitioner. Oral white patches. *Br Dent J* 199:565–572
- Scully C, Felix DH (2005) Oral medicine—update for the dental practitioner. Red and pigmented lesions. *Br Dent J* 199:639–645
- Johnson N, Franceschi S, Ferlay J, Ramadas K, Schmid S, MacDonald DG, Bouquot JE, Slootweg PJ (2005) Squamous cell carcinoma, Chapter 4: Tumours of the oral cavity and oropharynx. In: Barnes L, Eveson JW, Reichart P, Sidransky D (eds) World Health Organization Classification of tumours, pathology and genetics of head and neck tumours. IARC Publication. <http://www.iarc.fr/IARCPress/pdfs/bb9/bb9-chap4.pdf>. Accessed 09 Sep 2009
- Gray MGL, Burls A, Elley K (2000) The clinical effectiveness of toluidine blue dye as an adjunct to oral cancer screening in general dental practice. A West Midlands Development and Evaluation Service Report. http://www.pcpoh.bham.ac.uk/publichealth/wmhtac/pdf/toluidine_blue.pdf. Accessed 20 Jan 2007
- Reichart PA (2001) Identification of risk groups for oral precancer and cancer and preventive measures. *Clin Oral Invest* 5:207–213
- Epstein JB, Zhang L, Rosin M (2002) Advances in the diagnosis of oral premalignant and malignant lesions. *J Can Dent Assoc* 68:17–21
- Patton LL (2003) The effectiveness of community-based visual screening and utility of adjunctive diagnostic aids in the early detection of oral cancer. *Oral Oncol* 39:708–723
- Samei E, Flynn MJ, Peterson E, Eyler WR (2003) Subtle lung nodules: influence of local anatomic variations on detection. *Radiology* 228:76–84
- Niimi T, Imai K, Maeda H, Ikeda M (2007) Information loss in visual assessments of medical images. *Eur J Radiol* 61:362–326
- Knispel G (1991) Factors affecting the process of colour matching restorative materials to natural teeth. *Quintessence Int* 22:525–531
- Billmeyer FW, Saltzman M (1980) Observer metamerism. *Color Res Appl* 5:72
- Douglas RD (1997) Precision of in vivo colorimetric assessments of teeth. *J Prosthet Dent* 77:464–470
- Wozniak WT, Moser JB (1981) How to improve shade matching in the dental operator. Council on dental materials, instruments, and equipment. *J Am Dent Assoc* 102:209–210
- Vleugels L, Lafosse C, van Nunen A, Nachtergaele S, Ketelaer P, Charlier M, Vandenbussche E (2000) Visuoperceptual impairment in multiple sclerosis patients diagnosed with neurophysiological tasks. *Mult Scler* 6:241–254
- Iregren A, Andersson M, Nylen P (2002) Color vision and occupational chemical exposures: I. An overview of tests and effects. *Neurotoxicology* 23:719–733
- Shuwairi SM, Cronin-Golomb A, McCarley RW, O'Donnell BF (2002) Color discrimination in schizophrenia. *Schizophr Res* 55:197–204
- Brewer JD, Wee A, Seghi R (2004) Advances in color matching. *Dent Clin North Am* 48:341–358
- Joiner A (2004) Tooth color: a review of the literature. *J Dent* 32:3–12
- Okubo SR, Kanawati A, Richards MW, Childress S (1998) Evaluation of visual and instrument shade matching. *J Prosthet Dent* 80:642–648
- Uchida H, Vaidyanathan J, Viswanadhan T, Vaidyanathan TK (1998) Colour stability of dental composites as a function of shade. *J Prosthet Dent* 79:372–377
- Cal E, Sonugelen M, Guneri P, Kesercioglu A, Kose T (2004) Application of a digital technique in evaluating the reliability of shade guides. *J Oral Rehabil* 31:483–491
- Cal E, Guneri P, Kose T (2006) Comparison of digital and spectrophotometric measurements of color shade guides. *J Oral Rehabil* 33:221–228
- McCaslin AJ, Haywood VB, Potter BJ, Dickinson GL, Russell CM (1999) Assessing dentin color changes from nightguard vital bleaching. *J Am Dent Assoc* 130:1485–1490
- Bentley C, Leonard RH, Nelson CF, Bentley SA (1999) Quantitation of vital bleaching by computer analysis of photographic images. *J Am Dent Assoc* 130:809–816
- Lai YL, Yang ML, Lee SY (2003) Microhardness and color changes of human dentin with repeated intracoronal bleaching. *Oper Dent* 28:786–792
- Jarad FD, Albadri SS, Mair LH (2008) The use of objective digital matching to achieve an esthetic composite restoration. *J Clin Dent* 19:9–13
- Wilson J, Firnhaber R, Kutcher MJ (1992) Computer-aided analysis of intraoral ulcerative lesions. *Oral Surg Oral Med Oral Pathol* 74:393–399
- Ishihara R, Yamada T, Iishi H, Kato M, Yamamoto S, Yamamoto S, Masuda E, Tatsumi K, Takeuchi Y, Higashino K, Uedo N, Tatsuta M, Ishiguro S (2009) Quantitative analysis of the color change after iodine staining for diagnosing esophageal high-grade intraepithelial neoplasia and invasive cancer. *Gastrointest Endosc* 69:213–218
- Iwami Y, Hayashi N, Takeshige F, Ebisu S (2008) Relationship between the color of carious dentin with varying lesion activity, and bacterial detection. *J Dent* 36:143–151
- Pladellorens J, Pintó A, Segura J, Cadevall C, Antó J, Pujol J, Vilaseca M, Coll J (2008) A device for the color measurement and detection of spots on the skin. *Skin Res Technol* 14:65–70
- Jönsson A, Mattsson U, Cassuto J, Heyden G (1998) Quantification of burn induced extravasation of Evans blue albumin based on digital image analysis. *Comput Biol Med* 28:153–167
- Kayser K, Görtler J, Metze K, Goldmann T, Vollmer E, Mireskandari M, Kosjerina Z, Kayser G (2008) How to measure image quality in tissue-based diagnosis (diagnostic surgical pathology). *Diagn Pathol* 3(Suppl 1):S11
- Silverman S Jr, Sugerman PB (2000) Oral premalignancies and squamous cell carcinoma. *Clin Dermatol* 18:563–568
- Mashberg A (1983) Final evaluation of toluidine chloride rinse for screening of high-risk patients with asymptomatic squamous carcinoma. *J Am Dent Assoc* 106:319–323
- Martin LC, Kerawala CJ, Reed M (1998) The application of toluidine blue as a diagnostic adjunct in the detection of epithelial dysplasia. *Oral Surg Oral Med Oral Pathol Oral Radiol Endod* 85:444–446

37. Missmann M, Jank Siegfried J, Laimer K, Gassner R (2006) A reason for the use of toluidine blue staining in the presurgical management of patients with oral squamous cell carcinomas. *Oral Surg Oral Med Oral Pathol Oral Radiol Endod* 102:741–743
38. Patton LL, Epstein JB, Kerr AR (2008) Adjuncts for oral cancer examination and lesion diagnosis: a systematic review of literature. *J Am Dent Assoc* 139:896–905
39. Epstein JB, Oakley C, Millner A, Emerton S, van der Meij E, Le N (1997) The utility of toluidine blue application as a diagnostic aid in patients previously treated for upper oropharyngeal carcinoma. *Oral Surg Oral Med Oral Pathol Oral Radiol Endod* 83:537–547
40. Guo Z, Yamaguchi K, Sanchez-Céspedes M, Westra WH, Koch WM, Sidransky D (2001) Allelic losses in OraTest-directed biopsies of patients with prior upper aerodigestive tract malignancies. *Clin Cancer Res* 7:1963–1968
41. Epstein JB, Feldman R, Dolor RJ, Porter SR (2003) The utility of toluidine chloride rinse in the diagnosis of recurrent or second primary cancers in patients with prior upper aerodigestive tract cancer. *Head Neck* 25:911–921
42. Epstein JB, Zhang L, Poh C, Nakamura H, Berean K, Rosin M (2003) Increased allelic loss in toluidine blue positive oral malignant lesions. *Oral Surg Oral Med Oral Pathol Oral Radiol Endod* 95:45–50
43. Zhang L, Williams M, Poh CF, Laronde D, Epstein JB, Durham S, Nakamura H, Berean K, Hovan A, Le ND, Hislop G, Priddy R, Hay J, Lam WL, Rosin MP (2005) Toluidine blue staining identifies high-risk primary oral premalignant lesions with poor outcome. *Cancer Res* 65:8017–8021
44. Gandolfo S, Pentenero M, Brocchetti R, Pagano M, Carrozzo M, Scully C (2006) Toluidine blue uptake in potentially malignant oral lesions in vivo: clinical and histological assessment. *Oral Oncol* 42:89–95
45. Epstein JB, Scully C, Spinelli J (1992) Toluidine blue and Lugol's iodine application in the assessment of oral malignant disease and lesions at risk of malignancy. *J Oral Pathol Med* 21:160–163
46. Warnakulasuriya KA, Johnson NW (1996) Sensitivity and specificity of OraScan (R) toluidine blue mouthrinse in the detection of oral cancer and precancer. *J Oral Pathol Med* 25:97–103
47. Epstein JB, Silverman S Jr, Epstein JD, Lonky SA, Bride MA (2008) Analysis of oral lesion biopsies identified and evaluated by visual examination, chemiluminescence and toluidine blue. *Oral Oncol* 44:538–544
48. Ram S, Siar CH (2005) Chemiluminescence as a diagnostic aid in the detection of oral cancer and potentially malignant epithelial dysplasia. *Int J Oral Maxillofac Surg* 34:521–527
49. Silverman S, Migliorati C, Barbosa J (1984) Toluidine blue staining in the detection of oral precancerous and malignant lesions. *Oral Surg* 57:379–382
50. Russell MD, Gulfranz M, Moss BW (2000) In vivo measurement of color changes in natural teeth. *J Oral Rehabil* 27:786–792
51. Rogers DF (1988) Procedural elements for computer graphics, 4th edn. McGraw-Hill Inc, Singapore, pp 383–410
52. Park JH, Lee YK, Lim BS (2006) Influence of illuminants on the color distribution of shade guides. *J Prosthet Dent* 96:402–411
53. Williams JL (1990) Oral cancer and precancer: clinical features. *Br Dent J* 168:13–17
54. Mashberg A, Samit A (1995) Early diagnosis of asymptomatic oral and oropharyngeal squamous cancers. *CA Cancer J Clin* 45:328–351
55. Epstein JB, Sciubba J, Silverman S Jr, Sroussi HY (2007) Utility of toluidine blue in oral premalignant lesions and squamous cell carcinoma: continuing research and implications for clinical practice. *Head Neck* 29:948–958
56. Mashberg A (1980) Re-evaluation of toluidine blue application as a diagnostic adjunct in the detection of asymptomatic oral squamous cell carcinoma: a continuing prospective study of oral cancer. *Cancer* 46:758–763
57. Onofre MA, Sposto MR, Navarro CM (2001) Reliability of toluidine blue application in the detection of oral epithelial dysplasia and in situ and invasive squamous cell carcinomas. *Oral Surg Oral Med Oral Pathol Oral Radiol Endod* 91:535–540
58. Da Silva JD, Park SE, Weber HP, Ishikawa-Nagai S (2008) Clinical performance of a newly developed spectrophotometric system on tooth color reproduction. *J Prosthet Dent* 99:361–368
59. Ishikawa-Nagai S, Ishibashi K, Tsuruta O, Weber HP (2005) Reproducibility of tooth color gradation using a computer color-matching technique applied to ceramic restorations. *J Prosthet Dent* 93:129–137
60. Kerawala CJ, Beale V, Reed M, Martin IC (2000) The role of vital tissue staining in the marginal control of oral squamous cell carcinoma. *Int J Oral Maxillofac Surg* 29:32–35
61. Rosenberg D, Cretin S (1989) Use of meta-analysis to evaluate toluidine chloride in oral cancer screening. *Oral Surg Oral Med Oral Pathol* 67:621–627
62. Jiang WW, Fujii H, Shirai T, Mega H, Takagi M (2001) Accumulative increase of loss of heterozygosity from leukoplakia to foci of early cancerization in leukoplakia of the oral cavity. *Cancer* 92:2349–2356
63. Joiner A, Hopkinson I, Deng Y, Westland S (2008) A review of tooth colour and whiteness. *J Dent* 36:52–57
64. Bayindir F, Bayindir YZ, Gozalo-Diaz DJ, Wee AG (2009) Coverage error of gingival shade guide systems in measuring color of attached anterior gingiva. *J Prosthet Dent* 101:46–53
65. Heydecke G, Schnitzer S, Türp JC (2005) The color of human gingiva and mucosa: visual measurement and description of distribution. *Clin Oral Invest* 9:257–265
66. Patel VL, Kaufman DR, Arocha JF (2002) Emerging paradigms of cognition in medical decision-making. *J Biomed Inform* 35:52–75

Copyright of Clinical Oral Investigations is the property of Springer Science & Business Media B.V. and its content may not be copied or emailed to multiple sites or posted to a listserv without the copyright holder's express written permission. However, users may print, download, or email articles for individual use.