

Bone density changes around teeth during orthodontic treatment

Jui-Ting Hsu · Hsin-Wen Chang · Heng-Li Huang ·
Jian-Hong Yu · Yu-Fen Li · Ming-Gen Tu

Received: 9 November 2009 / Accepted: 22 March 2010 / Published online: 15 April 2010
© Springer-Verlag 2010

Abstract The objective of this study was to evaluate bone density changes around the teeth during orthodontic treatment by using cone beam computed tomography (CBCT). CBCT was used to measure the bone densities around six teeth (both maxilla central incisors, lateral incisors, and canines) before and after 7 months of orthodontic treatment in eight patients. In addition, each root was divided into three portions (cervical, intermediate, and apical) to determine whether the bone density change varied with tooth level. The mean reduction in bone density around the measured teeth was 24% after orthodontic treatment. The bone density reduction around teeth was largest for the upper-right and upper-left central incisor (29% and 26%, respectively) and ranged from 20% to 23% for the other four teeth. The mean bone density reduction did not differ significantly between the cervical, portion, and apical portions of the teeth (26%, 22%, and 24%, respectively). CBCT is useful for evaluating bone density changes around teeth during orthodontic treatment. The bone density around the teeth reduced significantly after the application of orthodontic forces for 7 months.

Keywords Cone beam computed tomography · Orthodontics · Tooth movement · Bone density

Introduction

Orthodontic treatment has been a popular oral rehabilitation approach for several decades. Orthodontists correct irregularities of the teeth themselves or the relation between the teeth and surrounding anatomy in order to correct malocclusion problems or for aesthetic reasons. In general, orthodontists can straighten the teeth or otherwise move them into better positions within several months to years, which is readily observable externally. In contrast, changes in density of the alveolar bone around teeth during orthodontic treatment are difficult to observe and measure.

Some researches [1–4] have indicated that the alveolar bone fraction and tissue mineral density are reduced after orthodontic treatment in rat models. The main reason was the newer bone induced by the application of orthodontic forces having lower mineralization and being less dense than older bone [5, 6]. However, all of these studies were based on animal experiments. Some researchers have created three-dimensional finite element models of the teeth and jawbone to study the response of the alveolar bone to orthodontic forces [7–10]. However, it is difficult to simulate the time-dependent effects such as bone density changes after several months of orthodontic treatment in the finite element method. Thus, few finite element researches have investigated bone density change during orthodontic treatment.

Several noninvasive methods can be used to measure the alveolar bone density, including digital image analysis of microradiographs [11], dual energy X-ray absorptiometry [12, 13], and ultrasound [14]. However, all of these approaches have inherent limitations, such as nonavailability of three-dimensional information and the evaluation being only qualitative. Computed tomography (CT) is one of the most useful medical image techniques for obtaining

J.-T. Hsu (✉) · H.-W. Chang · H.-L. Huang · J.-H. Yu · M.-G. Tu
School of Dentistry, College of Medicine,
China Medical University,
91 Hsueh-Shih Road,
Taichung 40402 Taiwan, Republic of China
e-mail: jthsu@mail.cmu.edu.tw

Y.-F. Li
Institute of Environmental Health, China Medical University,
Taichung, Taiwan 404, Republic of China

data on both the structure and density of body tissue. Theoretically, the bone density in Hounsfield units (HU) is directly related to the tissue attenuation coefficient [15–17]. Some clinicians and researchers [18–22] have used CT to investigate the bone density in potential implant sites prior to dental implant implantation. However, CT is not an acceptable approach for evaluating the alveolar bone density during orthodontic treatment due to its high radiation dosage, especially given that patients typically need several CT scans over several months. Aranyarachkul et al. [23] have demonstrated that cone beam CT (CBCT) could be an alternative diagnostic method for bone density evaluation, especially since the reported radiation dosage is much less than that for CT.

Previous studies [7–10] using histomorphometric methods in animal experiments have indicated that the bone fraction and mineral density are reduced during tooth movements associated with orthodontic treatment. However, no data on human subjects have been published. The objective of this study was therefore to use CBCT to investigate changes in the alveolar bone density around teeth after 7 months of orthodontic treatment. The hypothesis tested by this study was that the bone density around the teeth would reduce after orthodontic treatment.

Materials and methods

Patient selection and CBCT scan setup

Eight patients (three females and five males, aged from 20 to 25 years) were selected in this study. The beam hardening effect was avoided by excluding patients with metal crowns, dental bridges, and dental implants. A stainless steel bracket (Micro-arch, Roth type, Tomy International, Tokyo, Japan) and improved superelastic NiTi-alloy archwire (LH wire, Tomy International) were used in this study. All of our patients received nonextraction orthodontic treatment. In addition, the patients had no systemic diseases and were not receiving medication treatments. The CBCT images were obtained before and after 7 months of orthodontic treatment using the i-CAT scanner (Imaging Sciences International, Hatfield, PA, USA). Before CBCT scanning, the patient was placed in a seated position with the head upright and positioned so that the intersection lines were straight horizontal and vertical through the center of the region of interest. CBCT images were taken with the following parameters: 120 kVp, 47 mA, 250 μm voxel resolution, and 16-cm field of view (FOV). The ethical issues of the research protocol were approved by the institutional research board of China Medical University and Medical Center.

Measurement of bone density around the teeth

The six teeth in the anterior region of the maxilla (right canine, right lateral incisor, right central incisor, left central incisor, left lateral incisor, and left canine) were selected as the target teeth. The CBCT images of each patient were imported into professional medical imaging software (Mimics 10.0, Materialise, Leuven, Belgium) to construct a three-dimensional (3D) computer model. Prior to measuring the bone densities around teeth, the 3D model was resliced to obtain new CBCT slices of the teeth that were perpendicular to the longitudinal axes of the teeth (i.e., passing from the tips of the crowns to the tips of the roots) by using the “reslice” function in the software program. The separation between adjacent resliced images was set as 250 μm . The bone density around the tooth was assessed at three levels: cervical, intermediate, and apical portions, where the cervical and intermediate portions were located 3 and 8 mm above the cemento enamel junction, respectively, and the apical portion was located 1 mm below the root tip (Fig. 1). In addition, three adjacent slices of the cervical and intermediate portions and two adjacent slices of the apical portion were used to obtain more completed information.

The steps involved in measuring the bone density in the middle slice of the intermediate portion of the upper-right lateral incisor of patient #5 are shown in Fig. 2. First, the area of the tooth in the slice was selected based on the grayscale threshold value (approximately 1,100) of the cementum (Fig. 2a). This was expanded by 1 voxel (250 μm) to include the thickness of the periodontal ligament (PDL) (Fig. 2b) [24] and then by a further 3

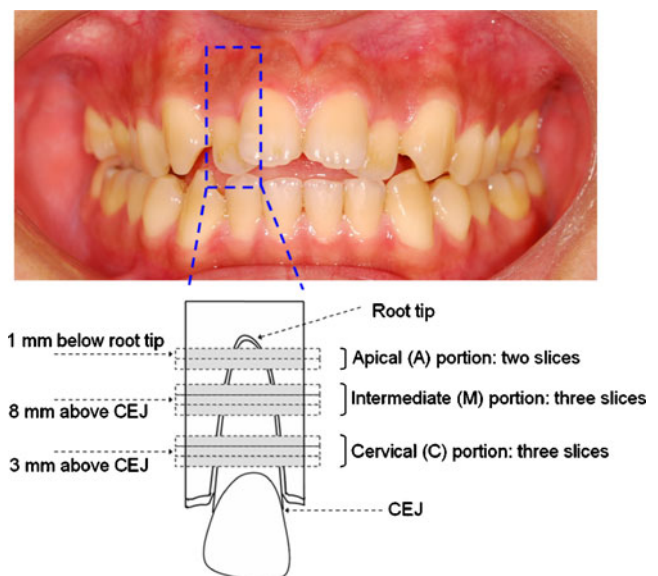


Fig. 1 Schematic of the three portions at which the root of the upper right lateral incisor and the surrounding bone were cross-sectioned. CEJ, cemento enamel junction

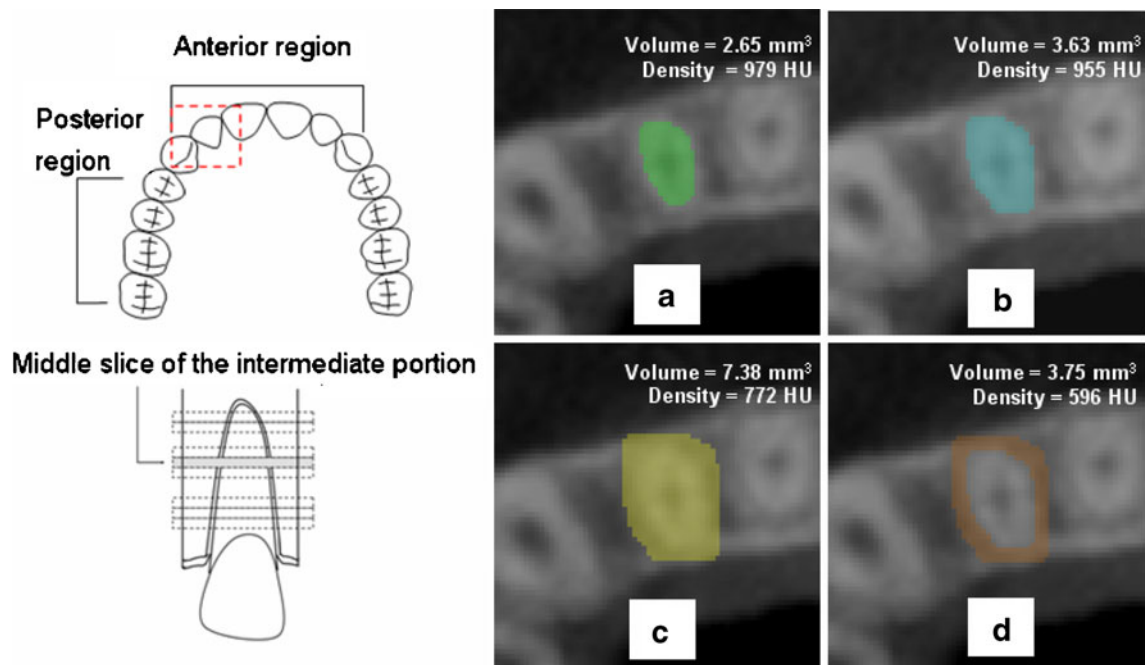


Fig. 2 Steps involved in measuring the bone density around the upper-right lateral incisor in the middle slice of the intermediate portion of patient #5: (*upper left*) schematic occlusal view of the maxilla, lower-left schematic of the middle slice of the intermediate portion of the upper-right lateral incisor; **a** segmenting the area of the

tooth from the CBCT image using the threshold value of the cementum, **b** expanding by 1 voxel to include the PDL, **c** expanding by a further 3 voxels to include the surrounding bone, **d** subtracting the tooth and PDL from the tooth, PDL, and surrounding bone. The volumes of the areas and their density values are also indicated

voxels (750 μm) to include the surrounding bone (Fig. 2c). Finally, the combined area of the tooth plus PDL was subtracted from the entire area (tooth plus PDL plus surrounding bone) using a Boolean operation to obtain the bone density (as the grayscale value) of the bone around the tooth (Fig. 2d).

Statistical analysis

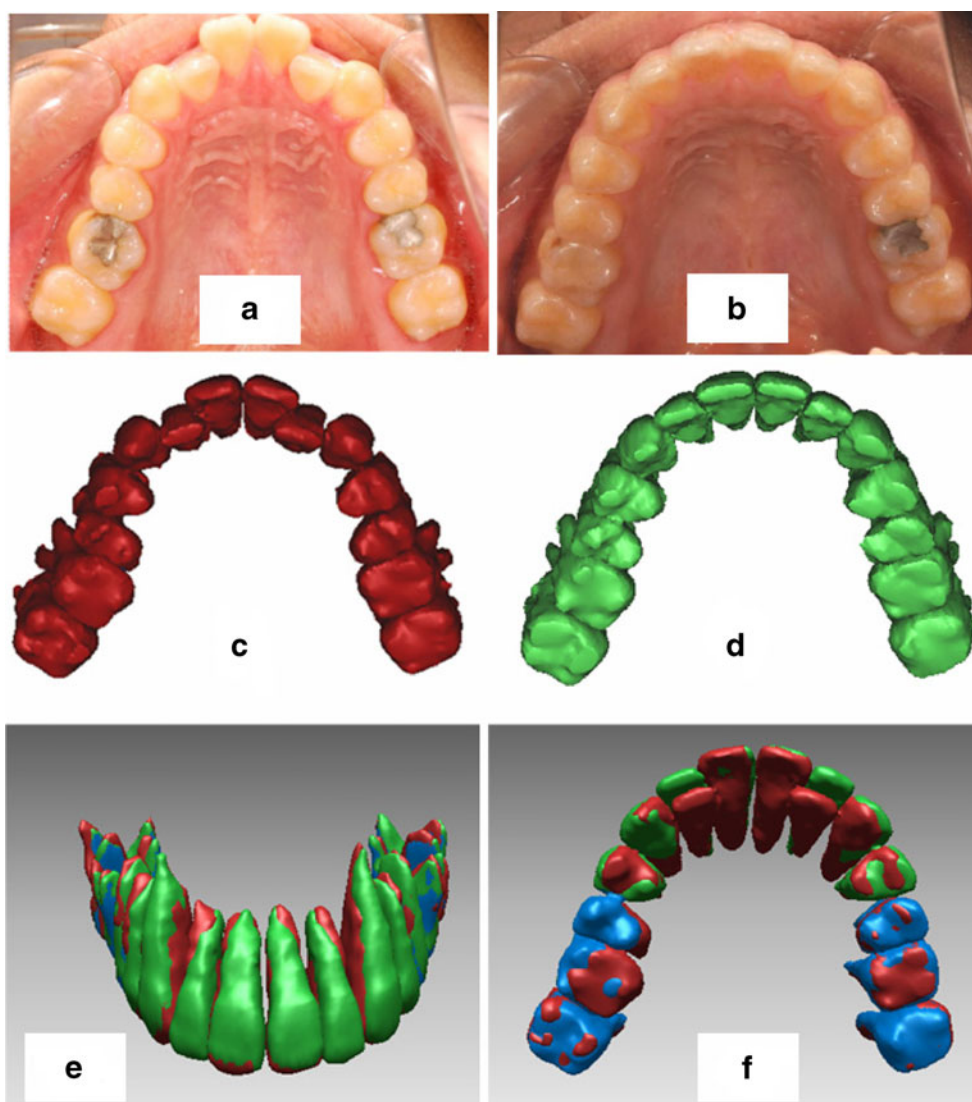
The accuracies of the instrumentation and measurements were validated before analyzing the bone density changes during orthodontic treatment. Two phantoms (constructed from water and high-density acrylic) with specific densities were used to validate the consistency at two CBCT scanning times (performed on the same days in all patients at before and 7 months after orthodontic treatments). The intraclass correlation coefficient (ICC) and repeated-measures analysis of variance (ANOVA) were used to determine the reliability of the CBCT instrument. The ICC and p value of repeated-measures ANOVA tests were 0.993 and 0.891, respectively. In addition, two statistical analyses were used to assess the reliabilities of intraexaminer and interexaminer measurements. The interexaminer error was determined by the bone density around the tooth in a certain CBCT slice being measured once by each of two examiners—the ICC and p value of repeated-measures ANOVA tests were 0.956 and 0.608, respectively. The intraexaminer error was determined

by the bone density around the tooth in a certain CBCT slice being measured five times by a single examiner—the ICC and p value of repeated-measures ANOVA tests were 0.987 and 0.727, respectively. These values indicate that the intraexaminer and interexaminer errors of this method could be neglected in this study. The bone density changes around the teeth after 7 months of orthodontic treatment were analyzed using the Wilcoxon signed-rank test. In addition, the bone density changes in different teeth were analyzed using the Kruskal–Wallis test. The cutoff for statistical significance was a p value of 0.05. All the statistical analyses were performed by the SAS statistical package (SAS Institute, Cary, NC, USA).

Results

None of the patients complained during the 7 months orthodontic treatment. The mean body weight of the patient decreased by about 5% from the first week, but this lost weight was recovered after 1 month. The irregular teeth moved into better positions after the orthodontic treatment in all patients. For the example of patient #5 (Fig. 3a, b), mapping the computer models of maxilla molars obtained using RapidFoam software (Inus Technology, Seoul, Korea) before (Fig. 3c) and after (Fig. 3d) orthodontic treatment readily revealed that the teeth in the anterior region of

Fig. 3 Occlusal photographs of the maxilla of patient #5 before treatment (a) and after treatment (b). Three-dimensional computer models: before treatment (a) and after treatment (b). Superimposing the models of the before and after treatments: frontal view (e) and occlusal view (f). Red, model of maxilla before orthodontic treatment; green, model of maxilla after orthodontic treatment; blue, overlapping region



maxilla moved into better positions, resulting in overall U-shaped dentition.

In all eight patients, with the exception for the apical portion of the upper-left lateral incisor (UL2) and the cervical portion of upper-left canine (UL3) of patient # 3 (Fig. 4c), the bone density around the maxilla anterior teeth reduced by $24.3 \pm 9.5\%$ (mean \pm standard deviation)—range 1.8–48.0%—during 7 months of orthodontic treatment (Fig. 4).

The mean bone density reduction was greatest in both central incisor—by 29.0% and 25.8% in the upper-right and upper-left central incisors, respectively (Table 1)—followed by the upper-right and upper-left canine teeth (23.1% and 22.9%) and then the upper-right and upper-left lateral incisors (22.0% and 20.7%) (Table 1). The mean bone density changes did not differ significantly between the cervical, intermediate, and apical portions of the teeth: 25.9%, 21.9%, and 23.9%, respectively (Table 1).

Discussion

Orthodontic treatment not only moves irregular teeth to better positions but also induces a response in the alveolar bone. However, the tissue response inside the alveolar bone is difficult to observe. Although some studies have evaluated the bone response during tooth movements associated with orthodontic treatment, most of them have only investigated animal [1–4] or performed computer simulations [7–10]. To our best knowledge, no published papers have focused on the bone density changes during orthodontic treatment in human subjects. This study has pioneered the use of a CBCT approach to assess the bone

Fig. 4 a–h Bone density changes around the teeth in the three portions of each patient during orthodontic treatment. UR3, upper-right canine; UR2, upper-right lateral incisor; UR1, upper-right central incisor; UL1, upper-left central incisor; UL2, upper-left lateral incisor; UL3, upper-left canine

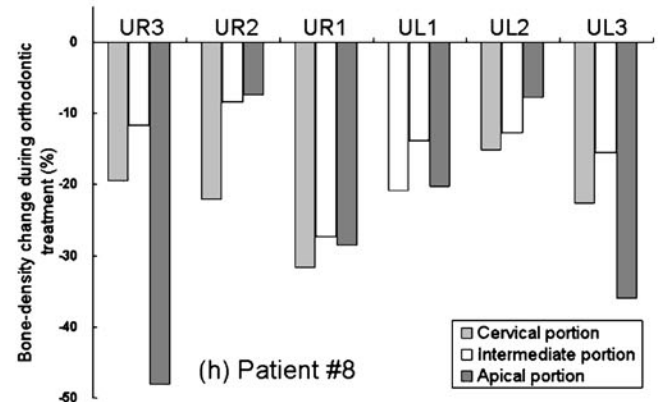
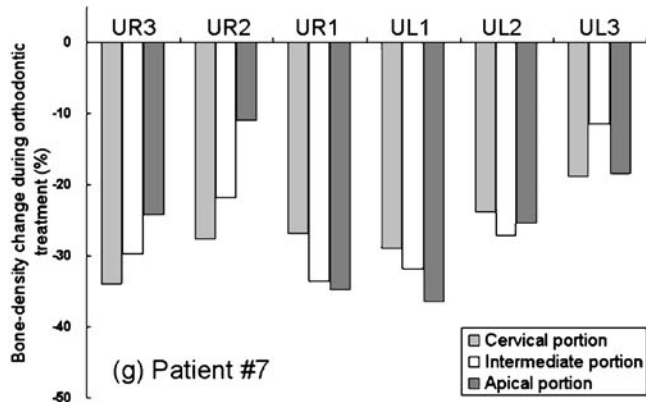
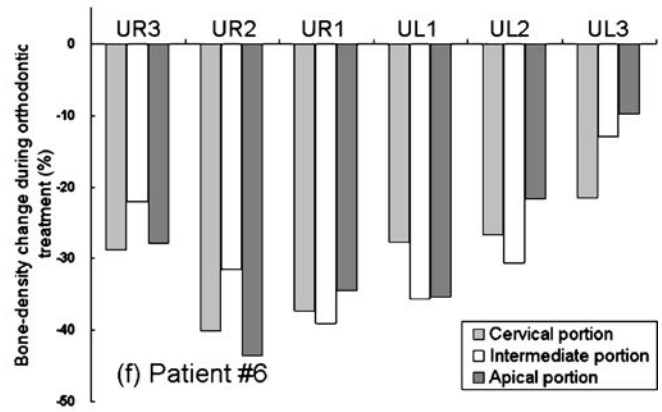
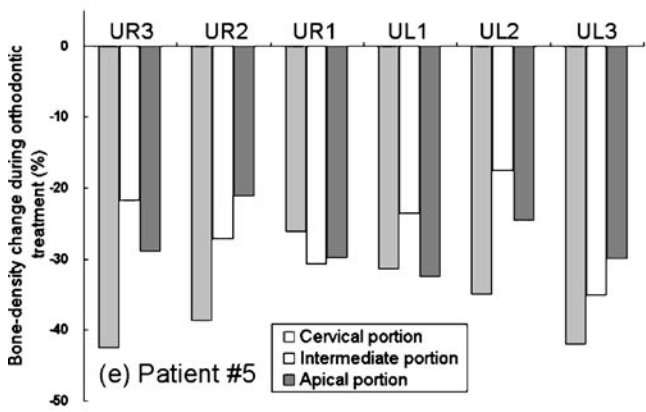
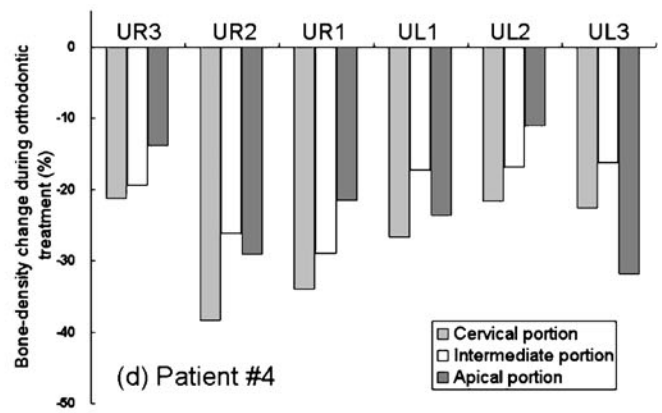
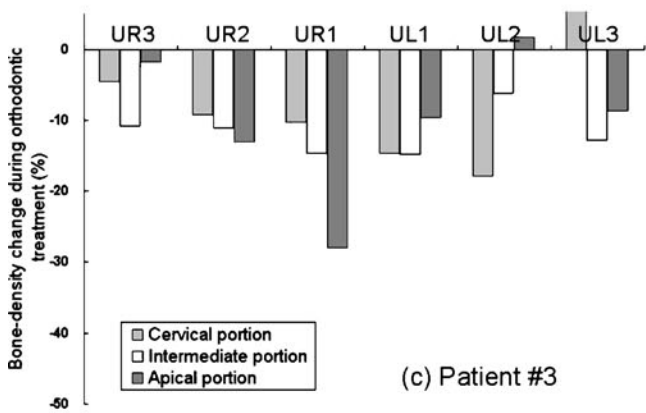
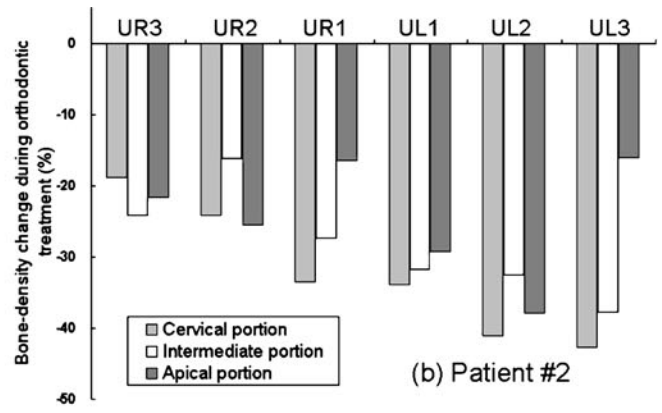
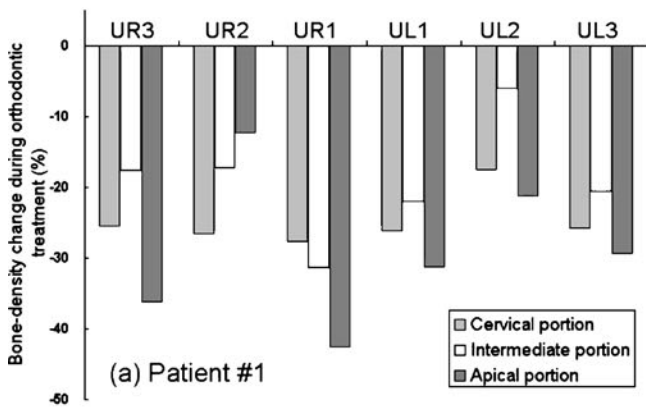


Table 1 Percentage bone density (grayscale value) reductions (mean \pm standard deviation values) around the teeth in the three portions of the eight patients during orthodontic treatment

Portion of tooth	UR3	UR2	UR1	UL1	UL2	UL3	Mean \pm SD
Cervical	24.3 \pm 11.3	28.3 \pm 10.5	28.4 \pm 8.3	26.3 \pm 6.0	24.8 \pm 9.1	23.3 \pm 16.1	25.9 \pm 10.3
Intermediate	19.6 \pm 6.3	20.0 \pm 8.1	29.1 \pm 7.0	23.8 \pm 8.4	18.7 \pm 10.4	20.3 \pm 10.3	21.9 \pm 8.9
Apical	22.5 \pm 13.9	18.1 \pm 12.1	26.2 \pm 8.1	24.2 \pm 9.0	16.4 \pm 12.3	20.0 \pm 10.5	23.9 \pm 11.2
Mean \pm SD	23.1 \pm 10.8	22.0 \pm 12.1	29.0 \pm 7.5	25.8 \pm 7.7	20.7 \pm 10.6	22.9 \pm 10.7	

UR3 upper-right canine, UR2 upper-right lateral incisor, UR1 upper-right central incisor, UL1 upper-left central incisor, UL2 upper-left lateral incisor, UL3 upper-left canine

density changes around teeth during movements induced by orthodontic treatment.

Many orthodontists have confused the terms of “modeling” and “remodeling” in recent decades [25]. According to the definitions of Frost et al., “modeling” is the sculpting mechanism that uses the raw material of bone growth to shape structures, whereas “remodeling” is the mechanism involving the lifelong skeletal turnover and maintenance [25]. Basically, tooth movements resulting from orthodontic forces provide a mechanical stimulus to biological responses, and the transformation involves both bone modeling and remodeling. Previous animal experimental studies have indicated that the alveolar bone around a tooth is significantly affected by orthodontic force [1–3, 25, 26], but it was unclear whether these evaluations applied in vivo to human subjects.

Some researches have demonstrated that CT is a very useful approach for evaluating the alveolar bone density. Most of them have focused on evaluating the bone density prior to dental implant surgery [18–22]. However, CT was not considered a good option for this study due to its high radiation dosage, since (1) CT scanning was to be performed twice within 1 year (before and after 7 months of orthodontic treatment) and (2) the radiation dosage delivered to the patient during each scan is typically around 3 mGy for CT [27] and 0.62 mGy for CBCT [28]. Other advantages of CBCT are that it is cheaper and is readily available in dental clinics. However, Hua et al. [29] reported that the bone density could not be accurately determined from the CBCT image. Although the image quality of CBCT is affected by many factors, including the FOV, voxel resolution, object morphology [30], object location (in the center or periphery of the scanning volume) [31], and the presence/absence of metal implants in the mouth [32], Lagravere et al. [33] reported that there is a linear relationship between actual densities and the HU values (grayscale values) obtained in a CBCT scan. In addition, Aranyarachkul et al. [23] demonstrated that CBCT is a feasible method for evaluating the bone density in implant preoperative assessments. Moreover, all of the parameters (i.e., FOV, voxel resolution, voltage, and

current) of the CBCT instrument and the posture and position of the patients were identical in each scan of our in vivo study. Finally, the grayscale values of the validation phantoms were consistent on the two CBCT scanning days. Therefore, CBCT was selected as the evaluation approach in this study.

Tooth movement is known to occur either “with bone” or “through bone” [3]. When teeth are moved with bone, the amount of bone resorption on the alveolar wall in the direction of the force balances the bone formation at a certain distance from the tooth in the direction of its movement, resulting in no net loss of bone [3]. However, upon increasing the pressure in the PDL to a high level, hyalinization is generated and an indirection resorption is started. Furthermore, no compensatory apposition occurs in this situation, and the balance between resorption and formation is lost [2], resulting in a net loss of bone. In the present study, the bone density around the teeth reduced by 20–30%, which probably indicates that the teeth were moved in the stage of “through bone”.

Our experimental results indicate that the application of orthodontic forces for 7 months significantly reduced the bone density around the teeth by 24.3 \pm 9.5%. Many factors can affect the bone density, such as body weight, diet habit, and occlusal force [34–36]. However, in this study there were no distinct changes in the dietary habits or body weight during the overall period of orthodontic treatment. Moreover, we also found no significant differences in trabecular bone density in the cervical spine after the orthodontic treatment in all patients (data not shown). Therefore, the bone density changes around the teeth could be attributed to the applied orthodontic forces.

Some studies have focused on the bone response to orthodontic treatment [1–3, 37, 38]. Verna et al. [2] studied the histomorphometric bone responses during tooth movements associated with orthodontic treatment in rats. They found that the alveolar bone fraction (bone volume/total volume) was significantly decreased around displaced teeth. Banse and Devogelaer [39] indicated that the bone density was closely correlated to the bone fraction. In addition, Bridges et al. [1] studied the effect of ages on the rate of

tooth movement and mineral density changes in rats. They found that the alveolar mineral density was significantly reduced after orthodontic treatment in both young and adult rats. Consistent with the previous animal studies, we found that the bone density around displaced teeth was decreased in humans, which is also consistent with immature bone having a lower mineralization and being less dense than older bone [1, 5, 6].

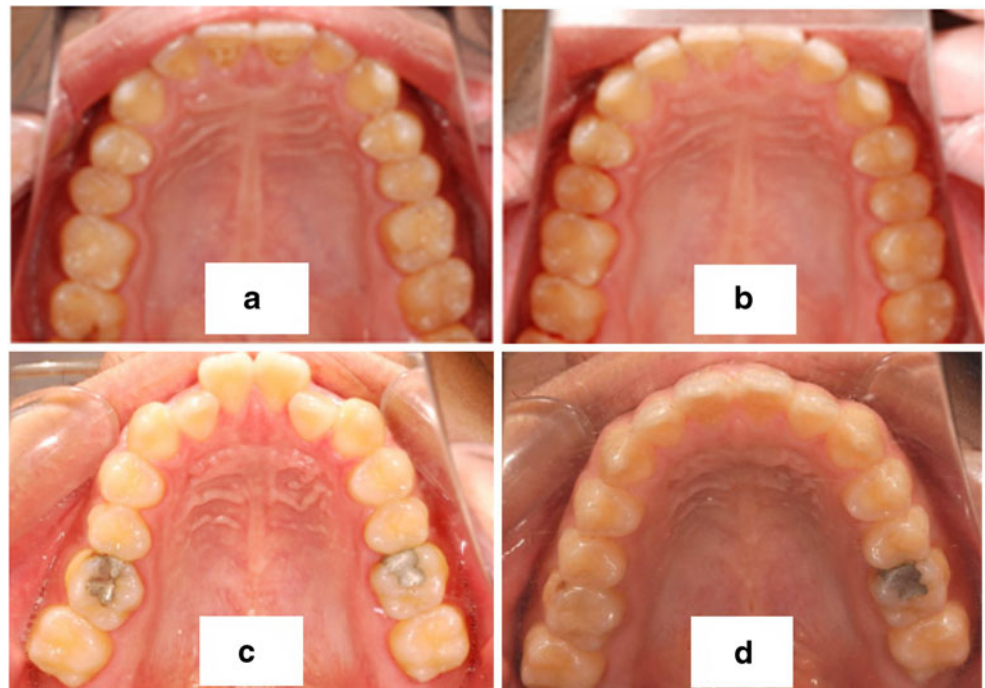
The Kruskal–Wallis test indicated that the bone density reductions were significantly higher in both central incisors than in both lateral incisors and canines (Table 1). This might be due to both central incisors experiencing the largest movements during the period of orthodontics. The tooth displacements in two of our patients between before and after orthodontic treatment are evident in the occlusal photographs of the maxilla shown in Fig. 5. Patient # 5 (Fig. 5c) had much more irregular teeth than patient #3 (Fig. 5a). The bone density reduction was $9.8\pm 8.0\%$ in patient #3 (Fig. 4c) and $29.8\pm 7.0\%$ in patient #5 (Fig. 4e), suggesting that a larger tooth movement during orthodontic treatment might produce a larger bone density change. However, more complete studies that include exact quantifications of tooth movement are needed to confirm this hypothesis.

The mean bone density changes around each tooth did not differ significantly among the cervical, intermediate, and apical portions after orthodontic treatment. This contrasts with Verna et al. [2] finding variations in the changes in different tooth portions. Such differences, if actually present, might be caused by tooth movement with sliding occurring in a stepwise manner involving tooth

tipping and uprighting [40] rather than as a continuous sliding process. Although we found no significant differences, there was a trend for the reduction to be smaller in the intermediate portion ($-21.9\pm 8.9\%$) than in the cervical ($-25.9\pm 10.3\%$) and apical ($-23.9\pm 11.2\%$) portions. This might be indicative of rotation about the intermediate portion and a corresponding smaller movement (compared with the cervical and apical portions of tooth) and hence a smaller reduction in bone density.

Some limitations of this study should be considered. First, the unit of bone density, HU or grayscale value, showed in this study was not as same as “mass per unit volume” in physical definition. However, HU or grayscale value is commonly used and accepted by most researchers to represent the density of bone [18–23]. Second, Mimics software was used in this study, and some previous studies [18, 33] have found that the measured grayscale value or the HU value of an object might vary with the medical software used; however, the values obtained with different software programs were found to be strongly correlated. Third, only eight patients were included in this study due to the CBCT examination not being an essential procedure during orthodontic treatment. However, even in this small sample, there were significant reductions of the bone density around the teeth after 7 months of orthodontic treatment. Fourth, only the teeth in the anterior region of the maxilla were evaluated due to their movements being larger. Teeth with multiple roots should be investigated in a further study. Fifth, the relationship between the bone density change and direction of tooth movements was also not investigated in this study, and the bone density around

Fig. 5 Occlusal photographs of the maxilla of patient # 3 before (a) and after (b) orthodontic treatment and of patient #5 before (c) and after (d) orthodontic treatment



the teeth was only measured at two time points (before and after 7 months of orthodontic treatment), with no long-term follow-up. Long-term follow-up assessments of whether the bone density returns to that prior to orthodontic treatment should be performed in the future. Hence, more complete experiments are needed to understand the bone density changes around teeth during orthodontic treatment.

In conclusion, we found that the bone density around the central incisor, lateral incisor, and canine on both sides of the maxilla reduced by about 24% as irregular teeth moved into better positions after 7 months of orthodontic treatment in all of the investigated patients. In addition to the use of computer simulations and histomorphometric animal models, CBCT represents another approach for evaluating bone density changes around teeth during orthodontic treatment.

Acknowledgements The authors thank Prof. Che-Shoa Chang and Prof. Yuh-Yuan Shiau for their suggestions in this study. The authors also wish to thank Li-Na Liao from Biostatistics Center and Department of Public Health, China Medical University for her assistance of statistical analysis.

Conflict of interest No authors of this study have any financial and personal relationships with other people or organizations that could have resulted in an inappropriate influence on this study.

References

- Bridges T, King G, Mohammed A (1988) The effect of age on tooth movement and mineral density in the alveolar tissues of the rat. *Am J Orthod Dentofacial Orthop* 93:245–250
- Verna C, Zaffe D, Siciliani G (1999) Histomorphometric study of bone reactions during orthodontic tooth movement in rats. *Bone* 24:371–379
- Melsen B (1999) Biological reaction of alveolar bone to orthodontic tooth movement. *Angle Orthod* 69:151–158
- Verna C, Dalstra M, Melsen B (2000) The rate and the type of orthodontic tooth movement is influenced by bone turnover in a rat model. *Eur J Orthod* 22:343–352
- Simmons DJ, Chang SL, Russell JE, Grazman B, Webster D, Oloff C (1983) The effect of protracted tetracycline treatment on bone growth and maturation. *Clin Orthop Relat Res* (180):253–259
- Russell JE, Grazman B, Simmons DJ (1984) Mineralization in rat metaphyseal bone exhibits a circadian stage dependency. *Proc Soc Exp Biol Med* 176(4):342–345
- Cattaneo PM, Dalstra M, Melsen B (2005) The finite element method: a tool to study orthodontic tooth movement. *J Dent Res* 84:428–433
- Cattaneo PM, Dalstra M, Melsen B (2009) Strains in periodontal ligament and alveolar bone associated with orthodontic tooth movement analyzed by finite element. *Orthod Craniofac Res* 12:120–128
- Liang W, Rong Q, Lin J, Xu B (2009) Torque control of the maxillary incisors in lingual and labial orthodontics: a 3-dimensional finite element analysis. *Am J Orthod Dentofacial Orthop* 135:316–322
- Field C, Ichim I, Swain MV, Chan E, Darendeliler MA, Li W, Li Q (2009) Mechanical responses to orthodontic loading: a 3-dimensional finite element multi-tooth model. *Am J Orthod Dentofacial Orthop* 135:174–181
- Jager A, Radlanski RJ, Taufall D, Klein C, Steinhofel N, Doler W (1990) Quantitative determination of alveolar bone density using digital image analysis of microradiographs. *Anat Anz* 170:171–179
- Drage NA, Palmer RM, Blake G, Wilson R, Crane F, Fogelman I (2007) A comparison of bone mineral density in the spine, hip and jaws of edentulous subjects. *Clin Oral Implants Res* 18:496–500
- Oltramari PV, Navarro Rde L, Henriques JF, Taga R, Cestari TM, Janson G, Granjeiro JM (2007) Evaluation of bone height and bone density after tooth extraction: an experimental study in minipigs. *Oral Surg Oral Med Oral Pathol Oral Radiol Endod* 104:e9–e16
- Al Haffar I, Padilla F, Nefussi R, Kolta S, Foucart JM, Laugier P (2006) Experimental evaluation of bone quality measuring speed of sound in cadaver mandibles. *Oral Surg Oral Med Oral Pathol Oral Radiol Endod* 102:782–791
- BouSerhal C, Jacobs R, Quirynen M, van Steenberghe D (2002) Imaging technique selection for the preoperative planning of oral implants: a review of the literature. *Clin Implant Dent Relat Res* 4:156–172
- Chen WP, Hsu JT, Chang CH (2003) Determination of Young's modulus of cortical bone directly from computed tomography: a rabbit model. *J Chin Inst Eng* 22:121–128
- Homolka P, Beer A, Birkfellner W, Nowotny R, Gahleitner A, Tschabitscher M, Bergmann H (2002) Bone mineral density measurement with dental quantitative CT prior to dental implant placement in cadaver mandibles: pilot study. *Radiology* 224:247–252
- de Oliveira RC, Leles CR, Normanha LM, Lindh C, Ribeiro-Rotta RF (2008) Assessments of trabecular bone density at implant sites on CT images. *Oral Surg Oral Med Oral Pathol Oral Radiol Endod* 105:231–238
- Norton MR, Gamble C (2001) Bone classification: an objective scale of bone density using the computerized tomography scan. *Clin Oral Implants Res* 12:79–84
- Shahlaie M, Gantes B, Schulz E, Riggs M, Crigger M (2003) Bone density assessments of dental implant sites: 1. Quantitative computed tomography. *Int J Oral Maxillofac Implants* 18:224–231
- Shapurian T, Damoulis PD, Reiser GM, Griffin TJ, Rand WM (2006) Quantitative evaluation of bone density using the Hounsfield index. *Int J Oral Maxillofac Implants* 21:290–297
- Turkylmaz I, Tozum TF, Tumer C (2007) Bone density assessments of oral implant sites using computerized tomography. *J Oral Rehabil* 34:267–272
- Aranyarachkul P, Caruso J, Gantes B, Schulz E, Riggs M, Dus I, Yamada JM, Crigger M (2005) Bone density assessments of dental implant sites: 2. Quantitative cone-beam computerized tomography. *Int J Oral Maxillofac Implants* 20:416–424
- Toms SR, Eberhardt AW (2003) A nonlinear finite element analysis of the periodontal ligament under orthodontic tooth loading. *Am J Orthod Dentofacial Orthop* 123:657–665
- Roberts WE, Roberts JA, Epker BN, Burr DB, Hartsfield JK (2006) Remodeling of mineralized tissues, part I: the Frost legacy. *Semin Orthod* 12:216–237
- Roberts WE, Epker BN, Burr DB, Hartsfield JK, Roberts JA (2006) Remodeling of mineralized tissues, part II: control and pathophysiology. *Semin Orthod* 12:238–253
- Cann CE (1988) Quantitative CT for determination of bone mineral density: a review. *Radiology* 166:509–522
- Mozzo P, Procacci C, Tacconi A, Martini PT, Andreis IA (1998) A new volumetric CT machine for dental imaging based on the cone-beam technique: preliminary results. *Eur Radiol* 8:1558–1564

29. Hua Y, Nackaerts O, Duyck J, Maes F, Jacobs R (2009) Bone quality assessment based on cone beam computed tomography imaging. *Clin Oral Implants Res* 20:767–771
30. Katsumata A, Hirukawa A, Okumura S, Naitoh M, Fujishita M, Arijji E, Langlais RP (2007) Effects of image artifacts on gray-value density in limited-volume cone-beam computerized tomography. *Oral Surg Oral Med Oral Pathol Oral Radiol Endod* 104:829–836
31. Katsumata A, Hirukawa A, Noujeim M, Okumura S, Naitoh M, Fujishita M, Arijji E, Langlais RP (2006) Image artifact in dental cone-beam CT. *Oral Surg Oral Med Oral Pathol Oral Radiol Endod* 101:652–657
32. Draenert FG, Coppenrath E, Herzog P, Muller S, Mueller-Lisse UG (2007) Beam hardening artefacts occur in dental implant scans with the NewTom cone beam CT but not with the dental 4-row multidetector CT. *Dento Maxillo Facial Radiol* 36:198–203
33. Lagravere MO, Carey J, Ben-Zvi M, Packota GV, Major PW (2008) Effect of object location on the density measurement and Hounsfield conversion in a NewTom 3G cone beam computed tomography unit. *Dento Maxillo Facial Radiol* 37:305–308
34. Weiss M, Yogev R, Dolev E (1998) Occupational sitting and low hip mineral density. *Calcif Tissue Int* 62:47–50
35. Sidiropoulou-Chatzigiannis S, Kourtidou M, Tsalikis L (2007) The effect of osteoporosis on periodontal status, alveolar bone and orthodontic tooth movement. A literature review. *J Int Acad Periodontol* 9:77–84
36. Midgett RJ, Shaye R, Fruge JF Jr (1981) The effect of altered bone metabolism on orthodontic tooth movement. *Am J Orthod* 80:256–262
37. Melsen B (2001) Tissue reaction to orthodontic tooth movement—a new paradigm. *Eur J Orthod* 23:671–681
38. Verna C, Melsen B (2003) Tissue reaction to orthodontic tooth movement in different bone turnover conditions. *Orthod Craniofac Res* 6:155–163
39. Banse X, Devogelaer JP (2002) Does peripheral quantitative computed tomography ignore tissue density of cancellous bone? *J Clin Densitom* 5:403–410
40. Bednar JR, Gruendeman GW, Sandrik JL (1991) A comparative study of frictional forces between orthodontic brackets and arch wires. *Am J Orthod Dentofacial Orthop* 100:513–522

Copyright of Clinical Oral Investigations is the property of Springer Science & Business Media B.V. and its content may not be copied or emailed to multiple sites or posted to a listserv without the copyright holder's express written permission. However, users may print, download, or email articles for individual use.