

Salivary IL-6 levels in oral leukoplakia with dysplasia and its clinical relevance to tobacco habits and periodontitis

Mohit Sharma · Indira Bairy · Keerthilatha Pai ·
Kapaettu Satyamoorthy · Shailendra Prasad ·
Barry Berkovitz · Raghu Radhakrishnan

Received: 9 January 2010 / Accepted: 7 June 2010 / Published online: 19 June 2010
© Springer-Verlag 2010

Abstract The development of oral cancer proceeds through discrete molecular changes that are acquired from loss of genomic integrity after continued exposure to environmental risk factors. It is preceded in the majority of cases by clinically evident oral potentially malignant disorders, the most common of which is leukoplakia. Early detection of these oral lesions by screening methods using suitable markers is critical as it mirrors molecular alterations, long before cancer phenotypes are manifested. Assessment of

salivary interleukin-6 (IL-6) as a marker of malignant progression was undertaken in patients with leukoplakia having coexisting periodontitis ($n=20$), periodontitis patients without leukoplakia ($n=20$), and healthy controls ($n=20$) by competitive enzyme-linked immunosorbent assay. Results showed elevation of IL-6 levels in leukoplakia with coexisting periodontitis and in periodontitis patients when compared to healthy control ($P<0.001$). Within the leukoplakia group, IL-6 level was found to be increased with increase in the severity of dysplasia. The use of tobacco was seen to play a significant role in the elevation of salivary IL-6. The importance of IL-6 as a specific marker for leukoplakia with dysplasia and the role of tobacco as an independent risk factor has been highlighted.

M. Sharma · R. Radhakrishnan (✉)
Department of Oral Pathology,
Manipal College of Dental Sciences, Manipal University,
Manipal, India
e-mail: raghu.radhakrishnan@gmail.com

I. Bairy
Department of Microbiology, Kasturba Medical College,
Manipal University,
Manipal, India

K. Pai
Department of Oral Medicine,
Manipal College of Dental Sciences, Manipal University,
Manipal, India

K. Satyamoorthy
Department of Biotechnology, Manipal Life Sciences Centre,
Manipal University,
Manipal, India

S. Prasad
Department of Family Medicine & Community Health,
Medical School, University of Minnesota,
Minneapolis, MN, USA

B. Berkovitz
Department of Anatomy & Human Sciences,
Biomedical & Health Sciences, King's College,
London, UK

Keywords Cytokine · IL-6 · NF- κ B · Leukoplakia ·
Epithelial dysplasia · Periodontitis · Oral cancer · Tobacco

Introduction

The pathogenesis of oral squamous cell carcinoma (OSCC) is a result of multiple molecular events triggered by various topical carcinogens such as tobacco use [1], alcohol misuse [2], and possibly viruses against a background of heritable resistance and susceptibility [3]. Tobacco and alcohol misuse patterns have shown to account for nearly all of the observed racial differences in rates of oral cancers [4]. Accumulation of these genetic changes leads to oral cancer in some instances via clinically evident oral potentially malignant disorder (OPMD) [5], which may undergo sequential pathological changes from dysplasia to invasive carcinoma. Although environmental factors may play an important role in the etiology, some patients are susceptible, owing to an inherited trait in their ability or inability to

metabolize carcinogens or procarcinogens, possibly along with an impaired ability to repair the DNA damage [4]. Leukoplakia is the most common of the OPMDs, with a risk of malignant transformation varying from 0.6% to 18% [6, 7]. Leukoplakia progressing to squamous cell carcinoma has been accepted to be directly related to the severity of dysplasia [8].

Measurement of suitable biomarkers has provided newer options for early detection and risk assessment of oral cancer. However, majority of these are identified either in serum, cell lines, or biopsy specimens, making it challenging for large-scale screening. Measurement of molecular markers in salivary fluid could potentially aid in development of a practical screening tool. The levels of certain inflammatory, proangiogenic cytokines in saliva, and tissue specimens of patients with oral cancer have been shown to be elevated. Significantly, levels of interleukin-6 (IL-6) and interleukin-8 (IL-8) have been shown to be consistently elevated in cancers of the head and neck with higher nodal stage [9].

In this study, we measured the level of IL-6 in whole unstimulated saliva (WUS) of patients with leukoplakia with dysplasia by competitive enzyme-linked immunosorbent assay (ELISA) and correlated the IL-6 levels with different grades of dysplasia. We hypothesized that salivary IL-6 levels would correlate strongly to level of dysplasia.

Material and methods

The study subjects were classified into three groups of 20 each based on the presence of leukoplakia and periodontitis. Group 1 consisted of patients with oral leukoplakia with histologically confirmed epithelial dysplasia, who presented with coexisting periodontitis. Group 2 were patients who had periodontitis without leukoplakia, and group 3 were healthy volunteers with normal oral mucosa. The saliva collected from group 1 patients constituted the test group, while those from group 2 and group 3 were considered as positive and negative controls, respectively.

Cases which were provisionally diagnosed as leukoplakia with dysplasia were graded by criteria put forth by Lumerman et al. [10]. The grading carried out by two independent observers was statistically analyzed using the Mann–Whitney *U* test to check for the interobserver variability. Since the interobserver variability was not significant, readings of just one observer were used for further statistical analyses.

Periodontal status (Community Periodontal Index) was recorded according to the criteria set forth by WHO [11] to ascertain uniform parameters for identical comparison. The presence of periodontitis was assessed dichotomously. The same examiner carried out the recordings for all the patients using Community Periodontal Index of Treatment Needs

probe. Intra-examiner reliability was assessed by kappa statistics ($\kappa=0.85$). Only cases with more than three sextants having scores of 3 and 4 were considered as having chronic generalized periodontitis.

Prior to study enrolment, a written informed consent form approved by University Ethics Committee (UEC/9/2009), Manipal was obtained from all the volunteers. The WUS was collected from each of the participants and stored at -70°C till analyzed. The IL-6 level in WUS was estimated by ELISA using a commercially available kit (Immunotech, France). The IL-6 levels measured in leukoplakia patients were subsequently correlated with their corresponding histopathological indicators [12].

Patients included in the study were in their third to sixth decade of life with or without a history of tobacco use. WUS was collected only from male patients to eliminate any gender difference. The following patients were excluded from the study: patients who were on strenuous exercise regimen a day before, those who had caffeine (tea/coffee), chewed gum or drank water just prior to test, consumed dairy products 20 min prior to saliva collection, had sugar or acidic food at the time of test, were alcoholics or had alcohol, addictive drugs, glucocorticoids, estrogens, anticholinergics, antihistamines, antihypertensives, and beta-adrenergic blockers 24 h before sample collection, those who had mucosal lesions other than leukoplakia, and with systemic diseases like Sjögren's syndrome and diabetes mellitus.

Collection of WUS

WUS was collected by standard techniques for 5 min [13] between 8:00 AM and 11:00 AM to avoid any diurnal variation in IL-6 levels. Patients were advised to rinse the mouth several times with deionized water and allowed to relax for 5 min. To increase the hydration, a waiting period of at least 10 min was necessary after rinsing and before collecting saliva to avoid sample dilution. With the head leaning forward, saliva was collected in wide mouth sterile containers using a funnel, sitting beside the patient by a simple drooling method. Containers were discarded after each use to comply with standard infection control procedures. The samples were stored at -70°C until analysis to minimize the effect of proteases present in saliva. Saliva was not stored longer than 2 months.

Salivary IL-6 calculation

Salivary analysis was done in one go to avoid repeated freeze–thaw cycles and to avoid sample degradation. The thawed salivary sample was centrifuged at 4,500 rpm/5 min and the supernatant collected in 5 ml vial. The concentration of salivary IL-6 in the supernatant was determined by an ELISA assay using A commercial kit [14] (Immunotech,

France). Components of the kit were allowed to equilibrate for 30 min at room temperature before use. From the 1,000-pg/ml calibrator solution, a fresh dilution series in plastic tubes was prepared prior to each assay using diluent 1 for IL-6 in saliva (as per manufacturer's instruction). This dilution series was used immediately and not stored. Briefly, 100 μ l of calibrator or sample was added to each well along with 100 μ l of IL-6 acetylcholinesterase conjugate and incubated for 2 h 18–25°C while shaking, following which the wells were washed with wash solutions. Two hundred microliters of substrate was added and incubated for 30 min in the dark while shaking. Finally, 50 μ l of stop solution was added and absorbance recorded at 405 nm. Pipetting of substrate and stop solution was carried out quickly.

Calibrators and samples were assayed at the same time. A calibrator curve was plotted with each assay (Fig. 1). A calibrator curve was drawn on a semilog paper. The horizontal (X) axis represents the IL-6 concentration of the calibrators obtained by diluting calibrator solution, and the vertical (Y) axis represents the corresponding optical density (OD). Concentration of samples was determined by plotting the OD obtained from ELISA Reader on the Y -axis and drawing a horizontal to intersect the calibrator curve. Dropping a perpendicular from the point of intersect on the graph provided a value in picograms per milliliter on X -axis. The IL-6 level was expressed as a mean \pm standard deviation.

Statistical analysis

The Statistical Package for Social Sciences 11.5 for Windows was used for analyzing the results. Analyses by

one-/two-way analysis of variance (ANOVA) and Bonferroni correction method were used. A P value of less than 0.05 was considered to be significant. A regression analysis was applied to analyze both the dependent and independent variables.

Results

A detailed history was recorded and clinical examination carried out, and the characteristics of the different groups are described (Table 1). Salivary IL-6 in leukoplakia with coexisting periodontitis had a mean of 414.95 ± 36.69 pg/ml, while the periodontitis cases without leukoplakia had a mean of 311.35 ± 11.51 pg/ml. The control subjects had a mean of 17.15 ± 8.44 pg/ml (Fig. 2). One-way ANOVA for IL-6 levels with regard to the three study groups was statistically significant (Table 1). Multiple comparisons by post hoc Bonferroni analysis between the three study groups showed that each group was different with respect to each other ($P < 0.001$).

Further, two-way ANOVA for IL-6 level with respect to habits showed that group 1 patients with a positive history of tobacco habits had higher IL-6 levels (420.94 ± 36.67 pg/ml) compared to those without tobacco habits (381.00 ± 1.00 pg/ml). Similar observations were also noted in the group 2, where a higher level of IL-6 was noted in patients with tobacco habits (320.90 ± 7.02 pg/ml) as compared to those without the habit (301.80 ± 5.27 pg/ml). The healthy group 3 individuals also yielded similar findings, with IL-6 levels being higher in those with tobacco habits (24.90 ± 2.60 pg/ml) than those without its use (9.40 ± 3.17 pg/ml; Fig. 3).

Fig. 1 Semilog graph showing the calibrator curve plotted on a semilog paper by plotting IL-6 concentration on the horizontal axis corresponding optical density on the vertical axis

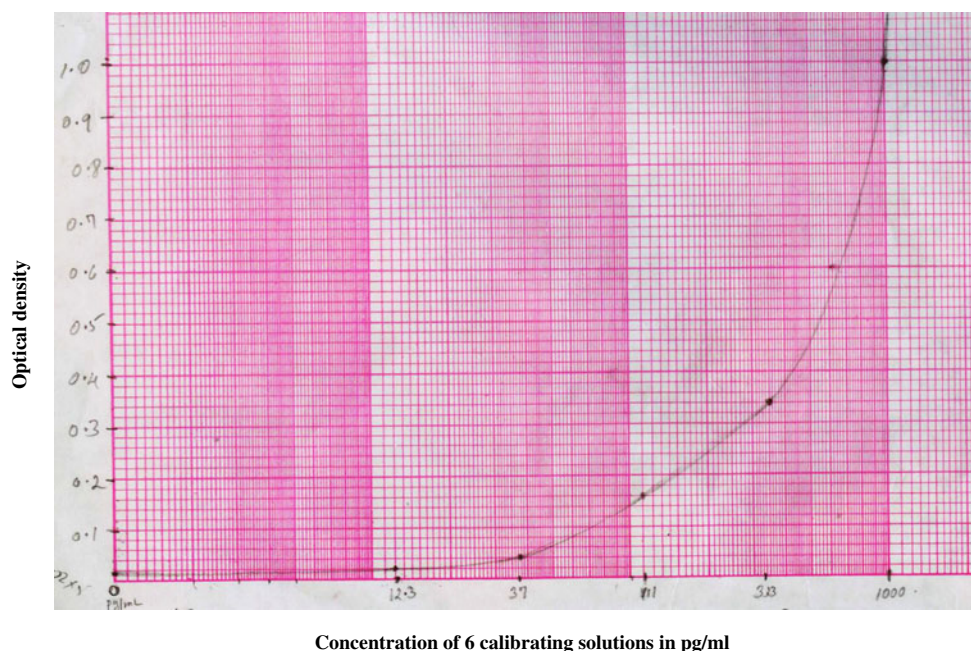


Table 1 Analysis of IL-6 in three different patient groups along with their habit history

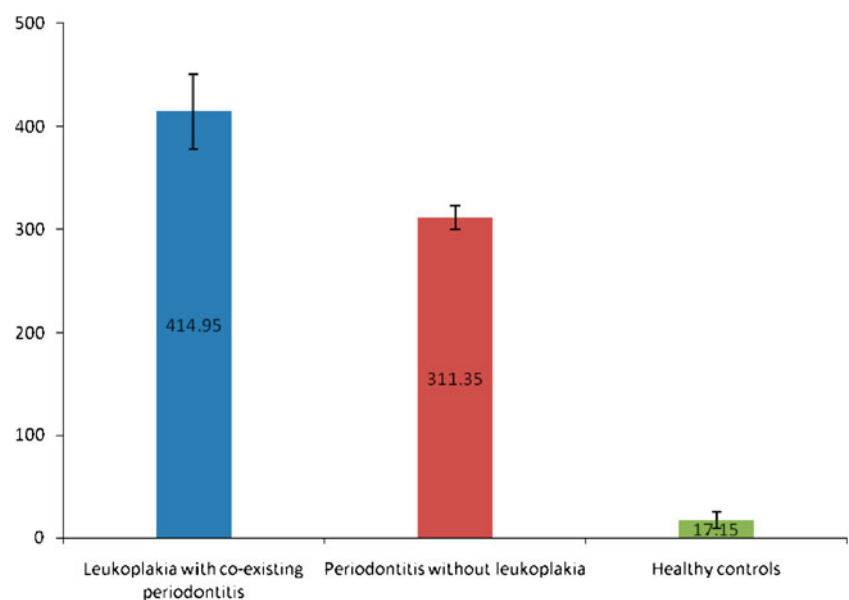
No	Age	Sex	Habit	Per day	Time (years)	Site	Variant	Grade	IL-6 (pg/ml)
Group 1—leukoplakia (with chronic periodontitis)									
1	58	M	Bidi	2 packs	25	Cheek	Homogenous	Mild	387
2	42	M	None			Cheek	Homogenous	Mild	380
3	43	M	None			Cheek	Homogenous	Mild	381
4	44	M	None			Cheek	Homogenous	Mild	382
5	45	M	Pan	4 packs	20	Cheek	Homogenous	Mild	388
6	46	M	Betel nut	3 number	15	Cheek	Homogenous	Mild	386
7	47	M	Tobacco	9 pouches	20	Cheek	Speckled	Mild	390
8	31	M	Tobacco	12 pouches	25	Cheek	Homogenous	Mild	391
9	45	M	Pan	3 sachet	25	Cheek	Speckled	Moderate	412
			Cigarette	1 pack	20				
10	48	M	Cigarette	1 pack	20	Lip	Speckled	Moderate	401
11	46	M	Bidi	15 number	15	Cheek	Speckled	Moderate	410
			Tobacco	10 pouch	10				
12	48	M	Bidi	10 number	10	Cheek	Homogenous	Moderate	409
13	43	M	Bidi	7 number	25	Cheek	Speckled	Moderate	398
14	47	M	Pan	9 number	20	Tongue	Homogenous	Moderate	405
			Bidi	20 number	15				
15	48	M	Tobacco	9 pouches	20	Cheek	Homogenous	Moderate	406
16	52	M	Tobacco	12 pouches	25	Cheek	Speckled	Severe	479
17	56	M	Tobacco	9 pouches	20	Tongue	Speckled	Severe	472
18	59	M	Bidi	7 number	25	Tongue	Speckled	Severe	470
19	48	M	Pan	4 packs	20	Cheek	Homogenous	Severe	474
			Tobacco	4 pouches	7				
20	45	M	Pan	5 packs	10	Cheek	Speckled	Severe	478
Group 2—chronic periodontitis (without leukoplakia)									
1	54	M	Bidi	10 number	9				327
2	47	M	None						309
3	55	M	Tobacco	6 pouches	10				324
4	61	M	None						306
5	60	M	None						301
6	50	M	None						302
7	35	M	None						303
8	40	M	Pan	6–7 packs	10				320
9	39	M	None						305
10	47	M	Tobacco	5 pouches	10				328
11	48	M	Pan	6–8 packs	10				326
12	48	M	None						301
13	47	M	Pan	6–8 packs	14				330
			Bidi	20 number	2				
14	50	M	None						302
15	38	M	Gutkha	5–6 packs	2				310
16	40	M	None						300
17	48	M	Pan	5 packs	10				315
			Cigarettes	2 packs	5				
18	35	M	Pan	4–5 packs	10				314
19	36	M	Pan	5–6 packs	11				315
20	38	M	None						289

Table 1 (continued)

No	Age	Sex	Habit	Per day	Time (years)	Site	Variant	Grade	IL-6 (pg/ml)
Group 3—healthy controls									
1	40	M	None						10
2	41	M	Pan	5–6 packs	12				21
3	34	M	None						13
4	37	M	None						12
5	45	M	Pan	3–4 packs	10				22
6	41	M	None						13
7	65	M	Pan	3–5 packs	12				26
8	42	M	None						13
9	38	M	Betel nut	5–6 packs	12				27
10	39	M	Bidi	8–9 number	10				28
11	28	M	None						8
12	30	M	Pan	3–4 packs	10				25
13	36	M	Pan	3–4 packs	10				24
14	39	M	None						7
15	35	M	None						5
16	39	M	None						6
17	38	M	None						7
18	36	M	Pan	5–6 packs	10				24
19	37	M	Pan	4–5 packs	10				23
20	32	M	Bidi	12 number	12				29

Every group was significantly different with respect to each other as demonstrated by Bonferroni analysis. IL-6 was significantly higher in all the three groups with a positive tobacco habit history than those without tobacco habits ($P<0.001$).

One-way ANOVA for IL-6 levels with regard to different grades of dysplasia was statistically significant ($P<0.001$). Eight individuals with mild dysplasia presented with a mean value of 385.63 ± 4.17 pg/ml. 7 individuals with moderate dysplasia yielded a mean value of $405.86\pm$

Fig. 2 Bar diagram showing the level of IL-6 in three different groups studied

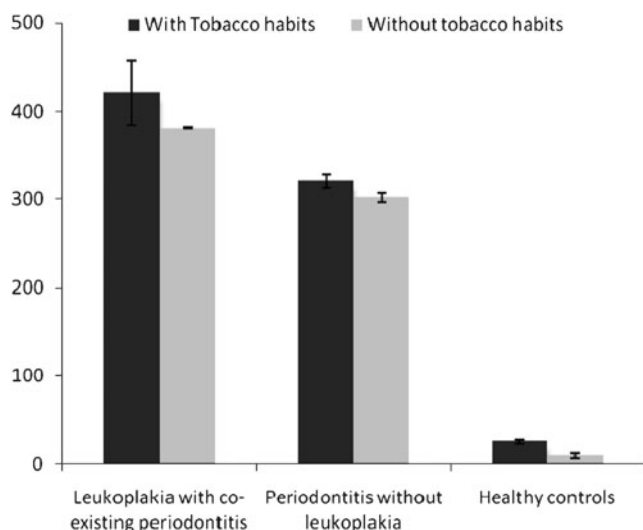


Fig. 3 Bar diagram showing the level of IL-6 with respect to habits associated in the study group

5.01 pg/ml, while five individuals with severe dysplasia gave a mean value 474.60 ± 3.85 pg/ml (Tables 2 and 3). Regression analysis of the different groups showed that 98.6% of IL-6 variation was explainable by patient grouping and association with tobacco use (Table 4).

Discussion

Molecular markers which are identified and characterized in saliva have distinct advantages in pathological diagnosis as they reflect the overall health and disease states in an individual. Because of the anatomical proximity of saliva to the oral cavity, salivary testing would be ideal for evaluating potentially malignant and malignant oral lesions [15–17]. IL-6 is an NF- κ B dependent cytokine produced by inflammatory cells as well as tumor cells [18]. The serum levels of IL-6 have been shown to be consistently elevated in patients with cancers of the head and neck and in patients with higher nodal stages [19]. It has also been shown to be an important serum biomarker for predicting therapeutic responses and survival in advanced-stage, head and neck cancer [20].

As NF- κ B-dependent cytokine levels are shown to be significantly elevated in saliva of patients with preneoplastic lesions and OSCC [21], the potential value of IL-6 as a diagnostic marker of malignant transformation was considered keeping tobacco associated and degree of dysplasia into consideration. A significant correlation has been demonstrated between the IL-8 and IL-6 levels in serum and saliva [22]. In this context, it has been found that the IL-6 level in saliva was three to four times more than that in serum.

The saliva-based evaluation of IL-6 in our series showed that all the leukoplakia patients with coexisting periodontitis had higher IL-6 levels when compared with saliva of patients with periodontitis alone. This finding of elevated IL-6 in saliva is supported by a similar study carried out by Brailo et al. [12]. The elevated salivary IL-6 level in their observations was independent of any tobacco habit, unlike our findings where we noted a direct correlation between IL-6 and tobacco habits, implying that tobacco did play a significant role in IL-6 elevation. The NF- κ B-dependent cytokines are elevated as a result of localized production from at least two sources, either by the lesional epithelium itself or by the activated T lymphocytes present in the connective tissue affected with leukoplakia. Besides that, it is also known that oral epithelial cells are able to secrete IL-6 as a response to various microbial and chemical stimuli [23, 24].

Our study showed a sequential increase in IL-6 level from mild to severe dysplasia. These findings are in agreement with another report by Rhodus et al. [21] who demonstrated that IL-6 was increased in mild, moderate, and severe dysplasia compared to controls but not as much when compared with OSCC. It has also been suggested that an increase in both the systemic and local IL-6 level correlates with the growth of oral carcinomas [25]. The increased levels related to the clinical stage of the disease seemed to be the most sensitive parameter, particularly in the early stages of oral cancer. These cytokines and their transcripts were localized in stromal macrophages and in the tumor cells, particularly in the tumor front, indicating active synthesis of these cytokines by tumor cells [26].

All the patients with leukoplakia in our study had coexisting periodontitis as it was not possible to exclude

Table 2 One-way analysis of variance of IL-6 levels in three study groups

Group	Number	Mean	Standard deviation	95% confidence interval for mean	
				Lower bound	Upper bound
Leukoplakia–periodontitis	20	414.95	36.693	397.78	432.12
Periodontitis	20	311.35	11.509	305.96	316.74
Controls	20	17.15	8.437	13.20	21.10

ANOVA $F=1,648.587$; $P<0.001$; HS

Table 3 One-way ANOVA for IL-6 level with respect to grades of dysplasia

Group	Number	Mean IL-6 (pg/ml)	SD	95% confidence interval for mean	
				Lower bound	Upper bound
Periodontitis + mild dysplasia	8	385.63	4.173	382.14	389.11
Periodontitis + moderate dysplasia	7	405.86	5.014	401.22	410.49
Periodontitis + severe dysplasia	5	474.60	3.847	469.82	479.38

ANOVA $F=5,658.345$; $P<0.001$; HS

this feature due to the demographic profile of our patients. This inclusion was distinct, in contrast to Brailo et al. [12] who excluded patients with periodontitis. It is perhaps because of this inflammatory component in periodontitis, in addition to the dysplastic epithelium of leukoplakia, that the IL-6 level noted in our series was greater than that previously reported in literature.

IL-6 as a multifunctional cytokine binds to a heterodimeric receptor, which contains the ligand-binding IL-6 α chain and the common cytokine receptor signal-transducing subunit gp130 [27]. IL-6 receptor engagement leads to activation of the JAK family of tyrosine kinases, which then stimulate multiple pathways involving MAPKs, PI3Ks, STATs, and other signaling proteins [28]. Various subcomponents of these pathways have been implicated in influencing the carcinogenic cascade in various cancers including OSCC and premalignant oral lesions [29–31].

IL-6 expression has shown to be induced by the transcription factor NF- κ B under hypoxic conditions [32]. It has been shown that the presence of hypoxia is correlated with aggressive tumor growth and poor patient prognosis [33]. This detrimental effect of hypoxia has been attributed to an increase in the level of hypoxia inducible factor-1 α . The latter one is mediated through the downstream signaling element of IL-6 pathway—the STAT3 [34]. STAT3 regulates G1 to S cell-cycle progression as well as the prevention of apoptosis through c-Myc, Pim-family proteins, valosine containing protein, and Bcl-family proteins [35]. Thus, the IL-6/gp130/STAT3 axis has been

implicated in playing a crucial role in the sequential change from hyperplasia to neoplasia [36, 37].

The change from a paracrine to an autocrine mode of IL-6 signaling is believed to be a key contributing factor in the progression from benign hyperplasia to neoplasia and cancer as reported in several studies [29, 37–40]. Perhaps, increasingly amplified amounts of IL-6, produced by autocrine stimulation, is able to overcome p53 inhibition through the hypermethylation of its promoter [41], and this may well be the point in discussion for elevated IL-6 seen in our series of patients with leukoplakia.

It has been reported that wild-type p53 and Rb repress the promoter of the IL-6 gene [42]. The reciprocal is also true, namely that IL-6 suppresses the activation of p53 [43] and Rb genes. Thus, the balance that is tilted in favor of the p53 and Rb probably keeps tabs on the uncontrolled proliferation of keratinocytes. While autocrine IL-6 production by tumor cells maintains this hypermethylation, withdrawal of IL-6 leads to reversal of methylation of p53 promoter and its subsequent reactivation, with resultant suppression of keratinocyte proliferation [41]. Autocrine IL-6 signaling has thus been implicated as a key event in carcinogenesis [44] and also drug resistance [45].

As expected, elevated IL-6 levels were found in patients with periodontitis alone without leukoplakia, although it was increased to a lesser extent when compared to patients with both leukoplakia and periodontitis. Large numbers of gram-negative periodontopathic bacteria present in the subgingival plaque may seem to be the most obvious cause

Table 4 Results of regression analysis of different habits

Model	Unstandardized coefficients	Standard error	<i>R</i>	<i>R</i> ²	Model fit <i>F</i> value	Standardized coefficients	<i>t</i>	<i>P</i>
	<i>B</i>					Beta		
Constant	6.200	5.409					1.146	0.257
Periodontitis	294.200	6.468				0.816	45.482	0.000
Leukoplakia–periodontitis	390.135	6.777				1.082	57.569	0.000
Habit	21.900	5.774				0.063	3.793	0.000
1			0.993 ^a	0.986	1,361.965			<0.001

Predictors: (constant), habit, periodontitis, leukoplakia–periodontitis. Dependent variable: IL-6 (pg/ml) habit

^a Dependent variable

for this increase. As these bacteria do not invade the periodontium in appreciable numbers, their solubilized components diffuse into periodontal tissues including the epithelium, thereby providing the stimulus for cytokine production. These soluble bacterial components act on a family of membrane bound receptors called toll-like receptors leading to subsequent activation of the NF- κ B pathway, which results in inflammatory cytokine gene transcription and leads to the production of IL-6 and other cytokines [46].

Various studies have shown that the cytokine-rich oral cavity in periodontal disease may contribute to accelerated carcinogenesis [47, 48]. These studies suggest that chronic periodontitis is an independent risk factor for HNSCC and smoking modifies this association [49]. This association was particularly significant in our study, considering the demographics and the increased incidence of oral cancer in the subcontinent.

Significant differences in the concentration of salivary IL-6 between tobacco users and non users in both the study group as well as in control group have been demonstrated by Zhang et al. [50], who reported higher systemic level of IL-6 as a consequence of passive smoking in animal models. Erdemir et al. [51] on the other hand have reported no influence of smoking on IL-6 level in gingival crevicular fluid. The influence of tobacco on IL-6 is attributed to an interaction of the released tobacco products with keratinocytes [23, 52]. Nicotine from tobacco smoke and lipopolysaccharide from bacterial infection may also synergistically enhance IL-6 production in patients with periodontitis [53].

In our study, we found that leukoplakia, periodontitis, and tobacco habits contributed to an elevated IL-6 level. Our observation thus confirms and extends the previous findings that IL-6 expression could be used as a specific marker for lesions that are at high risk of malignant transformation. Our findings also support the recently proposed hypothesis that periodontitis may be a significant contributing risk factor for oral cancer. The study, however, has the limitation of not including female subjects and diet being a confounder. Large multicenter trials are deemed necessary to establish the role of interleukin in the pathogenesis of tobacco associated OPMD.

Acknowledgment This work was supported by a grant from Manipal University, Manipal and generous support from the Department of Microbiology, Kasturba Manipal for the use of laboratory consumables.

Conflict of interest statement The authors of the manuscript titled “Salivary IL-6 levels in oral leukoplakia with dysplasia and its clinical relevance to tobacco habits and periodontitis” hereby declare that no financial or any personal relationship with other individuals or organization has influenced the outcome of this work.

References

1. Amarasinghe HK, Usgodaarachchi US, Johnson NW, Lalloo R, Warnakulasuriya S (2010) Betel-quid chewing with or without tobacco is a major risk factor for oral potentially malignant disorders in Sri Lanka: a case-control study. *Oral Oncol* 46:297–301
2. Harris CK, Warnakulasuriya KA, Cooper DJ, Peters TJ, Gelbier S (2004) Prevalence of oral mucosal lesions in alcohol misusers in south London. *J Oral Pathol Med* 33:253–259
3. Scully C, Field JK, Tanzawa H (2000) Genetic aberrations in oral or head and neck squamous cell carcinoma (SCCHN): 1. Carcinogen metabolism, DNA repair and cell cycle control. *Oral Oncol* 36:256–263
4. Day GL, Blot WJ, Austin DF, Bernstein L, Greenberg RS, Preston-Martin S, Schoenberg JB, Winn DM, McLaughlin JK, Fraumeni JF Jr (1993) Racial differences in risk of oral and pharyngeal cancer: alcohol, tobacco, and other determinants. *J Natl Cancer Inst* 85:465
5. Warnakulasuriya S, Johnson NW, van der Waal I (2007) Nomenclature and classification of potentially malignant disorders of the oral mucosa. *J Oral Pathol Med* 36:575–580
6. Banoczy J, Csiba A (1976) Occurrence of epithelial dysplasia in oral leukoplakia. *Oral Surg Oral Med Oral Pathol* 42:766–774
7. Gupta PC, Mehta FS, Daftary DK, Pindborg JJ, Bhonsle RB, Jalnawalla PN, Sinor PN, Pitkar VK, Murti PR, Irani RR, Shah HT, Kadam PM, Iyer KS, Iyer HM, Hegde AK, Chandrashekar GK, Shiroff BC, Sahiar BE, Mehta MN (1980) Incidence rates of oral cancer and natural history of oral precancerous lesions in a 10-year follow-up study of Indian villagers. *Community Dent Oral Epidemiol* 8:283–333
8. Silverman S Jr, Gorsky M, Lozada F (1984) Oral leukoplakia and malignant transformation. A follow-up study of 257 patients. *Cancer* 53:563–568
9. De Schutter H, Landuyt W, Verbeken E, Goethals L, Hermans R, Nuyts S (2005) The prognostic value of the hypoxia markers CA IX and GLUT 1 and the cytokines VEGF and IL 6 in head and neck squamous cell carcinoma treated by radiotherapy \pm chemotherapy. *BMC Cancer* 5:42
10. Lumerman H, Freedman P, Kerpel S (1995) Oral epithelial dysplasia and the development of invasive squamous cell carcinoma. *Oral Surg Oral Med Oral Pathol Oral Radiol Endod* 79:321–329
11. World Health Organization (1997) Oral health surveys. Basic methods. World Health Organization, Geneva
12. Brailo V, Vucićević-Boras V, Cekić-Arambasin A, Alajbeg IZ, Milenović A, Lukac J (2006) The significance of salivary interleukin 6 and tumor necrosis factor alpha in patients with oral leukoplakia. *Oral Oncol* 42:370–373
13. Navazesh M, Kumar SK, University of Southern California School of Dentistry (2008) Measuring salivary flow: challenges and opportunities. *J Am Dent Assoc* 139(Suppl):35S–40S
14. Ng PY, Donley M, Hausmann E, Hutson AD, Rossomando EF, Scannapieco FA (2007) Candidate salivary biomarkers associated with alveolar bone loss: cross-sectional and in vitro studies. *FEMS Immunol Med Microbiol* 49:252–260
15. Ferguson DB (1987) Current diagnostic uses of saliva. *J Dent Res* 66:420–424
16. Streckfus CF, Bigler LR (2002) Saliva as a diagnostic fluid. *Oral Dis* 8:69–76
17. Zimmermann BG, Wong DT (2008) Salivary mRNA targets for cancer diagnostics. *Oral Oncol* 44:425–429

18. Wang PL, Ohura K, Fujii T, Oido-Mori M, Kowashi Y, Kikuchi M, Suetsugu Y, Tanaka J (2003) DNA microarray analysis of human gingival fibroblasts from healthy and inflammatory gingival tissues. *Biochem Biophys Res Commun* 305:970–973
19. Liao WC, Lin JT, Wu CY, Huang SP, Lin MT, Wu AS, Huang YJ, Wu MS (2008) Serum interleukin-6 level but not genotype predicts survival after resection in stages II and III gastric carcinoma. *Clin Cancer Res* 14:428–434
20. Bigbee WL, Grandis JR, Siegfried JM (2007) Multiple cytokine and growth factor serum biomarkers predict therapeutic response and survival in advanced-stage head and neck cancer patients. *Clin Cancer Res* 13:3107–3108
21. Rhodus NL, Ho V, Miller CS, Myers S, Ondrey F (2005) NF-kappa B dependent cytokine levels in saliva of patients with oral preneoplastic lesions and oral squamous cell carcinoma. *Cancer Detect Prev* 29:42–45
22. St John MA, Li Y, Zhou X, Denny P, Ho CM, Montemagno C, Shi W, Qi F, Wu B, Sinha U, Jordan R, Wolinsky L, Park NH, Liu H, Abemayor E, Wong DT (2004) Interleukin 6 and interleukin 8 as potential biomarkers for oral cavity and oropharyngeal squamous cell carcinoma. *Arch Otolaryngol Head Neck Surg* 130:929–935
23. Chang MC, Wu HL, Lee JJ, Lee PH, Chang HH, Hahn LJ, Lin BR, Chen YJ, Jeng JH (2004) The induction of prostaglandin E2 production, interleukin-6 production, cell cycle arrest, and cytotoxicity in primary oral keratinocytes and KB cancer cells by areca nut ingredients is differentially regulated by MEK/ERK activation. *J Biol Chem* 279:50676–50683
24. Johnson GK, Poore TK, Squier CA, Wertz PW, Reinhardt RA, Vincent SD (1994) Prostaglandin E2 and interleukin 1 levels in smokeless tobacco-induced oral mucosal lesions. *J Periodontol Res* 29:430–438
25. Jablonska E, Piotrowski L, Grabowska Z (1997) Serum levels of IL-1 β , IL-6, TNF- α , TNF-R1 and CRP in patients with oral cavity cancer. *Pathol Oncol Res* 3:126–129
26. Nakano Y, Kobayashi W, Sugai S, Kimura H, Yagihashi S (1999) Expression of tumor necrosis factor- α and interleukin 6 in oral squamous cell carcinoma. *Jpn J Cancer Res* 90:858–866
27. Schafer ZT, Brugge JS (2007) IL-6 involvement in epithelial cancers. *J Clin Invest* 117:3660–3663
28. Hong DS, Angelo LS, Kurzrock R (2007) Interleukin-6 and its receptor in cancer: implications for translational therapeutics. *Cancer* 110:1911–1928
29. Sansone P, Storci G, Tavoroli S, Guarnieri T, Giovannini C, Taffurelli M, Ceccarelli C, Santini D, Paterini P, Marcu KB, Chieco P, Bonafè M (2007) IL-6 triggers malignant features in mammospheres from human ductal breast carcinoma and normal mammary gland. *J Clin Invest* 117:3988–4002
30. Wu HT, Ko SY, Fong JH, Chang KW, Liu TY, Kao SY (2009) Expression of phosphorylated Akt in oral carcinogenesis and its induction by nicotine and alkaline stimulation. *J Oral Pathol Med* 38:206–213
31. Söland TM, Husvik C, Koppang HS, Boysen M, Sandvik L, Clausen OP, Christoffersen T, Byrne M (2008) A study of phosphorylated ERK1/2 and COX-2 in early stage (T1–T2) oral squamous cell carcinomas. *J Oral Pathol Med* 37:535–542
32. Muraoka K, Shimizu K, Sun X, Zhang YK, Tani T, Hashimoto T, Yagi M, Miyazaki I, Yamamoto K (1997) Hypoxia, but not reoxygenation, induces interleukin 6 gene expression through NF-kappa B activation. *Transplantation* 63:466–470
33. Powis G, Kirkpatrick L (2004) Hypoxia inducible factor-1alpha as a cancer drug target. *Mol Cancer Ther* 3:647–654
34. Niu G, Briggs J, Deng J, Ma Y, Lee H, Kortylewski M, Kujawski M, Kay H, Cress WD, Jove R, Yu H (2008) Signal transducer and activator of transcription 3 is required for hypoxia-inducible factor-1alpha RNA expression in both tumor cells and tumor-associated myeloid cells. *Mol Cancer Res* 6:1099–1105
35. Shirogane T, Fukada T, Muller JM, Shima DT, Hibi M, Hirano T (1999) Synergistic roles for Pim-1 and c-Myc in STAT3-mediated cell cycle progression and antiapoptosis. *Immunity* 11:709–719
36. Hirano T, Ishihara K, Hibi M (2000) Roles of STAT3 in mediating the cell growth, differentiation and survival signals relayed through the IL-6 family of cytokine receptors. *Oncogene* 19:2548–2556
37. Barton BE, Murphy TF, Adem P, Watson RA, Irwin RJ, Huang HF (2001) IL-6 signalling by STAT3 participates in the change from hyperplasia to neoplasia in NRP-152 and NRP-154 rat prostatic epithelial cells. *BMC Cancer* 1:19
38. Grivennikov S, Karin M (2008) Autocrine IL-6 signaling: a key event in tumorigenesis? *Cancer Cell* 13:7–9
39. Gao SP, Mark KG, Leslie K, Pao W, Motoi N, Gerald WL, Travis WD, Bommann W, Veach D, Clarkson B, Bromberg JF (2007) Mutations in the EGFR kinase domain mediate STAT3 activation via IL-6 production in human lung adenocarcinomas. *J Clin Invest* 117:3846–3856
40. Sriuranpong V, Park JI, Amornphimoltham P, Patel V, Nelkin BD, Gutkind JS (2003) Epidermal growth factor receptor-independent constitutive activation of STAT3 in head and neck squamous cell carcinoma is mediated by the autocrine/paracrine stimulation of the interleukin 6/gp130 cytokine system. *Cancer Res* 63:2948–2956
41. Hodge DR, Peng B, Cherry JC, Hurt EM, Fox SD, Kelley JA, Munroe DJ, Farrar WL (2005) Interleukin 6 supports the maintenance of p53 tumor suppressor gene promoter methylation. *Cancer Res* 65:4673–4682
42. Resnitzky D, Tiefenbrun N, Berissi H, Kimchi A (1992) Interferons and interleukin-6 suppress phosphorylation of the retinoblastoma protein in growth-sensitive hematopoietic cells. *Proc Natl Acad Sci U S A* 89:402–406
43. Santhanam U, Ray A, Sehgal PB (1991) Repression of the interleukin 6 gene promoter by p53 and the retinoblastoma susceptibility gene product. *Proc Natl Acad Sci U S A* 88:7605–7609
44. Angelo LS, Talpaz M, Kurzrock R (2002) Autocrine interleukin-6 production in renal cell carcinoma: evidence for the involvement of p53. *Cancer Res* 62:932–940
45. Conze D, Weiss L, Regen PS, Bhushan A, Weaver D, Johnson P, Rincón M (2001) Autocrine production of interleukin 6 causes multidrug resistance in breast cancer cells. *Cancer Res* 61:8851–8858
46. Beklen A, Hukkanen M, Richardson R, Kontinen YT (2008) Immunohistochemical localization of Toll-like receptors 1–10 in periodontitis. *Oral Microbiol Immunol* 23:425–431
47. Hong SH, Ondrey FG, Avis IM, Chen Z, Loukinova E, Cavanaugh PF Jr, Van Waes C, Mulshine JL (2000) Cyclooxygenase regulates human oropharyngeal carcinomas via the proinflammatory cytokine IL-6: a general role for inflammation? *FASEB J* 14:1499–1507
48. Tezal M, Sullivan MA, Reid ME, Marshall JR, Hyland A, Loree T, Lillis C, Hauck L, Wactawski-Wende J, Scannapieco FA (2007) Chronic periodontitis and the risk of tongue cancer. *Arch Otolaryngol Head Neck Surg* 133:450–454
49. Tezal M, Sullivan MA, Hyland A, Marshall JR, Stoler D, Reid ME, Loree TR, Rigual NR, Merzianu M, Hauck L, Lillis C, Wactawski-Wende J, Scannapieco FA (2009) Chronic periodontitis and the incidence of head and neck squamous cell carcinoma. *Cancer Epidemiol Biomarkers Prev* 18:2406–2412
50. Zhang J, Liu Y, Shi J, Larson DF, Watson RR (2002) Side stream cigarette smoke induces dose response in systemic inflammatory cytokine production and oxidative stress. *Exp Biol Med* (Maywood) 227:823–829

51. Erdemir EO, Duran I, Haliloglu S (2004) Effects of smoking on clinical parameters and the gingival crevicular fluid levels of IL-6 and TNF- α in patients with chronic periodontitis. *J Clin Periodontol* 31:99–104
52. Jeng JH, Wang YJ, Chiang BL, Lee PH, Chan CP, Ho YS, Wang TM, Lee JJ, Hahn LJ, Chang MC (2003) Roles of keratinocyte inflammation in oral cancer: regulating the prostaglandin E2, interleukin-6 and TNF-alpha production of oral epithelial cells by areca nut extract and arecoline. *Carcinogenesis* 24:1301–1315
53. Wendell KJ, Stein SH (2001) Regulation of cytokine production in human gingival fibroblasts following treatment with nicotine and lipopolysaccharide. *J Periodontol* 72:1038–1044

Copyright of Clinical Oral Investigations is the property of Springer Science & Business Media B.V. and its content may not be copied or emailed to multiple sites or posted to a listserv without the copyright holder's express written permission. However, users may print, download, or email articles for individual use.