

# Sealing occlusal caries lesions in adults referred for restorative treatment: 2–3 years of follow-up

Azam Bakhshandeh · Vibeke Qvist · Kim R. Ekstrand

Received: 15 October 2010 / Accepted: 14 March 2011 / Published online: 9 April 2011  
© Springer-Verlag 2011

**Abstract** The aim of this study was to assess the possibility to arrest occlusal caries lesions in adults by sealant as well as to assess the presence of radiographic progression, arrest, and regression of the sealed lesions. Seventy-two occlusal caries lesions in 52 adult patients referred to restorative treatment by senior lecturers at School of Dentistry, Copenhagen, Denmark were included. In case the patient had more than one occlusal caries lesion, randomization between sealing and restoration was made; otherwise, the lesion was sealed. In total, 60 resin sealants and 12 composite restorations were made. Follow-up period was 25–38 months (mean=33 months). Data were analyzed using non-parametric statistics including kappa statistics. After 2–3 years, the dropout rate was 15%; two patients did not show up for control and nine previously sealed lesions were restored by the patients' general practitioners. All 12 restorations and 39 of the remaining 49 sealants were well functioning, seven (14%) sealants were repaired/replaced due to failure, and three (6%) sealed lesions were restored due to caries progression ( $p>0.05$ ). The radiographic assessment showed caries progression beneath five (10%) sealants, caries regression beneath one (2%) sealant, and unchanged depth beneath 43 (88%) sealants and all restorations ( $p>0.05$ ). The majority of the referred lesions were successfully arrested by sealants, indicating the possibility for extending the criteria for sealing occlusal caries lesions in adults. However, a longer observation period is needed for final conclusion. Extending the criteria of therapeutic sealing of occlusal caries lesions in adults will lead to increased dental health.

**Keywords** Occlusal caries lesion · Resin sealant · Dentin

## Introduction

Treatment strategies for primary occlusal caries lesions on permanent teeth have generally changed during the past decades from operative treatment towards non-operative strategies [1–6]. This development has occurred primarily due to the concern about saving tooth substance, the increased knowledge about the efficiency of non-operative strategies, and the general decrease in the rate of caries progression [2, 7]. In addition, there is an increased understanding that the long-term prognosis for survival of the carious tooth is critically affected by choosing restorative treatment of the lesion [8]. Caries progression can be arrested through several non-operative methods such as plaque control, by motivation and instruction of the patients in optimal oral hygiene, by fluoride application, and by sealing [5, 6]. The indication for using resin sealants to prevent caries progression on occlusal surfaces in permanent molars and premolars has changed during the last 10–15 years [9]. Previously, occlusal surfaces were sealed preventively. Today, sealants are mostly used therapeutically on indication, attempting to arrest active non-cavitated lesions [10–12]. Previous studies indicate that the caries beneath the sealant do not progress as long as the sealant is intact and tight [13–15]. It has even been stated that number and viability of microorganisms in infected dentin will be highly reduced because of the lacking access to the oral environment [16, 17].

It is worth noticing that great variations in treatment philosophies and strategies of carious lesions exist all around the world, also in Scandinavia. In a survey by Espelid et al., it was found that 70% of the dentists in Scandinavia would not choose restorative treatments until

A. Bakhshandeh (✉) · V. Qvist · K. R. Ekstrand  
Department of Cariology and Endodontics, School of Dentistry,  
Faculty of Health Sciences, University of Copenhagen,  
Nørre Allé 20,  
2200 Copenhagen N, Denmark  
e-mail: azamba@sund.ku.dk

the caries progression led to clinical formation of cavity and/or any radiolucency was seen in the dentin. However, 30% indicated that they might use operative treatment for enamel caries lesions [18]. Accordingly, a recent Danish clinical study on children and adolescents showed that around 25% of the occlusal caries lesions restored were enamel lesions with or without initial cavitation; additionally, 43% of the lesions were restored when lesion progression was limited to the outer one third of dentin [19]. Thus, on one side previous studies indicate that sealing might be an appropriate treatment for occlusal lesions even with dentin penetration, while on the other hand most dentists still prefer to make restorative treatment of such lesions. It is well known that restorations can stop caries progression. The idea of the present study is to examine the possibilities of extending the usage of non-operative treatment strategy in occlusal caries lesions in adults.

Our objectives were:

- to assess whether progression of occlusal caries lesions in the outer and middle third of the dentin in adults referred for restorative treatment may be arrested by sealants.
- to assess the presence of radiographic progression, arrest, and regression of the sealed lesions.

In order to assess the clinical efficacy of sealing occlusal lesions located in the outer and middle third of the dentin, a minor number of restorations are included in the study for comparison.

## Materials and methods

### Sample size

Sample size was based on 5-year follow-up and the following premise: the size of the non-operative, therapeutic sealing group to be five times the size of operative restoration group, an annual failure rate for sealants at 10% and for restorations 1.5%,  $\alpha=5\%$ ,  $1-\beta=80\%$  [20]. Using a formula for testing differences in proportions, a sample size of 58 sealants and 12 restorative treatments at the beginning of the study was needed. Less than 58 patients could satisfy the requirement regarding number of sealed and restored teeth if patients with a restoration also received a sealant. In case of 5% annual dropouts, the sample should consist of 77 sealants and 16 restorations.

### Inclusion and exclusion criteria

Adult patients ( $\geq 18$  years of age) with one or more occlusal lesions in need of restoration were included in the study. The patients were referred by senior teachers at the School of Dentistry to one of the authors (AB), who performed all

baseline assessments and treatments. The lesions were registered to be in need of restorative treatment either clinically and/or radiographically by the referring dentist. The maximum depth of the lesions, radiographically assessed, was limited to the middle third of the dentin. Patients with serious chronic diseases, affecting their caries experience and activity, were not included in the project. Neither should the patient have stimulated or un-stimulated symptoms in the included teeth. Patients were also excluded from the study if the caries lesion was limited to enamel clinically and radiographically, lesions had penetrated to the inner third of the dentin, lesion communicated with the approximal or with a restoration, or the lesion was located at the cusp top.

The study was approved by The Research Ethics Committee for Copenhagen and Frederiksberg municipalities [J.nr. (KF) 03 324580] and The Danish Data Protection Agency (J.nr. 2006-41-7099). Signed informed consent from all patients was obtained before initiating the treatments.

### Baseline assessments

**Clinical** The occlusal surface of teeth referred for the study was professionally cleaned with toothpaste and rotating brushes, and air-dried before assessment of the severity of the caries lesion (Table 1). The patient's caries experience was classified as low, average, and high according to age-related DMFT values (decayed, missed, filled teeth) for Scandinavia [21]. DMFT values outside the upper and lower limits of the 67% confidence interval of the average were classified as high and low caries experience, respectively. The patients' oral hygiene and caries risk was subjectively assessed as being low, average, and high based on amount of plaque, oral hygiene habits, caries experience, eating and drinking habits, regular visit to the dentist and so on (Table 2).

**Radiographic** To obtain multiple intraoral radiographs in the same position over time of the selected lesions, E-speed film was fixed to an alignment made of vinyl polysiloxane bite registration material (Occlufast®; Zenith Dental Aps, Italy) of each patient (and automatically processed Dürr Dental®, XR 24 Nova, Germany; 65 kV, 7.5 mA, exposure time 0.32 s). Assessment of radiographs was made after scanning and digitalizing the conventional radiographs into a computer (Fig. 1). The scoring system is described in Table 1. The six scores ranged from no radiolucency to radiolucency with obvious spread in the inner third of the dentin using modified classification scores by Ekstrand et al. [22].

### Clinical procedures

The lesion was sealed if only one lesion was present in the patient. For patients with more than one occlusal caries

**Table 1** The clinical and radiographic diagnostic criteria used at baseline

Clinical assessment of lesion, modified criteria [18]	
0	No evidence of caries
1	No cavity + shadows
2	Cavitation in enamel ± shadows
3	Cavitation in dentin ± shadows
Radiographic assessment of lesion, modified criteria [22]	
0	No radiolucency or radiolucency confined to the enamel
1	Radiolucency in the enamel up to but not beyond the enamel–dentin junction
2	Radiolucency in the dentin; broken enamel–dentin junction but without obvious spread in the dentin
3	Radiolucency with obvious spread in the outer third of dentin
4	Radiolucency with obvious spread in the middle third of dentin
5	Radiolucency with obvious spread in the inner third of dentin

lesion, randomization between sealing and restorative treatment was made; consequently, one lesion was restored and all the other lesions were sealed.

**Sealing** After clinical and radiographical assessments, the tooth was isolated with rubber dam. The occlusal surface was etched with 38% phosphoric acid for 60 s, rinsed with water spray for 20 s, air-dried, dehydrated twice by 99.6% ethanol, and air-dried. The light curing resin sealant (Delton®; Dentsply, PA, USA) was applied with an applicator, and after 20 s the sealant was light cured for 40 s. Adaptation, occlusion, and articulation were controlled and adjusted after removing the rubber dam.

**Restoration** After excavation of the caries lesion and application of rubber dam, the deepest part of the cavity was lined with a thin layer of calcium hydroxide base material (Dycal Dentin®; Dentsply). The enamel was etched for 30 s and the dentin for 10 s with phosphoric acid 38% followed by water spraying the cavity for 20 s. The cavity was gently dried with air for 5 s without dehydration of dentin. The enamel and dentin were treated with primer (Scotchbond Multi-Purpose Primer®; 3M ESPE, MN, USA) for 10 s and gently air-dried for 5 s followed by application of a thin layer of adhesive (Adper™ Scotchbond™ Multi-Purpose Adhesive®; 3M ESPE) for 10 s. The adhesive was light cured for 10 s. The light curing nanofill composite (Filtek™ Supreme XT Universal Restorative®; 3M ESPE) was inserted into the cavity in sloped layers of maximum

2 mm each and polymerized for 40 s. Adaptation, occlusion, and articulation were controlled and adjusted after removing the rubber dam. Finally, the restoration and 1 mm of the surrounding enamel was re-etched with the phosphoric acid 38% for 10 s, water-sprayed, and air-dried followed by dehydrating the surface twice with ethanol 99.6% and air-drying. The restoration and tooth was covered with a layer of low viscous, non-filled resin (Adper™ Scotchbond™ Multi-Purpose Plus Adhesive® + Catalyst®, 3M ESPE) and after 20 s the resin was light cured for 20 s.

#### Follow-up







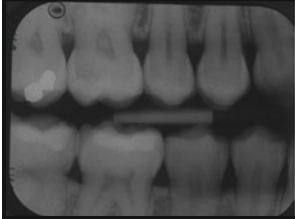

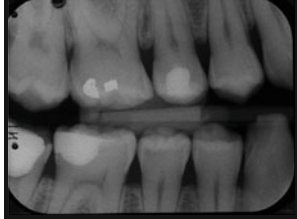
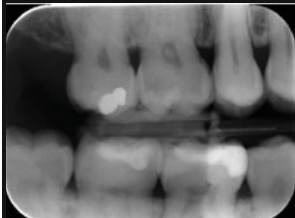
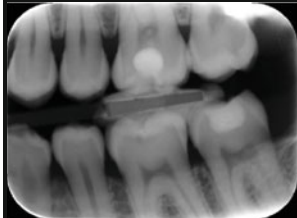

Recall examinations of the treatments were performed with 6–12-month intervals in a period of 25–38 months ( $X=33$  months). While the baseline radiographs were made conventionally, the follow-up radiographs were made by using digital X-ray phosphor plate and scanned into the computer (DIGORA® Optime Classic, Finland), however using the same alignment as used at baseline.

Reading of radiographs was done by scoring the lesion as in progression, unchanged, or in regression. One of the authors (KE) examined and scored paired radiographs from baseline and final follow-up of each treated occlusal lesion. Intra-examiner reproducibility assessment was obtained by re-reading all of the paired radiographs a week after the first reading.

**Table 2** Baseline assessments of 52 patients' caries experience, oral hygiene, and caries risk

Caries experience DMFT	Oral hygiene			Caries risk			No. of patients
	Low	Average	High	Low	Average	High	
Low	3 (1)	14 (4)	8	13 (2)	11 (2)	1 (1)	25
Average	5 (2)	9 (1)	9 (2)	3 (1)	14 (4)	6	23
High	0	2 (1)	2	0	3	1 (1)	4
No. of patients	8	25	19	16	28	8	52

The number of drop-out patients in the categories is enclosed in parentheses

Year	Case I Tooth #16	Case II Tooth #36 & #37		Case III Tooth #45
2007				
				
2010				
				
Tooth no.	#16	#36	#37	#45
Baseline Clinical assessment	Shadow	CE+Shadow	Shadow	CE+Shadow
Baseline Radiographic assessment	1/3–2/3D	<1/3 D	<1/3 D	<1/3 D
Follow-up Clinical assessment	No change	No change	No change	No change
Follow-up Radiographic assessment	No change	No change	No change	No change
Action at Baseline	Sealant	Sealant	Restoration	Sealant
Action at Follow-up	None	None	None	None

CE: Cavity in enamel; D: Dentin

**Fig. 1** Clinical and radiographic examples on three patients with four lesions at baseline and at 3-year follow-up

The clinical and radiographic assessments at the follow-ups are summarized in Table 4. The sealant was re-sealed in cases that the sealant was partly or totally lost, if primary caries on the occlusal surface beside the sealed area was assessed, or in cases with uncertainty or disagreement in whether the lesion was progressed beneath the sealant or not. The sealant was replaced by restoration when there was a progression of the lesion assessed clinically or radiographic. The restoration was replaced in case there was a major failure as secondary caries assessed clinically or radiographic (Fig. 1). Repair or replacements of sealants and restorations were made by the same procedure as baseline. The clinical follow-up examinations were performed by two

of the authors together (AB and VQ). The authors had to be in agreement when comparing the extent of the lesions at baseline and follow-ups.

#### Statistical analysis

PASW (SPSS) 18.0 software for Windows was used for the statistical analyses [23]. Non-parametric statistics including Fisher's exact test, chi-square test, and kappa statistics were used for analyzing the significance of correlation between background variables, need for re-treatments and intra-examiner agreement in the radiographic assessments. Differences between sealants and restorations in the 12

patients with more than one lesion were analyzed by McNemar change test [24]. The significance level was set at 5% ( $p < 0.05$ ).

## Results

During the recruiting period of 10 months, 52 referred patients (26 men; 26 women) aged 21–68 years (mean=28 years) with 72 occlusal caries lesions in five premolars and 67 molars (38 in the upper jaw; 34 in the lower jaw) were included in the study. Further, 14 referred patients had to be excluded from the study according to the exclusion criteria. Overall, 39 of the 52 included patients had one occlusal lesion; eight patients had two lesions; three patients had three lesions; and two patients had four lesions.

The decision making of the treatment was based on clinical assessment only in 40 cases, clinical and radiographic assessment in 31 cases, and radiographic appearance only in one lesion. Nearly half of the 52 patients were assessed to have average caries experience (44%), oral hygiene (48%), and caries risk (54%) (Table 2). Caries risk assessment was slightly higher in patients with more than one lesion included, while no differences were found in oral hygiene and previous caries experience compared to patients with a single lesion.

A total of 16 lesions (22%) were assessed to be with shadows but no cavitations; 47 lesions (65%) were clinically scored to have cavitation in enamel with or without shadows, and nine lesions showed cavitation in dentin with or without shadows (13%) (Table 3). Furthermore, 15 (21%) lesions were radiographically assessed to be in the middle third of dentin, 48 (67%) lesions were in the outer third of dentin, eight (11%) lesions were progressed to the enamel–dentin junction, and one (1%) lesion was in enamel, exclusively (Table 3).

**Table 3** The clinical and radiographic assessments of the lesions at baseline

Radiographic assessment	Clinical assessment			Total
	No cavity + shadow	CE ± shadow	CD ± shadow	
Caries in enamel	1		1	
Caries at EDJ	2	6 (1)		8
Caries ≤1/3 D	11 (1)	32 (2)	5 (1)	48
Caries 1/3–2/3 D	3 (1)	8 (3)	4 (2)	15
Total	16	47	9	72

The number of drop-out patients in the categories is enclosed in parentheses

CE cavity in enamel, CD cavity in dentin, EDJ enamel–dentin junction, D dentin

A total of 32 lesions were sealed locally (53%) and 28 lesions were sealed over the total fissure system (47%) because of extended lesions or presence of more than one lesion on the occlusal surface.

After 2–3 years, the dropout rate was 15%; two patients did not show up for the follow-up, and nine sealants in nine patients were restored by the patients' general practitioners, and data on clinical and radiographic appearance of the lesions prior to restorative treatment were missing.

As shown in Table 4, all 12 restorations and 39 (80%) of the remaining 49 sealants were still well functioning, giving an annual failure rate of 0% for restorations and 7.4% (CI, 0.08–14.7%) for sealants. Seven sealants (14%) in seven patients were repaired or replaced and three sealants (6%) in three patients were replaced by restorations, one after 4 months, another after 11 and yet another after 13 months. The extent and location of the sealant did not influence the frequency of re-treatments: 14% of the 29 locally sealed teeth and 30% of the 20 totally sealed teeth ( $p=0.31$ ); 12% of the 26 upper jaw teeth and 24% of the 29 lower jaw teeth ( $p=0.23$ ); 0% of the five premolars; 14% of the 22 first molars, 25% of the 20 second molars, and 40% of the five third molars were re-treated ( $p=0.33$ ). No association was found between the need for re-treatment of sealants and patients' oral hygiene level ( $p=0.79$ ), previous caries experience ( $p=0.67$ ), or estimated caries risk ( $p=0.80$ ). No significant difference was found concerning the need for re-treatments of sealants and restorations in the 12 patients with both types of treatments ( $p=0.25$ ), and only one of these patients received two re-treatments of sealants; one by the patient's general practitioner and one by AB.

















Caries progression, judged radiographically, occurred beneath five (10%) of the 49 controlled sealants but none of the 12 restorations. Caries regression was recorded beneath one (2%) of the sealed lesions, and unchanged depth beneath 43 (88%) sealants. Tertiary dentin formation was observed in nine (18%) sealants and one (8%) restoration. Concerning the radiographic assessment of lesion changes, the intra-examiner kappa was calculated to 0.75. The intra-examiner kappa for tertiary dentin formation was 0.68.

## Discussion

Most of the previous studies on the efficacy/effectiveness of sealants to prevent or arrest occlusal caries have been conducted in populations of children and adolescents [9, 25–27], while the knowledge on the effect of sealants in the permanent dentition of adults is sporadic. A few clinical studies indicate that sealants placed on fissure caries can prevent the caries progression in adults as well as in children and adolescents, but there are limitations with these studies, e.g., short evaluations



**Table 4** The clinical and radiographic diagnostic criteria used at the control examination of 72 occlusal lesions (the numbers in each group are indicated in parentheses)

	Clinical assessment	Radiographic assessment	Action
<b>SEALANTS (n=60)</b>	Full retention (40) 	Regression (1)  Unchanged (36)  Progression (3) 	None (39) Repair or replacement Restoration (1)
	Partly retention (2) 	Regression Unchanged (2)  Progression	None Repair or replacement (2) Restoration
	Lost retention (7) 	Regression Unchanged (5)  Progression (2) 	None Repair or replacement (5) Restoration (2)
	Unavailable for control: (11) 		Not controlled (2) Restoration (9) <sup>a</sup>
<b>RESTORATIONS (n=12)</b>	Optimal (11) 	i.a. (11) 	None (11)
	Acceptable (1) 	i.a. (1)   Progression beneath restoration (0)	None (1) Observation Preventive measurement Repair or replacement  Repair or replacement
	Unacceptable (0) 	i.a. (0)  Progression beneath restoration (0)	None Observation Preventive measurement Repair or replacement  Repair or replacement

<sup>a</sup> Nine sealed lesions were restored by the patients' general practitioner

periods, unclear caries status of the fissures at baseline, or large dropout frequencies [28, 29]. This led us to conducting this study.

In the very first planning of the study, the authors aimed to recruit only patients who had at least two occlusal lesions well into the dentin, allowing a paired design, where one tooth

would be restored and one sealed. However, during the 10-month recruitment period, we realized that very few adult patients fulfilled this inclusion criterion, and that it was difficult to reach the calculated number of patients for optimal comparison of the two treatments. As the main focus in this study was to verify the possibility for extending the use of non-operative sealant treatment, and several previous studies have dealt with the clinical quality and longevity of occlusal resin restorations in adults [30], we decided that patients with a single lesion also could be included and that randomization between sealing and restoration only should be made if more than one lesion was found in the same patient. In order to standardize the treatments, all sealants and restorations were made by one of the authors (AB); however, re-examinations were performed by two authors (AB/VQ), and in case of disagreement, consensus was achieved.

The criteria used for restorative dentistry have changed in Denmark and other Scandinavian countries. Restorative treatment is chosen when the non-operative treatment strategies are not sufficient to arrest the caries progression. The enamel integrity is one important sign for the decision making in performing the operative intervention due to the close relationship between cavity formation and bacterial invasion of the demineralized dentin part of the lesion [31, 32]. However, cavity formation with exposed dentin does not make it mandatory to restore the lesion automatically. Disparities among the referring senior lectures in indication of lesions in need of restorations were observable in this study. Of the 72 lesions referred to the study, 78% had cavitations with or without shadows (Table 3); 56% of the lesions were decided to be in need of restoration clinically and 43% both clinically and radiographically. These findings are consistent with recent results from the Danish Public Health Service which showed that 66% of 1591 occlusal caries lesions were assessed to be in need of restoration by clinical appearance exclusively and 27% by clinical and radiographic appearance [19].

The annual failure rate for resin sealants placed on initial active enamel lesions is shown to be 0–10%. A number of studies have shown that 85% of the sealants remain completely intact after 1 year and at least 50% after 5 years; however, the inclusion criteria vary in these studies and only non-cavitated lesions were sealed [33, 34]. In the present study, the annual failure rate for resin sealants was 7.4%. The high frequency of lesions with cavitation is of clinical importance for the failure rate because the penetration of sealant can be hampered due to the irregular shapes of the cavitated fissures leading to loss of the sealant. The presence of the biofilm/dental plaque that might be left in the deeper parts of the cavity might reduce the adaptation of the sealants as well [35]. Previous studies have further shown that demineralized and cavitated surfaces may decrease sealant longevity because microleakage occurs more frequently

around sealed carious lesions than sealed sound surfaces as the irregular shapes of the cavitated lesions might disturb the penetration of the sealant in the carious fissure [36]. In the present study, most of the re-treatments were performed in case of the totally sealed fissures which often presented more than one lesion on the surface. Furthermore, as shown in another study, the more posterior teeth were placed, the higher was the rate of re-treatment, i.e., re-treatments were more frequent on second molars than first molars [37].

It is unfortunate that, in this study, 21 sealants (36%) were repaired or replaced by sealant or restoration due to partial, total loss of sealant or radiographic progression of the lesion after an average of 33 months. However, nine of the sealed lesions were restored by the patients' general practitioners with lacking data on the clinical and radiographic appearance of the lesions at the time of re-treatment. These results confirm that the included lesions in this study were in need of restorations in the general practitioner's current world. It is notable that there are no systematic differences between distributions of patients and lesions in the dropout group and the total material (Tables 2 and 3).

Comparisons of the depth of the lesions at baseline and the depth of the restorations (at the final radiograph) further indicated unchanged depth in four cases and progression in five lesions. The extended depth of the restorations may not be caused of caries progression as restorations are often extended beyond the caries lesions. However, when including the nine dropout patients, the caries progression beneath sealants would increase from 10% (5/49) to 17% (10/58).

The longevity of the restorations in the permanent dentition is affected by factors such as the size of the cavity, the type of the materials, the used technique, age of the patient, oral hygiene and caries activity, caries experience, etc. [8]. Replacement of posterior resin restorations is made mostly due to secondary caries and fracture of restorations or tooth and pulpal complication [30, 38]. The annual failure rate for posterior resin restorations in permanent dentition varies between 0 and 8.7% with a median annual failure of 2% [8]. A 5-year follow-up study showed that the survival time for occlusal restoration is better than for approximal restorations in posterior teeth [39]. However, due to the small number, it is not surprising that all 12 restorations in this study were both clinically and radiographically scored as optimal during the follow-up period.

In the present study, different radiographic systems unfortunately had to be used at baseline and follow-ups as the conventional films were not available at the follow-ups due to digitalization of the radiographic system at the University. However, the accuracy of digital radiograph assessment has improved over time due to increased familiarity of dentists with the new technology and the majority of studies on the current digital intra-oral radiography systems have shown that they are as accurate

as conventional films for the detection of caries [40, 41]. Furthermore, the brightness and contrast were adjusted to a more satisfying image in the present study, and the tooth of interest was isolated by cutting away the surrounding tissue, thus only the tooth of interest was visible to scoring.

Non-compliant patients who do not show up during the follow-up examinations are of concern when extending the criteria for non-operative intervention of caries lesions. However, in the present study, all dropout patients were examined by the patients' general practitioners.

## Conclusions

The results from the present study suggest that in adults, occlusal caries lesions in need of restorative treatments according to current treatment strategies can be arrested clinically and radiographically by sealing the lesions with resin sealant even in case of lesions with penetration into the dentin. Accordingly, conventional excavation and restoring of occlusal lesions can be postponed as long as the sealant is intact and tight. Individualized and regular clinical and radiographic examination is necessary to ensure that the sealant is sufficient and evaluate the lesion extension during the observation period. It may be necessary to restore the sealed lesion in future; nevertheless, the prognosis for the individual tooth will be increased due to postponing the restorative treatment. Long-term observation is needed for generalizing the results from this study.

## Clinical relevance

Once a permanent tooth has been restored, the filling is likely to be replaced several times in the patient's life, and repeated replacements of restorations may compromise the survival of the tooth. The results from the present study indicate the possibility of arresting progression of occlusal caries lesions by non-operative sealing instead of restorations. Extending the criteria of non-operative sealing of occlusal caries lesions in the permanent dentition will lead to increased dental health.

**Acknowledgments** The authors wish to thank Professor Svante Twetman for valuable contribution to this study and The Danish Dental Association for the financial support of the study. Dentsply DeTrey and 3M ESPE in Denmark are gratefully acknowledged for the sponsored material used in this study.

**Conflict of interest** The authors declare that they have no conflict of interest.

## References

- Mejare I, Kallestål C, Stenlund H, Johansson H (1998) Caries development from 11 to 22 years of age: a prospective radiographic study. Prevalence and distribution. *Caries Res* 32:10–16
- Mejare I, Sundberg H, Espelid I, Tveit B (1999) Caries assessment and restorative treatment thresholds reported by Swedish dentists. *Acta Odontol Scand* 57:149–154
- Pitts NB (2004) Are we ready to move from operative to non-operative/preventive treatment of dental caries in clinical practice? *Caries Res* 38:294–304
- Ekstrand KR, Christiansen ME (2005) Outcomes of a non-operative caries treatment programme for children and adolescents. *Caries Res* 39:455–467
- Carvalho JC, Ekstrand KR, Thylstrup A (1991) Results after 1 year of non-operative occlusal caries treatment of erupting permanent first molars. *Community Dent Oral Epidemiol* 19:23–28
- Carvalho JC, Thylstrup A, Ekstrand KR (1992) Results after 3 years of non-operative occlusal caries treatment of erupting permanent first molars. *Community Dent Oral Epidemiol* 20:187–192
- Mejare I, Stenlund H (2000) Caries rates for the mesial surface of the first permanent molar and the distal surface of the second primary molar from 6 to 12 years of age in Sweden. *Caries Res* 34:454–461
- Qvist V (2008) Longevity of restorations: the "death spiral". In: Fejerskov O, Kidd E (eds) *Dental caries. The disease and its clinical management*, 2nd edn. Blackwell, Oxford, pp 443–456
- Ahovuo-Saloranta A, Hiiri A, Nordblad A et al. (2009) Pit and fissure sealants for preventing dental decay in the permanent teeth of children and adolescents. *Cochrane Database Syst Rev* (4): CD001830 (Review)
- Gore DR (2009) The use of dental sealants in adults: a long-neglected preventive measure. *Int J Dent Hyg* 8:198–203
- Beauchamp J, Caufield PW, Crall JJ, Donly KJ, Feigal R, Gooch B et al (2009) Evidence-based clinical recommendations for the use of pit-and-fissure sealants: a report of the American Dental Association Council on Scientific Affairs. *Dent Clin North Am* 53:131–147
- Hiiri A, Ahovuo-Saloranta A, Nordblad A et al. (2010) Pit and fissure sealants versus fluoride varnishes for preventing dental decay in children and adolescents. *Cochrane Database Syst Rev* (3):CD003067
- Handelman SL, Leverett DH, Solomon ES, Brenner CM (1981) Use of adhesive sealants over occlusal carious lesions: radiographic evaluation. *Community Dent Oral Epidemiol* 9:256–259
- Handelman SL (1982) Effect of sealant placement on occlusal caries progression. *Clin Prev Dent* 4:11–16
- Mertz-Fairhurst EJ, Curtis JW Jr, Ergle JW, Rueggeberg FA, Adair SM (1998) Ultraconservative and cariostatic sealed restorations: results at year 10. *J Am Dent Assoc* 129:55–66
- Handelman SL, Washburn F, Woppper P (1976) Two-year report of sealant effect on bacteria in dental caries. *J Am Dent Assoc* 93:967–970
- Weerheijm KL, de Soet JJ, van Amerongen WE, de Graaff J (1992) Sealing of occlusal hidden caries lesions: an alternative for curative treatment? *ASDC J Dent Child* 59:263–268
- Espelid I, Tveit AB, Mejare I, Sundberg H, Hallonsten AL (2001) Restorative treatment decisions on occlusal caries in Scandinavia. *Acta Odontol Scand* 59:21–27
- Qvist V (2009) Quality and longevity of posterior restorations in permanent teeth of adolescents. The 22nd Congress of the International Association of Pediatric Dentistry, Abstract ID: 015-4
- Petrie A, Sabine C (2009) *Medical statistics at a glance*, 3rd edn. Wiley-Blackwell, Oxford
- Brattall D, Hänsel Peterson G, Stjernswärd JR (2004) Cariogram, Internet version 2.01. Available at <http://www.db.od.mah.se/cariogram/cariograminfo.html>



22. Ekstrand KR, Ricketts DN, Kidd EA (1997) Reproducibility and accuracy of three methods for assessment of demineralization depth of the occlusal surface: an in vitro examination. *Caries Res* 31:224–231
23. SPSS Statistical Analysis Software Program (2009). PASW Statistic 18
24. Seigel S, Castellan JR NJ (eds) (1988) Nonparametric statistics for the behavioral sciences, 2nd edn. McGraw-Hill, Singapore, pp 75–80
25. Mejare I, Lingstrom P, Petersson LG, Holm AK, Twetman S, Kallestal C et al (2003) Caries-preventive effect of fissure sealants: a systematic review. *Acta Odontol Scand* 61:321–330
26. Azarpazhooh A, Main PA (2008) Pit and fissure sealants in the prevention of dental caries in children and adolescents: a systematic review. *J Can Dent Assoc* 74:171–177
27. Splieth CH, Ekstrand KR, Alkilzy M, Clarkson J, Meyer-Lueckel H, Martignon S et al (2010) Sealants in dentistry: outcomes of the ORCA Saturday Afternoon Symposium 2007. *Caries Res* 44:3–13
28. Mertz-Fairhurst EJ, Schuster GS, Fairhurst CW (1986) Arresting caries by sealants: results of a clinical study. *J Am Dent Assoc* 112:194–197
29. Handelman SL, Leverett DH, Espeland M, Curzon J (1987) Retention of sealants over carious and sound tooth surfaces. *Community Dent Oral Epidemiol* 15:1–5
30. Qvist V, Qvist J, Mjor IA (1990) Placement and longevity of tooth-colored restorations in Denmark. *Acta Odontol Scand* 48:305–311
31. Thylstrup A, Qvist V (1987) Principal enamel and dentin reactions during caries progression. In: Thylstrup A, Leach SA, Qvist V (eds) *Dentine and dentine reactions in oral cavity*. IRL, Oxford, pp 3–16
32. Ekstrand KR, Martignon S, Ricketts DJ, Qvist V (2007) Detection and activity assessment of primary coronal caries lesions: a methodologic study. *Oper Dent* 32:225–235
33. National Institute of Health (1984) National Institutes of Health Consensus Development Conference statement on dental sealants in prevention of tooth decay. *J Am Dent Assoc* 108:233–236
34. Benteke M, Berntsson L, Broman U, Edfeldt K, Skold-Larsson K, Twetman S (2006) Population- vs. risk-based applications of fissure sealants in first permanent molars: a 13-year follow-up. *Oral Health Prev Dent* 4:151–156
35. Fejerskov O, Kidd EA (2008) Dental caries. The disease and its clinical management, 2nd edn. Blackwell Munksgaard, Oxford
36. Hevinga MA, Opdam NJ, Frencken JE, Bronkhorst EM, Truin GJ (2008) Can caries fissures be sealed as adequately as sound fissures? *J Dent Res* 87:495–498
37. Poulsen S, Laurberg L, Vaeth M, Jensen U, Haubek D (2006) A field trial of resin-based and glass-ionomer fissure sealants: clinical and radiographic assessment of caries. *Community Dent Oral Epidemiol* 34:36–40
38. Mjor IA, Moorhead JE, Dahl JE (2000) Reasons for replacement of restorations in permanent teeth in general dental practice. *Int Dent J* 50:361–366
39. Opdam NJ, Loomans BA, Roeters FJ, Bronkhorst EM (2004) Five-year clinical performance of posterior resin composite restorations placed by dental students. *J Dent* 32:379–383
40. Wenzel A (2000) Digital imaging for dental caries. *Dent Clin North Am* 44:319–338
41. Wenzel A (2004) Bitewing and digital bitewing radiography for detection of caries lesions. *J Dent Res* 83(Spec No C):C72–C75

Copyright of Clinical Oral Investigations is the property of Springer Science & Business Media B.V. and its content may not be copied or emailed to multiple sites or posted to a listserv without the copyright holder's express written permission. However, users may print, download, or email articles for individual use.