

Correlation between maxillofacial radiographic features and systemic severity as sickle cell disease severity predictor

Frederico Sampaio Neves · Cristina Pinho Passos · Christiano Oliveira-Santos ·
Maria Cristina Teixeira Cangussu · Paulo Sérgio Flores Campos ·
Roberto José Meyer Nascimento · Iêda Crusoé-Rebello ·
Maria Isabela Guimarães Campos

Received: 9 February 2011 / Accepted: 26 May 2011 / Published online: 7 June 2011
© Springer-Verlag 2011

Abstract This study was conducted to investigate the relationship among radiographic features observed on panoramic radiographs of sickle cell disease patients and analyze their relationship with history of systemic severity of the disease. Panoramic radiographs of 71 subjects with sickle cell disease were evaluated for the presence of the following radiographic bony alterations: radiopaque areas, increased spacing of bony trabeculae, horizontal arrangement of bony trabeculae and corticalization of mandibular canal. History of clinical systemic severity was assessed through direct questioning about the frequency of vaso-occlusive crisis, history of stroke, clinical jaundice, femur head necrosis, and leg ulceration. Chi-square or Fisher's exact test were applied in order to analyze possible associations between radiographic features and history of complications, with $p < 0.05$ significance level. Increased spacing of bony trabeculae was statistically associated with absence of corticalization of mandibular canal ($p < 0.01$) and horizontal arrangement of

bony trabeculae ($p = 0.04$). Statistically significant associations were demonstrated between history of clinical jaundice and presence of increased spacing of bony trabeculae ($p = 0.02$) and between history of stroke and presence of horizontal arrangement of bony trabeculae ($p = 0.04$). Based on the results of the current study, maxillofacial radiographic features may be associated with clinical parameters of systemic complications in sickle cell disease patients. The relationship between radiographic features and history of complications associated with clinical severity of sickle cell disease has not been demonstrated in the literature. Acknowledgment of such possible association may help establish prognosis and influence clinical treatment of systemic and oral complications.

Keywords Sickle cell anemia · Trabecular pattern · Sickle cell disease · Systemic complications · Radiographic features

F. S. Neves
Department of Oral Diagnosis, Division of Oral Radiology,
Piracicaba Dental School, University of Campinas,
Piracicaba, São Paulo, Brazil

C. P. Passos
Graduate Program of Interactive Processes of Organs and
Systems, Institute of Health Science, Federal University of Bahia,
Salvador, Bahia, Brazil

C. Oliveira-Santos
Department of Stomatology, Bauru Dental School,
University of São Paulo,
Bauru, São Paulo, Brazil

M. C. T. Cangussu
Department of Social Dentistry and Pediatrics,
School of Dentistry, Federal University of Bahia,
Salvador, Bahia, Brazil

P. S. F. Campos · I. Crusoé-Rebello
Department of Oral and Maxillofacial Radiology,
School of Dentistry, Federal University of Bahia,
Salvador, Bahia, Brazil

R. J. M. Nascimento
Department of Biointeraction, Institute of Health Science,
Federal University of Bahia,
Salvador, Bahia, Brazil

M. I. G. Campos
Department of Biomorphology, Institute of Health Science,
Federal University of Bahia,
Salvador, Bahia, Brazil

M. I. G. Campos (✉)
Departamento de Biomorfologia, Instituto de Ciências da Saúde,
Av. Reitor Miguel Calmon, s/nº, Vale do Canela,
CEP 40.110-902, Salvador, Bahia, Brazil
e-mail: misabela@ufba.br

Introduction

Sickle cell disease (SCD) is a genetic hematologic disorder in which the polymerization of abnormal hemoglobin (HbS) leads to morphologic alterations in erythrocytes. Sickle cell anemia (SCA), the most common and severe form of SCD, is characterized by homozygosis for HbS (HbSS genotype) [1]. The SC disease (HbSC genotype) is a milder clinic presentation of SCD, in which abnormal HbC induces erythrocyte dehydration, facilitating HbS polymerization [2].

Sickle erythrocytes show less flexibility and higher adherence to endothelium, causing vaso-occlusion in the microcirculation that can result in tissue ischemia and infarction [3]. Premature destruction of altered red blood cells leads to a chronic hemolytic anemia [4]. SCD exhibits a wide range of severity in systemic manifestations that include pulmonary hypertension, priapism, leg ulceration, stroke, vaso-occlusive pain crisis (VOC), acute chest syndrome and osteonecrosis [5].

SCD is an important cause of osteonecrosis mainly affecting hips, shoulders and knee [6]. Symptomatic patients complain of painful and limited motion of the affected joint. Magnetic resonance imaging (MRI) is appropriate for the early diagnosis, while advanced disease may be diagnosed with plain radiographs, which show mottled attenuation of the epiphysis, subchondral lucent areas and flattening or collapse of the articular surfaces [7, 8]. This may be followed by narrowing of the joint space, articular sclerosis and osteophyte formation [9]. Avascular necrosis of the mandibular condyle was also reported with similar radiographic features [10, 11]. MRI confirms that chronic anaemia, including SCA, may cause bone marrow alterations that may be associated with the progression to osteonecrosis of the mandibular condyle [12]. Abnormal skull radiographic findings in sickle cell anaemia include widening of the diploic space, thinning of the outer table, vertical trabeculation (hair-on-end sign) and granular appearance of the skull [13].

Considering the maxillofacial area, radiographic features frequently associated with SCD patients have been reported, such as increase radiolucency of the jaws due to the decreased number of trabeculae, coarse trabeculae pattern, thin inferior border of mandible, distinct areas of radiopacity, stepladder appearance created in the interdental alveolar bone by horizontal rows of trabeculation and osteomyelitis [4, 14–22]. Few studies have analyzed their prevalence among SCD patient and healthy controls [23–30]. However, to the best of our knowledge, relationship between the presence of radiographic features and history of complications associated with clinical severity of SCD has not been demonstrated. Acknowledgment of such possible association may help establish prognosis

and influence clinical treatment of systemic and oral complications.

The aims of this study were to investigate the relationship among radiographic features observed on panoramic radiographs of SCD patients and analyze their relationship with history of systemic severity of the disease.

Materials and methods

The current study was approved by the Research Ethics Committee of the School of Dentistry—Federal University of Bahia, and all volunteers signed free informed consent terms.

Seventy-one Brazilian subjects with SCD (36 HbSS and 35 HbSC subjects) took part in this study. All subjects had their hemoglobin condition diagnosed by electrophoresis examination through high performance liquid chromatography (HPLC) method. Presence of other systemic diseases or use of medications that could affect bone metabolism were considered as exclusion criteria.

Volunteers were screened from the Laboratory of Genetics of Professor Edgar Santos University Hospital, the Foundation of Hematology and Hemotherapy of Bahia or the Laboratory of Specialized Analysis in Hematology of School of Pharmacy of Federal University of Bahia. They were asked to attend the School of Dentistry of Federal University of Bahia, where panoramic radiographs were taken complementary examinations to their dental treatment.

All panoramic radiographs were obtained using the Rotograph Plus® machine (Vila Sistemi Medicali, Buccinasco, Italy), operating in the following conditions: 60–75 kV, 10 mA, exposure time of 15 s. After the radiographic exposure, films were processed manually, following the manufacturer's recommendations, with new and fresh chemical solutions (Kodak-Pathé, Paris, France). The radiographs were digitized with a scanner device with a transparency reader (HP Scanjet 4890 Photo Scanner) and exported in TIFF format, without data compression. Images with acceptable technical quality, allowing good visualization of radiographic features assessed were included in the study. An oral and maxillofacial radiologist, who had more than 15 years of experience, evaluated the images with Image J software version 1.34 s (National Institutes of Health, Bethesda, MD) on a computer (21-in LCD monitor with 1,280×1,024 resolution) under dim light conditions and without prior knowledge of hematological diagnosis, age or gender of subjects. Task specific filters, “zoom” tool or any image enhancement were not applied. Images were re-evaluated after a 4-month interval and intra-observer agreement was calculated, demonstrating high reproducibility (kappa index=0.81).

The radiographic parameters evaluated were based on previously reported features commonly associated with SCD [28, 29] and β -thalassaemia major [31], categorized as follows:

1. Radiopaque areas in jaw bones: homogeneous and well-defined radiopaque areas, located on the course of blood vessels or on apical region of teeth (Fig. 1a).
2. Increased spacing of bony trabeculae: decreased trabecular bone density and enlarged and locular bone marrow spaces (Fig. 1b).
3. Horizontal arrangement of bony trabeculae: trabecular bone in a horizontal pattern, in a “stepladder” aspect (Fig. 1c).
4. Absence of mandibular canal corticalization: Inferior and superior radiopaque lines of mandibular canal were not clearly seen (Fig. 1d).

History of clinical systemic severity was assessed through direct questioning regarding history of potential complications associated with SCD, such as: frequency of vaso-occlusive crisis (without episodes or more than 3 years in steady state, once or twice a year and more than twice a month), history of stroke, clinical jaundice, femur head necrosis and leg ulceration.

Chi-square or Fisher's exact test with $p < 0.05$ significance level were applied in order to analyze possible associations between radiographic features and history of clinical parameters of disease severity.

Results

The studied group consisted of 44 female (62%) and 27 males (38%). Significant statistical difference was observed

according to gender ($p = 0.04$). The mean age was 34.4 (± 11.3), ranging between 18 and 61 years. Radiopaque areas (42%) and increased spacing of bony trabeculae (41%) were the most common features, followed by absence of mandibular canal corticalization (34%) and horizontal arrangement of bony trabeculae (23%).

Increased spacing of bony trabeculae demonstrated statistically significant association with the absence of mandibular canal corticalization and horizontal arrangement of bony trabeculae, but association was not demonstrated when the presence of radiopaque areas was analyzed. These data are shown in Table 1.

Association between history of clinical severity and radiographic features are presented in Table 2. Statistically significant associations were demonstrated only between history of jaundice and presence of increased spacing of bony trabeculae ($p = 0.02$) and between history of stroke and presence of horizontal arrangement of bony trabeculae ($p = 0.04$).

Discussion

Although increased spacing of bony trabeculae is not considered a pathognomonic sign of SCD [14, 23, 25], this radiographic feature has been frequently described in sickle subjects [4, 19, 22–24, 32], and may produce bony expansion of maxilla, increased overjet and spacing of maxillary incisors [16].

In a previous study, evaluation of intraoral radiographs of 16 SCA children under 10 years of age demonstrated occurrence of increased radiolucency of bone and a coarse trabecular pattern in 100% of the sample, while none of the

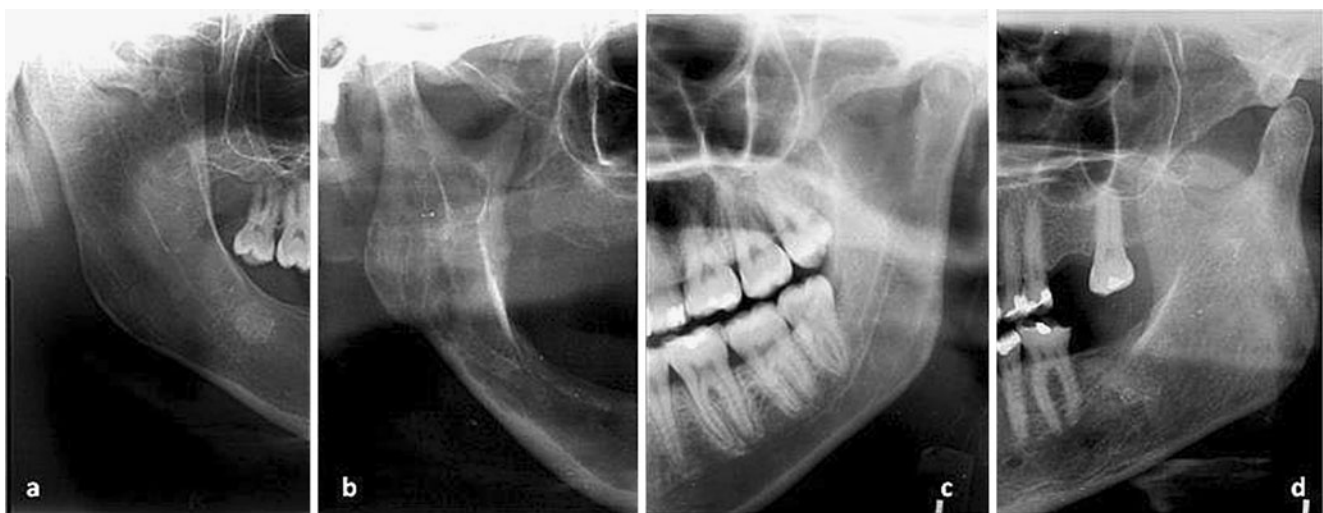


Fig. 1 Cropped panoramic radiographs displaying radiographic features observed in sickle cell disease patients: **a.** Radiopaque areas in jaw bones. **b.** Increased trabecular bone spacing. **c.** Significant

horizontal arrangement of bony trabeculae. **d.** Absence of mandibular canal corticalization

Table 1 Statistical analysis between increased trabecular spacing and other radiographic features

	No increased spacing of bony trabeculae <i>n</i> =42 (%)	Increased spacing of bony trabeculae <i>n</i> =29 (%)	<i>p</i>
Radiopaque areas	14 (33.3)	15 (51.7)	0.18
Absence of mandibular canal corticalization	12 (28.6)	17 (58.6)	<0.001*
Horizontal arrangement of bony trabeculae	19 (45.2)	10 (34.5)	0.04*

*Statistical significant value

healthy controls presented bony changes [24]. The same radiographic features were observed in 85% of 80 SCD individuals (5–40 years), with lower occurrence (50%) in younger children (5–10 years) and higher (100%) in adolescents (17–21 years) [23]. Visual examination of panoramic and periapical radiographs showed decreased trabecular bone density in 66.7% of SCA patients (16–40 years) and in none of healthy control subjects [28].

In anterior area of jaws, Fourier and strut analysis of periapical radiographs revealed increased trabecular spacing in SCA patients when compared to control individuals [26, 27]. Fractal analysis of panoramic radiographs revealed a scarcity of trabecular bone of posterior mandible in HbSS subjects under 20 years old and a high variability of fractal dimension among SCD subjects when compared to healthy control individuals. It was suggested that radiographic differences among SCD patients could be influenced by disease severity [30]. Furthermore, younger SCD individuals may present significant bony changes when compared to adults because of their lower adaption to the disease, higher incidence of crises and higher amounts of red bone marrow [24].

Increased spacing of bony trabeculae was also a frequent finding in the present study (41%). This feature was statistically associated with absence of mandibular canal corticalization ($p<0.01$) and horizontal arrangement of bony trabeculae ($p=0.04$), pointing to a possible similar etiology. In SCD patients, premature destruction of erythrocytes and chronic anemia result in increased erythropoiesis, causing a compensatory marrow hyperplasia and thinning of bony trabeculae [22]. Consequently, enlarged bone marrow spaces are noted, usually as radiolucent areas between apices of posterior teeth and inferior margin of the mandible [19].

According to Mourshed and Tuckson [23], increased spacing of bone trabeculae is not a specific sign of SCD. In fact, decrease in bone density may be related to many different conditions, including loss of teeth, which was not evaluated in the present study. However, studies have demonstrated that although such feature may be also found in healthy patients or in other systemic conditions, occurrence of increased spacing of bone trabeculae is significantly more common among SCD patients; thus, it

may be considered a strong indication of the disease [26–28, 30, 33].

A horizontal trabecular pattern creating “stepladder” effect between the roots of mandibular molars is frequently described for SCD patients, mainly in periapical radiographs [19, 21, 23, 32]. Sixteen patients (22.5%) presented this radiographic feature. Frequencies vary among studies, ranging from 27.8% to 70% of patients [23, 25, 28]. Different age groups evaluated among studies could account for the observed divergences in the occurrence of this feature. Moreover, in the current study, additional evaluation using periapical radiographs could reveal the incidence of this radiographic feature with more accuracy.

Bone resorption with enlargement of the marrow spaces may impair the visualization of two parallel radiopaque lines adjacent to teeth roots corresponding to the mandibular canal. Although less frequently reported in SCD and in other hereditary hemolytic anemias, such as β -thalassemia major [31], impaired visualization of the mandibular canal is a relevant feature to be considered prior to surgical intervention in posterior mandible in order to avoid injury to the inferior dental nerve.

In the present study, SCD patients with increased spacing of bony trabeculae were significantly associated with history of clinical jaundice ($p=0.02$). In SCD, jaundiced skin and eyes frequently result from hemolytic process due to release of bilirubin during hemoglobin degradation, commonly associated with hepatic dysfunction [34, 35]. Since clinical jaundice can be a direct consequence of hemolysis, it is reasonable to assume that these individuals develop bone marrow hyperplasia observed in radiographs as increased spacing of bony trabeculae.

Two distinct subphenotypes are suggested for clinical systemic complications of SCD. A vasculopathy subphenotype related to hemolysis comprises pulmonary hypertension, priapism, leg ulceration and stroke, while a viscosity-vaso-occlusive subphenotype involves vaso-occlusive pain crisis, acute chest syndrome and osteonecrosis [5]. Despite the small number of evaluated patients, SCD individuals with horizontal arrangement of bony trabeculae were significantly associated with history of stroke ($p=0.04$), which suggests that these individuals can be classified in the hemolytic subphenotype.

Table 2 Statistical analysis between history of clinical severity and radiographic features

	No radiopaque areas <i>n</i> =41 (%)	Radiopaque areas <i>n</i> =30 (%)	<i>p</i>	No increased spacing of bony trabeculae <i>n</i> =42 (%)	Increased spacing of bony trabeculae (%)	<i>p</i>	Absence of mandibular canal corticalization <i>n</i> =47 (%)	Presence of mandibular canal corticalization <i>n</i> =24 (%)	<i>p</i>	No trabecular horizontal arrangement <i>n</i> =55 (%)	Trabecular horizontal arrangement <i>n</i> =16 (%)	<i>p</i>
Jaundice			0.94			0.2*			0.35			0.08
Absence	15 (36.6)	11 (36.7)		20 (47.6)	6 (20.7)		19 (40.4)	7 (29.2)		23 (41.8)	3 (18.8)	
Presence	26 (63.4)	19 (63.3)		22 (52.4)	23 (79.3)		28 (59.6)	17 (70.8)		32 (58.2)	13 (81.2)	
Leg ulceration			0.49			0.97			0.27			
Absence	24 (58.5)	20 (66.7)		28 (66.7)	16 (55.2)		27 (57.4)	17 (70.8)		33 (60)	11 (68.8)	0.52
Presence	17 (41.5)	10 (33.3)		14 (33.3)	13 (44.8)		20 (42.6)	7 (29.2)		22 (40)	5 (31.2)	
Stroke			0.91			0.97			0.76			0.04*
Absence	38 (92.7)	28 (93.3)		39 (92.9)	27 (93.1)		44 (93.6)	22 (91.7)		53 (96.4)	13 (81.3)	
Presence	3 (7.3)	2 (6.7)		3 (7.1)	2 (6.9)		3 (6.4)	2 (8.3)		2 (3.6)	3 (18.7)	0.07
Femur osteonecrosis			0.69			0.61			0.24			
Absence	33 (80.4)	23 (76.7)		34 (81.0)	22 (75.9)		39 (83.0)	17 (70.8)		46 (83.6)	10 (62.5)	
Presence	8 (19.5)	7 (23.3)		8 (19.0)	7 (24.1)		8 (17.0)	7 (29.2)		9 (16.4)	6 (37.5)	0.54
VOC frequency			0.76			0.12			0.19			
Without episodes or more than 3 years in steady state	12 (29.3)	8 (26.7)		15 (35.7)	5 (17.2)		16 (34.0)	4 (16.7)		16 (29.1)		
Once or twice a year	17 (41.4)	15 (50.0)		15 (35.7)	17 (58.6)		21 (44.7)	11 (45.8)		26 (47.3)	6 (37.5)	
More than twice a month	12 (29.3)	7 (23.3)		12 (20.6)	7 (24.1)		10 (21.3)	9 (37.5)		13 (23.6)	6 (37.5)	

*Statistical significant value

Radiopacities in the bone are reported in SCD patients, occurring more commonly in posterior mandible along vascular canals or apical region of teeth, and reflect a previous history of bone infarcts [21]. During generalized sickle cell crises, vaso-occlusive involvement of mandible of ischemic and aseptic nature can occur, displaying odontogenic pain or neuropathy [17, 29] and contributing for dental pulp death [36]. Literature reports few cases of mandibular infarction [14, 15, 17, 37], probably due to significant collateral circulation and difficulty in documenting infarction in this bone [9]. Kavadia-Tsatala et al. [29] found 14% of 42 SCA patients with radiopaque areas on panoramic radiographs that were considered of vaso-occlusive origin considering symptomatology and absence of dental lesions or acute infection. In a radiographic analysis of 80 SCD subjects, Mourshed and Tuckson [23] referred to the radiopaque areas observed in SCD patients as reaction to chronic infection and healed infarcts were not considered. However, the criteria used for this diagnosis were not presented. In the current study, 42% of the 71 SCD subjects presented radiopaque areas. Specific history of jaw pain was not registered; thus, definite association of such radiopaque areas with previous infarcted areas is not possible. This feature did not show significant association with higher frequency of vaso-occlusive crises (Table 2) or any other clinical parameters of systemic severity. Since infarctions are less common in facial bones [15], it is likely that in these patients vaso-occlusive crises with major systemic symptomatology did not affect the mandible. It may be suggested that radiopaque areas in jaws could be a consequence of subclinical vaso-occlusions, causing bony microinfarctions [14]. Identification of infarcted areas is important, since it is believed that these areas are prone to develop osteomyelitis due to the lower vascularization [38].

Although maxillofacial bony manifestations are not uncommon in SCD, they are not well studied in the literature. Acknowledgment of these radiologic manifestations, understanding its pathophysiology and relationship with systemic complications, can expand the contribution of dentistry in the approach of SCD patients. Based on the results of the current study, maxillofacial radiographic features may be associated with clinical parameters of systemic complications. Large prospective studies involving clinical and laboratory diagnosis of systemic complications should be conducted to confirm these results. Additionally, in order to confirm bony jaw alterations as radiographic predictors of the disease severity other imaging techniques, such as MRI, should be evaluated.

Acknowledgements We are thankful to Professor Marilda Souza Gonçalves for carrying out the electrophoresis examinations in the Laboratory of Specialized Analysis in Hematology of School of Pharmacy of Federal University of Bahia. This study was supported by the Research Foundation of the State of Bahia (FAPESB).

Conflict of interest The authors declare that they have no conflict of interest.

References

- Steinberg MH (1998) Pathophysiology of sickle cell disease. *Baillieres Clin Haematol* 11:163–84
- Nagel RL, Fabry ME, Steinberg MH (2003) The paradox of hemoglobin SC disease. *Blood Rev* 17:67–178
- Stuart MJ, Nagel RL (2004) Sickle-cell disease. *Lancet* 364:1343–1360
- Kelleher M, Bishop K, Briggs P (1996) Oral complications associated with sickle cell anemia: a review and case report. *Oral Surg Oral Med Oral Pathol Oral Radiol Endod* 82:225–228
- Kato GJ, Hebbel RP, Steinberg MH, Gladwin MT (2009) Vasculopathy in sickle cell disease: Biology, pathophysiology, genetics, translational medicine, and new research directions. *Am J Hematol* 84:618–625
- Flouzat-Lachaniette CH, Roussignol X, Poignard A, Mukasa MM, Manicom O, Hernigou P (2009) Multifocal joint osteonecrosis in sickle cell disease. *Open Orthop J* 15:32–35
- Almeida A, Roberts I (2005) Bone involvement in sickle cell disease. *Br J Haematol* 129:482–490
- Madani G, Papadopoulou AM, Holloway B, Robins A, Davis J, Murray D (2007) The radiological manifestations of sickle cell disease. *Clin Radiol* 62:528–538
- Lonergan GJ, Cline DB, Abbondanzo SL (2001) Sickle cell anemia. *Radiographics* 21:971–994
- Baykul T, Avdin MA, Nasir S (2004) Avascular necrosis of the mandibular condyle causing fibrous ankylosis of the temporomandibular joint in sickle cell anemia. *J Craniofac Surg* 15:1052–1056
- el-Sabbagh AM, Kamel M (1989) Avascular necrosis of temporomandibular joint in sickle cell disease. *Clin Rheumatol* 8:393–397
- Orhan K, Delilbasi C, Paksoy C (2009) Magnetic resonance imaging evaluation of mandibular condyle bone marrow and temporomandibular joint disc signal intensity in anaemia patients. *Dentomaxillofac Radiol* 38:247–254
- Sebes JI, Diggs LW (1979) Radiographic changes of the skull in sickle cell anemia. *AJR Am J Roentgenol* 132:373–377
- Sanger RG, Greer RO Jr, Averbach RE (1977) Differential diagnosis of some simple osseous lesions associated with sickle-cell anemia. *Oral Surg Oral Med Oral Pathol* 43:538–545
- Royal JE, Harris VJ, Sansi PK (1988) Facial bone infarcts in sickle cell syndromes. *Radiology* 169:529–531
- Duggal MS, Bedi R, Kinsey SE, Williams SA (1996) The dental management of children with sickle cell disease and beta-thalassaemia: a review. *Int J Paediatr Dent* 6:227–234
- Podlesh SW, Boyden DK (1996) Diagnosis of acute bone/bone marrow infarction of the mandible in sickle hemoglobinopathy. Report of a case. *Oral Surg Oral Med Oral Pathol Oral Radiol Endod* 81:547–549
- Lawrenz DR (1999) Sickle cell disease: a review and update of current therapy. *J Oral Maxillofac Surg* 57:171–178
- Gillis MV, West NM (2004) Sickle cell disease and trait: an increase in trabecular spacing, a case study. *J Dent Hyg* 78:355–339
- da Fonseca M, Oueis HS, Casamassimo PS (2007) Sickle cell anemia: a review for the pediatric dentist. *Pediatr Dent* 29:159–169
- Ramakrishna Y (2007) Dental considerations in the management of children suffering from sickle cell disease: a case report. *J Indian Soc Pedod Prev Dent* 25:140–143

22. Saito N, Nadgir RN, Flower EN, Sakai O (2010) Clinical and radiologic manifestations of sickle cell disease in the head and neck. *Radiographics* 30:1021–1034
23. Mourshed F, Tuckson CR (1974) A study of the radiographic features of the jaws in sickle-cell anemia. *Oral Surg Oral Med Oral Pathol* 37:812–819
24. Sanger RG, Bystrom EB (1977) Radiographic bone changes in sickle cell anemia. *J Oral Med* 32:32–37
25. Taylor LB, Nowak AJ, Giller RH, Casamassimo PS (1995) Sickle cell anemia: a review of the dental concerns and a retrospective study of dental and bony changes. *Spec Care Dentist* 15:38–42
26. White SC, Cohen JM, Mourshed FA (2000) Digital analysis of trabecular pattern in jaws of patients with sickle cell anemia. *Dentomaxillofac Radiol* 29:119–124
27. Faber TD, Yoon DC, White SC (2002) Fourier analysis reveals increased trabecular spacing in sickle cell anemia. *J Dent Res* 81:214–218
28. Demirbaş Kaya A, Aktener BO, Unsal C (2004) Pulpal necrosis with sickle cell anaemia. *Int Endod J* 37:602–606
29. Kavadia-Tsatala S, Kolokytha O, Kaklamanos EG, Antoniadis K, Chasapopoulou E (2004) Mandibular lesions of vasoocclusive origin in sickle cell hemoglobinopathy. *Odontology* 92:68–72
30. Demirbaş AK, Ergün S, Güneri P, Aktener BO, Boyacıoğlu H (2008) Mandibular bone changes in sickle cell anemia: fractal analysis. *Oral Surg Oral Med Oral Pathol Oral Radiol Endod* 106:41–48
31. Hazza'a AM, Al-Jamal G (2006) Radiographic features of the jaws and teeth in thalassaemia major. *Dentomaxillofac Radiol* 35:283–288
32. Soni NN (1966) Microradiographic study of dental tissues in sickle-cell anaemia. *Arch Oral Biol* 11:561–564
33. Gurevitch O, Slavin S (2006) The hematological etiology of osteoporosis. *Med Hypotheses* 67:729–735
34. Dhaliwal G, Cornett PA, Tierney LM Jr (2004) Hemolytic anemia. *Am Fam Physician* 69:2599–2606
35. Durand C, Schiffer JT (2009) With jaundiced eyes. *Am J Med* 122:21–23
36. Bishop K, Briggs P, Kelleher M (1995) Sickle cell disease: a diagnostic dilemma. *Int Endod J* 28:297–302
37. Walker RD, Schenck KL Jr (1973) Infarct of the mandible in sickle cell anemia: report of case. *J Am Dent Assoc* 87:661–664
38. Olaitan AA, Amuda JT, Adekeye EO (1997) Osteomyelitis of the mandible in sickle cell disease. *Br J Oral Maxillofac Surg* 35:190–192

Copyright of Clinical Oral Investigations is the property of Springer Science & Business Media B.V. and its content may not be copied or emailed to multiple sites or posted to a listserv without the copyright holder's express written permission. However, users may print, download, or email articles for individual use.