

Immediate post-traumatic upper incisor reconstruction using composite resin materials

CASE REPORT

Vlatko Panduric¹, Dragana Gabric², Visnja Negovetic-Mandic¹

¹Department of Restorative Dentistry, School of Dental Medicine, University of Zagreb, Zagreb;

²Clinical Hospital Center Zagreb, University Dental Clinic, Zagreb, Croatia

Correspondence to: Vlatko Panduric DDS, PhD, Department of Dental Pathology, School of Dental Medicine, University of Zagreb, Gundulićeva 5, HR-10000 Zagreb, Croatia

Tel.: +38514802143

Fax: +38514802159

e-mail: vpanduric@sfg.hr

Accepted 18 January, 2006

Abstract – Single visit reconstruction of the fractured crown can be completed with composite resins if there is no bleeding due to the soft tissue injury. Clinical inspection revealed a complex crown fracture of the central incisor as well as a simple horizontal fracture of the lateral incisor crown of the enamel-dentin type. Vertical fracture separated the palatal enamel wall from the rest of the lateral incisor crown. After the completion of the endodontic sanitation, root canals were prepared for prefabricated composite posts and crown reconstructions were performed with the Finger Tip Technique by using composite resin materials. The advantage of this kind of reconstruction is preservation of the hard dental crown tissue removed in case of prosthetic therapy, especially in younger patients. Reconstruction can be finished in one visit, without the need for a dental technician and laboratory.

After the trauma in the dental arch area exposed to direct view, patients often demand and expect single visit solution of the problem. In young patients, preservation of the remaining tooth crown tissue is necessary. Taking into consideration the demand for immediate reconstruction as well as maximal preservation of the dental tissue, the material of choice is composite resin. The indication for use will depend on the size of defect or on the fracture type (1). The extent of crown damage can threaten pulp vitality or if it is exposed, necessitate endodontic treatment. Sometimes additional support of the root canal with an intracanal post is necessary followed by immediate crown reconstruction in accordance with esthetic criteria (2). Metal cast dowel core, besides extended manufacturing time in comparison to prefabricated posts, can, because of their color, shine through the composite resin and root and jeopardize esthetics of the reconstruction. In addition, the cast and prefabricated metal dowel cores are too stiff and do not have module of elasticity similar to dentin. Because of the lack of elasticity, there is an increased risk of vertical root fractures (3, 4). Prefabricated ceramic posts that meet esthetic criteria can also, because of their rigidity, cause vertical fractures. In order to avoid the need for a dental technician and because of biomechanical characteristics similar to dentin, intracoronal build-up using prefabricated composite posts in combination with composite resin materials is recommended (5). They are cemented inside the root canal using adhesive composite cements. After the cementation, all prerequisites are met for tooth crown composite reconstruction. Single visit reconstruction of the fractured crown can be completed with composite resins (6) if there is no bleeding due to the soft tissue injury.

Clinical case

A 21-year-old patient arrived at the office with oblique fractures of the upper left incisal crowns. Clinical inspection revealed a complex crown fracture of the central incisor as well as a simple horizontal fracture of the lateral incisor crown of the enamel-dentin type. Vertical fracture separated the palatal enamel wall from the rest of the lateral incisor crown. The fractured fragment remained attached to the crown by periodontal fibers (Fig. 1). Acute pain on thermal stimuli and on occlusal movements resulted in necessary endodontic treatment. After the rubber-dam placement, the pulp was removed and the length of the root canals was determined by using an electronic apex locator (ES-03; Artronic, Zagreb, Croatia). Root canals were chemically and mechanically cleaned and shaped by using the step-back technique and then filled by using the cold lateral condensation technique (Fig. 2).

After the completion of the endodontic sanitation, root canals were prepared for prefabricated composite posts FRC Postec (Ivoclar Vivadent, Shaan, Liechtenstein).

Gutta-percha was removed and each root canal was shaped by using a calibrated burr recommended by the manufacturer for specific post type. Composite posts were also cemented according to the manufacturer's recommendation with composite cement Multicore Flow (Ivoclar Vivadent). The self-etching adhesive system AdheSE DC (Ivoclar Vivadent) was used for hybridization of the root dentin. A specific quality of this self-etching adhesive system is its capability to polymerize chemically and by light. In this way, dentinal hybridization was enabled even in the areas inaccessible to

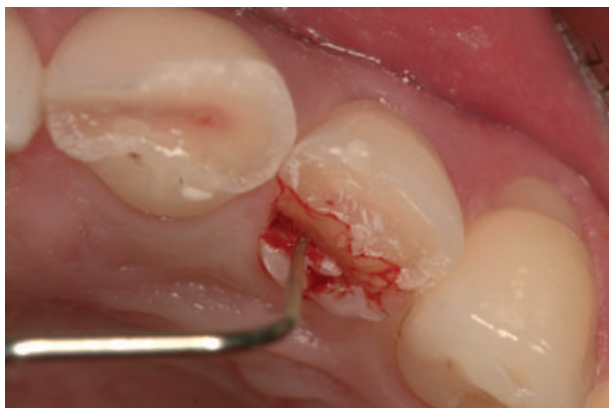

Fig. 1. Horizontal fracture of upper incisors and vertical fracture of the palatal enamel of the second lateral upper incisor.

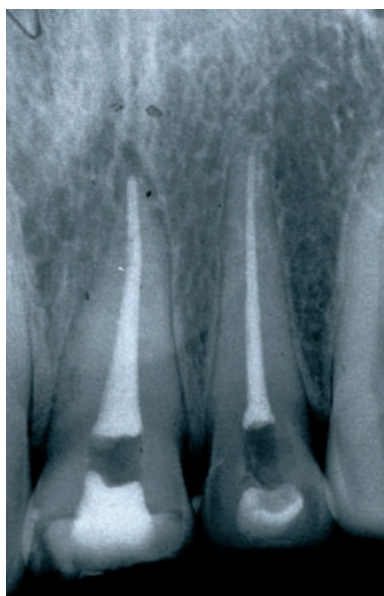


Fig. 2. Upper incisors after endodontic treatment.

polymerization light. Before cementation, the post surface is etched and silanized with Monobond-S (Ivoclar Vivadent). Surface silanization increases the bond strength between the cement and the composite post. Shortening the post to the desired length before cementation is recommended (Fig. 3).

After post fixation, crown reconstruction was performed with the Finger Tip Technique by using composite resin materials. Hard dental tissues of the tooth crown were treated mechanically and chemically. Mechanical treatment consisted of burr beveling of the enamel to increase the bonding surface as well as to achieve gradual transfer of the composite resin to the tooth surfaces and easier adjustment of the color. The color of the tooth crown depends on internal as well as on external crown structure. It is very complex and never consists of a single shade. Therefore, because of the complexity of the dental tissue it is impossible to perform the reconstruction in only one color shade of the

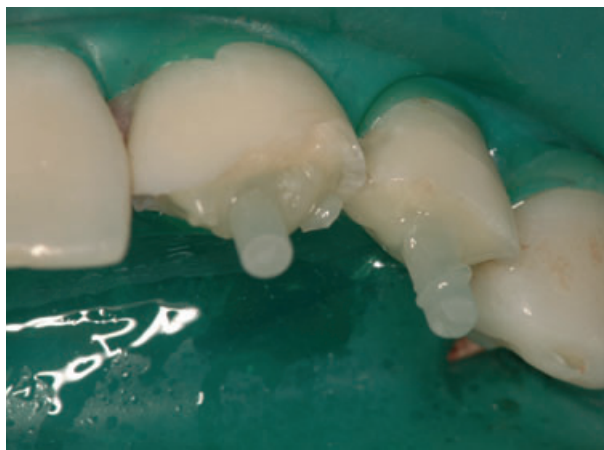

Fig. 3. FRC Postec cemented in root canal with composite cement.

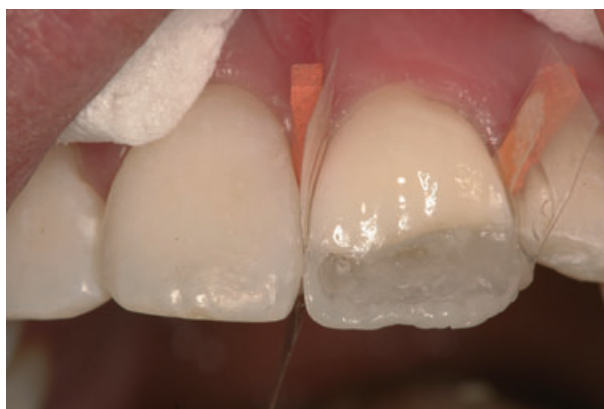

Fig. 4. Palatal wall reconstructed with enamel shade.

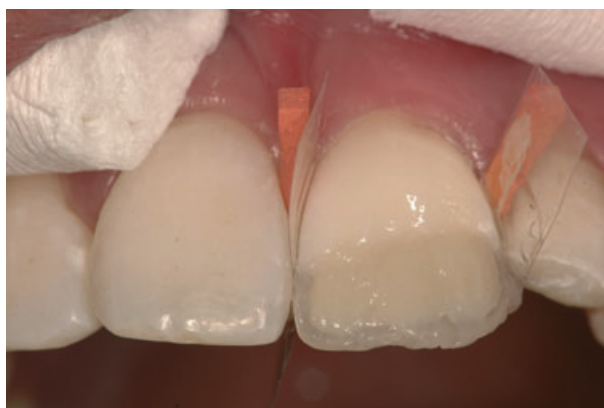

Fig. 5. Reconstruction of the fractured crown with dentin shades.

composite resin. The central incisor was reconstructed first. A layer of enamel shade of the composite resin was placed at the palatal shell (Fig. 4), slightly under the desired length, around 1 mm thick. As the color of dentin determines the color of the tooth, it is important that the palatal wall is not too thick so as to leave enough room for dentin composite material (Fig. 5) and in the

end final layer of enamel shade of composite resin material.

After constructing the central incisor, the lateral incisor was reconstructed as well. A celluloid stripe was placed in the gingival sulcus in the palatal gingival sulcus and fixed with the organic resin Heliobond (Ivoclar Vivadent). This procedure decreased the possibility of dentinal surface contamination with saliva and gingival fluids. The palatal wall was reconstructed first as in the case of the central incisor, but because of the fracture type the entire palatal veneer was placed followed by the labial veneer (Figs 6 and 7). After completion of the composite placement and polymerization, incisors were finely modeled using diamond burs (Figs 8 and 9). Horizontal growth lines were made and for the final polishing of the labial surface Astrobrushes (Ivoclar Vivadent) were used (7).

Discussion

The reasons for choosing an immediate, single visit reconstruction of the upper incisor trauma with composite materials instead of prosthetic therapy are: age of the patient, preserving the remaining hard dental tissue,

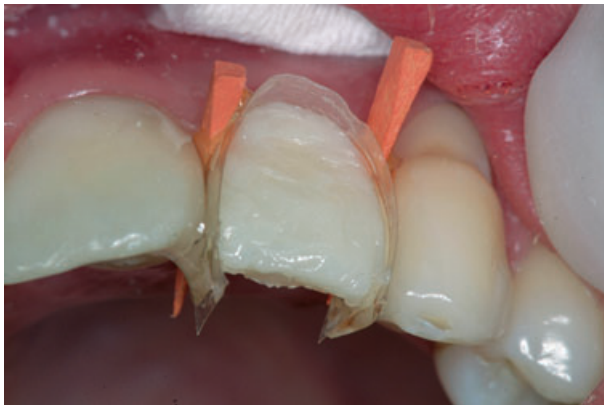

Fig. 6. Shaping of the vestibular surface on the upper lateral incisor.

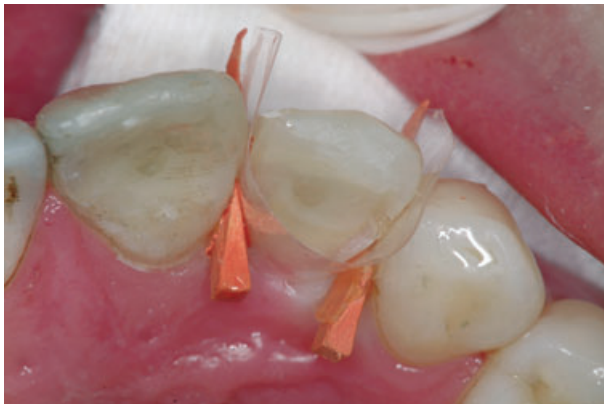

Fig. 7. Shaping of the palatal surface on the upper lateral incisor.

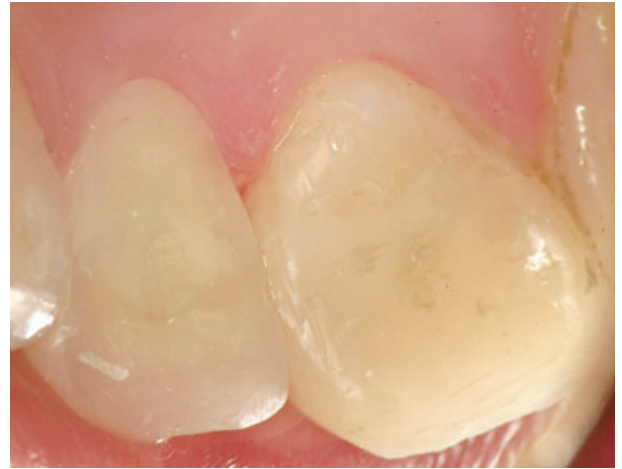

Fig. 8. Palatal surfaces of reconstructed upper incisors.

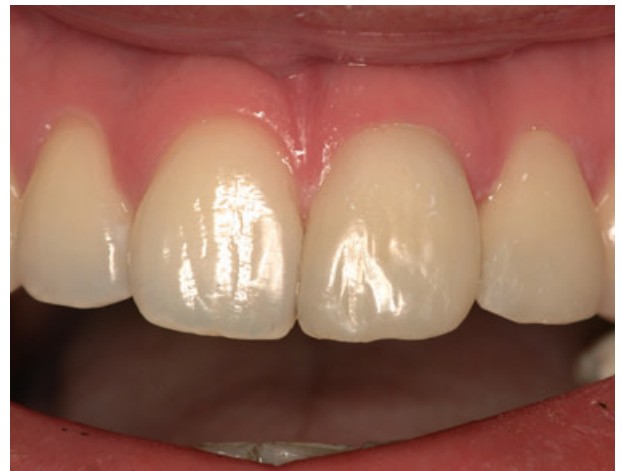

Fig. 9. Reconstructed upper incisors.

patient request for immediate sanitation and his inability to finance prosthetic therapy. During the reconstruction of the fractured crown, it is important to consider possible mistakes. Complete removal of the gutta-percha from the dentinal walls is necessary when preparing the root canal for adhesive cementation of the prefabricated composite post because the remaining gutta-percha and paste interfere with hybridization of the root dentin. The posts must not fit too tightly to the root canal walls or additional tension will be created during polymerization (8). In order to achieve good retention the posts should be inserted at two-thirds of the canal length (9). To decrease the porosity caused by air bubbles that remain in the root canal upon cement insertion, the use of a lentulo spiral is recommended.

Reconstruction should satisfy the esthetic criteria, i.e. the tooth shade and resin shade should match. Tooth color is determined by dentin (10). The organic component in dentin is responsible for absorption of light wavelengths. The size and orientation of dentinal tubules can also influence absorption (11). Taking that into

consideration it is clear why tooth shade of younger patients differs from that of older patients. The thickness of the enamel and the dentin is also determined by shade or transmission of light. The influence of dentin on tooth shade in the cervical third of the tooth crown is greater than that in the middle and incisal third (12). The angles of cutting the enamel and their transmission of the background color influence color in the middle and incisal third (13). The appropriate shade was chosen before rubberdum placement because rubberdum can negatively influence eye's ability to perceive dental tissue shade.

The dentin shade of composite materials should be opaque because it should block the dark background of the oral cavity that shines through composite resin and can change the color of the reconstruction. If there are mamelons in dentin, they should be reconstructed in dentinal shade. Enamel shade of the composite material was placed as a final layer (14). The crown will gain definite shape by final treatment with diamond burrs and its shape adjusted to conform with the shape of the remaining frontal teeth.

The advantage of this kind of reconstruction is preservation of the hard dental crown tissue removed in case of prosthetic therapy, especially in younger patients. Besides, reconstruction can be finished in one visit, without the need for a dental technician and laboratory.

References

1. Villat C, Machtou P, Naulin Ifi C. Multidisciplinary approach to the immediate esthetic repair and long-term of an oblique crown-root fracture. *Dent Traumatol* 2004;20:56–60.
2. Lassila VJL, Tanner J, Le Bell AM. Flexural properties of fiber reinforced root canal posts. *Dent Mater* 2004;20:29–36.
3. Assif D, Bitenski A, Pilo R, Oren E. Effect of post design on resistance to fracture of endodontically treated teeth with complete crowns. *J Prosthet Dent* 1993;69:36–40.
4. Torbörner A, Karlsson S, Syverud M, Hensten-Pettersen A. Carbon fiber reinforced root canal posts. Mechanical and cytotoxic properties. *Eur J Oral Sci* 1996;104:605–11.
5. Pes LB, Cavalli G, Bertani P, Galiani M. Adhesive post-endodontic restorations with fiber post: push-out test and SEM observation. *Dent Mater* 2002;18:596–602.
6. Mannocci F, Bertelli E, Sherrieff M, Watson FT, Ford TRP. Three-year clinical comparison of survival of endodontically treated teeth restored with either full cast or with direct composite restoration. *J Prosthet Dent* 2002;88:297–301.
7. Lendhard M. Aesthetische Frontzahnfüllungen mit komposit. *Quintessence* 2004;55:961–76.
8. Lui JL. Enhanced post crown retention in resin composite-reinforced, compromised, root-filled teeth: a case report. *Quintessence Int* 1999;30:601–6.
9. Newman PM, Yaman P, Dennison J, Rafter M, Billy E. Fracture resistance of endodontically treated teeth restored with composite posts. *J Prosthet Dent* 2003;89:360–7.
10. Ten Bosch JJ, Coops JC. Tooth color and reflectance as related to light scattering and enamel hardness. *J Dent Res* 1995;74:374–80.
11. Ragain JC, Johnston WM. Accuracy of Kubelka-Munk reflectance theory applied to human enamel. *J Dent Res* 2001;80:449–52.
12. Dozic A, Kleverlaan JC, Aartman HAI, Feilzer JA. Relation in color of three regions of vital human incisors. *Dent Mater* 2004;20:832–8.
13. Price RB, Murphy DG, Derand T. Light energy transmission through cured resin composite and human dentin. *Quintessence Int* 2000;9:659–67.
14. Hoelscher DC, Gregory WA, Linger JB, Pink FE. Effect of light source positioning and bevel placement on facial margin adaptation of resin-based composite restorations. *Am J Dent* 2000;134:171–5.

This document is a scanned copy of a printed document. No warranty is given about the accuracy of the copy. Users should refer to the original published version of the material.