

Orthodontic movement of a dilacerated maxillary incisor in mixed dentition treatment

CASE REPORT

Giampietro Farronato¹, Cinzia Maspero¹, Davide Farronato²

¹Department of Orthodontics, ²Department of Orthodontics, University of Milan, Milan, Italy

Correspondence to: Cinzia Maspero, University of Milan, Via Commenda 10, 20100 Milan, Italy

Tel.: +39 (0)257 992 520

Fax: +39 (0)250 320 239

e-mail: cinzia.maspero@libero.it

Accepted 25 April, 2008

Abstract – Dilaceration is a dental deformity characterized by an angulation between crown and root causing non-eruption of the tooth. It generally occurs following trauma to the deciduous dentition the apices of which lie close to the permanent tooth buds. Surgical extraction used to be the first choice in treating the severely dilacerated teeth. In this case report, it is described how a dilacerated central incisor was successfully moved into alignment in a young patient with proper surgical and orthodontic management avoiding use of prosthetic/implant devices. The panoramic radiograph after the traumatic injury is compared with the one at the end of treatment. The results were sustainable over long-term in both periodontal and aesthetic terms.

Determining prognosis and designing a treatment plan for a dilacerated impacted tooth are often difficult tasks. The easiest chosen therapy is surgical extraction.

Dilaceration is defined as a distorted root form and it can occur from any distortion of the crown relative to the root (1, 2). This sort of lesion in a permanent tooth is caused by some trauma to the corresponding deciduous tooth (usually upper and lower incisors) (3–5).

The severity of the lesion on a permanent tooth depends on the developmental stage of the tooth, the force of impaction and the direction the force of the trauma was applied with respect to the permanent tooth (6, 7). The trauma usually responsible for this type of lesion is frequent traumatic intrusion or avulsion during childhood. If the trauma occurs while the crown of the permanent tooth is forming, enamel formation will be disturbed and there will be a defect in the crown of the permanent tooth (1). If the trauma occurs after the crown is complete, the crown may be displaced relative to the root. Root formation may stop, leaving a permanently shortened root. More frequently, however, root formation continues, but the remaining portion of the root then forms at an angle to the traumatically displaced crown. If distortion of root position is severe enough, it is almost impossible for the crown to assume its proper position (1, 8). The crown is usually dislocated forward with the palatal surface facing the vestibular site, the incisor border is turned up towards the anterior nasal bone; the root remains in its normal position.

Dilacerations may result from mechanical interference with eruption.

In growing patients, it is often possible to save dilacerated impacted teeth with a multidisciplinary approach. The factor determining prognosis is whether the tooth is already ankylosed or if excessive or intermittent orthodontic forces lead to external resorption of

the roots (9, 10). In this case report, it is described how a dilacerated upper central incisor was moved into its proper position with surgical exposure and orthodontic traction avoiding prosthetic/implants replacement. The dilacerated incisor presented pulpal vitality and periodontal health.

Case report

The patient was a 5-year-old boy in excellent physical health who came to the Department of Orthodontics of the University of Milan for an orthodontic visit. The dental and medical history was unremarkable. The intraoral examination showed the presence of all the primary teeth, flush terminal plane occlusal relationship, no cross bite, overjet and overbite were within the norm. A panoramic radiograph was performed. It showed the presence of all the permanent teeth buds without any ectopic teeth or disturbance of eruption. There was no orthodontic indication for therapy. The patient was seen every 3 months for 1 year for oral hygiene and motivation.

At the age of 7, the patient came for another orthodontic visit as the upper right central incisor was not erupting.

His parents mentioned a traumatic episode 1 year before in which he fractured and lost the upper right central deciduous incisor.

Diagnosis

Facial proportions were normal.

On intraoral examination, the presence of mixed dentition, dental class I on both sides, an anterior open bite, the absence of the maxillary right central incisor, the drift of the adjacent teeth into the unoccupied space

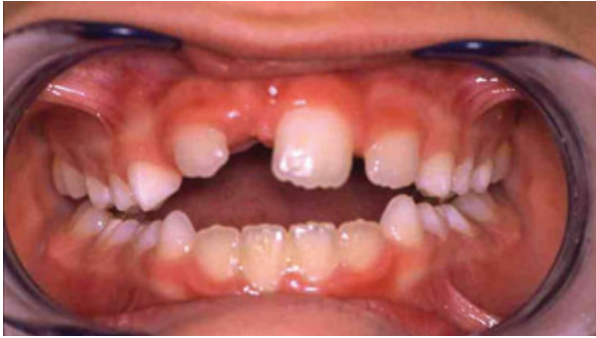

Fig. 1. Pretreatment intraoral photograph showing the non-eruption of maxillary right central incisor.

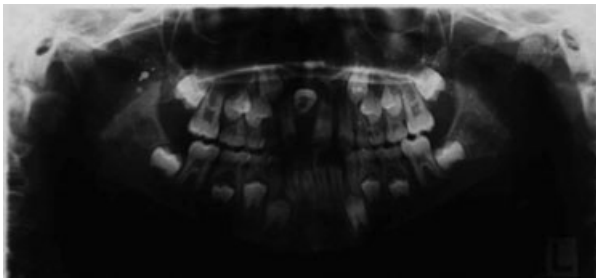


Fig. 2. Pretreatment panoramic radiograph shows dilacerated maxillary incisor.

and slight midline discrepancies were observed. The upper left central incisor was inclined mesially (Fig. 1). While smiling, the unerupted incisor was very noticeable.

The periodontal health was good, with no recession or gingival bleeding.

Both panoramic and periapical radiograph results were examined (Figs 2,3). They revealed a triangular profile structure with the apex facing down in the area of the right central incisor. It was not possible to obtain more information regarding morphology and the exact dimensions of the impacted upper central incisor. It was also possible to identify an eruption cyst around the tooth.

The periapical radiographs, performed according to Clark's technique and the occlusal radiograph (Fig. 4) provided useful indications to the vestibular position of the dilacerated tooth in the labial palatal plane. The vestibular position of the crown and the palatal direction of the root could be noted easily.

The lateral and frontal telerradiographies allowed confirming the diagnosis of dilaceration of the upper central incisor that showed an inverted position with the crown in the apical area. The incisor margin was below the anterior nasal bone (Figs 5,6).

The vestibular mucosa palpation indicated a bulge in the upper anterior area where the dilacerated incisor was probably located.

Treatment objectives

The aim of the treatment was to recover the integrity of the upper arch centring the superior and inferior incisors midline.

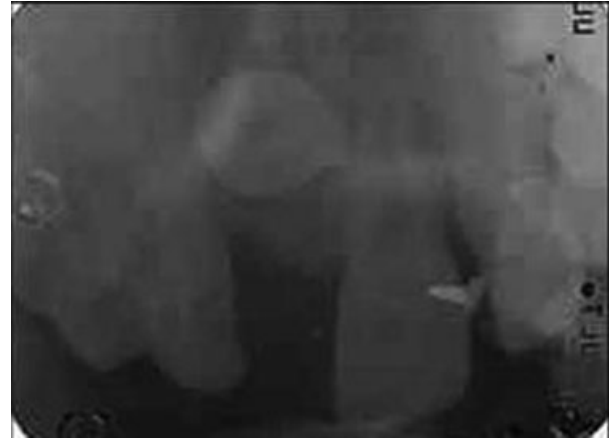

Fig. 3. Pretreatment periapical radiograph of impacted central incisor.

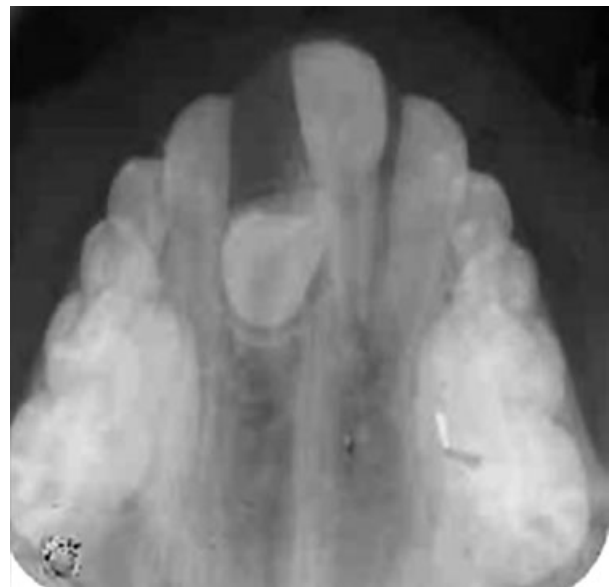


Fig. 4. Pretreatment occlusal radiograph of impacted central incisor.

The purpose was to guide the impacted incisor into proper alignment with the adjacent incisor teeth and to re-create a complete anterior dentition. The treatment aimed to resume root formation because the apex was still open, to obtain proper crown and root alignment without root damage maintaining the vitality and integrity of the root of the dilacerated tooth (11).

The purpose of the treatment was, also, to extrude the tooth with all its supporting tissues (alveolar bone and attached gingiva), to investigate the effects that surgical exposure, orthodontic movements, and final tooth position would have had on them and to evaluate the long-term gingival and periodontal conditions. To create adequate gingival support during repositioning of the dilacerated tooth was also necessary.

The approach was multidisciplinary involving a combined surgical/orthodontic treatment (12, 13).

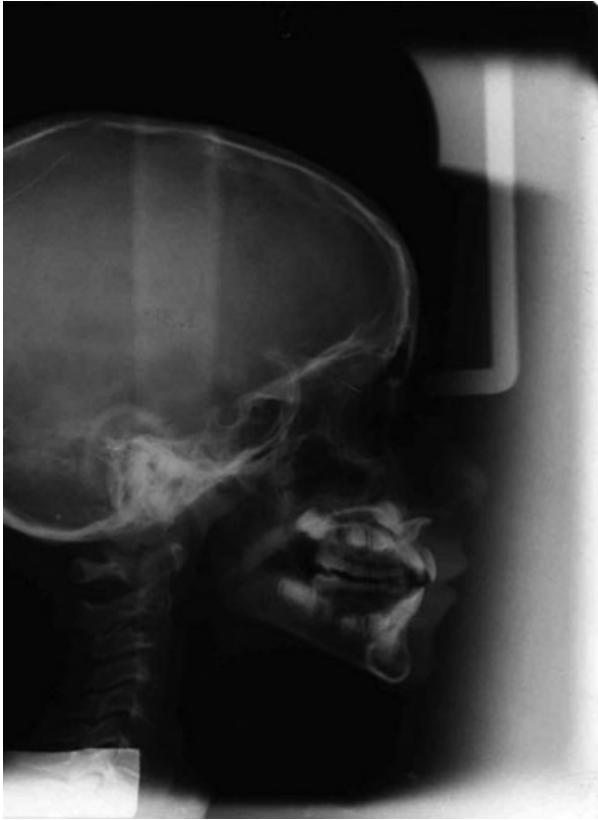

Fig. 5. Pretreatment lateral cephalometric radiograph showing dilacerated tooth.

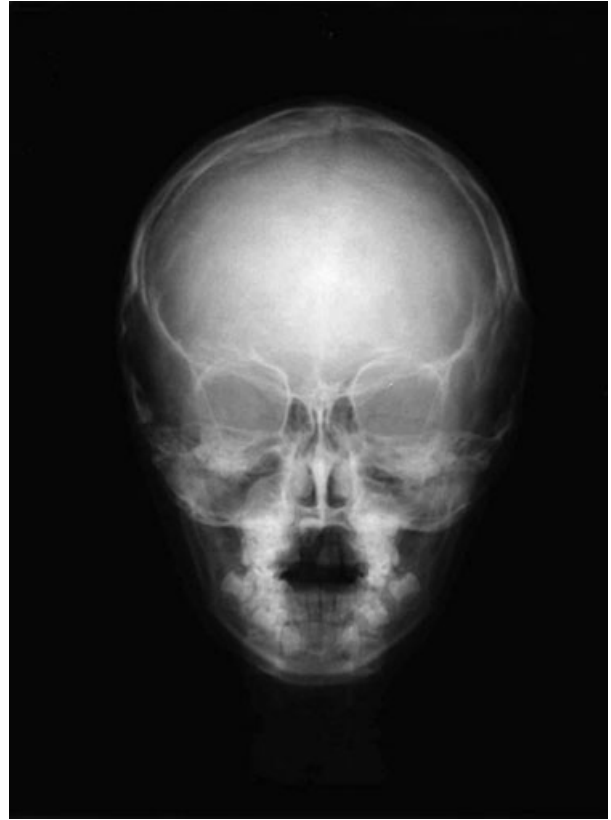


Fig. 6. Pretreatment frontal cephalometric radiograph showing dilacerated tooth.

Treatment progress

After explaining the advantages and disadvantages of the therapeutic options to the parents of the patient, they accepted to proceed with the surgical exposure and orthodontic traction of the dilacerated tooth while being fully aware of the uncertain prognosis. Repositioning the dilacerated tooth in its position was the most convenient option, although this solution presented orthodontic difficulties. Therefore, the approach was based on combined surgical/orthodontic treatment.

The treatment plan required to recover and manage the necessary eruption space to allow the impacted dilacerated tooth to settle into the maxillary arch while adequately redistributing the residual space in the upper frontal area.

A rapid palatal expander (RPE) was performed. It was performed with two vestibular steel wire arms and soldered to first permanent molar bands; one arm arriving in correspondence of the left central incisor to which it was bonded to gain space on the right side and to avoid the drift of left central incisor in the space created by the activation of the RPE; the second vestibular arm was on the right side arriving in correspondence of the edentulous space and ending with a loop for the traction of the dilacerated tooth. The appliance was activated twice per day for 2 weeks (Figs 7,8). After adequate space was obtained, the surgery was planned.

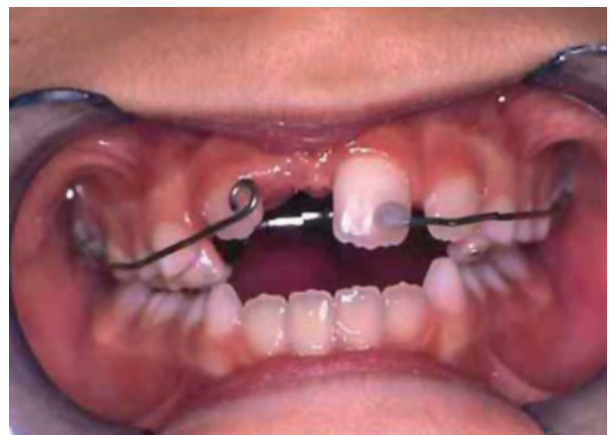

Fig. 7. Intraoral frontal view with the rapid palatal expander.

The surgical technique involved a split-thickness pedicle reflected from the edentulous area extended vertically into the vestibule. Bone covering the dental crown was removed with a surgical round bur. This allowed the palatal surface of the right central incisor to be exposed (5, 14, 15).

A retention cyst was found around the tooth and consequently removed. The flap was then repositioned apically and sutured to the periosteum adhering to the surrounding gingiva and leaving two thirds of the crown of the tooth uncovered (14).

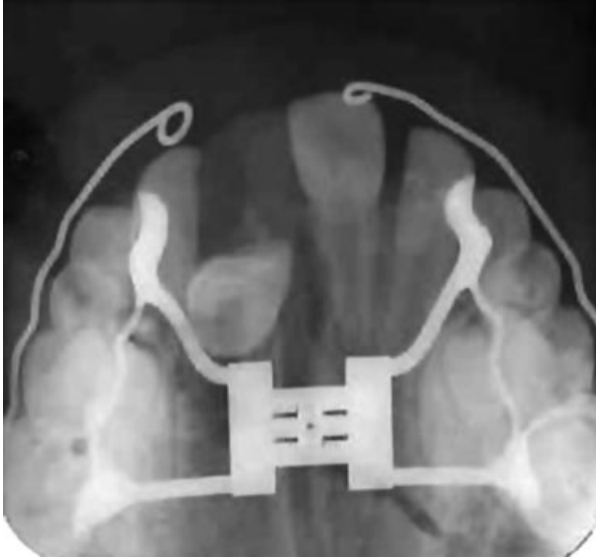


Fig. 8. Occlusal radiograph showing the maxillary expansion.

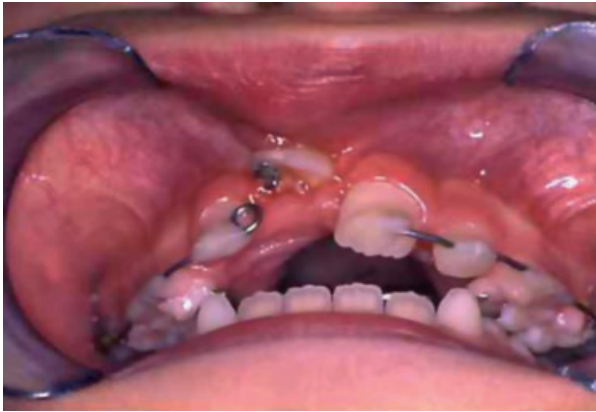

Fig. 9. Surgical exposition of dilaceration with apical repositioning flap. Crown exposure with buccal button bonded on the surface and the elastic module connected to the expensor.

Upon healing, a button was directly bonded to the dilacerated incisor and a 0.010-inch wire ligature was attached from the attachment to the loop of the vestibular right arm of palatal expander. An elastomeric module was applied and connected to the wire ligature to the loop of the right vestibular arm (Fig. 9). The elastic module generated a constant light force of no more than 30–40 g (5, 16, 17).

The force was activated monthly creating a physiological direction of tooth eruption (4, 14, 15).

Periapical X-rays were performed every 6 weeks to monitor the extrusion and the presence of side effects such as radicular resorption or ankylosis of the dilacerated tooth.

When the central incisor was close enough to the arch line and after completing the RPE retention period, the device was removed. After 1 month, bands were cemented on the upper first molars and brackets were positioned on the maxillary upper incisors to extrude the dilacerated tooth into the arch (Fig. 10).

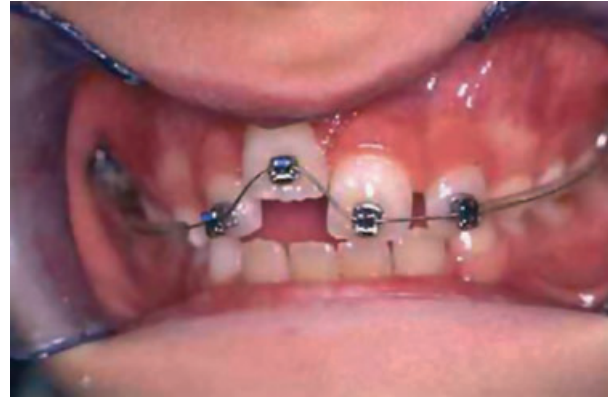

Fig. 10. Brackets positioned on the maxillary upper incisors to extrude the dilacerated tooth.

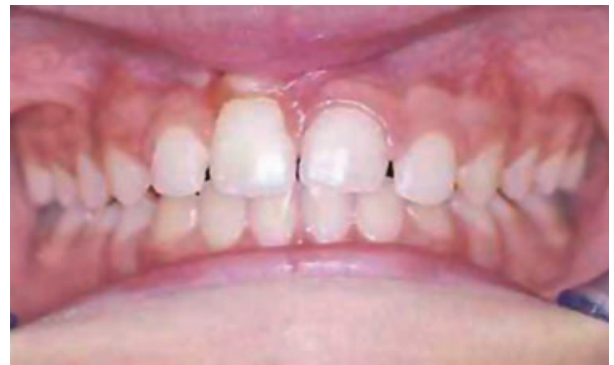

Fig. 11. Post-treatment intraoral photograph.

When the dilacerated tooth was in its position in the upper arch, the brackets were debonded, and the patient began wearing an elastodontic appliance to wait for the eruption of all the permanent teeth to achieve final root position by a full multibracket appliance to obtain optimal results (Fig. 11).

The patient was seen at 4-month intervals to control the vitality of the dilacerated and the stability of the results obtained.

Results

The dilacerated tooth was successfully repositioned into proper alignment with the adjacent incisors resulting in a complete anterior dentition and a nice smile.

The profile was aesthetically improved with alignment of the incisors.

The progression of root dilacerations was avoided because the early reposition of the dilacerated incisor permitted obtaining the resume of root formation as the root was not completely formed.

No pulp pathology or colour change of the right central incisor was found.

No vertical (intrusive) relapse was observed from the end of treatment to the time of recalls.

No loss of attachment was found on the facial surface of the dilacerated tooth. The width of attached gingival was greater on the facial surface of the tooth.

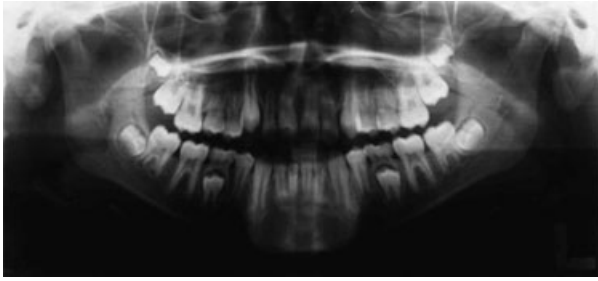


Fig. 12. Post-treatment panoramic radiograph. Note that root formation has continued the tooth in final position with reasonable root length, good periodontal health.

The gingival margins were appropriate and the attached gingiva was adequate. Probing did not reveal periodontal damage. The tooth presented reasonable root length, good periodontal health and physiological mobility after orthodontic traction.

X-rays showed that root formation has continued with minimal distortion, the root morphology and dimensions of the incisor presented no apparent signs of resorption (Fig. 12). No further root shortening occurred.

The treatment was complete after 12 months.

Six months and 1 year recalls showed complete healing of periodontal tissues and continued normal responses to vitality testing.

The patient is scheduled for long-term control.

Discussion

There are currently contrasting opinions on both the therapeutic choice for cases of dilacerated teeth and the appropriate use of terminology.

Some authors define dilacerated a dental element presenting an anomalous curvature of the root (18, 19). Others state that it must be limited to cases showing a marked angle between crown and root (3).

The anomaly in the first case would be attributed to any sort of axial modification between calcified and calcifying parts of the root during its development. In the second case, an amelo-cemental deformation would have to be specifically present.

The most commonly mentioned therapeutic solution in literature is surgical extraction and substitution with Maryland-bridge or prosthetic/implants devices (20, 21). This is most likely because of the technical difficulty involved in exposure and orthodontic alignment and the uncertain prognosis of such malformed teeth (22, 23).

Anterior tooth transplantation should be considered as an alternative solution. The advantages of this approach include immediate aesthetic improvement, use of a single and simplified surgical procedure, simple and short orthodontic therapy and the possibility of the developing root's adapting to the new position (18). Czychowska et al. demonstrated that autotransplantation of premolars to the maxillary incisor region may be a realistic treatment of missing maxillary incisors (24). Tooth transplantation represents an inherent potential for bone induction and reestablishment of a normal

alveolar process. Transplantation of premolars has its major indication in young individuals. The most successful procedure involves transplanting premolars before the root is fully formed to preserve pulp revascularization and vitality (24). The same authors reported survival and success rates observed in a study of 33 transplanted teeth examined with a mean follow-up period of 26 years (25). The survival rate was 90% while the success rate was 79%. Comparison between the transplants and the natural control teeth demonstrated no clinical and radiographic differences except for pulp obliteration. Furthermore, the patients responded favourably regarding their perception of the treatment (25). The Authors concluded that survival and success rates for teeth autotransplanted when the root is partly developed compare favourably in a long-term perspective with other treatment modalities for substituting missing teeth (25). Premolar transplants were found to be physiologically similar to natural incisors (26).

Even though transplantation cases have been presented in literature, the decision chosen was treating the impacted maxillary dilacerated incisor by surgical exposure combined with orthodontic traction because the tooth was present, the patient was growing and the root was still forming.

The main diagnostic problem is definitely the difficulty of radiological diagnosis of the exact morphology of the dilacerated tooth and predicting whether it will be possible to reposition it into the arch.

It is therefore difficult to establish the prognosis. It depends on both the seriousness and position of the dilaceration as well as the formation of the root. A dilacerated tooth with a crown-root obtuse angle, a position near the marginal crest and incomplete formation of the root has better prognosis for orthodontic traction.

Traumatically displaced tooth in children should be repositioned as early as possible, so that when root formation does resume, distortion of the root position will be minimized (2, 27). Careful planning is required to avoid any progression of the root dilaceration and resorption through orthodontic treatment (11). Some studies find the more bone that is removed during exposition, the more bone loss there will be during orthodontic traction and the possibility of causing damage to the tooth to be extruded (19, 20). These studies suggest dividing the exposition into two phases to save more bone.

The advantages of this approach include aesthetic improvement, avoid of prosthetic rehabilitation, and better periodontal results.

This case report demonstrates the quality of the results that can be achieved by treating impacted maxillary dilacerated teeth with the apically positioned flap technique followed by orthodontic treatment (28, 29).

The disadvantages described in literature of this method of uncovering impactions are: unaesthetic sequelae, increase in clinical crown length, increased width of attached tissue, gingival scarring and intrusive relapse (21). Several authors (21, 29) propose the closed-eruption technique as an alternative method to avoid

these disadvantages. These clinicians believe that the closed eruption method replicates natural tooth eruption and therefore produces the best aesthetic and periodontal results compared with the apically positioned flap technique.

Nevertheless, the decision chosen was the surgical procedure to postpone the bonding of the bracket because it was difficult to isolate the tooth from contamination by saliva and haemorrhage during surgery and because more attached gingiva was required. The position of the dilacerated tooth (the palatal surface was facing the vestibular cortical bone) could not provide an adequate quantity of attached gingiva during extrusion (5, 6, 15). In fact, one of the aims was to provide attached gingiva to prevent the muscles of the face from detaching the marginal periodontal tissue from the tooth, causing marginal bone loss, gingival recession and un-aesthetic sequelae.

Furthermore, the apically positioned flap offers the possibility to obtain the crown of the tooth to extrude free of fibrous and granulation tissues or flaps of mucosa that could oppose the orthodontic extrusive movements.

Conclusions

The factors that determined a positive outcome were: (i) the surgical technique freeing the fibrous tissue blocking eruption; (ii) use of light and constant orthodontic forces (30–40 g); (iii) the favourable crown–root angle allowing the crown to be aligned without excessive dislocation of the root.

This final aspect can only be evaluated with precision during treatment. In any case, the orthodontic-surgical option is a possible technique guaranteeing sustainable results.

References

- Proffit WR. Contemporary orthodontics. C.V. Mosby Year Book; 1993.
- Gianni E. La nuova Ortognatodonzia. Padova: Ed.Piccin; 1980.
- Odegaard J. The treatment of class I malocclusion with horizontally impacted maxillary canines. *Am J Orthod Dentofacial Orthop* 1997;111:357–65.
- Farronato GP, Santoro F, Pignanelli M. Terapia chirurgico ortodontica di denti inclusi in soggetti adulti. *Mondo Ortodontico* 1982;1:38–49.
- Kearns HP. Dilacerated incisors and congenitally displaced incisors: three case reports. *Dent Update* 1998;25:339–42.
- Farronato GP, Santoro F, Loiaconi G. Mesiodens e trattamento chirurgico-ortodontico: terapia chirurgico ortodontica. *Mondo Ortodontico* 1982;7:1–9.
- Kamat SS, Kumar GS, Raghunath V, Rekha KP. Permanent maxillary central incisor impaction: report of two cases. *Quintessence Int* 2003;34:50–2.
- Kuvvetli SS, Seymen F, Gencay K. Management of an unerupted dilacerated maxillary central incisor: a case report. *Dent Traumatol* 2007;23:257–61.
- Becker A. The orthodontic treatment of impacted teeth. London: Martin Dunitz Ltd; 1998.
- Kolokithas G, Karakasis D. Orthodontic movement of dilacerated maxillary central incisor. *Am J Orthod Dentofacial* 1979;76:310–5.
- Tanaka E, Hasegawa T, Hanaoka K, Yoneno K, Matsumoto E, Dalla-Bona D et al. Severe crowding and a dilacerated maxillary central incisor in an adolescent. *Angle Orthod* 2006;76:510–8.
- Lin YT. Treatment of an impacted dilacerated maxillary central incisor. *Am J Orthod Dentofacial Orthop* 1999;115:406–9.
- Uematsu S, Uematsu T, Furusawa K, Deguchi T, Kurihara S. Orthodontic treatment of an impacted dilacerated maxillary central incisor combined with surgical exposure and apicoectomy. *Angle Orthod* 2004;74:132–6.
- Vanarsdall RL, Corn H. Soft-tissue management of labially positioned unerupted teeth. *Am J Orthod* 1977;72:53–64.
- Vermette ME, Kokich VG, Kennedy DB. Uncovering labially impacted teeth: apically positioned flap and closed-eruption techniques. *Angle Orthod* 1995;65:23–32.
- Kokavi D, Becker A, Zilbermann Y. Surgical exposure, orthodontic movement and final tooth position as factor in periodontal breakdown of treated palatally impacted canines. *Am J Orthod Dentofacial Orthop* 1984;85:72–7.
- Crawford LB. Impacted maxillary central incisor in mixed dentition treatment. *Am J Orthod Dentofacial Orthop* 1997;76:310–5.
- Tsai TP. Surgical repositioning of an impacted dilacerated incisor in mixed dentition. *J Am Dent Assoc* 2002;133:61–6.
- Saldarriaga JR, Constanza P. Ectopic eruption and severe root resorption. *Am J Orthod Dentofacial Orthop* 2003;123:259–65.
- Archer WH. Oral and maxillo-facial surgery. Philadelphia: Saunders company; 1975.
- Hone GL. Minor Oral Surgery. 2nd ed. Bristol: Wright; 1971.
- Di Biase DD. The effects of variations in tooth morphology and position on eruption. *Dent Pract Dent Rec* 1971;22:95–108.
- McNamara T, Woolfe SN, McNamara CM. Orthodontic management of a dilacerated maxillary central incisor with an unusual sequela. *J Clin Orthod* 1998;32:293–7.
- Czochrowska EM, Stenvik A, Album B, Zachrisson BU. Autotransplantation of premolars to replace maxillary incisors: a comparison with natural incisors. *AJODO* 2000;118:592–600.
- Czochrowska EM, Stenvik A, Bjercke B, Zachrisson BU. Outcome of tooth transplantation: survival and success rates 17–41 years posttreatment. *AJODO* 2001;121:110–9.
- Czochrowska EM, Stenvik A, Zachrisson BU. The esthetic outcome of autotransplanted premolars replacing maxillary incisors. *Dent Traumatol* 2002;18:237–45.
- Agnihotri A, Marwah N, Dutta S. Dilacerated unerupted central incisor: a case report. *J Indian Soc Pedod Prev Dent* 2006;24:152–4.
- Chew MT, Ong MM. Orthodontic-surgical management of an impacted dilacerated maxillary central incisor: a clinical case report. *Pediatr Dent* 2004;26:341–4.
- Becker A, Brin I, Ben-Bassat Y. Closed-eruption surgical technique for impacted maxillary incisors: a postorthodontic periodontal evaluation. *Am J Orthod Dentofacial Orthop* 2002;122:9–14.

This document is a scanned copy of a printed document. No warranty is given about the accuracy of the copy. Users should refer to the original published version of the material.