

Management of a complicated crown-root fracture using adhesive fragment reattachment and orthodontic extrusion

CASE REPORT

Célia Tomiko Matida Hamata Saito, Marcos Heidy Guskuma, Jéssica Lemos Gulinelli, Celso Koogi Sonoda, Idelmo Rangel Garcia-Júnior, Osvaldo Magro Filho, Sônia Regina Panzarini

Department of Surgery and Integrated Clinics, Dental School Araçatuba, São Paulo State University (UNESP), Araçatuba, SP, Brazil

Correspondence to: Profa. Dra. Sônia Regina Panzarini, Departamento de Cirurgia e Clínica Integrada, Disciplina de Clínica Integrada, Faculdade de Odontologia do Campus de Araçatuba, UNESP, Rua José Bonifácio 1193, CEP: 1601-050, Araçatuba, SP, Brasil
Tel.: +55-18-3620-3240 or +55-18-3622-5693
Fax: +55 18 36363332
e-mail: panzarin@foa.unesp.br

Accepted on 17 April, 2009

Abstract – Dental trauma is more common in young patients and its sequelae may impair the establishment and accomplishment of an adequate treatment plan. This paper reports a case of complicated crown-root fracture in a young adult that was treated using adhesive tooth fragment reattachment and orthodontic root extrusion. Considering the time elapsed to follow up, the fracture extension, the amount of remaining root portion and the patient's low socioeconomic status, the treatment approach proposed for this case provided good functional and aesthetic outcomes. Clinical and radiographic results after 2 years were successful. This case report demonstrates the importance of establishing a multidisciplinary approach for a successful dental trauma management.

Dental trauma is a more common event in young patients and its sequelae may impair the establishment and accomplishment of an adequate treatment plan. Each trauma case should be evaluated on an individual basis (1).

Crown-root fractures correspond to a significant part of cases of tooth injuries and are more prevalent in the 11–18-year-old age group (2). Depending on the existence or not of pulp involvement, they may be classified respectively as complicated, which are more frequent, or non-complicated crown-root fractures (2, 3).

There are several treatment strategies for aesthetic and functional rehabilitation in cases of crown-root fracture, including mucogingival flap and adhesive reattachment of the original fragment (4), orthodontic extrusion followed by reconstruction of tooth crown with a restorative material (5), orthodontic extrusion followed by prosthetic rehabilitation (6), adhesive fragment reattachment associated to laminate veneer (7) and intentional replantation (8). Indication of the type of treatment to be used depends primarily on the bone level of fracture.

This paper reports a case of complicated crown-root fracture in a young adult treated using adhesive tooth fragment reattachment and orthodontic extrusion.

Case report

A 21-year-old female victim of motorcycle accident was referred to the Oral and Maxillofacial Traumatology and Surgery Service of the Dental School of Araçatuba (UNESP, Brazil) after receiving first-aid medical care. The patient presented with abrasions in the region of the nose and chin, soft-tissue laceration in the upper lip and a complicated crown-root fracture with pulp exposure in the maxillary left central incisor (Fig. 1). Part of the coronal fragment was in place, attached to the gingival. The incisal coronal fragment, which was the largest portion, was found at the site of accident right after the first-aid care and was maintained in saline storage until the following treatment session (Fig. 2). Periapical radiographs taken from different angulations revealed an oblique root fracture that extended approximately 2 mm intraosseous in the distal aspect. The maxillary left lateral incisor presented enamel cracks and the neighbouring teeth presented absence of clinical and radiographic findings (Fig. 3).

The emergency dental care aimed to alleviate the pain and discomfort. The coronal fragment was gently removed under local anaesthesia, the soft-tissue laceration was

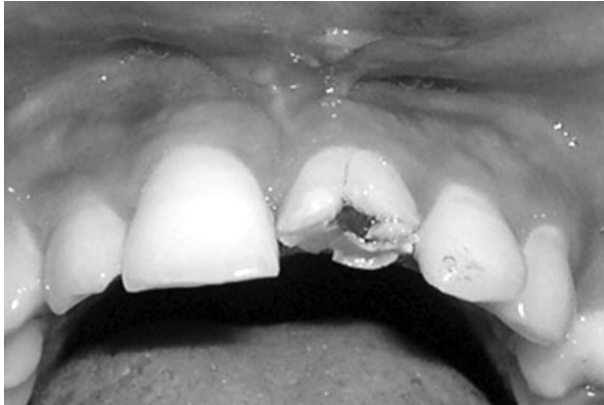

Fig. 1. Pre-operative clinical view.




Fig. 2. Incisal coronal fragment.

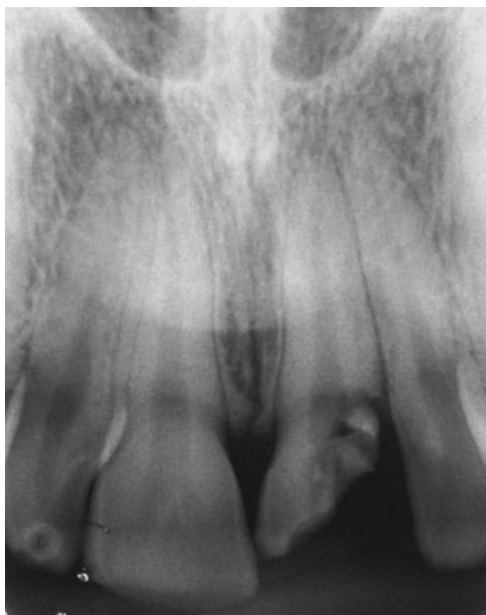

Fig. 3. Pre-operative periapical radiograph.

treated conservatively with local antiseptic solution, the coronal pulp was curetted, and the pulp chamber received a dressing with a commercially prepared antibiotic-corticosteroid product (Otosporin[®], Farmoquímica S/A, Rio de Janeiro, RJ, Brazil) and was provisionally sealed with a glass ionomer cement (Vidrion R, SS White, Rio de Janeiro, RJ, Brazil). Antibiotic therapy (amoxicillin 500 mg, three times/day; Eurofarma, São Paulo, SP, Brazil) was started and maintained for 7 days. An anti-inflammatory (Potassium diclofenac 50 mg every 8 h for 3 days; Novartis Biociências SA, São Paulo, SP, Brazil) and an analgesic (Paracetamol 750 mg every 6 h in case of pain; Aventis Pharma Ltd, Suzano, SP, Brazil) were also prescribed.

Two days after the emergency visit, an exploratory surgery showed that the fracture complicated crown-root extended deeply subgingivally, invading the biological width in the distal aspect and reaching 2 mm below the bone crest (Fig. 4). In the same session, the coronal fragment maintained in saline storage was reattached to the root remnant using an adhesive restorative technique with a total-etch adhesive system (Single Bond; 3M/ESPE, St Paul, MN, USA) and a light-cured microhybrid composite resin (TPH, Dentsply Ind. e Com. Ltda, Petrópolis, RJ, Brazil). The restoration of the fractured crown was completed with composite resin (Fig. 5). Due to the loss of tooth structure, a bevel was made on the remaining root portion to increase fragment retention. An adequate adaptation of the incisal fragment to the

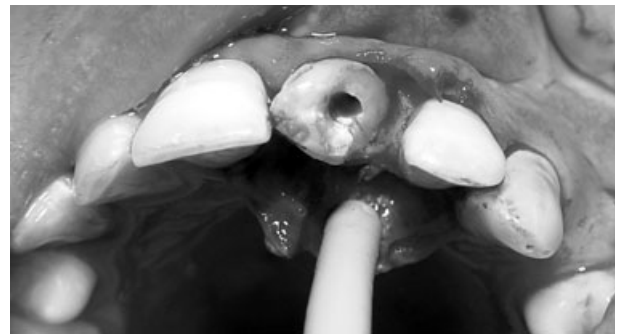

Fig. 4. Clinical aspect during the exploratory surgery showing the extension of the complicated crown-root fracture, invading the biological width in the distal aspect.

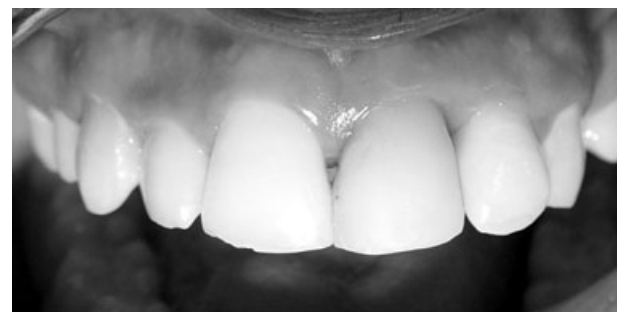

Fig. 5. Clinical aspect after adhesive coronal fragment reattachment.

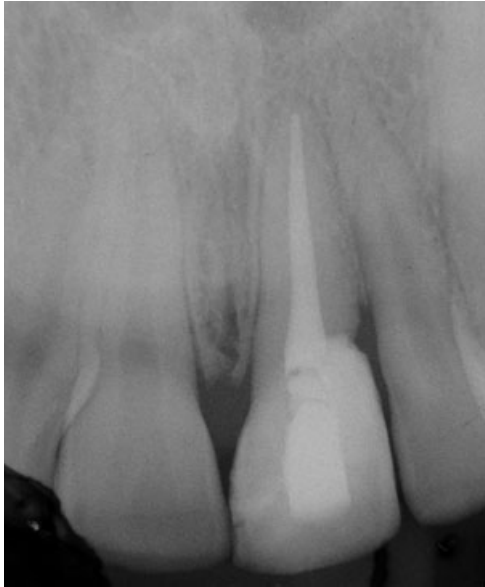


Fig. 6. Periapical radiograph after adhesive coronal fragment reattachment.

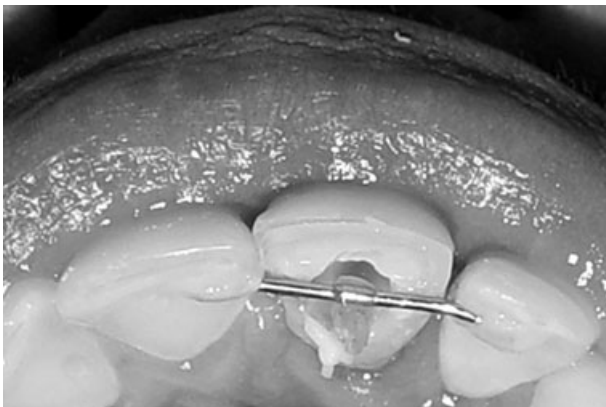

Fig. 7. Fixed appliance used for orthodontic extrusion installed and activated.

distal aspect of the apical fragment was not possible due to the invasion of the biological width (Fig. 6). Endodontic therapy started with removal of pulp tissue from the remaining root portion under copious 1% sodium hypochlorite irrigation (Milton solution, Asfer-Industria Quimica Ltda, São Caetano do Sul, SP, Brazil), instrumentation and placement of a calcium hydroxide-based intracanal dressing for 30 days. Definitive root canal obturation was performed thereafter with lateral condensation of gutta-percha points (Tanari; Tanariman Industrial Ltda., Manacapuru, AM, Brazil) and Sealapex root canal sealer (Kerr Corp., Orange, CA, USA), leaving the coronal third unfilled.

Orthodontic extrusion was performed using a fixed appliance to re-establish the biological width. A 0.028-inch round stainless steel orthodontic wire (Dental Morelli, Sorocaba, SP, Brazil) was fixed with light-cured composite resin to the palatal surface of the maxillary

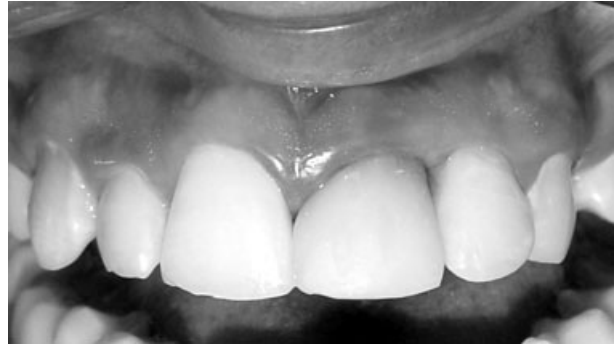

Fig. 8. Clinical view after 24 months of follow up.

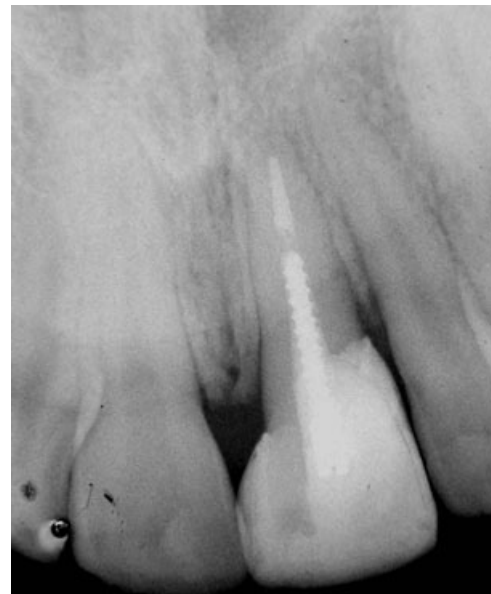

Fig. 9. Radiographic aspect after 24 months of follow up.

right central incisor and maxillary left lateral incisor, at the incisal third, to provide the necessary anchorage for tooth movement (Fig. 7). A 0.012-inch stainless steel wire (Dental Morelli) was bent to form a 2-mm diameter loop with a 4-mm radicular extension, which was further roughened with diamond disks to provide retention and was cemented with glass ionomer cement (Vidrion R, SS White) in the coronal root canal third of the fractured tooth. Next, a 1/8 diameter orthodontic elastic was placed through the coronal loop and tied to the palatal bow fixed between the neighbouring teeth. The elastic string was changed once a week. Orthodontic extrusion was terminated when all root margins were exposed, which was achieved within 21 days. After reestablishment of the biological width, the tooth was splinted with composite resin (TPH, Dentsply) for 12 weeks and a mucoperiosteal flap repositioning surgery was performed in the area surrounding the extruded tooth. The treatment was completed with post space preparation and cementation of a metallic radicular post (FKG Dentaire, La-Cheaux-de Fonds, Switzerland) to provide resistance to the fractured tooth. The palatal access was

sealed with composite resin and tooth/composite surfaces were repaired with composite resin, polished and adjusted for occlusal interferences.

Clinical and radiographic follow up after 24 months showed a good adaptation of the tooth fragment/composite resin restoration, absence of radiographic signs of root resorption and absence of painful symptomatology (Figs 8 and 9).

Discussion

One of the determinant factors for the functional and aesthetic success in the management of complicated crown-root fractures is the adoption of a multidisciplinary approach involving surgery, endodontics, periodontics and prosthodontics (6). The literature shows that coronal restoration of teeth with crown-root fracture is usually challenging, especially when the fracture extends below the bone level (9), as occurred in the present case. Different treatment strategies have been proposed for cases of complicated crown-root fracture including surgical exposure of the fractured surface, orthodontic or surgical extrusion of the apical fragment, intentional replantation and tooth extraction in more severe cases (1, 4–8, 10, 11).

Orthodontic extrusion was the treatment of choice to re-establish the biological width in this case because it is considered a safe procedure with respect to the occurrence of root resorption and does not involve loss of periodontal support or bone tissue of the surrounding teeth, which favours aesthetics (12–14).

Although adhesive fragment reattachment cannot be considered a durable procedure for the management of extensive fractures (5), this technique offers an effective and conservative treatment option in some cases because this technique shortens the operative time and improves the reproduction of tooth colour, shape and contour (15).

On the other hand, the reconstruction of a fractured tooth with composite resin is a good alternative for young patients, having the advantage of preserving the remaining root portion and providing an immediate resolution to the case, which is particularly important for patients that cannot afford a prosthetic rehabilitation (16). In the present case, composite resin reconstruction was associated with tooth fragment reattachment. The reduced resistance of the restored tooth to the masticatory efforts was compensated by the cementation of an intracanal retainer. Although the use of the tooth fragment reattachment technique is not common in these cases, it is important that dentists warn their patients on the importance of collecting fragments of teeth fractured due to traumatic injuries and instruct them on the use of adequate wet storage medium, so that the fragments can be suitable for reattachment (4).

Considering the time elapsed to follow up, the fracture extension, the amount of remaining root portion and

patient's age, the treatment proposed for this case, combining adhesive tooth fragment reattachment and orthodontic root extrusion, provided good functional and aesthetic outcomes. Clinical and radiographic results after 2 years were successful. This case report demonstrates the importance of establishing a multidisciplinary approach for a successful management of dental trauma.

References

- Canoglu H, Gungor HC, Cehreli ZC. Management of cervical root fracture using orthodontic extrusion and crown reattachment: a case report. *Oral Surg Oral Med Oral Pathol Oral Radiol Endod* 2007;104:46–9.
- Castro JCM, Poi WR, Manfrin TM, Zina LG. Analysis of the crown fractures and crown-root fractures due to dental trauma assisted by the Integrated Clinic from 1992 to 2002. *Dent Traumatol* 2005;21:121–6.
- Andreasen FM. Reattachment of subgingivally fractured central incisor with an open apex. *Dent Traumatol* 2007;23:263–4.
- Eden E, Yanar SC, Sönmez S. Reattachment of subgingivally fractured central incisor with an open apex. *Dent Traumatol* 2007;23:184–9.
- Emerich-Poplatek K, Sawicki L, Bodal M, Adamowicz-Klepalska B. Forced eruption after crown/root fracture with a simple and aesthetic method using the fractured crown. *Dent Traumatol* 2005;21:165–9.
- Poi WR, de Cardoso L, de Castro JC, Cintra LT, Gulinelli JL, de Lazari JA. Multidisciplinary treatment approach for crown fracture and crown-root fracture – a case report. *Dent Traumatol* 2007;23:51–5.
- Nandlal B, Daneswari V. Restoring biological width in crown-root fracture: a periodontal concern. *J Indian Soc Pedod Prev Dent* 2007;25(Suppl):S20–4.
- Wang Z, Heffernan M, Vann WF Jr. Management of a complicated crown-root fracture in a young permanent incisor using intentional replantation. *Dent Traumatol* 2000;24:100–3.
- Koyuturk AE, Malkoc S. Orthodontic extrusion of subgingivally fractured incisor before restoration. A case report: 3-years follow-up. *Dent Traumatol* 2005;21:174–8.
- Heda CB, Heda AA, Kulkarni SS. A multi-disciplinary approach in the management of a traumatized tooth with complicated crown-root fracture: A case report. *J Indian Soc Pedod Prev Dent* 2006;24:197–200.
- Villat C, Machtou P, Naulin-Ifi C. Multidisciplinary approach to the immediate esthetic repair and long-term treatment of an oblique crown-root fracture. *Dent Traumatol* 2004;20:56–60.
- Bach N, Baylard JF, Voyer R. Orthodontic extrusion: periodontal considerations and applications. *J Can Dent Assoc* 2004;70:775–80.
- Benenati FW, Simon JHS. Orthodontic root extrusion: its rationale and uses. *Gent Dent* 1986;34:285–9.
- Heithersay GS. Combined endodontic-orthodontic treatment of transverse root fractures in the region of the alveolar crest. *Oral Surg Oral Med Oral Pathol* 1973;36:404–15.
- Cengiz SB, Kocadereli I, Gungor HC, Altay N. Adhesive fragment reattachment after orthodontic extrusion: a case report. *Dent Traumatol* 2005;21:60–4.
- Panduric V, Gabric D, Negovetic-Mandic V. Immediate post-traumatic upper incisor reconstruction using composite resin materials. *Dent Traumatol* 2008;24:108–11.

This document is a scanned copy of a printed document. No warranty is given about the accuracy of the copy. Users should refer to the original published version of the material.