

# Patients' perceptions of recovery after surgical exposure of impacted maxillary teeth treated with an open-eruption surgical-orthodontic technique

S. Chaushu\*, A. Becker\*, R. Zeltser\*\*, N. Vasker\* and G. Chaushu\*\*\*

Departments of \*Orthodontics and \*\*Oral and Maxillofacial Surgery, Hebrew University–Hadassah School of Dental Medicine, Jerusalem and \*\*\*Oral and Maxillofacial Surgery, The Tel Aviv Sourasky Medical Centre and School of Dental Medicine, Tel Aviv University, Tel Aviv, Israel

**SUMMARY** This study assessed patient perceptions of immediate post-operative recovery after the surgical exposure of impacted maxillary teeth with an open-eruption technique. Thirty patients (24 females and six males) underwent surgical exposure of 39 impacted maxillary teeth using this technique. After surgery the patients were contacted by telephone daily for 7 days, to complete a health-related quality of life (HRQOL) questionnaire, which assessed their perception of recovery in four main areas: pain, oral function, general activity, and other symptoms.

Severe pain was reported by 30 per cent of the patients in the first post-operative day (POD 1), which declined to 6.7 per cent by POD 6. Consumption of analgesics declined gradually over the post-operative days (POD 1: 80 per cent, POD 7: 20 per cent). Difficulty in eating required 5 days to reach minimal levels; enjoying everyday food, 2.5 days; school attendance, limitations in daily routine, swallowing, and speech, 2 days each; swelling, bad taste/smell, 1.5 days each; within 1 day all other measures attained minimal levels. The need for bone removal during the exposure resulted in delayed recovery with regard to the ability to eat. In general, females reported delayed recovery for pain.

The present data may serve as basic guidelines against which future studies which assess post-operative management of patients after surgical exposure of impacted teeth by an open-eruption technique may be compared.

## Introduction

The final outcome of treatment of an impacted maxillary tooth is largely dependent on the ability of the orthodontist, oral surgeon, and the patient to co-operate (Becker, 1998). In order to fully comprehend the surgical procedure and then sign an informed consent document, which has become mandatory in dental practice, the patient must be provided with the maximum amount of relevant information (Troidl *et al.*, 1987; Fraser, 1993; Morton, 1996; Shugars *et al.*, 1996; Savin and Ogden, 1997; Conrad *et al.*, 1999).

Impacted teeth may be exposed by the removal or repositioning of the soft tissue that envelops them, to leave them in full view at the end of the surgical procedure. This has been termed 'open-eruption' exposure (Becker, 1998). The main advantages of this technique are that the orthodontist's presence in the operating theatre is unnecessary, in the case of failure attachment bonding may be performed at any subsequent convenient time. Rebonding of a failed attachment on the impacted tooth needs no additional surgery. However, several disadvantages have been described, including the need for wide bone exposure and increased discomfort, the risk of infection, and a bad taste and smell in the mouth after surgery (Becker, 1998). These

claims are founded on clinical experience, which has never been challenged in a prospective study. It is inadmissible for patients of the third millennium to be presented with advice that is based on assumption, when they are entitled to a higher level of evidence-based knowledge and understanding before consenting to treatment. The term 'quality of life' has thus been increasingly used in the last decade in a large number of clinical investigations in different areas. Such investigations do not focus merely on the clinical outcomes of a procedure, but now include additional parameters designed to describe the patient's own perception of recovery in relation to clinical outcomes (Troidl *et al.*, 1987; Slevin *et al.*, 1988; Reisine and Weber, 1989; Fraser, 1993; Morton, 1996; Shugars *et al.*, 1996; Savin and Ogden, 1997; Conrad *et al.*, 1999).

Quality of life studies regarding the surgical removal of third molars have been widely published (Shugars *et al.*, 1996; Savin and Ogden, 1997; Conrad *et al.*, 1999), while a review of the English literature revealed no parallel study focusing on the immediate post-operative outcomes and patients' perceptions of recovery of surgical exposure of impacted maxillary teeth with the widely used open-eruption technique. Surgical removal of third molars and surgical exposure of impacted teeth

treated with an open-eruption surgical-orthodontic technique involve a process of wound healing by secondary intention. It was felt to be beneficial in the study of post-operative sequelae of surgery to impacted teeth to evaluate this type of surgical exposure by using a third molar surgery-related methodology for understanding health-related quality of life (HRQOL) issues.

This prospective study was therefore designed to assess patient perceptions of immediate post-operative recovery after the surgical exposure of impacted maxillary teeth treated with an open-eruption surgical-orthodontic technique.

### Subjects and methods

Two HRQOL instruments (Savin and Ogden, 1997; Conrad *et al.*, 1999) were combined for use in this study (see Appendix).

Patients who had been scheduled for surgical exposure of impacted maxillary incisors and canines treated with an open-eruption surgical-orthodontic technique were asked to enrol in a prospective clinical study conducted in four clinics over a 12 month period beginning in December 2001. All patients in the sample were aged between 12 and 20 years and in good general health.

On the day of surgery, after consenting to participate in the study, baseline data (age, gender, orthodontist's name, surgeon's name, tooth number, tooth location buccal/palatal, and height of impaction apical/middle/cervical) were recorded.

Three oral and maxillofacial surgeons performed the surgery according to a standard protocol which included local anaesthesia and tooth exposure (Becker, 1998). No flaps were raised. The open-eruption technique employed the use of electrosurgery to remove the fibrous mucosa covering the impacted tooth. Rotatory instruments were used when appropriate. A periodontal pack (Coe-Pak, GC America Inc, Illinois, USA) was placed at the end of the procedure to prevent rehealing over the tooth. Two 3/0 silk sutures were placed over the pack to prevent premature dislodgement. Subsequently, the surgeon recorded a description of the surgery, including the duration of the surgical procedure and the need for bone removal. The sutures and the pack were removed at the follow-up visit 1 week later.

Bonding of a small eyelet attachment threaded with a steel ligature wire on the impacted tooth was performed by the orthodontist 1 week following surgical exposure. Light orthodontic traction maintained on the ligature wire was initiated 1 week after surgery, with the aim of bringing the tooth to its correct place in the arch.

After surgery the patients received the modified HRQOL instrument and were contacted by telephone for 7 days, to confirm its daily completion. The HRQOL instrument assessed patient perception of recovery in

four main areas: pain, oral function, general activity, and other symptoms. Pain was graded according to severity and the need for analgesic consumption. Oral function dealt specifically with swallowing, mouth opening, ability to eat and enjoy ordinary food, and speech. General activity measures targeted the ability to participate in routine daily activities, sleeping, and school attendance. Other symptoms included bleeding, bruising, swelling, food accumulation and stagnation in surgical sites, the presence of a bad taste or smell, and malaise. The patients were not required to return for post-surgical visits, but were encouraged to do so if symptoms worsened after the first few post-operative days.

The degree of pain was assessed on a visual analogue scale of 1–10, with 1–3 referring to mild pain, 4–7 moderate pain, and 8–10 severe pain. The remaining parameters were assessed on a five-point scale: 1, not at all; 2, very little; 3, some; 4, quite a lot; 5, very much.

Descriptive statistics were used to summarize separate 'time for recovery' for each of the following parameters: gender, duration of surgery less than 30 minutes versus 30 minutes or longer, the impacted tooth location (buccal/palatal), height of impaction (apical/middle/cervical), and the need for bone removal during exposure.

The time for recovery was equated with the median number of days to reach very little/not at all (1–2/5) and mild pain (1–3/10), and this was assessed for each of the parameters examined.

The influence of each predictor variable on recovery time was assessed using Fisher's exact test, which is a multiple comparisons statistical analysis, with  $P < 0.05$  taken as the minimum criterion of significance.

### Results

Thirty patients (24 females and six males) underwent surgical exposure of 39 impacted maxillary teeth treated with an open-eruption surgical-orthodontic technique. Six patients were treated for bilateral impactions. The mean age of the patients was  $14.8 \pm 2.7$  years. Two orthodontists and four maxillofacial surgeons participated in the study. There were 33 impacted maxillary canines and six impacted maxillary incisors. Twenty-four teeth were palatally impacted, 14 buccally, and one was bucco-lingual in the middle of the alveolar crest. Regarding the height of impaction, 10 teeth were cervically, 18 middle, and 11 apically located.

The mean duration of surgery was  $44.6 \pm 15.2$  minutes. For 20 of the 30 patients, this was 30 minutes or greater. In 23 patients there was a need for bone removal.

Measures of pain, oral function, interference with daily activity, and other symptoms were reported as the percentage of patients who had substantial impairment (score 4–10 for pain, and score 4–5 for other symptoms).

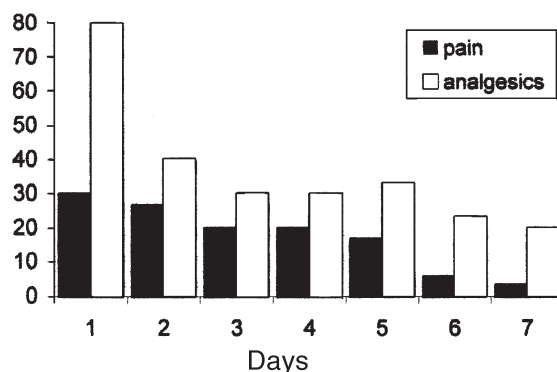
### Pain

On the first post-operative day (POD 1), 30.0 per cent of the patients reported that they experienced their worst pain and described this as severe at some point in the day; by POD 6 that number had decreased to 6.7 per cent (Figure 1). Analgesic consumption declined gradually over the post-operative days (POD 1: 80 per cent; POD 7: 20 per cent).

### Oral function

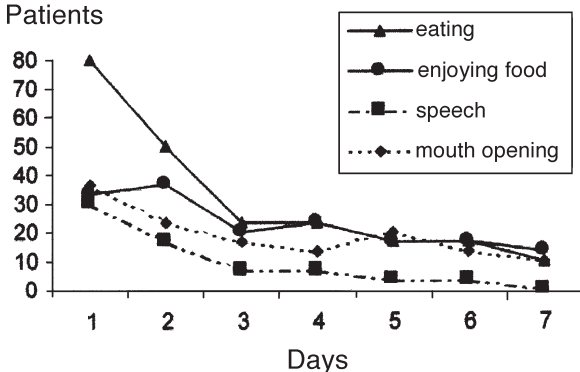
On POD 1, the ability to eat everyday food was most affected (80.0 per cent), followed by the ability to enjoy everyday food (33.3 per cent), speech (30.0 per cent), swallowing (26.7 per cent), and mouth opening (20.0 per cent) (Figure 2). Improvement in oral function was evident by POD 7 (ability to enjoy everyday food: 13.3 per cent; ability to eat everyday food: 10 per cent; swallowing: 6.7 per cent; mouth opening: 6.7 per cent; speech: 0 per cent).

% Patients



**Figure 1** The proportion of patients reporting pain as severe (score 8–10/10) and taking analgesics, according to day post-surgery.

% Patients



**Figure 2** The proportion of patients reporting considerable difficulty in eating, speech, mouth opening, and ability to enjoy regular food (score 4–5/5), according to day post-surgery.

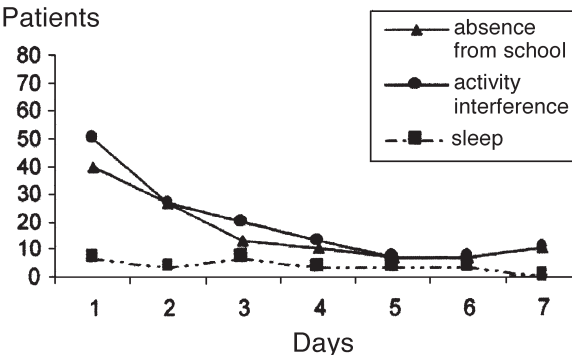
### General activity

On POD 1, 40 per cent of patients had been absent from school and 23.3 per cent of respondents reported substantial interference in daily activity (Figure 3). The limitations in daily routine and school attendance fell to 10.0 per cent (three individuals) by POD 4. Sleeping was minimally affected, only being experienced on POD 1 (6.7 per cent).

### Other symptoms

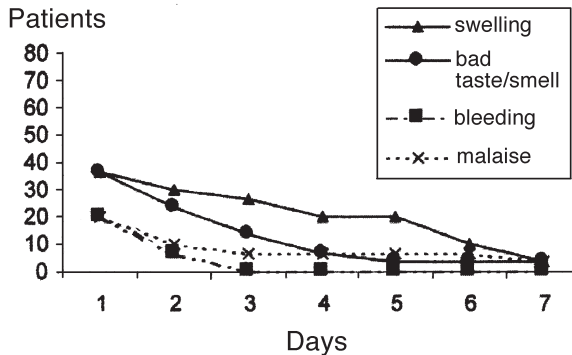
The presence of a bad taste/smell was the major post-operative distressing symptom. It was reportedly the greatest on POD 1 (36.7 per cent), diminishing gradually over the study period until POD 4 (6.7 per cent). Food accumulation (23.3 per cent on POD 1) decreased to 6.7 per cent by POD 7. Swelling peaked by POD 1 (23.3 per cent), but had largely resolved by POD 3 (6.7 per cent). Bleeding and malaise were reported by 20.0 per cent of the patients, but were of major concern only during the first day after surgery (Figure 4). Bruising was minimally evident to patients in the recovery period.

% Patients



**Figure 3** The proportion of patients reporting absence from school and marked interference with normal activity and sleep (score 4–5/5), according to day post-surgery.

% Patients



**Figure 4** The proportion of patients reporting considerable swelling, bad taste/smell, bleeding, and malaise (score 4–5/5), according to day post-surgery.

### Time to recovery

The ability to return to eating everyday food required 5 days, followed by pain (4.5 days), the ability to enjoy everyday food (2.5 days), school attendance, limitations in daily routine, analgesic consumption, swallowing, and speech (2 days each), swelling, bad taste/smell (1.5 days); within 1 day all other measures attained minimal levels (Figure 5).

The impact of each predictor variable on the time to recovery was assessed. Recovery did not differ significantly for tooth location, height of impaction, or surgery time. The need for bone removal and gender were the only significant predictor variables. Delayed recovery was evident for those in which bone removal had been performed with regard to the ability to eat (POD 6 versus POD 3,  $P=0.05$ ). Females reported delayed recovery regarding pain (POD 5 versus POD 2.5,  $P=0.02$ ).

### Discussion

This prospective study aimed to overcome the lack of subjective information regarding the patient's well-being in the immediate post-operative period following surgical exposure of impacted maxillary incisors treated with an open-eruption surgical-orthodontic technique. A similar wound healing process is involved in both the surgical exposure of impacted maxillary incisors treated with an open-eruption surgical-orthodontic technique and the surgical removal of third molars—healing by secondary intention. As this latter procedure has already been researched and documented in this context, it was felt justified to use it for baseline comparisons with the procedure being examined in this investigation (Conrad *et al.*, 1999). However, the present group of patients differed from those in third molar studies with regard to age. The patients included in the present investigation were

younger than those in earlier third molar extraction studies.

The dynamics of worst pain (maximal pain on POD 1 and significant improvement by POD 6) are similar in both surgical interventions, yet third molar surgery would appear to be much more traumatic, as it takes up to 9 days to reach minimum levels (Conrad *et al.*, 1999).

As a whole, the present group required a median of 5 days to overcome eating difficulties, 2.5 days to enjoy everyday food, 2 days for speech and swallowing, and 1 day for mouth opening, affecting 80.0, 33.3, 30.0, 26.7, and 20.0 per cent of the study population, respectively. After third molar surgery, difficulty in eating lasted for 6 days and in speech for 2 days, affecting similarly large parts of the study population (85 and 37.5 per cent, respectively). In contrast, mouth opening difficulties lasted for 5 days and affected 78.5 per cent of the third molar extraction sample (Conrad *et al.*, 1999). Mouth opening was less affected in the present study due to the anatomy of the area involved. No muscle involved in mandibular movement was severed, leaving almost no ill-effects on mouth opening.

Limitations in daily activity and school attendance only returned to normal by POD 4 in the present study. Comparing this data with third molar surgery (Conrad *et al.*, 1999) shows that working (older) patients reported better dynamics for resumption of daily activity and a return to work, POD 3, despite the more traumatic nature of the surgical intervention. The younger patients in the present study who missed an additional day from school may have had other reasons than recovery from surgery! Sleeping was minimally affected for both surgical exposure of impacted maxillary incisors treated with an open-eruption surgical-orthodontic technique and for third molar surgery.

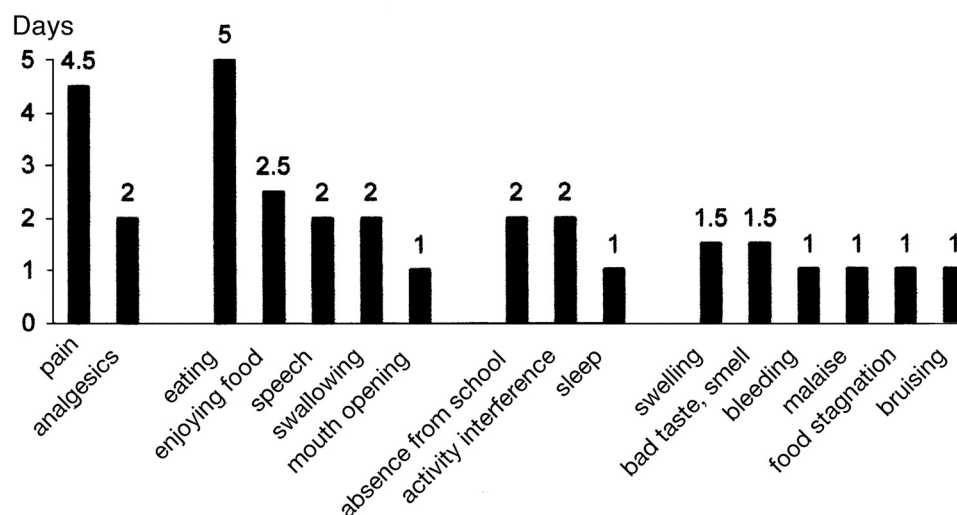


Figure 5 The recovery time for each of the parameters studied in the entire group of patients.

Swelling peaked in the present study by POD 1, resolving by POD 6 and affected only 46.6 per cent of the study group. In third molar surgery, the peak was reached by POD 2 and resolved by POD 5, and affected 61 per cent of the study group (Conrad *et al.*, 1999). The fact that third molar surgery is more traumatic and involves a different anatomical area might explain such differences. Malaise, bleeding, and bruising were not common findings for either of these surgical procedures. The presence of a bad taste/smell was considered minimal after a median of 1.5 days, although it affected 43.3 per cent of the present sample. Food accumulation at the surgical site was 23.3 per cent over the entire follow-up period. Both these recovery factors were regarded as a major concern after third molar surgery, taking 7 days to reach acceptable levels. Healing by secondary intention in both procedures may explain the results, which are more severe after third molar surgery.

In general, while the adverse effects in the present study subsided after 5 days, in third molar surgery they frequently persisted beyond 1 week (Savin and Ogden, 1997; Conrad *et al.*, 1999).

The need for bone removal resulted in delayed recovery with regard to ability to eat. It could be speculated that a palatally located procedure might be responsible for the delayed recovery in relation to eating. In addition, females reported delayed recovery for pain. This result is in agreement with previous studies suggesting that females report more severe levels of pain, more frequent pain, and pain of a longer duration compared with males (Unruh, 1996; Dao and LeResche, 2000).

## Conclusions

The present study describes, for the first time, data characterizing recovery after surgical exposure of impacted maxillary teeth treated with an open-eruption surgical-orthodontic technique from the patient's perspective. The data may serve as a basic guideline against which future investigations evaluating the efficacy of pre-operative steroids, analgesics, mouth rinses, etc., can be referred.

It may be concluded that:

1. patients should expect, in general, recovery within 5 days after surgical exposure of impacted maxillary teeth treated with an open-eruption surgical-orthodontic technique;
2. teenagers may absent themselves from school for 4 days;
3. the need for bone removal will result in a prolonged period of inability to eat and females will report a prolonged period of pain;
4. additional and larger HRQOL studies should be devoted to understanding recovery following surgical exposure of impacted maxillary teeth.

## Address for correspondence

Stella Chaushu  
Department of Orthodontics  
Hebrew University–Hadassah School of Dental Medicine  
P. O. Box 12272  
Jerusalem 91120  
Israel

## Acknowledgements

The authors wish to thank Drs Dov Kishinovsky and Robert Miller for having referred several of their patients for inclusion in this study.

## References

- Becker A 1998 The orthodontic treatment of impacted teeth. Martin Dunitz, London
- Conrad S M, Blakey G H, Shugars D A, Marciani R D, Philips C, White Jr R P 1999 Patient's perception of recovery after third molar surgery. *Journal of Oral and Maxillofacial Surgery* 57: 1288–1294
- Dao T T, LeResche L 2000 Gender differences in pain. *Journal of Orofacial Pain* 14: 169–184
- Fraser S C A 1993 Quality of life measurement in surgical practice. *British Journal of Surgery* 80: 163–169
- Morton R P 1996 Quality of life assessment: integral to clinical practice. *Clinical Otolaryngology* 21: 1–2
- Reisine S T, Weber J 1989 The effects of temporomandibular joint disorders on patient's quality of life. *Community Dental Health* 6: 257–270
- Savin J, Ogden G R 1997 Third molar surgery—a preliminary report on aspects affecting quality of life in the early post-operative period. *British Journal of Oral and Maxillofacial Surgery* 35: 246–253
- Shugars D A, Benson K, White Jr R P, Simpson K N, Bader J D 1996 Developing a measure of patient perception of short-term outcomes of third molar surgery. *Journal of Oral and Maxillofacial Surgery* 54: 1402–1408
- Slevin M L, Plant H, Lynch D, Drinkwater J, Gregory W M 1988 Who should measure quality of life, the doctor or the patient? *British Journal of Cancer* 57: 109–112
- Troidl H, Kusche J, Vestweber K H, Eypasc E, Koeppen L, Bouillon B 1987 Quality of life: an important endpoint both in surgical practice and research. *Journal of Chronic Diseases* 40: 523–528
- Unruh A M 1996 Gender variations in clinical pain experience. *Pain* 65: 123–167



## Appendix

### Surgical exposure questionnaire

In order to improve the quality of care we provide for our patients, it is important for us to know how the surgical exposure has affected you. We ask you to take a few moments to complete this survey form. Everyday you will be called on the telephone and asked to repeat this. Please choose the number which corresponds most closely to your assessment over the past 24 hours:

1. Rate the worst pain you have felt during the past 24 hours on a scale from 1 to 10 (1 = not at all; 10 = very much).
2. Have you taken any medication to relieve pain today? (0 = no; 1 = yes).

For the remaining questions, please use the following system: 1 = not at all; 2 = very little; 3 = a little; 4 = quite a lot; 5 = very much.

3. Has it been difficult to swallow today?
4. Has it been difficult to open your mouth today?

5. Were there any foods you could not eat today?
6. Have you enjoyed your food today?
7. Has speech been difficult today?
8. Was it difficult to sleep last night?
9. Have you missed school/work today?
10. Has it been difficult to continue your daily activities today?
11. Has there been any swelling today?
12. Has there been bruising today?
13. Has there been bleeding today?
14. Has there been any malaise today?
15. Have you had a bad taste or smell today?
16. Has there been any food debris in the operation area today?

Reprinted from the American Journal of Orthodontics and Dentofacial Orthopedics, 125(6), Chaushu G *et al.*, Patients' perceptions of recovery after exposure of impacted teeth with a closed-eruption technique, pp. 690–696. © 2004 with permission from American Association of Orthodontists.

Copyright of European Journal of Orthodontics is the property of Oxford University Press / UK and its content may not be copied or emailed to multiple sites or posted to a listserv without the copyright holder's express written permission. However, users may print, download, or email articles for individual use.