

Sagittal airway dimensions following maxillary protraction: a pilot study

Korkmaz Sayınsu, Fulya Isik and Tülin Arun

Faculty of Dentistry, Yeditepe University, Istanbul, Turkey

SUMMARY The relationship between changes in the position of the maxillary structures caused by maxillary protraction therapy and airway dimensions have not been investigated as comprehensively as the accompanying skeletal changes. The purpose of this study was to examine the effects of rapid palatal expansion (RPE) used in conjunction with maxillary protraction headgear on the sagittal dimension of the airway.

The treatment sample consisted of 19 Class III patients (12 girls, 7 boys) with a mean age of 10.51 ± 1.15 years, presenting with maxillary retrognathism. A cap splint type rapid palatal expander that had hooks between the upper lateral and canine teeth was used intraorally, and a Petit type facemask device extraorally, for an average of 6.78 ± 0.93 months. Pre- and post-treatment cephalometric radiographs were evaluated.

The results of the study revealed that point A moved anteriorly. The palatal plane showed a counter-clockwise rotation matched by the clockwise rotation of the mandible and an accompanying decrease in SNB angle. The vertical parameters showed a statistically significant increase. The head was in a more extensive position in relation to the cervical vertebrae. The nasopharyngeal airway measurements (PNS–ad1, PNS–ad2) showed an increase of 2.71 ± 3.35 and 3.03 ± 2.37 mm, respectively. These results demonstrated that limited maxillary widening together with protraction of the maxilla, improve nasopharyngeal but not oropharyngeal airway dimensions in the short term.

Introduction

The skeletal and dentoalveolar effects of orthopaedic treatment in subjects with Class III malocclusions with maxillary retrognathia, have been well documented in the orthodontic literature. Maxillary skeletal protraction, forward movement of the maxillary dentition, counter-clockwise rotation of the palatal plane, labial tipping of the maxillary incisors, inhibition of anterior mandibular growth, augmentation of face height, clockwise rotation of the mandible and lingual tipping of the lower incisors have all been shown to take place when treating growing skeletal Class III patients with a facemask (Ishii *et al.*, 1987; Mermigos *et al.*, 1990; Delaire, 1997; Nartallo-Turley and Turley, 1998; Baccetti *et al.*, 1998, 2000; da Silva Filho *et al.*, 1998; Macdonald *et al.*, 1999; Jäger *et al.*, 2001; Turley, 2002).

Animal experiments have shown that the entire maxilla is displaced anteriorly, and not only point A. Furthermore, the significant effects of the facemask were seen as posteriorly as the zygomatico-temporal suture (Kambara, 1977; Nanda, 1978; Jackson *et al.*, 1979). The use of rapid palatal expansion (RPE) is postulated to disarticulate the maxillary sutures and allow more efficient forward protraction of the maxilla (McNamara, 1987; Turley, 1988, 1996). The relationship between these extreme changes in the position of the maxillary structures and the airway dimensions has not been investigated as comprehensively as the skeletal

changes. Severe maxillary hypoplasia seen in craniofacial anomalies has been suggested to constrict the upper airway, including the nasal cavity and velopharynx (Handler, 1985; Hui *et al.*, 1998). The positive effect of midface distraction carried out to alleviate upper airway obstruction in midface hypoplasia seen with achondroplasia has recently been reported (Elwood *et al.*, 2003). The change in respiratory function induced by RPE has also been documented (Basciftci *et al.*, 2002; Doruk *et al.*, 2004). The effects of a maxillary protraction appliance used in combination with a chin cap have been shown to alter the upper airway dimension during maxillary protraction (Hiyama *et al.*, 2002). The purpose of this study was to examine the effect of RPE and maxillary protraction headgear on the sagittal dimensions of the upper airway.

Materials and methods

The material for this retrospective study consisted of 38 lateral cephalometric films obtained from 19 Class III patients with maxillary retrognathism from a university clinic. All the patients were between PP₂ and MP₃ cap developmental stages at the beginning of the treatment period. The mean ages for girls ($n = 12$) and boys ($n = 7$) were 10.50 ± 0.96 and 10.54 ± 1.51 , respectively. The patients were included in the study based on the following criteria: (1) The presence of a skeletal Class III malocclusion

with maxillary skeletal retrusion, (2) No other congenital anomalies or endocrine problems, (3) An anterior crossbite with a Class III molar relationship, and (4) No mandibular displacement.

An acrylic cap splint type rapid palatal expander (A0620-09, Leone, Firenze, Italy), that had hooks between the upper lateral incisors and canines, was fabricated for each patient and cemented with fluoride releasing glass ionomer cement (Unitek Multi-Cure Glass Ionomer Band Cement, 3M-Unitek, Monrovia, California, USA) (Figure 1). Treatment started with one week of palatal expansion for the purpose of sutural disarticulation. The palatal screw was activated twice a day for seven days. At the end of day 7 protraction therapy was commenced. The facemask utilized in the study was a Petit type device (Ormco Corp., Glendora, California, USA) with bilateral forces set to 600–800 g. The direction of the elastics was approximately 30 degrees below the occlusal plane, as recommended in the literature (Itoh *et al.*, 1985; Roberts and Subtelny, 1988; Ngan *et al.*, 1996) (Figure 2). The patients were instructed to wear the appliance for at least 16 hours per day. The mean and standard deviation of treatment time was 6.78 ± 0.93 months.

Lateral cephalometric films, in natural head posture, were taken at the start and end of protraction. All the radiographs were taken with Trophy Ortho Slice 1000 C (Asahi Roentgen Ind. Co. Ltd, Kyoto, Japan) and were scanned at 300 dpi with an Epson Expression 1680 Pro scanner (Seiko Epson Corp., Nagano-Ken, Japan) into Dolphin Imaging Software 9.0 (Los Angeles, California, USA). The skeletal and dental parameters were calculated using the Dolphin Imaging software program, whereas head posture and sagittal airway measurements were traced, measured and registered by hand using conventional methods. The skeletal changes were assessed by SN–GoMe angle, ANSMe/NMe ratio, NP–A distance, maxillary depth angle, maxillary height angle, SNA angle, SNB angle and ANB angle. The dental changes were evaluated by U1–SN angle, L1–MP angle, SN–PP angle and SN–OP angle. The other parameters related to head posture and sagittal pharyngeal airway were NSL–OPT, NSL–CVT, NL–OPT, NL–CVT, and OPT–CVT

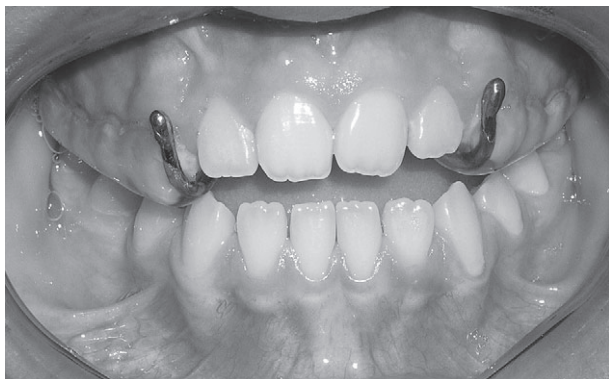

Figure 1 Intraoral view of the appliance.

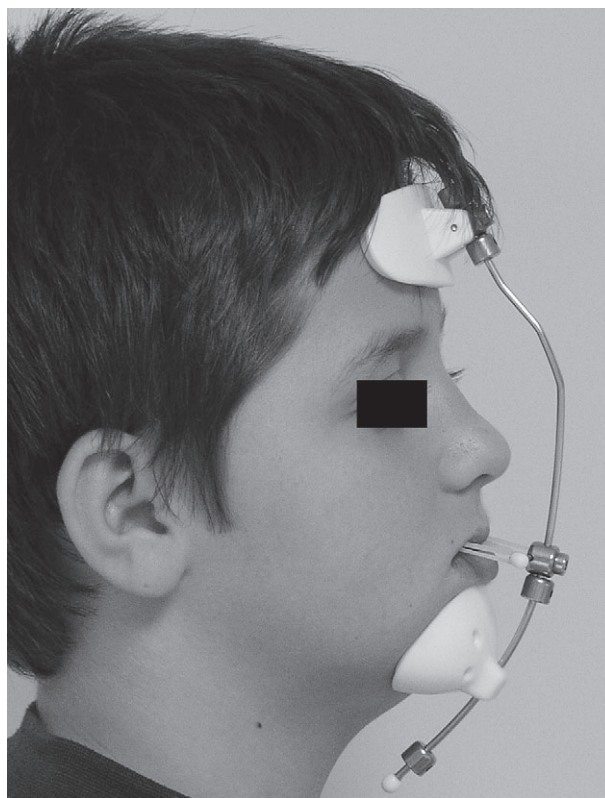


Figure 2 Profile view of a patient wearing facemask.

angles, and PNS–ad1, PNS–ad2, OAW1, OAW2, OAW3, SPPS, MPS, and IPS distances, as defined by earlier research (Linder-Aronson and Henrikson, 1973; Solow and Tallgren, 1976; Hellsing, 1989; Figure 3).

Statistical calculations were performed with GraphPad Prisma Version 3.0 software (San Diego, California, USA) for Windows. In addition to standard descriptive statistical calculations (mean and standard deviation), the non-parametric Wilcoxon signed rank test was utilized for the comparison of pre- and post-treatment changes (Table 1). The results were evaluated within a 95 per cent confidence interval. The statistical significance level was established at $P < 0.05$.

In order to assess the magnitude of the method error for each parameter, 20 randomly selected lateral cephalometric radiographs were retraced and remeasured by the same examiner (KS) with an interval of 20 days. Inter-rater correlation coefficients were found to be within 0.91 and 0.99.

Results

The changes which occurred during facemask therapy are shown in Table 1. Parameters regarding the sagittal maxillary position (NPer–A distance, maxillary depth angle, SNA angle) demonstrated that point A moved anteriorly. The palatal plane demonstrated a counter-clockwise rotation parallel

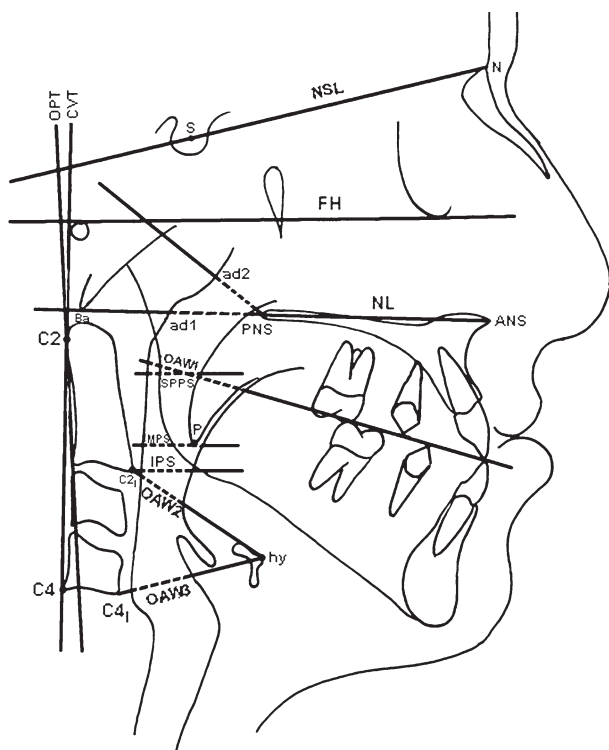


Figure 3 Diagrammatic representation of cephalometric head posture and airway variables. ad1, the point where posterior nasal spine (PNS)–basion (Ba) line intersects the posterior pharyngeal wall; ad2, the point where a line perpendicular to sella (S)–Ba plane passing through PNS intersects the posterior pharyngeal wall; OAW1, the distance between the points where the functional occlusal plane intersects the anterior and posterior pharyngeal walls; OAW2, the distance between points where a line passing through hyoid (hy) and C2_i intersects the anterior and posterior pharyngeal walls; OAW3, the distance between the points where a line passing through hy and C4_i intersects the anterior and posterior pharyngeal walls; SPPS, anteroposterior width of the pharynx measured between the posterior pharyngeal wall and the dorsum of the soft palate on a line parallel to the Frankfort horizontal (FH) plane that runs through the middle of a line from PNS to pogonion (P); MPS, anteroposterior width of the pharynx measured between the posterior pharyngeal wall and the dorsum of the tongue on a line parallel to the FH plane that runs through P; IPS, anteroposterior width of the pharynx measured between the posterior pharyngeal wall and the dorsum of the tongue on a line parallel to the FH plane that runs through C2_i.

to the clockwise rotation of the mandible, revealed by the decrease in SNB angle. The vertical parameters (SN–GoMe, ANSMe/NMe) showed a statistically significant increase.

The upper incisors tipped labially, a mean of 1.37 degrees with respect to the anterior cranial base, and the lower incisors tipped lingually. The amount of mean overjet increase was 8.06 mm.

The head was in a more extended position in relation to the cervical vertebrae, confirmed by the 2.38 degrees increase in NSL–CVT angle. NL–OPT and NL–CVT angles also showed an increase, slightly more than the NSL–CVT angle, supporting the counter-clockwise rotation of the maxillary complex. The mean increases in nasopharyngeal airway measurements (PNS–ad1 and PNS–ad2) were 2.71 and 3.03 mm, respectively.

Discussion

The present investigation analysed the treatment changes after orthopaedic therapy of Class III malocclusions by means of a bonded RPE used in conjunction with a facemask. An acrylic cap splint-type RPE was used as the anchorage appliance for the protraction therapy in order to obtain greater stability and skeletal effects (Kim *et al.*, 1999; Turley, 1988, 1996).

A control group could not be established in the present study. There are studies in the literature where Class I control groups have been used; however, the dentoalveolar and skeletal growth trends in subjects with a Class III malocclusion may differ from those of normal subjects. The need to use a Class III adequately matched control sample to make valid comparisons is therefore essential. Furthermore, there are examples which show that Class I control groups are not suitable for comparing with Class III treatment groups (Tindlund, 1989; Takada *et al.*, 1993; Shanker *et al.*, 1996). As for airway measurements, Özbek *et al.* (1998) showed that only negligible changes occurred in the upper airway during their 1.8 year observation period. Another limitation of the present study is the two-dimensional airway measurements, meaning that the results for these parameters are for the sagittal section only, and should be interpreted with caution taking this fact into consideration.

The parameters regarding the sagittal maxillary position (NP–A distance, maxillary depth angle, SNA angle) show that point A moved anteriorly. These results are similar to previously published reports as far as the amount and nature of the protraction effects. Most other studies (Nanda, 1980; Mermigos *et al.*, 1990; Gallagher *et al.*, 1998) reported between 1 and 3 mm of maxillary protraction, in line with the current study. This skeletal movement was accomplished by a force below the centre of resistance of the maxilla and directed downward and forward, lowering the posterior maxilla more than the anterior. The amount of skeletal movement of the maxilla was limited by the amount of dental movement, because the patients were generally treated until a positive overjet was achieved (Gallagher *et al.*, 1998). However, there is also a large range of responses reported in the literature, from significant maxillary advancement to minimal or no change with treatment (Turley, 2002). This inconsistency in response might be due to variations in treatment protocol including the design of appliances, the force level used, the number of hours worn per day, and the overall treatment time.

Maxillary height did not show any significant changes in the present study. Shanker *et al.* (1996) reported a 0.3 mm downward movement of the vertical position of point A in the treatment group, compared with a 1.0 mm downward movement in the control group. Those authors concluded that treatment appeared to inhibit normal downward movement of

Table 1 Comparison of intra-group changes (Wilcoxon sign rank test).

	Pre-treatment				Post-treatment				Difference					<i>P</i>
	Mean	SD	Median	Range	Mean	SD	Median	Range	Mean	SD	Median	Range		
<i>Skeletal</i>														
Sn–GoMe (°)	38.11	6.14	39.10	17.50	40.43	6.51	40.60	19.50	2.33	1.28	2.50	6.10	***	
NPer–A (mm)	−4.43	2.93	−5.20	9.70	−2.12	3.61	−2.20	14.50	2.31	2.05	2.00	6.50	**	
Maxillary height (°)	61.77	3.32	61.60	11.10	61.53	3.29	61.20	11.50	−0.24	1.65	−0.60	6.50		
Maxillary depth (°)	85.88	3.24	84.90	11.20	87.76	3.24	88.00	13.70	1.88	2.38	2.10	9.30	**	
SNA (°)	76.99	4.17	77.10	16.20	79.59	4.61	79.40	19.00	2.59	1.59	2.30	5.50	***	
SNB (°)	78.90	3.24	80.00	10.40	76.79	3.30	77.40	10.30	−2.11	1.01	−2.10	4.70	***	
ANB (°)	−1.88	2.22	−1.40	8.50	2.78	2.45	3.00	9.20	4.52	1.59	4.20	6.20	***	
SN–PP(°)	10.17	2.92	10.20	10.70	8.32	3.18	8.40	10.00	−1.85	1.60	−2.10	6.90	***	
ANS–Me/NMe (%)	54.46	2.60	54.90	8.60	56.27	2.60	57.00	9.20	1.81	1.26	2.00	5.20	***	
<i>Dental</i>														
SN–OP (°)	19.98	4.85	20.20	15.80	19.59	5.00	19.30	2.30	−0.39	2.40	−0.20	7.40		
U1–SN (°)	101.86	5.38	102.30	17.30	103.23	5.50	104.00	17.70	1.37	2.92	1.20	10.60	*	
L1–MP (°)	82.72	7.55	82.30	26.50	80.17	7.20	79.70	25.90	−2.55	2.71	−1.70	9.70	***	
Overjet (mm)	−1.75	2.02	−2.00	8.90	6.31	3.35	6.10	12.50	−2.47	6.60	7.30	11.40	***	
Overbite (mm)	1.42	2.25	1.90		1.04	2.11	0.60		3.95	2.41	−0.10			
<i>Head posture</i>														
NSL–CVT (°)	101.75	8.43	100.90	35.60	104.13	9.07	102.20	37.70	2.38	4.67	2.40	18.00	*	
NSL–OPT (°)	100.26	7.07	100.00	33.00	101.37	9.54	101.00	36.00	1.05	5.17	0.50	18.00		
NL–CVT (°)	91.89	9.18	90.00	37.00	95.79	10.09	93.50	42.00	3.89	5.01	4.50	19.00	*	
NL–OPT (°)	89.47	8.75	88.50	41.50	92.79	10.22	89.50	44.00	3.32	5.06	3.00	19.00	**	
OPT–CVT (°)	2.71	2.08	2.00	8.50	3.29	2.04	3.00	8.50	0.58	1.90	0.50	8.00		
<i>Airway</i>														
PNS–ad1 (mm)	15.16	4.37	14.50	17.00	17.87	4.05	18.00	13.00	2.71	3.35	2.00	11.00	**	
PNS–ad2 (mm)	11.05	2.99	11.50	11.50	14.08	3.47	14.00	12.50	3.03	2.37	2.50	9.00	***	
OAW1 (mm)	17.92	5.38	18.00	20.00	17.74	4.38	19.00	16.50	−0.18	3.21	−0.50	12.00		
OAW2 (mm)	10.92	3.96	11.00	18.00	10.66	3.16	11.00	13.00	0.26	3.24	0.00	11.00		
OAW3 (mm)	11.95	2.44	11.00	10.50	12.84	2.36	12.00	10.50	0.89	1.71	1.50	6.50		
SPPS (mm)	10.34	2.59	10.00	9.00	10.76	2.01	10.50	7.00	0.42	3.10	1.00	14.00		
MPS (mm)	13.84	3.45	13.00	15.50	14.50	3.10	14.50	10.50	0.66	2.49	1.00	10.50		
IPS (mm)	10.03	2.56	90.50	10.00	10.55	2.27	10.00	8.00	0.53	2.52	1.00	8.50		

* $P < 0.05$; ** $P < 0.01$; *** $P < 0.001$.

SD, standard deviation.

point A, which may be the result of the reported counter-clockwise rotation of the maxilla with protraction forces (Linder-Aronson and Henrikson, 1973; Ishii *et al.*, 1987; Tindlund, 1989; Shanker *et al.*, 1996). The palatal plane in this study showed a counter-clockwise rotation, resulting in a backward and downward displacement of the mandible. These findings are similar to the results of da Silva *et al.* (1998) and Ishii *et al.* (1987), where the ratio between maxillary anterior displacement and mandibular retroposition was almost 1:1.

The accompanying decrease in SNB angle is not a reflection of a change in dimension (da Silva *et al.*, 1998), but of a change in position, revealed by the vertical parameters (SN-GoMe, ANSMe/NMe) which showed a statistically significant increase. This downward and backward mandibular rotation results in point B moving backward, which then allows an increase in facial convexity and improvement in the profile.

Post-treatment, the head was in a more extended position in relation to the cervical vertebrae demonstrated,

by a mean increase of 2.38 degrees in NSL-CVT angle. NL-OPT and NL-CVT angles also showed an increase, slightly more than that of NSL-CVT angle, supporting the counter-clockwise rotation of the maxillary complex.

Upper airway dimension and head posture were found to be strongly correlated with previous research (Spann and Hyatt, 1971; Thach and Stark, 1979; Hiyama *et al.*, 2002). Nasopharyngeal airway measurements (PNS-ad1 and PNS-ad2) showed a mean increase of 2.71 and 3.03 mm, respectively in this study. The other airway parameters measured demonstrated no statistically significant differences. There are studies regarding the influence of functional appliances or RPE devices on the upper airway. In a recent review, oral devices were shown to be effective in approximately 50–70 per cent of patients with obstructive sleep apnoea (OSA; Verse *et al.*, 2003). Mandibular distraction osteogenesis may also be of help in OSA in patients with mandibular hypoplasia and severe

upper airway obstruction (Elwood *et al.*, 2003; Mandell *et al.*, 2004). Considering that mandibular growth has a definite influence on the upper airway dimension, it can be speculated that maxillary growth could also have beneficial effects on the upper airway (Hiyama *et al.*, 2002).

Even though no significant changes between pre- and post-treatment airway parameters were found by Hiyama *et al.* (2002), they carried out a multiple regression analysis which revealed that greater forward maxillary growth was associated with a greater increase in the superior upper airway dimension. A possible explanation as to why Hiyama *et al.* (2002) could not find any differences in the between the pre- and post-treatment airway parameters may be the lack of related parameters in their study. The upper airway measurements used (SPPS, MPS, IPS) were mainly at the back of the tongue and very minimally related to maxillary structures. The backward rotation of the mandible, although implicitly restricting the related sagittal airway dimensions, did not appear to cause any change.

Conclusions

This study evaluated the effect of using maxillary disarticulation and protraction on the sagittal dimension of the naso- and oropharyngeal airways in 19 growing patients with a skeletal Class III relationship. The results, however, should be interpreted with caution because of the small sample size and the lack of a control group. The findings showed:

1. Point A moved anteriorly, the palatal plane showed a counter-clockwise rotation matching the clockwise rotation of the mandible as revealed by the decrease in SNB angle, and the vertical parameters showed a statistically significant increase.
2. The head was in a more extended position in relation to the cervical vertebrae. Nasopharyngeal airway measurements (PNS-ad1, PNS-ad2) showed a mean increase of 2.71 and 3.03 mm, respectively.
3. Maxillary disarticulation and protraction improved naso- but not oropharyngeal airways.

Further research may be needed to evaluate the functional status of the airway after maxillary protraction.

Address for correspondence

Dr Korkmaz Sayınsu
Yeditepe University
Faculty of Dentistry
Bagdat cad. No: 238 34730
Göztepe
Istanbul
34730 Turkey
E-mail: drkorkmaz@yeditepe.edu.tr

References

- Baccetti T, McGill J S, Franchi L, McNamara Jr J A, Tollaro I 1998 Skeletal effects of early treatment of Class III malocclusion with maxillary expansion and face-mask therapy. *American Journal of Orthodontics and Dentofacial Orthopedics* 113: 333–343
- Baccetti T, Franchi L, McNamara Jr J A 2000 Treatment and posttreatment craniofacial changes after rapid maxillary expansion and facemask therapy. *American Journal of Orthodontics and Dentofacial Orthopedics* 118: 404–413
- Basciftci F A, Mutlu N, Karaman A I, Malkoc S, Kucukkolbasi H 2002 Does the timing and method of rapid maxillary expansion have an effect on the changes in nasal dimensions? *Angle Orthodontist* 72: 118–123
- da Silva Filho O G, Magro A C, Capelozza Filho L 1998 Early treatment of the Class III malocclusion with rapid maxillary expansion and maxillary protraction. *American Journal of Orthodontics and Dentofacial Orthopedics* 113: 196–203
- Delaire J 1997 Maxillary development revisited: relevance to the orthopaedic treatment of Class III malocclusions. *European Journal of Orthodontics* 19: 289–311
- Doruk C, Söktücü O, Sezer H, Canbay E 2004 Evaluation of nasal airway resistance during rapid maxillary expansion using acoustic rhinometry. *European Journal of Orthodontics* 26: 397–403
- Elwood E T, Burstein F D, Graham L, Williams J K, Paschal M 2003 Midface distraction to alleviate upper airway obstruction in achondroplastic dwarfs. *Cleft Palate-Craniofacial Journal* 40: 100–103
- Gallagher W, Miranda F, Buschang P H 1998 Maxillary protraction: treatment and posttreatment effects. *American Journal of Orthodontics and Dentofacial Orthopedics* 113: 612–619
- Handler S D 1985 Upper airway obstruction in craniofacial anomalies: diagnosis and management. *Birth Defects* 21: 15–31
- Hellsing E 1989 Changes in the pharyngeal airway in relation to extension of the head. *European Journal of Orthodontics* 11: 359–365
- Hiyama S *et al.* 2002 Effects of maxillary protraction on craniofacial structures and upper-airway dimension. *Angle Orthodontist* 72: 43–47
- Hui S, Wing Y K, Kew J, Chan Y L, Abdullah V, Fok T F 1998 Obstructive sleep apnea syndrome in a family with Crouzon's syndrome. *Sleep* 21: 298–303
- Ishii H, Morita S, Takeuchi Y, Nakamura S 1987 Treatment effect of combined maxillary protraction and chin cap appliance in severe Class III cases. *American Journal of Orthodontics and Dentofacial Orthopedics* 92: 304–312
- Itoh T, Chaconas S J, Caputo A A, Matyas J 1985 Photoelastic effects of maxillary protraction on the craniofacial complex. *American Journal of Orthodontics* 88: 117–124
- Jackson G W, Kokich V G, Shapiro P A 1979 Experimental and postexperimental response to anteriorly directed extraoral force in young *Macaca nemestrina*. *American Journal of Orthodontics* 75: 318–333
- Jäger A, Braumann B, Kim C, Wahner S 2001 Skeletal and dental effects of maxillary protraction in patients with Angle Class III malocclusion. A meta-analysis. *Journal of Orofacial Orthopedics* 62: 275–284
- Kambara T 1977 Dentofacial changes produced by extraoral forward force in the *Macaca irus*. *American Journal of Orthodontics* 71: 249–277
- Kim J H, Viana M A, Graber T M, Omerza F F, BeGole E A 1999 The effectiveness of protraction face mask therapy: a meta-analysis. *American Journal of Orthodontics and Dentofacial Orthopedics* 115: 675–685.
- Linder-Aronson S, Henrikson C O 1973 Radiocephalometric analysis of anteroposterior nasopharyngeal dimensions in 6- to 12-year-old mouth breathers compared with nose breathers. *Journal for Oto-Rhino-Laryngology and Its Related Specialties* 35: 19–29
- Macdonald K E, Kapust A J, Turley P K 1999 Cephalometric changes after the correction of Class III malocclusion with maxillary expansion/facemask therapy. *American Journal of Orthodontics and Dentofacial Orthopedics* 116: 13–24

- Mandell D L, Yellon R F, Bradley J P, Izadi K, Gordon C B 2004 Mandibular distraction for micrognathia and severe upper airway obstruction. *Archives of Otolaryngology-Head and Neck Surgery* 130: 344–348
- McNamara J A 1987 An orthopedic approach to the treatment of Class III malocclusion in young patients. *Journal of Clinical Orthodontics* 21: 598–608
- Mermigos J, Full C A, Andreasen G 1990 Protraction of the maxillofacial complex. *American Journal of Orthodontics and Dentofacial Orthopedics* 98: 47–55
- Nanda R 1978 Protraction of maxilla in rhesus monkeys by controlled extraoral forces. *American Journal of Orthodontics* 74: 121–141
- Nanda R 1980 Biomechanical and clinical considerations of a modified protraction headgear. *American Journal of Orthodontics* 78: 125–139
- Nartallo-Turley P E, Turley P K 1998 Cephalometric effects of combined palatal expansion and facemask therapy on Class III malocclusion. *Angle Orthodontist* 68: 217–224
- Ngan P, Hägg U, Yiu C, Merwin D, Wei S H 1996 Treatment response to maxillary expansion and protraction. *European Journal of Orthodontics* 18: 151–168
- Özbek M M, Memikoglu T U, Gögen H, Lowe A A, Baspinar E 1998 Oropharyngeal airway dimensions and functional-orthopedic treatment in skeletal Class II cases. *Angle Orthodontist* 68: 327–336
- Roberts C A, Subtelny J D 1988 Use of the face mask in the treatment of maxillary skeletal retrusion. *American Journal of Orthodontics and Dentofacial Orthopedics* 93: 388–394
- Shanker S *et al.* 1996 Cephalometric A point changes during and after maxillary protraction and expansion. *American Journal of Orthodontics and Dentofacial Orthopedics* 110: 423–430
- Solow B, Tallgren A 1976 Head posture and craniofacial morphology. *American Journal of Physical Anthropology* 44: 417–435
- Spann R W, Hyatt R E 1971 Factors affecting upper airway resistance in conscious man. *Journal of Applied Physiology* 31: 708–712.
- Takada K, Petdachai S, Sakuda M 1993 Changes in dentofacial morphology in skeletal Class III children treated by a modified protraction headgear and a chin cup: a longitudinal cephalometric appraisal. *European Journal of Orthodontics* 15: 211–221
- Thach B T, Stark A R 1979 Spontaneous neck flexion and airway obstruction during apneic spells in preterm infants. *Journal of Pediatrics* 94: 275–281
- Tindlund R S 1989 Orthopedic protraction of the midface in the deciduous dentition—results covering 3 years out of treatment. *Journal of Cranio-Maxillofacial Surgery* 17 (Suppl 1): 17–19
- Turley P K 1988 Orthopedic correction of Class III malocclusion with palatal expansion and custom protraction headgear. *Journal of Clinical Orthodontics* 22: 314–325
- Turley P K 1996 Orthopedic correction of Class III malocclusion: retention and phase II therapy. *Journal of Clinical Orthodontics* 30: 313–324
- Turley P K 2002 Managing the developing Class III malocclusion with palatal expansion and facemask therapy. *American Journal of Orthodontics and Dentofacial Orthopedics* 122: 349–352
- Verse T, Pirsig W, Stuck B A, Hormann K, Maurer J T 2003 Recent developments in the treatment of obstructive sleep apnea. *American Journal of Respiratory Medicine* 2: 157–168

Copyright of European Journal of Orthodontics is the property of Oxford University Press / UK and its content may not be copied or emailed to multiple sites or posted to a listserv without the copyright holder's express written permission. However, users may print, download, or email articles for individual use.