

Surgical repositioning of a developing maxillary permanent central incisor in a horizontal position: spontaneous eruption and root formation

Kazuto Kuroe, Hiroshi Tomonari, Kazuhisa Soejima and Aya Maeda

Department of Orthodontics, Kagoshima University Graduate School of Medical and Dental Sciences, Japan

SUMMARY This report describes the surgical repositioning of a developing maxillary permanent central incisor in a horizontal position, followed by spontaneous eruption and root formation without orthodontic traction. Surgical exposure of the right central incisor was achieved.

A 7-year-old boy referred for orthodontic consultation. Radiographic examination showed the crown of a maxillary right central incisor to be positioned horizontally with root formation at the initial stage. The surgically repositioned incisor (by a close-eruption surgical flap technique) spontaneously erupted into correct alignment after 2 years 3 months. The erupted incisor remained vital and responded normally to percussion, mobility and sensitivity testing. The soft tissue, periodontal attachment, gingival contour and probing depths were normal. Follow-up radiographs confirmed the continued development of the root, with revascularization of the pulp and a normal appearance of the periodontal space and lamina dura. There was, however, shorter root formation and a narrower root cavity compared with the contralateral incisor. As a result, no orthodontic traction and alignment were required.

This method of surgical repositioning is a viable alternative to the traditional approach of extraction or surgical exposure followed by orthodontic traction for a developing maxillary permanent central incisor in a horizontal position.

Introduction

A developing maxillary permanent incisor in a horizontal position could lead to a dilacerated root while growth of the root is still progressing in a cranial direction (Foster, 1982; Filippi *et al.*, 1998). Extraction or surgical exposure followed by orthodontic traction is the most common treatment for a horizontally impacted maxillary central incisor (Filippi *et al.*, 1998; McNamara *et al.*, 1998; Sandler and Reed, 1988; Lin, 1999; Tsai, 2002; Agrait *et al.*, 2003; Chew and Ong, 2004; Uematsu *et al.*, 2004). Either option involves an extended period of treatment (Tsai, 2002). Furthermore, multiple surgery, complicated orthodontic management, additional periodontal surgery and a compromised gingival margin are usually inevitable because of the root angulation of the impacted incisor (Tsai, 2002). Even in successful cases the gingival tissue of the exposed incisor necessitating periodontal surgery may be unaesthetic (Machtei *et al.*, 1990).

If the developing maxillary permanent central incisor is in a horizontal position and at the early stage of root formation, surgical repositioning is possible which may permit spontaneous eruption and root formation. This report presents the surgical repositioning of a maxillary permanent central incisor developing in a horizontal position, followed by spontaneous eruption and root formation without orthodontic traction.

Subjects and methods

Subject

A 7-year-old boy referred for orthodontic consultation regarding a developing maxillary right permanent central incisor in a horizontal position (Figure 1a). The patient sustained traumatic injury to the maxillary primary central incisors at 4 years of age and root canal treatment had been undertaken. He was in mixed dentition with a Class I normal occlusion. The overjet was 1 mm and the overbite was 2 mm. Radiographic examination showed the crown of the maxillary right central incisor to be positioned horizontally, with root formation at the initial stage.

Treatment plan

The treatment plan consisted of extraction of the maxillary right primary central incisor, surgical repositioning of the maxillary right permanent central incisor from a horizontal to a vertical position, and orthodontic traction and alignment to obtain a normal occlusion.

Surgery

Surgical exposure of the right central incisor was achieved with the close-eruption surgical flap technique (Figure 1b) (Vermette *et al.*, 1995; Lin, 1999; Tsai, 2002). The surrounding

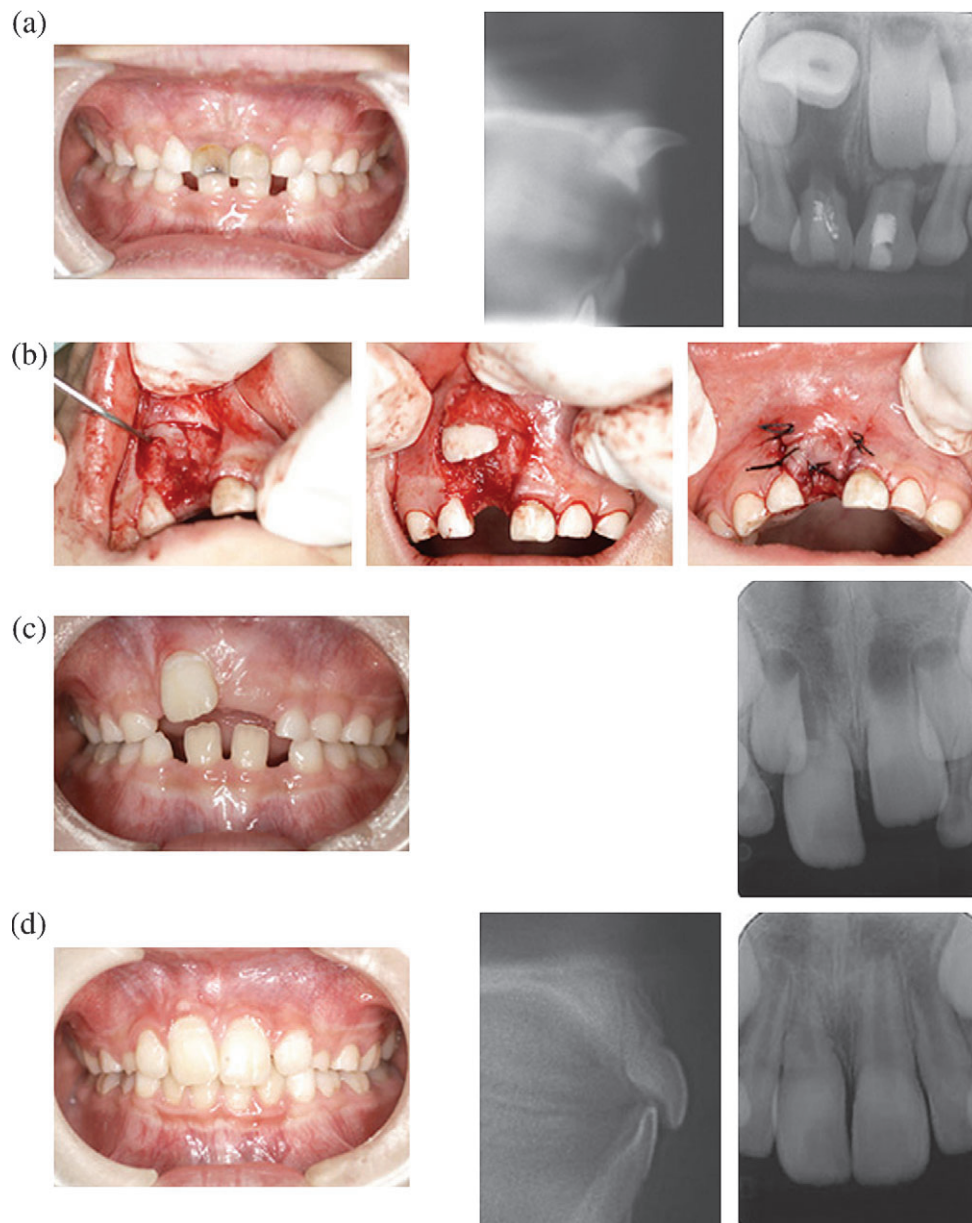


Figure 1 Surgical repositioning of the developing maxillary permanent incisor from a horizontal position, followed by spontaneous eruption and root formation. (a) Pre-treatment: maxillary right central incisor in a horizontal position in the patient aged 7 years 5 months. (b) Surgery: surgical repositioning of the right maxillary central incisor from the horizontal position. (c) Post-surgery: 11 months. (d) Post-surgery: 38 months; central incisor correctly aligned in the patient aged 11 years 7 months.

bone was carefully removed from the horizontally positioned crown and the tooth follicle was separated from the socket. The incisor was then repositioned in the correct orientation and the flap was returned to its original location.

Post-surgery

The surgically repositioned incisor spontaneously erupted in a high position after 11 months and was successfully positioned into correct alignment after 2 years and 3 months

(Figure 1c,d). The erupted incisor remained vital and responded normally to percussion, mobility and sensitivity testing. The soft tissue, periodontal attachment, gingival contour and probing depth were normal. Follow-up radiographs showed continued development of the root with revascularization of the pulp and a normal appearance of the periodontal space and lamina dura. There was, however, shorter root formation and a narrower root cavity compared with the contralateral incisor, with vestibular root angulation just below the cemento-enamel junction due to the partially

arrested distal surface of the root. As a result, no orthodontic traction and alignment were needed.

Discussion

The aetiology of a horizontal or inverted displaced maxillary permanent central incisor has been reported as a result of trauma to the developing tooth germ (Smith and Winter, 1981; Foster, 1982; Diab and elBadrawy, 2000; Macias *et al.*, 2003) or ectopic development of the tooth germ (Andreasen *et al.*, 1971; Stewart, 1978). A developing maxillary permanent incisor in a horizontal or inverted position could lead to a dilacerated root while root growth is still progressing in a cranial direction (Foster, 1982; Filippi *et al.*, 1998). In either case, extraction or a surgical/orthodontic approach to treatment is essential. Extraction has been the first choice because of the complexity of surgical/orthodontic procedures.

Surgical exposure followed by orthodontic traction (McNamara *et al.*, 1998; Lin, 1999; Kajiyama and Kai, 2000; Macias *et al.*, 2003; Chew and Ong, 2004), surgical repositioning followed by orthodontic alignment (Tsai, 2002) and surgical reimplantation followed by orthodontic traction (Agrait *et al.*, 2004) were the treatment modalities for a horizontal or inverted displaced maxillary permanent central incisor with a dilacerated root. Surgical exposure and orthodontic traction required complicated orthodontic mechanics and compromised the gingival contour. New approaches to surgical repositioning followed by orthodontic alignment for inverted displaced maxillary permanent central incisors have been recently reported (Tsai, 2002). That author stated that surgical repositioning offers simplified treatment for a dilacerated incisor with the advantages of immediate aesthetic improvement, use of a single surgical procedure, simple and short orthodontic therapy, a normal gingival margin and the possibility of the developing root adapting to its new position. Agrait *et al.* (2003) reported that the combination of reimplantation of an inverted maxillary permanent central incisor in an upright position after luxation and orthodontic traction could be an optimal treatment choice. These reports suggest that surgical repositioning or reimplantation followed by orthodontic traction and alignment could be a better procedure. The treatment approach used in this case has not been previously reported. The technique of surgical repositioning at an early stage of the developing tooth is relatively simple compared with transplantation.

Spontaneous tooth eruption and root formation with vestibular root angulation at just below the cemento-enamel junction were observed in this patient. Injury to the periodontal ligament resulting in root resorption and/or ankylosis, and damage to the pulp, possibly leading to pulp necrosis, and to Hertwig's epithelial root sheath, resulting in partial or total arrest of further root development, have been reported (Azaz *et al.*, 1980; Andreasen, 1981; Engel

and Katsaros, 1997; Tsai, 2002). Thus, the presence of an intact and viable periodontal ligament and Hertwig's epithelial root sheath are the most important factors in ensuring normal root growth. Agrait *et al.* (2003), in a radiographic investigation of repositioning an inverted maxillary central incisor showed at 2-year follow-up that its root was complete, although it did not reach the same length as the contralateral central incisor. Those authors stated that the subsequent reduction in root length was probably due to distortion of Hertwig's epithelial root sheath caused by compression of the dental follicle, and suggested that root growth was highly related to the stage of root development at the time of repositioning. In the present case, the surgically repositioned central incisor possibly had an injury to Hertwig's root sheath, since vestibular root angulation was just below the cemento-enamel junction, and partially arrested distal root. Tsai (2002) stated that surgical exposure and orthodontic traction must be carried out early so that normal root development can continue in a correct spatial relationship to the aligned crown. It is apparent from the results of this case that normal root formation might be expected at an earlier stage.

Surgical exposure followed by orthodontic traction of a horizontally impacted maxillary central incisor seems to result in unaesthetic gingival tissue of the exposed incisor requiring periodontal surgery (Machtei *et al.*, 1990). In the patient in the present study, no orthodontic traction or alignment were necessary since the position, periodontal attachment, gingival contour and probing depths of the surgically repositioned incisor were normal.

The timing of surgical repositioning in this subject was at 7 years of age, which was at an early stage of maxillary central incisor root formation. Tsai (2002) and Agrait *et al.* (2003) reported that the patients in their studies underwent surgical repositioning of the maxillary permanent central incisor at 9 years of age. They did not make it clear, however, what the stage of root development was at the time of root repositioning. It could be expected, therefore, that root formation had progressed further compared with the patient in this case report. The earlier stage of root formation could provide not only the ability to mobilize the developing incisor but also to prevent injury to the developing root. From this case, the success rate of surgical repositioning of a horizontally developing maxillary permanent central incisor depends on the degree of root formation of the tooth. An early stage of root formation would have a better prognosis for surgical repositioning of a developing horizontal maxillary permanent central incisor.

Conclusion

This method of surgical repositioning is a viable alternative to the traditional approach of extraction or surgical exposure followed by orthodontic traction for a developing horizontal maxillary permanent central incisor.

Address for correspondence

Kazuto Kuroe
 Department of Orthodontics
 Kagoshima University Graduate School of Medical and
 Dental Sciences
 8-35-1 Sakuragaoka
 Kagoshima 890-8544
 Japan
 E-mail: kk@denta.hal.kagoshima-u.ac.jp

References

- Agrait E M, Levy D, Gil M, Singh G D 2003 Repositioning an inverted maxillary central incisor using a combination of replantation and orthodontic movement: a clinical case report. *Pediatric Dentistry* 25: 157–160
- Andreasen J O 1981 Periodontal healing after replantation and autotransplantation of incisors in monkeys. *International Journal of Oral Surgery* 10: 54–61
- Andreasen J O, Sundstrom B, Ravn J J 1971 The effect of traumatic injuries to primary teeth on their permanent successors. I. A clinical and histologic study of 117 injured permanent teeth. *Scandinavian Journal of Dental Research* 79: 219–283
- Azaz B, Steiman Z, Koyoumdjisky-Kaye E, Lewin-Epstein J 1980 The sequelae of surgical exposure of unerupted teeth. *Journal of Oral Surgery* 38: 121–127
- Chew M T, Ong M M 2004 Orthodontic-surgical management of an impacted dilacerated maxillary central incisor: a clinical case report. *Pediatric Dentistry* 26: 341–344
- Diab M, elBadrawy H E 2000 Intrusion injuries of primary incisors. Part III. Effects on the permanent successors. *Quintessence International* 31: 377–384
- Engel M, Katsaros C 1997 Replantation of an inverted lower second premolar germ. *Journal of Orofacial Orthopedics* 58: 282–285
- Filippi A, Pohl Y, Tekin U 1998 Transplantation of displaced and dilacerated anterior teeth. *Endodontics and Dental Traumatology* 14: 93–98
- Foster T D (ed.) 1982 Aberrant developmental position of individual teeth. Localized factors affecting the development of the occlusion. In: *A textbook of orthodontics*, 2nd edn. Blackwell Scientific Publications, Oxford, pp. 145–155
- Kajiyama K, Kai H 2000 Esthetic management of an unerupted maxillary central incisor with a close eruption technique. *American Journal of Orthodontics and Dentofacial Orthopedics* 118: 224–228
- Lin Y T 1999 Treatment of an impacted dilacerated maxillary central incisor. *American Journal of Orthodontics and Dentofacial Orthopedics* 115: 406–409
- Machtei E E, Zyskind K, Ben-Yehouda A 1990 Periodontal considerations in the treatment of dilacerated maxillary incisors. *Quintessence International* 21: 357–360
- Macias E, Carlos F, Cobo J 2003 Posttraumatic impaction of both maxillary central incisors. *American Journal of Orthodontics and Dentofacial Orthopedics* 124: 331–338
- McNamara T, Woolfe S N, McNamara C M 1998 Orthodontic management of a dilacerated maxillary central incisor with an unusual sequela. *Journal of Clinical Orthodontics* 32: 293–297
- Sandler P J, Reed R T 1988 Treatment of a dilacerated incisor. *Journal of Clinical Orthodontics* 22: 374–376
- Smith D M H, Winter G B 1981 Root dilaceration of maxillary incisors. *British Dental Journal* 150: 125–127
- Stewart D J 1978 Dilacerate unerupted maxillary central incisors. *British Dental Journal* 145: 229–233
- Tsai T P 2002 Surgical repositioning of an impacted dilacerated incisor in mixed dentition. *Journal of the American Dental Association* 133: 61–66
- Uematsu S, Uematsu T, Furusawa K, Deguchi T, Kurihara S 2004 Orthodontic treatment of an impacted dilacerated maxillary central incisor combined with surgical exposure and apicoectomy. *Angle Orthodontist* 74: 132–136
- Vermette M E, Kokich V G, Kennedy D B 1995 Uncovering labially impacted teeth: apically positioned flap and closed-eruption techniques. *Angle Orthodontist* 65: 23–32

Copyright of European Journal of Orthodontics is the property of Oxford University Press / UK and its content may not be copied or emailed to multiple sites or posted to a listserv without the copyright holder's express written permission. However, users may print, download, or email articles for individual use.