

A prospective, randomized clinical study on the effects of an amine fluoride/stannous fluoride toothpaste/mouthrinse on plaque, gingivitis and initial caries lesion development in orthodontic patients

B. Øgaard*, A. Afzelius Alm**, E. Larsson** and U. Adolfsson***

*Department of Orthodontics, Institute of Clinical Dentistry, Faculty of Dentistry, University of Oslo, Norway, and Orthodontic Clinics, **Falköping, and ***Lidköping, Sweden

SUMMARY The aim of this study was to examine the effect of combined use of a toothpaste/mouthrinse containing amine fluoride/stannous fluoride (AmF/SnF₂; meridol®) on the development of white spot lesions, plaque, and gingivitis on maxillary anterior teeth in orthodontic patients. A prospective, randomized, double-blind study with 115 orthodontic patients (42 males and 73 females, average age 14.4 years, drop outs 18) was designed. Group A (50) brushed twice daily with an AmF/SnF₂ toothpaste (1400 ppm F) and rinsed every evening with an AmF/SnF₂ solution (250 ppm F). Group B (47) brushed twice daily with a sodium fluoride (NaF) toothpaste (1400 ppm F) and rinsed every evening with a NaF solution (250 ppm F). Visible plaque index (VPI), gingival bleeding index (GBI) and white spot lesion index (WSL) were recorded on the six maxillary anterior teeth at bonding and after debonding, and evaluated with *t* tests.

In group A no significant differences between bonding and debonding were recorded for WSL (1.02 ± 0.08 versus 1.05 ± 0.13 , $P = 0.14$), VPI (0.10 ± 0.21 versus 0.12 ± 0.21 , $P = 0.66$) or GBI (0.13 ± 0.21 versus 0.16 ± 0.22 , $P = 0.47$), whereas statistically significant differences were found in group B between bonding and debonding for WSL (1.00 ± 0.02 versus 1.08 ± 0.17 , $P = 0.01$), VPI (0.06 ± 0.13 versus 0.17 ± 0.25 , $P = 0.01$) and GBI (0.06 ± 0.12 versus 0.16 ± 0.21 , $P = 0.01$). The increase in lesions on the upper anterior teeth was 4.3 per cent in group A and 7.2 per cent in group B. It was concluded that the combined use of an AmF/SnF₂ toothpaste/mouthrinse had a slightly more inhibitory effect on white spot lesion development, plaque and gingivitis on maxillary anterior teeth during fixed orthodontic treatment compared with NaF.

Introduction

Caries development during treatment with fixed orthodontic appliances is a significant clinical problem despite fluoride therapy (Gorelick *et al.*, 1982; Mizrahi, 1983; Årtun and Brobakken, 1986; Øgaard, 1989a,b). Recent research has focused on the observation that pH in the plaque upper incisors is generally lower than in other parts of the bonded dentition. This is presumably due to the low clearance of saliva in this area. Accordingly, due to the low pH, any reservoirs of fluoride are rapidly lost. This loss of fluoride and a limited cariostatic effect of fluoride in the low pH in plaque, is perhaps one explanation why white spot lesions develop frequently on bonded upper incisors (Büyükyilmaz and Øgaard, 1994; Arneberg *et al.*, 1997). Plaque in association with fixed appliances also induces inflammation of the gingival tissue.

Currently, no acceptable clinical methods exist to build up normal enamel structure or obtain complete remineralization of lesions that develop on the labial surfaces of teeth during orthodontic treatment with fixed appliances (Øgaard *et al.*, 2004). Prevention of lesion

development during treatment is therefore crucial and is the responsibility of the orthodontic team.

Toothpaste containing both amine fluoride (AmF) and stannous fluoride (SnF₂) was introduced in 1985 and the cariostatic potential has been documented in several studies (Einwag *et al.*, 1995; Pakhomov *et al.*, 1997; Klimek *et al.*, 1998; Warrick *et al.*, 1999). SnF₂ also has a well-known plaque inhibiting effect and may inhibit bacterial metabolism (Øgaard *et al.*, 1980; Baehni and Takeuchi, 2003). It has been shown that a combination of AmF and SnF₂ reduced both plaque and retarded gingivitis (Brex *et al.*, 1992; Mengel *et al.*, 1996; Shapira *et al.*, 1999).

The present study was designed to test the effect of the combined use of a toothpaste/mouthrinse containing AmF and SnF₂ on development of initial (white spot) caries lesions, plaque and gingivitis on upper anterior teeth during orthodontic treatment with fixed appliances.

Subjects and methods

All individuals scheduled to start treatment from 1999 with fixed orthodontic appliances in both arches at the orthodontic

clinics of Falköping and Lidköping in Sweden were invited to participate. The parents signed informed consent. The ethics committee at the University of Gothenburg approved the study.

The participants were allocated into two groups (A and B) at bonding according to a randomized table. The study followed the requirements of a double-blind, prospective, randomized clinical trial. The subjects were followed longitudinally during the orthodontic treatment (average approximately 1.5 years). The last patients were debonded in November 2003. Of the 115 patients (42 males and 73 females) initially invited to participate, 97 (35 males and 62 females) completed treatment according to the requirements in the protocol in 2003. The drop-out was thus 15.6 per cent and was mainly due to moving. The average age at bonding was 14.5 years. Breaking the code in December 2003 showed that group A used the AmF/SnF₂ (meridol®, GABA international, Basel, Switzerland) products and group B the NaF products.

Subjects in group A (AmF/SnF₂ (meridol®); $n = 50$, 17 males and 33 females) were requested to brush in the morning and in the evening with a toothpaste containing AmF/SnF₂ (140 ppm F, pH 4.5) and rinse every evening after tooth brushing with a solution containing AmF/SnF₂ (250 ppm F, pH 4.0) during the entire treatment period.

Subjects in group B (NaF; $n = 47$, 18 males and 29 females) were requested to brush in the morning and in the evening with toothpaste containing neutral sodium fluoride (NaF; 1400 ppm F, pH 6.7) and rinse every evening after tooth brushing with a solution containing NaF (250 ppm F, pH 6.3) during the entire treatment period.

The toothpaste tubes/bottles were similar and coded either A or B. The colour and taste of the toothpastes and the rinsing solutions were as close to identical as possible. Neither the subjects nor the research team were informed about which group each participant belonged to. Both groups were supplied with the same type of toothbrush (GABA) and given oral hygiene instructions prior to bonding. Andrews standard brackets with a 0.22 inch bracket slot (A-Company, Amersfoort, The Netherlands) were bonded according to standard procedures using a non-fluoride adhesive (Unite, 3M Unitek, Monrovia, California, USA). Excess adhesive around the brackets was removed with a scaler before curing, or with a tungsten carbide bur after curing. Bands (American Orthodontics, Sheboygan, Wisconsin, USA and 3M Unitek) were used routinely on the first molars and cemented with a glass ionomer cement (Ketac-Cem, ESPE, Seefeld, Germany).

Clinical data collection

The following clinical data was collected according to a previously described protocol (Øgaard *et al.*, 2001):

Prior to bonding and at debonding: bitewing radiographs, colour photographs, white spot lesion index (WSL)

(Gorelick *et al.*, 1982), visible plaque index (VPI) and gingival bleeding index (GBI) (Ainamo and Bay, 1975).

Enamel demineralization: WSL was used. The labial surfaces of all bonded teeth were visually examined and registered as: (1) no white spot formation, (2) slight white spot formation (thin rim), (3) excessive white spot formation (thicker bands), and (4) white spot formation with cavitation.

Plaque: VPI was recorded as 1 for visible plaque, and 0 for non-visible plaque on the mesio-buccal surface of every bonded tooth after rinsing and drying of the tooth surface.

Gingivitis: GBI was assessed using a 0.5 mm diameter periodontal probe (LM Dental LM 550B Si WHO probe, LM-Instruments Oy, Parainen, Finland). The gingiva was lightly air-dried and the probe lightly inserted into the gingival crevice parallel to the long axis of the tooth until slight pressure was felt. The probe was run gently along the crevice in contact with the sulcular epithelium. Minimum axial force was used to avoid undue penetration into the tissue and the probe was moved around the crevice gently stretching the epithelium. Only the gingival margin at the mesio-labial surfaces was evaluated. Bleeding was recorded as 1, and no bleeding as 0. The number of elicited bleeding points was totalled and divided by the number of units probed.

A Student's *t*-test was used to evaluate statistical differences between bonding and debonding in the two groups. The level of significance was set at 5 per cent.

Results

White spot lesion index

The mean WSL for maxillary teeth prior to bonding and debonding is given in Table 1. A statistically significant difference between WSL prior to bonding and at debonding was found for the upper anterior teeth in the NaF group. For the meridol® group, there was no significant difference in WSL for the upper anterior teeth at bonding and debonding. The number of new lesions that developed on the upper anterior teeth in the meridol® group was 13 on a total of 297 teeth or 4.3 per cent compared with 20 new lesions on a total of 282 teeth or 7.2 per cent in the NaF group. Figure 1a and b show the WSL at bonding and debonding of the different maxillary teeth in group A and B, respectively.

Table 1 Mean white spot lesion index and standard deviation for the maxillary anterior teeth prior to bonding and at debonding, and level of significance.

Group	Bonding	Debonding	<i>P</i> value
AmF/SnF ₂	1.02 ± 0.08	1.05 ± 0.13	0.14
NaF	1.00 ± 0.02	1.08 ± 0.17	0.01

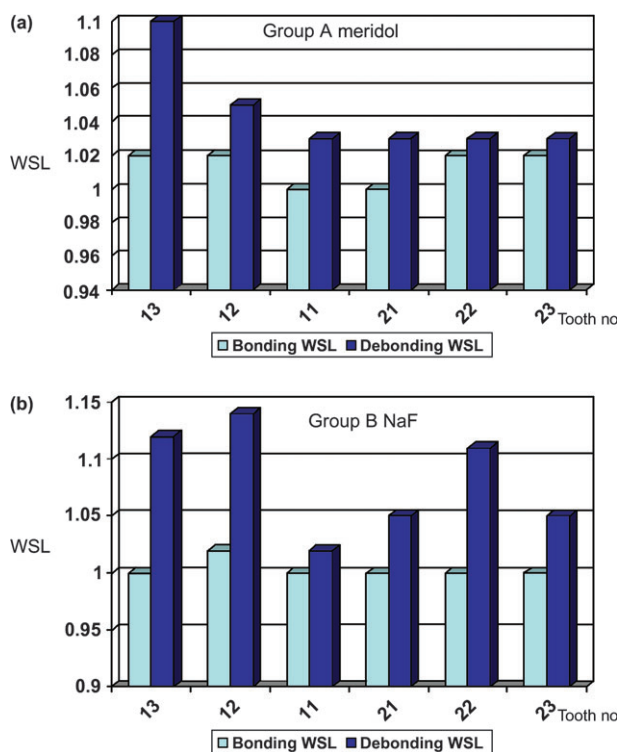


Figure 1 White spot lesion index (WSL) at bonding and debonding of the different maxillary teeth in (a) group A (meridol®) and (b) group B (NaF).

The canines and the laterals were generally more severely affected than the central incisors, and the right side more than the left side, particularly in the NaF group.

Visible plaque index

The mean VPI for maxillary teeth prior to bonding and debonding is given in Table 2. A statistically significant difference in VPI prior to bonding and at debonding was found for the upper anterior teeth in the NaF group. For the meridol® group, there was no significant difference in VPI for the upper anterior teeth at bonding and debonding.

Gingival bleeding index

The mean GBI for maxillary anterior teeth prior to bonding and at debonding is given in Table 3. A statistically significant difference in GBI prior to bonding and at debonding was found for the upper anterior teeth in the NaF group, whereas no such differences were found in the meridol® group.

Figure 2a and b show the VPI and GBI scores at bonding and debonding of the different maxillary teeth in group A and B, respectively.

Discussion

The prevalence of white spot lesions developed during treatment with fixed orthodontic therapy has been reported

Table 2 Mean visible plaque index and standard deviation for the maxillary anterior teeth prior to bonding and at debonding, and level of significance.

Group	Bonding	Debonding	P value
AmF/SnF ₂	0.10 ± 0.21	0.12 ± 0.21	0.66
NaF	0.06 ± 0.13	0.17 ± 0.25	0.02

Table 3 Mean gingival bleeding index and standard deviation for the maxillary anterior teeth prior to bonding and at debonding, and level of significance.

Group	Bonding	Debonding	P value
AmF/SnF ₂	0.13 ± 0.21	0.16 ± 0.22	0.47
NaF	0.06 ± 0.12	0.16 ± 0.21	0.02

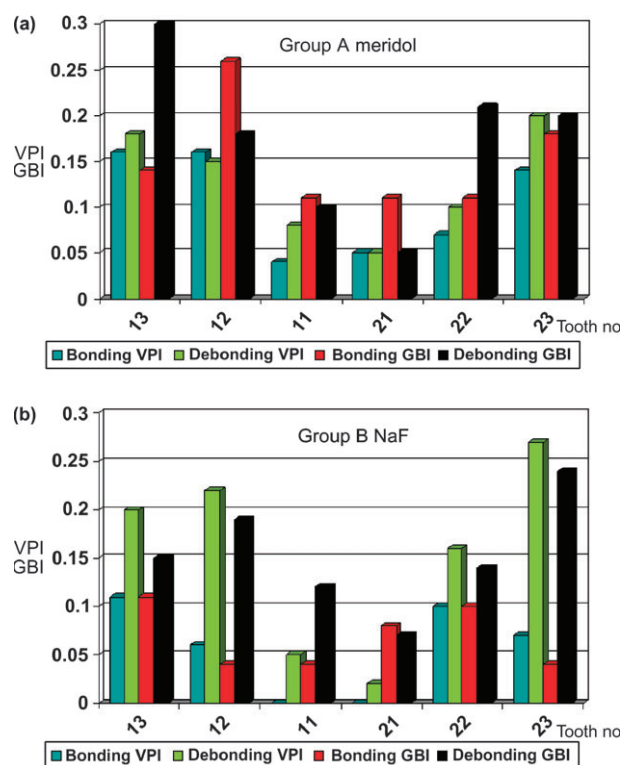


Figure 2 Visible plaque index (VPI) and gingival bleeding index (GBI) at bonding and debonding of the different maxillary teeth in (a) group A (meridol®) and (b) group B (NaF).

to be as high as 50–70 per cent in the absence of a prophylactic programme (Gorelick *et al.*, 1982; Øgaard *et al.*, 2001). From an aesthetic point of view the anterior maxillary segment is most important. Gorelick *et al.* (1982) found that the highest percentage incidence was found in this segment (15.3 per cent). In the present study the incidence of new lesions in both groups were lower in this segment compared with the study by Gorelick *et al.*

(1982). This may be due to the study design and the prophylactic programme. Gorelick *et al.*'s study was retrospective with no organized prophylactic programme, whereas in the present prospective investigation, both groups were informed about the aims of the study and given appropriate oral hygiene instruction both prior to and during the study. Compliance with the fluoride regimens were controlled regularly during the entire treatment period at the check-ups of the appliance. In addition, fluoride exposure from toothpastes/mouthrinses with AmF/SnF₂ or NaF was excessive and sufficient to build up reservoirs of fluoride which are important during cariogenic challenges. Still, fewer lesions developed on the upper anterior teeth in the meridol® group (4.3 per cent) compared with the NaF (7.2 per cent) group during treatment. The difference between WSL at bonding and debonding was statistically significant in the NaF group but not in the meridol® group.

The improved inhibiting effect of the AmF/SnF₂ compared with the NaF products may be due to several factors. AmF/SnF₂ products have a lower pH than NaF products. The pH of the AmF/SnF₂ was between 4 and 5 and for the NaF products between 6 and 7. It is well established that the major reaction product formed on enamel during short exposures such as brushing with toothpaste or rinsing is a calcium fluoride-like material (Rølla *et al.*, 1993). At neutral pH this calcium fluoride is contaminated with phosphate and has a higher rate of dissolution than calcium fluoride with less internal phosphate formed at lower pH (Christoffersen *et al.*, 1988). Support for such a hypothesis can be found in an article by Koch *et al.* (1982) comparing the cariostatic effect of toothpaste with different fluoride concentrations and pH. They observed that a toothpaste with 250 ppm F as NaF at pH 5.5 reduced caries development to the same extent as a neutral 1000 ppm NaF, which may be due to the quality of the calcium fluoride-like material deposited (Øgaard *et al.*, 2004).

In plaque associated with fixed orthodontic appliances, the pH may drop below 4. At this low pH plaque fluid will be undersaturated with respect to fluorapatite and no remineralization will occur. However, a calcium fluoride material with less internal phosphate is less soluble than fluorapatite and may protect the enamel as such against dissolution (ten Cate and Duijsters, 1983). This may be a significant factor since plaque pH is generally lower and hence clearance of fluoride can occur faster in the plaque on the upper anterior teeth than in other areas in orthodontic patients (Arneberg *et al.*, 1997).

Furthermore, the increase in plaque and gingival inflammation in the upper anterior region seen during treatment in the NaF group was not observed when the meridol® products were used. Less plaque and gingivitis, and perhaps also reduced acid production in plaque (Damen *et al.*, 2002), indicate a less severe cariogenic environment around the orthodontic appliance and may thus have

contributed to the improved cariostatic effect of the meridol® products.

Conclusions

The combined use of an AmF/SnF₂ toothpaste/mouthrinse had a slightly more inhibiting effect on white spot lesion development on maxillary anterior teeth during fixed orthodontic treatment compared with NaF products. Also, visible plaque and gingivitis were significantly lower on the upper anterior teeth after using the AmF/SnF₂ products. The clinical significance of these findings must be interpreted carefully as caries increment and plaque accumulation was low in these patients. However, a prophylactic regimen based on daily use of an AmF/SnF₂ toothpaste/mouthrinse may be recommended during treatment with fixed orthodontic appliances.

Address for correspondence

Professor Bjørn Øgaard
Department of Orthodontics
Faculty of Dentistry
University of Oslo
PO Box 1109
Blindern
Oslo 0317
Norway
E-mail: bogaard@odont.uio.no

Acknowledgement

The authors wish to thank Mrs Brita Einehag for technical assistance with the study. The study was supported by GABA International, Basel, Switzerland.

References

- Ainamo J, Bay I 1975 Problems and proposals for recording gingivitis and plaque. *International Dental Journal* 25: 229–235
- Arneberg P, Giertsen E, Emberland H, Øgaard B 1997 Intra-oral variations in total plaque fluoride related to plaque pH – a study in orthodontic patients. *Caries Research* 31: 451–456
- Årtun J, Brobakken B O 1986 Prevalence of carious white spots after orthodontic treatment with multibonded appliances. *European Journal of Orthodontics* 8: 229–234
- Baehni P C, Takeuchi Y 2003 Anti-plaque agents in the prevention of biofilm-associated oral diseases. *Review. Oral Diseases* 9: 23–29
- Brexx M, Brownstone E, MacDonald L, Gelskey S, Cheang M 1992 Efficacy of Listerine, Meridol and chlorhexidine mouthrinses as supplements to regular tooth cleaning measures. *Journal of Clinical Periodontology* 19: 202–207
- Büyükyılmaz T, Øgaard B 1994 Caries-preventive effects of fluoride releasing materials. *Advances in Dental Research* 9: 377–383
- Christoffersen J, Christoffersen M R, Kibalczyk W, Perdok W G 1988 Kinetics of dissolution and growth of calcium fluoride and effects of phosphate. *Acta Odontologica Scandinavica* 46: 325–336

- Damen J J, Buijs M J, ten Cate J M 2002 Acidogenicity of buccal plaque after a single rinse with amine fluoride-stannous fluoride mouthrinse solution. *Caries Research* 36: 53–57
- Gorelick L, Geiger A M, Gwinnett A J 1982 Incidence of white spot formation after bonding and banding. *American Journal of Orthodontics* 81: 93–98
- Einwag J, Hellwig E, Hotz P, Stadtler P 1995 The relative caries-inhibiting efficacy of amine fluoride and sodium fluoride in compatible dentifrices – results of a consensus conference. *Quintessence International* 26: 707–713
- Klimek J, Tussing F, Ganss C 1998 Effect of aminefluoride stannous fluoride mouthrinses on the acidogenic potential of established dental plaque. *Journal of Dental Research* 77: 3172 [abstract]
- Koch G, Petersson L G, Kling E, Kling L 1982 Effect of 250 and 1000 ppm fluoride dentifrice on caries. A three-year clinical study. *Swedish Dental Journal* 6: 233–238
- Mengel R, Wissing E, Schmitz-Habben A, Flores-de-Jacoby L 1996 Comparative study of plaque and gingivitis prevention by AmF/SnF₂ and NaF. A clinical and microbiological 9-month study. *Journal of Clinical Periodontology* 23: 372–378
- Mizrahi E 1983 Surface distribution of enamel opacities following orthodontic treatment. *American Journal of Orthodontics* 84: 323–331
- Øgaard B 1989a Incidence of filled surfaces from 10–18 years of age in an orthodontically treated and untreated group in Norway. *European Journal of Orthodontics* 11: 116–119
- Øgaard B 1989b Prevalence of white spot lesions in 19-year olds: a study on untreated and orthodontically treated persons 5 years after treatment. *American Journal of Orthodontics and Dentofacial Orthopedics* 96: 423–427
- Øgaard B, Bishara S E, Duschner H 2004 Enamel effects during bonding–debonding and treatment with fixed appliances. In: Graber T M, Eliades T, Athanasiou A E (eds.) *Risk management in orthodontics: experts' guide to malpractice*. Quintessence, Chicago, pp. 19–46
- Øgaard B, Gjermo P, Rølla G 1980 Plaque-inhibiting effect in orthodontic patients of a dentifrice containing stannous fluoride. *American Journal of Orthodontics* 78: 266–272
- Øgaard B, Larsson E, Henriksson T, Birkhed D, Bishara S E 2001 Effects of combined application of antimicrobial and fluoride varnishes in orthodontic patients. *American Journal of Orthodontics and Dentofacial Orthopedics* 120: 28–35
- Pakhomov G N, Moller I J, Atanassov N P, Kabackchieva R I, Sharkov N I 1997 Effect of an amine fluoride dentifrice on dental caries used in a community-based oral health education program. *Journal of Public Health Dentistry* 57: 181–183
- Rølla G, Øgaard B, Cruz R de Almeida 1993 Topical application of fluoride on teeth. New concepts of mechanism of interaction. *Journal of Clinical Periodontology* 20: 105–108
- Shapira L, Shapira M, Tandlich M, Gedalia I 1999 Effect of amine fluoride-stannous fluoride containing toothpaste (Meridol) on plaque and gingivitis in adults: a six-month clinical study. *Journal of International Academic Periodontology* 1: 117–120
- ten Cate J M, Duijsters P P 1983 Influence of fluoride in solution on tooth demineralization. II. Microradiographic data. *Caries Research* 17: 513–519
- Warrick J M, Miller L L, Doan E J, Stookey G K 1999 Caries-preventive effects of sodium and amine fluoride dentifrices. *American Journal of Dentistry* 12: 9–13

Copyright of European Journal of Orthodontics is the property of Oxford University Press / UK and its content may not be copied or emailed to multiple sites or posted to a listserv without the copyright holder's express written permission. However, users may print, download, or email articles for individual use.