

Cervical spine curvature and craniofacial morphology in an adult Caucasian group: a multiple regression analysis

Simona Tecco and Felice Festa

Department of Oral Science, University G.D'Annunzio, Chieti, Pescara, Italy

SUMMARY The aim of this study was to investigate the relationship between cervical curvature and skeletal facial morphology. Pre-treatment lateral cephalograms in natural head position were obtained from 98 orthodontic adult subjects (56 males and 42 females; mean age = 31.5 years, standard deviation ± 5.8 years). The amount of concavity of the cervical curvature was calculated by a second-order quadratic interpolation of the most infero-posterior points of the bodies of the seven cervical vertebrae on the radiographs. Linear regression with stepwise elimination was carried out to evaluate the sagittal and vertical craniofacial dimensions.

The results revealed that the amount of curvature was related to (1) the horizontal position of the upper incisors with respect to the maxillary and mandibular skeletal bases and (2) the sagittal millimetric dimension of the maxillary base. These cephalometric variables explained 51 per cent of the total variance of cervical curvature. There was no significant correlation between cervical curvature and any other cephalometric variable. Cervical curvature was not influenced by age or gender.

Introduction

From a lateral view, the cervical spine is generally concave with the concavity facing dorsally. Alignment of the cervical segment of the spine has been studied radiographically in adult volunteers without neck symptoms (Hardacker *et al.*, 1997). It has been demonstrated that most cervical lordosis occurs at the C1–C2 level, whereas only 6 degrees (15 per cent) occurs at the lowest three cervical levels (C4–C7), and that during standing the cervical curvature shows a strong negative correlation with thoracic angular measurements (Hardacker *et al.*, 1997).

The anatomy and position of the cervical curvature in space have been related to different factors concerning general aspects of the body: ethnicity (Solow *et al.*, 1982; Cooke and Wei, 1988; Grave *et al.*, 1999), gender (Borden *et al.*, 1960; Rechtman *et al.*, 1961; Solow *et al.*, 1982; Cooke and Wei, 1988; Hardacker *et al.*, 1997), age (Borden *et al.*, 1960; Rechtman *et al.*, 1961; Hellsing *et al.*, 1987a), stature (Huggare and Laine-Alava, 1997), and craniofacial morphology (Gresham and Smithells, 1954; Bench, 1963; Solow and Tallgren, 1976; Marcotte, 1981; Özbek and Köklu, 1993; Festa *et al.*, 2003).

Cervical posture and the anatomy of C1 have been related to factors such as nasorespiratory function (Kylämarkula and Huggare, 1985; Huggare and Raustia, 1992), temporomandibular dysfunction (TMD; Huggare and Raustia, 1992; D'Attilio *et al.*, 2004), and orthodontic therapy, e.g. removable orthodontic appliances and removable splints to increase the vertical occlusal dimension (Miralles *et al.*, 1997) and to the use of anterior repositioning devices in the treatment of children with skeletal Class II malocclusions (Tecco *et al.*, 2005).

Concerning craniofacial morphology, in particular, cervical posture has been related to the shape of face: subjects with a long dolichocephalic face have a straight, long, forwardly inclined cervical column, whereas brachycephalic subjects usually have increased lordosis of the spine (Bench, 1963).

Cervical posture has also been related to mandibular length, as the longer the mandible, the more inclined the cervical column to the true horizontal (Özbek and Köklu, 1993). It has also been shown that the longer the mandible, the straighter the cervical column, i.e. the lower the cervical lordosis angle (Festa *et al.*, 2003), even in adult patients with TMD (D'Attilio *et al.*, 2004). The cervical lordosis angle in children and adolescents (Hellsing *et al.*, 1987a,b) has also been related to mandibular divergence, as the higher the divergence, the lower the cervical lordosis angle, both in adult subjects with and without TMD (D'Attilio *et al.*, 2004). There is debate regarding the mechanism involved. Kantor and Norton (1987) observed that the normal lordotic curve can be altered as a result of cervical muscle spasm that causes the patient to posture the head in an effort to reduce pain and discomfort. On the other hand, cervical muscle spasm could also be related to a changed input from the stomatognathic apparatus (Sessle *et al.*, 1986; Coderre *et al.*, 1993). The reason may be found in the neurophysiological principles of convergence and sensitization, which is based on the principle that if a constant nociceptive input on second-order neurons increases the sensitivity of these neurons then non-nociceptive neural impulses from other areas within the same segment, which converge into these neurons, may give rise to nociceptive sensations (Sessle *et al.*, 1986; Coderre *et al.*, 1993).

For the craniocervical region, a constant nociceptive input from, for example, the upper part of the trapezius can result in increased sensitivity of the spinal trigeminal nucleus. Non-nociceptive stimuli from the masticatory system would then lead to painful sensations from the trigeminal region (Sessle *et al.*, 1986; Coderre *et al.*, 1993). In these cases, craniomandibular and cervical pain will be experienced and the pain could induce the patient to a new head posture in order to decrease pain.

Moya *et al.* (1994) studied the effect of occlusal splints on craniocervical relationships in 15 subjects with sternocleidomastoid and trapezius muscle spasms. Cephalometric analysis confirmed that the splint caused a significant extension of the head on the cervical spine. There was also a significant decrease in cervical spine lordosis in the C1–C3 segment.

Many studies have underlined the importance of muscles in stabilizing the cervical spine and the existence of various connections between muscles of the facial and neck regions (Marcotte, 1981; Ferrario *et al.*, 1992; Panjabi *et al.*, 1998; Kettler *et al.*, 2002; Maeda *et al.*, 2002). Firstly, muscles were found to be capable of stabilizing the spinal column *in vitro* and *in vivo* (Kettler *et al.*, 2002), mostly the C0–C2 segment (occipital bone–C2) in all loading and injury states of the cervical spine, while the role of the osteoligament system on stabilization was not so conclusive (Maeda *et al.*, 2002). In fact, the osteoligamentous apparatus of the cervical spine would not be able to sustain the weight of the head, because its critical load has been shown to be approximately one-fifth to one-quarter of the weight of the average head (Panjabi *et al.*, 1998). A recent study (Hellström *et al.*, 2002) showed that the presence of reflex connections between the temporomandibular joints (TMJ), nociceptors (stimulated through the injection of bradykinin in the ipsilateral TMJ), and the fusimotor–muscle spindle system of the dorsal neck muscles in a cat might be involved in the pathophysiological mechanisms responsible for sensory-motor disturbances in the neck region often found in patients with TMJ alterations.

Finally, it is well documented that change is observed in electromyographic (EMG) activity of the cervical muscle during routine oral functions in healthy subjects (Miralles *et al.*, 1997). There was a significant increase of the basal EMG activity of the sternocleidomastoid and trapezius muscles when the vertical dimension was varied every few millimetres from occlusion to 45 mm of jaw opening (Miralles *et al.*, 1997).

Several authors have underlined the importance of the developmental origin of the upper and the lower tracts of the cervical spine (Graber, 1958; Hellsing *et al.*, 1987a,b). It has been hypothesized that there is a different developmental origin for the upper and lower segments of the cervical column, while upper segment development was considered to be closely linked to facial development, the lower segment was classically considered as the final upper part of the column

(Graber, 1958). Hellsing *et al.* (1987a,b) in 125 children, aged 8, 11, and 15 years of both genders, showed, with increasing age, highly significant correlations between thoracic and lumbar curvature development, while no correlation was found between the cervical lordosis angle and thoracic kyphosis. These results suggest that curvature of the cervical spine develops in close union with the craniofacial complex and not with the rest of column. The same observation was also confirmed in a longitudinal controlled evaluation of a group of preadolescent females with a skeletal Class II malocclusion treated with a functional appliance, because the change in the stomatognathic input (due to the functional therapy) caused a change in the inclination of the upper tract of the cervical column but no variation in the inclination of the lower tract (Tecco *et al.*, 2005).

The influence of craniofacial morphology on curvature of the cervical column has generally been investigated through simple correlation analysis. This approach, however, ignores the simultaneous contribution of multiple factors to the individual variation of the curve. Therefore, the aim of this study was to determine the relationship between cervical column curvature and several features of craniofacial morphology by means of multiple regression analysis. The influence of gender and age on the amount of the curvature was also investigated.

Subjects and methods

Sample and clinical records

Pre-treatment lateral skull radiographs of 98 patients were selected from the archives of the Orthodontic Department at the University of Chieti, Italy. The population investigated comprised 56 males and 42 females [mean age = 31.5 years, standard deviation (SD) = ± 5.8 years, range = 18–51 years], each with a different type of vertical and sagittal skeletal discrepancy. The subjects were selected from an initial sample of 620 patients taken from the archive.

The inclusion criteria were as follows: Caucasian ethnic origin and older than 18 years of age. Ethnicity was controlled through an anamnestic questionnaire about the origin of the family. Subjects were excluded if they fulfilled the following additional criteria: previous orthodontic treatment (other than that undertaken at the University of Chieti), self-reported muscle pain in the cervical area or symptoms of TMD, and finally if they had a negative cervical lordosis, since this cannot be considered a physiological posture of the spine and is due to a postural disorder (Grave *et al.*, 1999; D'Attilio *et al.*, 2004).

Lateral skull radiographs were taken by a single technician using the Orthoceph 10E (Siemens AG, Berlin, Germany), whose vertical adjustability allowed for the recording of standing subjects. The X-ray device had a focus of 0.6 mm. The exposure data were 80–86 kV and 32 mA. The film was fixed at a focus plane distance of 190 cm and a midsagittal focus

plane distance of 10 cm, with a final enlargement of 10 per cent. For all subjects, 18 × 24-cm films were used. A 20 × 100-cm mirror was placed on the wall, 150 cm in front of the ear rods, to allow the recording of natural head posture (NHP) and the mirror position (Mølhave, 1958; Festa *et al.*, 2003). The recordings were carried out between the hours of 08:00 and 14:00.

Measurement of cervical spine curvature

On each lateral skull radiograph, the bodies of all the cervical vertebrae (C4–C7) and also the odontoid process were identified. The infero-posterior point of each body and the more posterior point of the odontoid process were marked and entered into a Cartesian axis reference (Figure 1).

The x-axis was superimposed on a line connecting the infero-posterior point of the body of C7 and the posterior point of the odontoid process; the origin was at the middle point of this line, and the y-axis was perpendicular to the x-axis through the origin.

Digitized co-ordinates of the infero-posterior points of the vertebral bodies were interpolated with a best-fit second-order polynomial function: $y = a + bx + cx^2$. The second-order polynomial function was chosen because it can describe the intrinsic shape of the cervical curvature.

The curve of cervical column (cervical curve) was calculated as $c \times 10^4$. This coefficient indicates the concavity of the curve; the larger it is, the more concave the curve. When the cervical curve is equal to 0, the curve is a straight line. By convention, the concavity of the curve is lordotic when the sign is positive and cifotic when the sign is negative. In this study, subjects with negative cervical lordosis values were excluded.

Digitization of points, calculation of Cartesian co-ordinates, and interpolation of the curve were performed by a single examiner (ST) using specific software (Adobe Photoshop 5.0, Microsoft Excel 97).

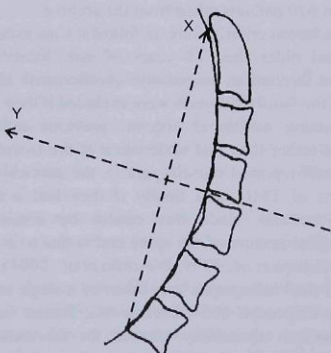


Figure 1 Cartesian axis references used for measurement of the cervical curve.

The procedure for measurement of the cervical curvature was similar to that described by Ferrario *et al.* (1992) for measurement of the curve of Spee.

Cephalometric measurements

The cephalometric measurements shown in Figure 2 were used to evaluate the sagittal and vertical craniofacial dimensions (Osborn, 1993).

Error of the method

The method employed in this study to obtain radiographs in NHP has been used in other investigations and its reliability confirmed after inter- and intra-operator investigations (Festa *et al.*, 2003).

The error of the method, associated with digitization of the points, was calculated on 34 randomly selected radiographs. The radiographs were traced twice with an interval of 1 week between the first and the second tracing by one author (ST).

The method error (ME) for all measurements was assessed using Dahlberg's (1940) formula

$$ME = \sqrt{\sum d^2 / 2n},$$

where d is the difference between the two measurements and n the number of recordings.

The mean errors were, in general, low. The errors for distance varied between 0.1 and 1.0 mm. The mean error for the cervical curve was 0.7 degrees, range 0–1.8 degrees.

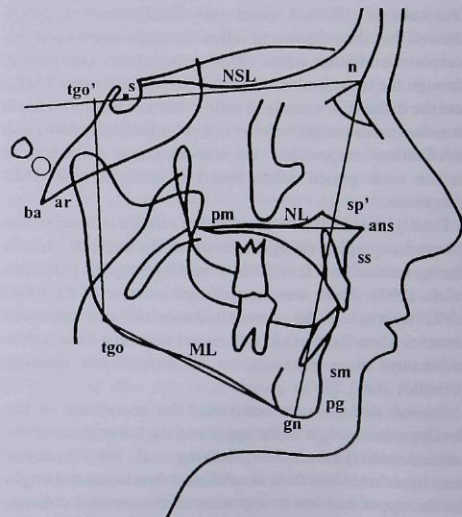


Figure 2 Vertical, horizontal, and dental measurements used to evaluate the craniofacial dimensions.

There was no systematic error for either cephalometric measurements or the coefficient cervical curve.

Statistical analysis

The data were analysed with conventional descriptive statistics. The mean, SD, and range were calculated for the cervical curve and for all the cephalometric variables. The normal distribution fitting of the data collected was tested by means of a Kolmogorov-Smirnov test. The hypothesis that data collected were normally distributed could not be rejected for any variable; therefore, subsequent analyses were performed using parametric statistical tests.

The goodness of fit of the cervical curve was calculated by correlation coefficients.

A multiple linear regression analysis with stepwise elimination was performed. The cervical curve was considered as the response variable. Explanatory variables included in the model were 'gender', 'age', and the cephalometric measurements previously described.

All the analyses were carried out using the Statistical Package for Social Sciences 8.0 (SPSS Inc., Chicago, Illinois, USA). Statistical significance was accepted at $P < 0.05$.

Results

Descriptive statistics for the cephalometric measurements are given in Table 1. The correlation coefficients for the cervical curve ranged from 0.56 to 0.99 (mean \pm SD = 0.86 ± 0.03).

After stepwise elimination, the total variance of cervical curvature explained by the regression model was 51 per cent. The adjusted R^2 was 45.7 per cent.

The amount of cervical curvature was significantly related to the millimetric horizontal length of the maxillary base (PNS-vpOK) and to the position of the upper incisor (1 + A-Pog; Table 2). No significant relationship was found between cervical curvature and any other cephalometric measurement. Cervical curvature was not significantly influenced by the age or gender of the subject.

Discussion

In this study, the cephalometric variables evaluated were precisely chosen to underline the aggregate effect of those morphological variables that have previously been shown to be related to cervical posture, i.e. shape of the face (Bench, 1963), vertical dimensions and mandibular divergence (Bench, 1963; Hellsing *et al.*, 1987a,b; D'Attilio *et al.*, 2004), mandibular size, (Özbek and Köklü, 1993; Festa *et al.*, 2003; D'Attilio *et al.*, 2004), maxillary base length (Hellsing *et al.*, 1987a,b; Festa *et al.*, 2003), and some dental variables (Hellsing *et al.*, 1987a,b; Festa *et al.*, 2003). However, these variables were considered in aggregation in a multiple regression analysis.

In addition, in this investigation, a particular construction was used to analyse cervical curvature shape (i.e. cervical lordosis). Previously, cervical curvature has been described as the down-opened angle between CVT (a line through the infero-posterior points of C2 and C4) and EVT (a line through the infero-posterior points of C4 and C6; Hellsing *et al.*, 1987a,b; Festa *et al.*, 2003; D'Attilio *et al.*, 2004; Tecco *et al.*, 2005). The method used in the present investigation, however, seems to better describe the intrinsic shape of the curvature as it included points taken on all the cervical vertebrae (except C1), and not those of only three cervical vertebrae.

In this study, cervical curvature was considered as the outcome or dependent variable in the multiple regression analysis. This measurement can be considered sufficiently reliable, because analysis revealed no significant ME in the determination of cervical curvature.

The mathematical and statistical approach used allows description of the intrinsic cervical curvature shape. As revealed by the coefficient of variation, the amount of the cervical curvature was highly variable among the individuals. Nevertheless, in only three patients was an inverse curvature (reversed curve) found, and these were excluded.

In the subjects investigated, the amount of curvature was not influenced by gender. The lack of sexual dimorphism was contrary to previous findings obtained using another method to define the shape of the curve (Hellsing *et al.*, 1987a,b). However, it seems to be in agreement with Borden *et al.* (1960) and Rechtman *et al.* (1961) who ascertained, in a roentgenographic study of the cervical spine of 180 asymptomatic Caucasians chosen at random, that the depth of cervical lordosis varies considerably in normal individuals, although it seems to be similar in both males and females. The findings could be explained by the fact that the age range was different in the three studies: while Hellsing *et al.* (1987a,b) investigated preadolescent children, Borden *et al.* (1960), Rechtman *et al.* (1961), and the present study focused on an adult sample.

No evidence was found concerning the potential relationship between cervical curvature and age. The effect of age on cervical curvature has been investigated in growing subjects up to young adulthood (Borden *et al.*, 1960; Rechtman *et al.*, 1961; Hellsing *et al.*, 1987a,b; Grave *et al.*, 1999).

Hellsing *et al.* (1987a,b) showed a correlation between age and cervical lordosis in a sample of children; as cervical lordosis angle was greater in the older subjects and seemed to increase with the age. On the contrary, Borden *et al.* (1960) and Rechtman *et al.* (1961), in an adult sample, found that cervical curvature did not change with time and was approximately the same in both genders, although it seemed to increase in females over 50 years compared with males.

It could be hypothesized that with increasing age and, consequently, in adults, homogeneous morphological and postural wear may occur as a consequence of a decrease in

Table 1 Summary statistics for age, cervical curvature, and cephalometric variables of the examined subjects ($n=98$).

	Minimum	Maximum	Mean	SD
Age (years)	18.0	51.0	31.5	5.8
Cervical curve	4.0	51.6	19.7	12.7
Cephalometric variables				
SNA ($^{\circ}$)	74.0	95.0	82.2	3.8
SNB ($^{\circ}$)	70.0	91.0	78.2	4.3
ANB ($^{\circ}$)	-9.0	6.0	4.0	3.1
NSL/ML ($^{\circ}$)	18.0	48.0	31.7	6.7
FH/ML ($^{\circ}$)	8.0	38.0	19.8	6.9
ANS-PNS/ML ($^{\circ}$)	0.0	38.5	22.5	6.7
Ini+Api+/ANS-PNS ($^{\circ}$)	89.00	125.5	108.5	8.9
Ini-Api-/ML ($^{\circ}$)	81.0	106.0	94.5	7.4
Incisal angle ($^{\circ}$)	108.0	157.5	131.3	13.1
1- A-Pog (mm)	-3.0	9.5	4.7	2.7
1+ A-Pog (mm)	-3.0	10.5	2.6	1.3
Cd-Go (mm)	41.0	69.0	56.1	7.6
Cd-A (mm)	73.0	108.0	91.5	6.3
PNS-vpOK point (mm)	41.0	63.0	51.0	5.1
S-N (mm)	60.0	77.0	69.7	3.5
O-M (mm)	28.0	56.0	43.5	6.1
O-J (mm)	27.0	52.0	41	5.8

SD, standard deviation; SNA, angle between the sella-nasion line and the nasion-A line; SNB, angle between the sella-nasion line and nasion-B line; ANB, angle between A-nasion line and B-nasion line; NSL/ML, angle between the sella-nasion line and the mandibular line; FH/ML, angle between the Frankfort line and the mandibular line; ANS-PNS/ML, angle between the palatal line and the mandibular line; Ini+Api+/ANS-PNS, angle between the long axis of the upper incisor and the palatal plane; Ini-Api-/ML, angle between the long axis of the lower incisor and the mandibular plane; incisal angle, angle between the long axis of the upper and lower incisors; 1- A-Pog, distance between the vestibular point of the upper incisor crown and the A-Pog line; 1+ A-Pog, distance between the vestibular point of upper incisor crown and the A-Pog line; Cd-Go, distance between gonion and condyloid; Cd-A, distance between Cd and point A; PNS-A', point, maxillary body length, distance between PNS and A' point, that is the projection of point A on the palatal plane; S-N, distance between S point and N point; O-M, distance between points O and M (where O is the intersection point between the occlusal plane and the posterior border of the mandibular ramus and M the molar inter-occlusal point); O-J, distance between points O and J (where J is the upper intersection point between the mandibular perimeter and the perpendicular line to the occlusal plane through O). These last two measurements were assessed according to Osborn (1993).

the amount of growth. This could result in a lack of correlation between age and cervical curvature in the adult sample.

Multiple regression analysis suggests that cervical curvature is more marked in subjects with a lower maxillary base length (PNS-vpOK; $B = -0.938$, $R^2 = 0.24$, $P < 0.05$). These results also suggest that cervical curvature shape is associated with the distance of the coronal point of the upper incisors to the A-Pog plane, as the more protruded the upper incisors, the greater the cervical curvature (1+ A-Pog; $B = 1.372$, $R^2 = 0.27$, $P < 0.05$).

Subjects with a shorter maxillary base and more protruded upper incisors are often skeletal Class III, in which the dental system adjusts or compensates for the skeletal discrepancy by varying the inclination of the anterior teeth, in order to decrease the difference between

the maxillary and the mandibular bases in the sagittal plane.

The present results seem to suggest that subjects with a lower maxillary length and a dental compensation of the discrepancy between maxillary and mandibular bases have a more lordotic cervical curve in the sagittal plane. The findings are contrary to the results of a previous cross-sectional investigation of adult Caucasian females (Festa *et al.*, 2003), where maxillary length was found to correlate only with anterior cranial base length. This may be due to the fact that in the present investigation the aggregate effect of morphological variables and not single areas of the face was evaluated.

Overall, the findings, at least for the variables included in this study, suggest that cervical curvature has only a weak

Table 2 Stepwise multiple regression analysis for the cervical curve.

Dependent variable		B	SE B	Standardized coefficients	R ² change	P-value
Cervical curve	(Constant)	62.015	21.796			0.011
	1+ A-Pog	1.372	0.518	0.468	0.27	0.016
	PNS-vpOK	-0.938	0.416	-0.398	0.24	0.037

Cervical curve is the dependent variable, B the unstandardized regression coefficient, and SE B the standard error of B.

influence on craniofacial morphology. Fifty per cent of the variation in curvature remains unexplained by these variables, and could probably be better explained by other factors. It would be interesting to evaluate the simultaneous contribution of several muscular lines of action to curvature variation.

Conclusions

Cervical column curvature is highly variable between individuals and had only a weak influence on the investigated craniofacial morphological variables included in this study. Variation of the curve was explained by the sagittal position of the upper incisors and, to an equal extent, by the horizontal dimension of the maxillary base. Cervical curvature is independent of gender, and no evidence was found for a relationship between age and the amount of curvature in adult subjects.

Address for correspondence

Simona Tecco
Via Le Mainarde 26
65121 Pescara
Italy
E-mail: simtecc@tin.it

References

- Bench R W 1963 Growth of the cervical vertebrae as related to tongue, face, and denture behavior. *American Journal of Orthodontics* 49: 183–214
- Borden A G, Rechtman A M, Gershon-Cohen J G 1960 The normal cervical lordosis. *Radiology* 74: 806–809
- Coderre T J, Katz J, Vaccarino A L, Melzack R 1993 Contribution of central neuroplasticity to pathological pain: review of clinical and experimental evidence. *Pain* 52: 259–285
- Cooke M S, Wei S H Y 1988 Intersex differences in craniocervical morphology and posture in southern Chinese and British Caucasians. *American Journal of Physical Anthropology* 77: 43–51
- Dahlberg G 1940 Statistical methods for medical and biological students. George Allen and Unwin Ltd., London
- D'Attilio M *et al.* 2004 Cervical lordosis angle measured on lateral cephalograms; findings in skeletal Class II female subjects with and without TMD: a cross sectional study. *Cranio, The Journal of Craniomandibular Practice* 22: 27–44
- Ferrario V F, Sforza C, Miani A, Colombo A, Tartaglia G 1992 Mathematical definition of the curve of Spee in permanent healthy dentitions in man. *Archives of Oral Biology* 37: pp. 691–694
- Festa F *et al.* 2003 Relationship between cervical lordosis and facial morphology in Caucasian women with skeletal Class II malocclusion: a cross-sectional study. *Journal of Craniomandibular Practice* 21: 121–129
- Graber T M 1958 Implementation of the roentgenographic cephalometric technique. *American Journal of Orthodontics* 44: 906–932
- Grave B, Brown T, Townsend G 1999 Comparison of cervicovertebral dimensions in Australian Aborigines and Caucasians. *European Journal of Orthodontics* 21: 127–135
- Gresham H, Smithells P A 1954 Cervical and mandibular posture. *Dental Record* 74: 261–264
- Hardacker J W, Shuford R F, Capicotto P N, Pryor P W 1997 Radiographic standing cervical segmental alignment in adult volunteers without neck symptoms. *Spine* 22: 1472–1480
- Hellsing E, Reigo T, McWilliam J, Spangfort E 1987a Cervical and lumbar lordosis and thoracic kyphosis in 8, 11 and 15-year-old children. *European Journal of Orthodontics* 9: 129–138
- Hellsing E, McWilliam J, Reigo T, Spangfort E 1987b The relationship between craniofacial morphology, head posture and spinal curvature in 8, 11 and 15-year-old children. *European Journal of Orthodontics* 9: 254–264
- Hellström F, Thunberg J, Bergenheim M, Sjölander P, Djupsjöbacka M, Johansson H 2002 Increased intra-articular concentration of bradykinin in the temporomandibular joint changes the sensitivity of muscle spindles in dorsal neck muscles in the cat. *Neuroscience Research* 42: 91–99
- Huggare J Å V, Raustia A 1992 Head posture and cervicovertebral and craniofacial morphology in patients with craniomandibular dysfunction. *Journal of Craniomandibular Practice* 13: 435–440
- Huggare J Å V, Laine-Alava M T 1997 Nasorespiratory function and head posture. *American Journal of Orthodontics and Dentofacial Orthopedics* 112: 507–511
- Kantor M L, Norton L A 1987 Normal radiographic anatomy and common anomalies seen in cephalometric films. *American Journal of Orthodontics and Dentofacial Orthopedics* 91: 414–426
- Kettler A, Hartwig E, Schultheiss B M, Claes L, Wilke H J 2002 Mechanically simulated muscle forces strongly stabilize intact and injured upper cervical spine specimens. *Journal of Biomechanics* 35: 339–346
- Kylämarkula S, Huggare J Å V 1985 Morphology of the first cervical vertebra in children with enlarged adenoids. *European Journal of Orthodontics* 7: 93–96
- Maeda T, Arizono T, Saito T, Iwamoto Y 2002 Cervical alignment, range of motion, and instability after cervical laminoplasty. *Clinical Orthopaedics and Related Research* 401: 132–138
- Marcotte M R 1981 Head posture and dentofacial proportions. *Angle Orthodontist* 51: 208–213
- Miralles R *et al.* 1997 Increase of the vertical occlusal dimension by means of a removable orthodontic appliance and its effect on craniocervical relationships and position of the cervical spine in children. *Journal of Craniomandibular Practice* 15: 221–228
- Mølhave A 1958 En biostatisk undersøgelse. Mennesketes stående stilling teoretisk og stato-metriske belyst. With an English summary [A biostatistical investigation of the human erect posture]. Munksgaard, Copenhagen
- Moya H, Miralles R, Zuniga C, Carvajal R, Rocabado M, Santander H 1994 Influence of stabilization occlusal splint on craniocervical relationships. Part I: cephalometric analysis. *Journal of Craniomandibular Practice* 12: 47–51
- Osborn J W 1993 Orientation of the masseter muscle and the curve of Spee in relation to crushing forces on the molar teeth of primates. *American Journal of Physical Anthropology* 92: 99–106
- Özbek M M, Köklü A 1993 Natural cervical inclination and craniofacial structure. *American Journal of Orthodontics and Dentofacial Orthopedics* 104: 584–591
- Panjabi M M, *et al.* 1998 Critical load of the human cervical spine: an *in vitro* experimental study. *Clinical Biomechanics* 13: 11–17
- Rechtman A M, Boreadis Borden A G, Gershon-Cohen J 1961 The lordotic curve is the cervical spine. *Clinical Orthopaedics* 20: 208–216
- Sessle B J, Hu J W, Amano N, Zhong G 1986 Convergence of cutaneous, tooth pulp, visceral, neck and muscle afferents onto nociceptive and non-nociceptive neurones in trigeminal sub-nucleus caudalis (medullary dorsal horn) and its implications for referred pain. *Pain* 27: 219–235
- Solow B, Tallgren A 1976 Head posture and craniofacial morphology. *American Journal of Physical Anthropology* 44: 417–435
- Solow B, Barrett M J, Brown T 1982 Craniocervical morphology and posture in Australian Aborigines. *American Journal of Physical Anthropology* 59: 33–45
- Tecco S *et al.* 2005 Evaluation of cervical spine posture after functional therapy with FR-2: a longitudinal study. *Cranio, The Journal of Craniomandibular Practice* 23: 53–66

Copyright of European Journal of Orthodontics is the property of Oxford University Press / USA and its content may not be copied or emailed to multiple sites or posted to a listserv without the copyright holder's express written permission. However, users may print, download, or email articles for individual use.