

Stability of upper incisor inclination changes in Class II division 2 patients

H. Devreese*, G. De Pauw*, G. Van Maele**, A. M. Kuijpers-Jagtman*** and L. Dermaut*

*Orthodontic Department, School of Dentistry, **Center for Medical Statistics, University of Ghent, Belgium and

***Department of Orthodontics, University of Nijmegen, The Netherlands

SUMMARY The aim of this study was to evaluate the changes in incisor inclination following orthodontic treatment in Class II division 2 patients, and to assess the long-term stability after retention. Dental casts and cephalograms of 61 Class II division 2 patients (31 males and 30 females, mean age 13.4 years) with a closed lip seal were available before (T1), at the end of treatment (T2), and 3.5 years (mean) post-treatment (T3). A method of measuring upper incisor inclination on dental casts was developed for the purpose of the investigation. This involved placing markers on the study casts and then taking radiographs which were measured to establish the upper incisor inclination.

Statistical analysis of the data included the calculation of mean values, standard deviation, standard errors, and ranges for each variable. Spearman ranked correlation coefficients were computed for selected model variables and scattergrams plotted. To investigate the influence of the chosen retention therapy, a Mann–Whitney *U*-test was used.

The mean change in incisor inclination during orthodontic treatment was 15.2 degrees. There was a mean relapse of 2.2 degrees between T2 and T3, but this was not considered clinically relevant. The amount of relapse was independent of the type of the retention appliance (Hawley type retainer or lingual retainer).

The relationship between long-term stability of the incisor inclination and between the lip line relative to the upper incisors was also investigated, based on cephalometric data. A mean decrease in lip line height of 0.6 mm was seen at T2 and, although the observed change was statistically significant, it would not be clinically relevant.

Introduction

A Class II division 2 malocclusion is characterized by retroclination of two or more maxillary incisors, retroclination of the lower incisors, a Class II molar relationship and an increased overbite (van der Linden, 1983). One of the most important features is the high position of the lower lip in relation to the maxillary incisors (Luffingham, 1982; van der Linden, 1983; Lapatki *et al.*, 2002).

Orthodontic treatment of Class II division 2 malocclusions is known to be difficult and prone to relapse (Canut and Arias, 1999). Maintenance of post-treatment results is reported to depend upon the intensity and direction of mandibular growth during and after retention (Riedel, 1960; Payne, 1964; Schudy, 1968; Simons and Joondeph, 1973). Some authors have found a significant correlation between the long-term stability of treated Class II division 2 malocclusions and a relative decrease in lower lip coverage of the maxillary incisors (Mills, 1973; Fletcher, 1975; Luffingham, 1982; van der Linden, 1986; Selwyn-Barnett, 1991; Lapatki *et al.*, 2002).

As relapse is often observed after retention, the height of the lip line could be one of the causative factors. However, the influence of forces exerted by the lips, cheeks, and tongue on the position of the teeth is still the subject of scientific debate (Weinstein *et al.*, 1963; Proffit, 1978).

The long-term stability of the correction of upper incisor inclination has not been well investigated. A small relapse in incisor inclination was reported by Binda *et al.* (1994) and Kim and Little (1999), while Mills (1973) found approximately 50 per cent relapse.

These studies were all performed on lateral head films and it is known that significant measurement errors can be involved in cephalometric landmark identification (Hatton and Grainger, 1958; Baumrind and Frantz, 1971a, b; Midtgård *et al.*, 1974; Houston, 1983; Houston *et al.*, 1986; Sandler, 1988). A study by Tng *et al.* (1994) found that the upper incisor edge was generally estimated to be further forward (0.6 mm) than the true landmark, thereby tending to overestimate proclination of the teeth. They suggested that the main cause of such errors was the overlapping of the images of the four upper incisors on the lateral cephalograms and encouraged the development of alternative methods to determine upper incisor inclination.

Therefore, the purpose of this study was: (1) to determine upper incisor inclination on dental casts by comparing a new method of measurement with conventional measurement on lateral cephalograms, (2) to evaluate changes in incisor inclination after orthodontic treatment in Class II division 2 patients, and (3) to investigate the relationship between long-term stability of incisor inclination and lip line height.

Materials and methods

Materials

For the main study, the records of 61 Class II division 2 patients (31 males and 30 females) were selected from patient files at the Orthodontic Departments of the University of Nijmegen, The Netherlands, and the University of Ghent, Belgium. All patients were treated and followed-up between 1985 and 2003. The mean age of the subjects before treatment (T1) was 13.4 years [standard deviation (SD) = 4.4 years]. The age distribution of the sample is presented in Table 1.

This classification of a Class II division 2 malocclusion was based on the existence of a Class II molar relationship and obvious retroclination of both upper central incisors. In addition, all subjects had competent lips on the lateral cephalograms.

All patients were treated using full upper and lower fixed appliances and the treatment plans varied depending upon the individual characteristics of each malocclusion at the start of treatment, with many treatments being two phase (removable and fixed appliances). The mean treatment time was 3.5 years (SD = 1.0 years) and all patients were treated to a normal overjet and overbite at the end of treatment.

Thirty-one patients (18 males and 13 females, mean age = 13.9 years at T1) wore Hawley retainers after orthodontic treatment, while 30 patients (13 males and 17 females, mean age = 13.0 years at T1) had an upper lingual retainer. The type of retention appliance was not randomly selected, but depended on patient compliance, oral hygiene during treatment, and the original clinical situation.

Dental casts and lateral cephalograms were available at the start of treatment (T1), at the end of active orthodontic treatment (T2), and an average of 3.4 years post-treatment (T3).

Radiographs of the dental casts, with radiographic markers (see below), were taken at T1, T2, and T3 and compared. The upper incisor inclination on the dental casts was defined as the angle between the inclination of the upper left central incisor and the line connecting both palatal reference points (method 7, Table 2). The measurements were carried out on the left central incisor for each patient in order to standardize the method. The left central incisor was chosen as it had the smallest magnification.

The cephalograms were used for evaluation of the lip line height in relation to the incisal edge. Lip line height was assessed by measuring the distance AB (difference in height between the upper incisal edge and the lip line), perpendicular to the sella-nasion line (Figure 1) and was recorded to the nearest half millimetre.

Methods

Upper incisor inclination was measured on standardized radiographs of dental casts using three radiographic markers

Table 1 Age distribution of the patients and observation periods.

	Mean age (years)	SD	Range
Pre-treatment (T1)	13.4	4.4	7–34.4
End of active orthodontic treatment (T2)	16.8	4.2	12–36.3
Post-treatment (T3)	20.3	5.1	15–42.3
	Duration (years)	SD	Range
Mean treatment duration	3.5	1.0	1.0–5.9
Mean retention duration	3.4	2.0	1.0–9.0

(Figure 2a–c). The first marker was made by cutting a 1-mm wide lead strip from a used radiographic film which was attached to the crown of the upper left central incisor to create a clear image of the outline of the crown on a radiograph. The strips were attached by bonding from the middle (mesio-distally) of the labial crown-root junction and over the middle of the incisal edge to the middle of the palatal crown-root junction, in an attempt to outline the crown in a sagittal dimension on the lateral radiograph of the cast (Dippenaar, 2003). Two other lead markers were used as reference points on the palate. To register these reference points radiographically, two different markers were used (Table 2): small lead bars made from the lead film-strips (methods 1–6), and small lead balls (methods 7 and 8). A standardized radiograph (Planmeca®, Prostyle Intra, Illinois, USA) of the dental cast was taken in a self-developed mini-cephalostat (Figure 3).

Different set-ups of the dental casts, with variation in the positions of the reference points, were tested to find the most accurate measurement procedure on the dental cast (Table 2). Two different reference lines (different positions of the reference points) were also tested. All reference points were marked on the midsagittal palatal plane. The medial first rugae were used as the first reference point. In methods 1, 3, and 5, the second reference point was placed on the medial third rugae, while in methods 2, 4, 6, 7, and 8, this point was placed more distally in the area of the fovea palatina. As the fovea palatina were not observable on every dental cast, a second reference point was placed on a recognizable point on the median raphe line, at fovea palatina height (Lebret, 1962). Measurements were carried out both on tracings and directly on the radiographs of the dental casts.

To determine the inclination of the upper central incisor on the radiographs of the cast, two different inclination lines were tested (Figure 2d). In methods 1–4, the images of the ends of the lead film-strip (gingival margins of the central incisor) were connected. The midpoint of this line was connected with the incisal edge and the constructed line was defined as the incisal inclination line (Figure 2d, method 1). In methods 5–8, the point of a pair of compasses was placed at the incisal edge and an arc constructed in the area of the

Table 2 Results of the pilot study to determine the most appropriate method for the main investigation.

	Method 1	Method 2	Method 3	Method 4	Method 5	Method 6	Method 7	Method 8
Reference points	Bars, 1st rugae, 3rd rugae	Bars, 1st rugae, fovea palatina	Bars, 1st rugae, 3rd rugae	Bars, 1st rugae, fovea palatina	Bars, 1st rugae, 3rd rugae	Bars, 1st rugae, fovea palatina	Balls, 1st rugae, fovea palatina	Balls, 1st rugae, fovea palatina
Incisal inclination line (see Figure 2d)	I	I	I	I	II	II	II	II
Measuring procedure	Tracing	Tracing	Directly	Directly	Directly	Directly	Directly	Directly*
Error of the method ($n = 10$)	s: 2.61	s: 2.44	s: 1.60	s: 1.26	s: 1.41	s: 1.20	s: 0.42	s: 0.49

*In an attempt to visualize the reference points more clearly on the radiograph, the cast used in method 7 was reduced in width (method 8) by sagittal grinding of all teeth, except the central incisors.

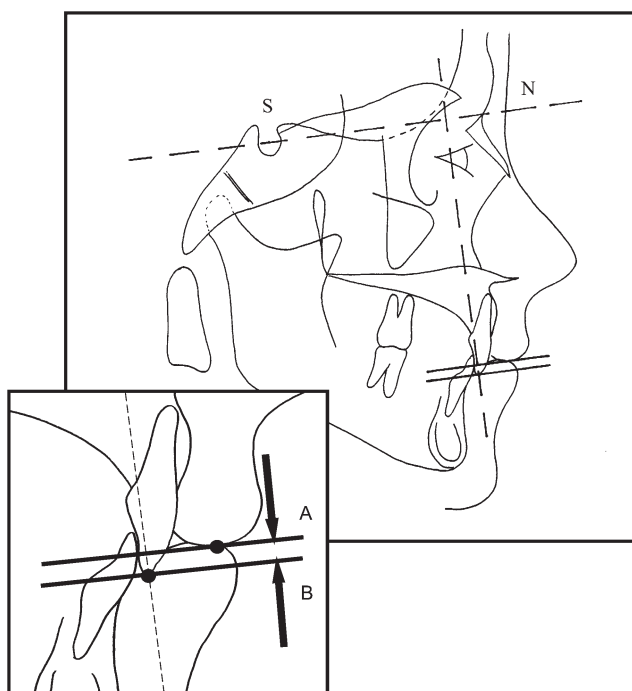


Figure 1 Determination of lip line height. AB: difference in height between the upper incisal edge and the lip line, perpendicular to the sella-nasion (S–N) line.

cemento-enamel junction, intersecting the crown. The incisal inclination line was defined as the perpendicular bisector on AB (Figure 2d, method 2).

To visualize the reference points more clearly on the radiograph, the cast in method 7 was reduced in width (method 8) by sagittal grinding of all teeth, except the central incisors. All measuring procedures were repeated 10 times on the same dental cast by the same investigator (HD; Table 2).

Method 7 was established as being the most accurate method, with the lowest SD, and was therefore selected for use in this study. To test the validity of method 7, a pilot

study ($n = 10$) was undertaken to compare changes in upper incisor inclination with measurements on conventional lateral cephalograms. The difference in inclination of the central incisors at T1 and T2 was measured on cephalograms (where the angle between the upper incisor inclination axis and the line sella-nasion was measured) and on the radiographic images of the dental casts.

Statistical analysis

Pilot study. The reproducibility of the measurements on the radiographs of the dental casts and the lateral cephalograms was assessed, according to Dahlberg's formula (1940), by analysing the difference between repeated measurements, taken 2 months apart:

$$s = \sqrt{\frac{\sum d^2}{2n}}$$

(where d is the difference between duplicated measurements and n is the number of double measurements).

The measurement error of the central incisor inclination on dental casts and cephalograms was 1.4 and 2.3 degrees, respectively. These results indicated that the proposed measurement procedure on dental casts (method 7) appeared to be a valid alternative to conventional cephalometric measurements.

Main study. Statistical analysis of the data included the calculation of mean values, SD, standard errors, and ranges for each variable. Spearman ranked correlation coefficients were computed for selected model variables and scattergrams plotted. To investigate the influence of the chosen retention therapy, a Mann–Whitney U -test was used.

Results

The changes in upper incisor inclination are summarized in Tables 3 and 4. Incisor inclination increased during treatment by an average of 15.2 degrees (SD = 9.2 degrees)

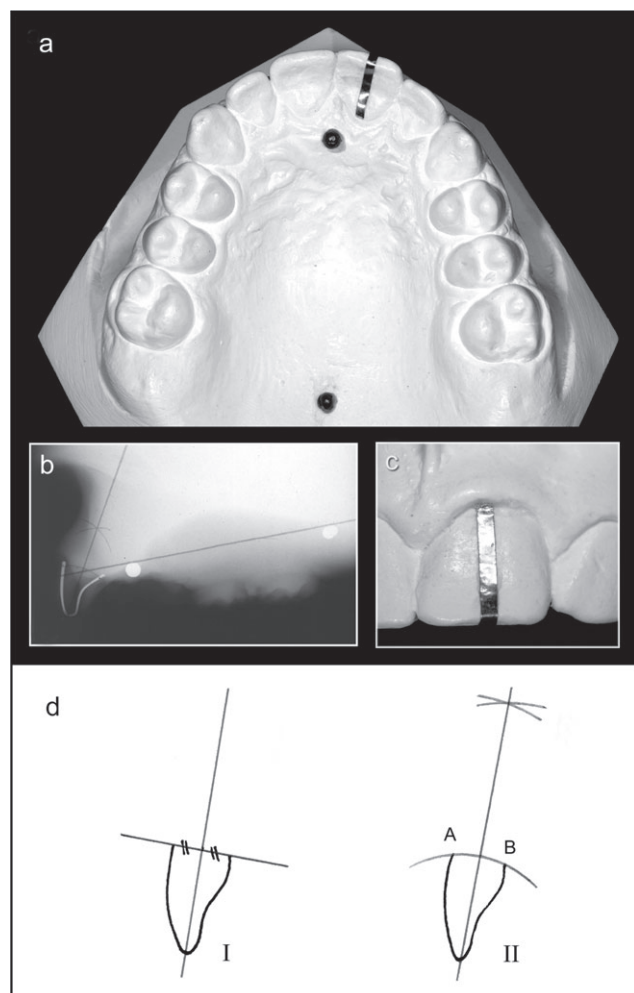


Figure 2 (a) Dental cast with lead film-strip and reference points on the palate. (b) Standardized radiograph of a dental cast. (c) Lead film-strip on the left upper central incisor. (d) Two measuring methods to determine the incisal inclination line (see Table 1).

and this was statistically significant ($P < 0.01$). Between T2 and T3, there was an average relapse of 2.2 degrees (SD = 4.1), hence there was a significant mean net change in incisor inclination of 13.0 degrees (SD = 7.2; $P < 0.01$).

There was a strong relationship ($R = 0.79$; $P < 0.01$) between the change in inclination of the upper central incisors during orthodontic treatment (T1–T2) and the net result at T3 (T1–T3), suggesting that the treatment changes were relatively stable. The scattergram also show that changes in inclination of the upper central incisors seemed to be relatively stable (Figure 4). Nevertheless, there was a significant negative correlation ($R = -0.61$; $P < 0.01$) between the amount of proclination and/or torque of the incisors during orthodontic treatment (T1–T2) and the amount of relapse (T2–T3). The more the incisors were proclined and/or torqued during treatment, the more relapse occurred afterwards.

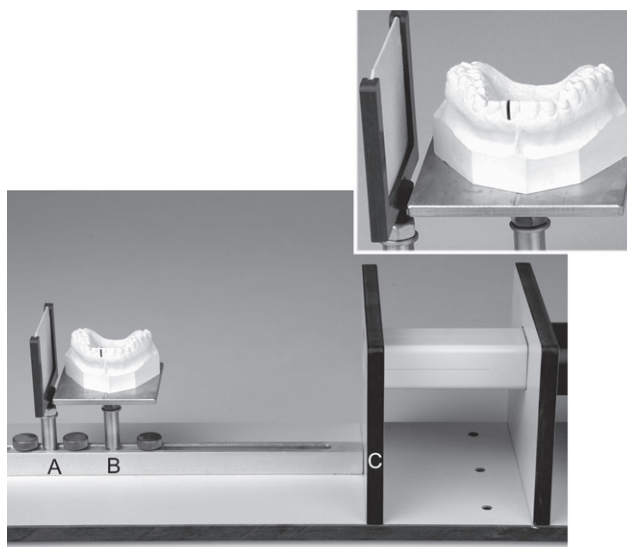


Figure 3 Self-developed mini-cephalostat. AB, film–midsagittal plane dental cast (50 mm); AC, film–long cone (250 mm); BC, midsagittal plane dental cast–long cone (200 mm).

Table 3 Changes in upper incisor inclination ($n = 61$) at T1, before orthodontic treatment; T2, at the end of active orthodontic treatment; T3, 3.4 years (mean) post-treatment.

	Mean	SD	Min	Max
T1–T2 (°)	15.2	9.2	4.0	52.0
T2–T3 (°)	–2.2	4.1	6.0	–17.0
T1–T3 (°)	13.0	7.2	4.0	35.0

Table 4 Correlations between the investigated parameters T1: before orthodontic treatment; T2: at the end of active orthodontic treatment; T3: 3.4 years (mean) post-treatment.

	Change in upper incisor inclination (T1–T3)	Change in upper incisor inclination (T2–T3)
Change in upper incisor inclination (T1–T2)	0.79**	–0.61**
Treatment time (years)	0.30*	–0.05
Retention time (years)	–0.02	–0.02
Age at T1	–0.04	–0.15

* $P < 0.05$; ** $P < 0.01$.

A small, but significant positive correlation ($R = 0.30$; $P < 0.05$) was observed between the net result at T3 (change in UI inclination T1–T3) and treatment duration. The longer the treatment duration, the larger the net change in incisor inclination.

There was no significant correlation between the amount of relapse and either treatment duration or the age at T1.

Thirty-one patients wore an upper Hawley type retainer and 30 an upper lingual retainer. The average change in incisor inclination during therapy was comparable for both

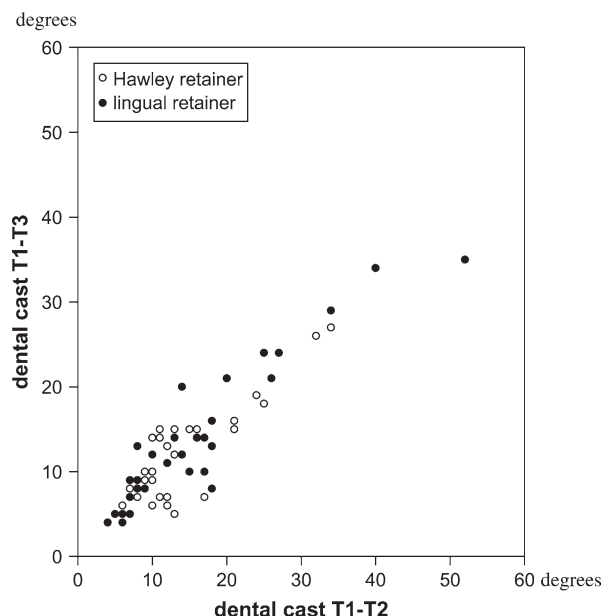


Figure 4 Scattergram of the correlation between upper incisor inclination at the end of treatment (T2) and post-treatment (T3) depending on the retention appliance used ($R = 0.79$).

groups: 14.4 degrees (SD = 6.9) for the Hawley retainer group and 16.0 degrees (SD = 11.1) for the lingual retainer group. The amount of relapse was similar in both groups: 2.3 degrees (SD = 3.9) for the Hawley type retainer group versus 2.1 degrees (SD = 4.4) for the lingual retainer group. There was no significant difference between the amount of relapse in incisor inclination and the type of retention. Nor was there any significant correlation between the amount of relapse and the duration of the retention period.

A significant decrease in lip line height of 0.6 mm (SD = 1.3) was observed after treatment, with an average relapse of 0.1 mm at T3. Although these changes were statistically significant, they are unlikely to be clinically relevant.

Discussion

Few studies have reported cephalometric errors for measurement of upper incisor inclination. Baumrind and Frantz (1971b) found a measurement error of 1.9 degrees for upper incisor inclination (UI/NA). Sandler (1988) reported an error of 2.3 degrees for this variable, while Kamoen *et al.* (2001) noted an error of 1.2 degrees. In the current pilot study, an error of 2.3 degrees was noted for the upper central incisor inclination to sella-nasion line.

Jacobson (1995) suggested that dental casts cannot be used to ascertain incisor inclination, because the plaster bases of the casts can be trimmed in different ways. Nevertheless, a small number of studies have used dental casts to assess incisor inclination. Carey (1952) utilized an

incisor angulator, while Lundström (1955) used a sliding gauge. Three-dimensional assessment techniques and contour tracings have also been employed (Lear, 1976; Richmond and Jones, 1985; Richmond, 1987). Techniques have also been described relating dental casts to lateral head films (Bennett and Smales, 1968; Perera, 1981). Richmond *et al.* (1998) described an alternative method of assessing incisor inclination with a 'tooth inclination protractor'. The tooth inclination protractor records the crown inclination to the occlusal plane. However, assessment of the crown inclination to the occlusal plane may be variable and the validity of the occlusal plane as a reference line is questionable. By comparing dental casts pre- and post-treatment, the occlusal planes may undergo changes during treatment. All the procedures described in these studies have some limitations; some have non-stable reference planes, while others are too complicated to use on large experimental groups. For this reason, attempts have been made to find stable reference lines on the palate of study casts, with the palatal rugae being studied extensively in the literature.

Simmons *et al.* (1987) found that the medial rugae were unstable reference points. In contrast, Lebet (1962) reported that the distances between the rugae landmarks were almost constant, especially for rugae points near the median raphe. Peavy and Kendrick (1967) and Almeida *et al.* (1995) found that the lateral ends of the rugae were greatly affected by movement of the teeth, but the medial rugae appeared to be a suitable anatomic landmark for the construction of stable reference points for longitudinal cast analysis. van der Linden (1978) observed that the rugae usually show remarkable stability in their antero-posterior relationships. His conclusion was that the rugae lend themselves to the analysis of the sagittal displacements of buccal teeth in normal developing dental arches. Bailey *et al.* (1996) concluded that the medial and lateral points of the third palatal rugae are stable landmarks for the construction of reference planes in the evaluation of tooth movements in transverse, vertical, and AP directions, in both extraction and non-extraction cases. They stated that the stability of the first and second palatal rugae is limited and depends on the type of orthodontic treatment. They also concluded that, although there is some lack of stability of these rugae both within and even between groups, the mean changes are often too small to be clinically relevant. Hoggan and Sadowsky (2001) concluded that rugae are as reliable as cephalometric superimpositions to assess AP molar displacements. The use of dental casts is not only more cost-effective, but does not require radiation exposure to the patient.

In the present investigation, the reference line was defined by the medial first rugae as the most anterior point and a second point on the median raphe line, which was recognizable on the casts before and after treatment for all individuals, preferably at fovea palatina height (Lebet,

1962). By choosing reference points as far apart as possible, an attempt was made to reduce the measuring error.

Riedel (1960) suggested that Class II division 2 patients require indeterminate periods of retention due to lack of adaptation of muscle function. Selwyn-Barnett (1991) concluded that treatment of Class II division 2 malocclusions is associated with doubtful prognosis and a high probability of relapse. Mills (1973) reported that in Class II division 2 patients, the upper incisors were proclined, on average, by just over 13 degrees. After at least 1 year of retention, relapse of approximately 50 per cent was observed. In contrast, Binda *et al.* (1994) noted that proclination of the upper incisors in Class II division 2 patients was relatively stable, although significant changes were noted 5 years post-retention. This is in agreement with the findings of the current study, where a mean relapse of 2.2 degrees was observed at T3. Although this relapse was statistically significant, such small changes are unlikely to be clinically relevant.

Several authors have claimed that the stability of treated Class II division 2 malocclusions depends on the intensity and direction of mandibular growth (Riedel, 1960; Payne, 1964; Schudy, 1968; Simons and Joondeph, 1973). In the present study, which included both growing and non-growing patients, mandibular growth intensity did not appear to be an important factor with respect to the stability of upper incisor inclination.

Although it was not the aim of the study to measure the amount and/or change in overbite, the interincisal angle is an important factor and, in order to achieve and maintain adequate overbite reduction, this angle must be managed appropriately during treatment (Riedel, 1960; Schudy, 1968; Berg, 1983). Proclination of the upper incisors to a more normal inclination is obviously an important part of this process. To prevent the mandibular incisors from inclining lingually, and so increasing the overbite after orthodontic treatment, it has been suggested that a bonded retainer is necessary on the lower labial segment teeth (Schudy, 1968). However, other authors have noted that there appears to be no relationship between the interincisal angle at the end of treatment and subsequent relapse of the overbite (Hasstedt, 1956; Simons and Joondeph, 1973; Kim and Little, 1999).

Long-term stability of treated Class II division 2 malocclusions is said to be related to a relative decrease of lower lip coverage of the upper incisors (Nicol, 1954, 1955, 1963; Ballard, 1956; Ridley, 1960; Mills, 1973; Fletcher, 1975; Luffingham, 1982; van der Linden, 1983, 1986; van der Linden and Boersma, 1988; Selwyn-Barnett, 1991). In the present investigation, lower lip coverage of the upper incisors was reduced from, on average, 3.3 to 2.7 mm. During the post-treatment period, the lip position remained stable. These findings are in accordance with the results of Schweitzer and Panherz (2001) and Binda *et al.* (1994).

Furthermore, in untreated subjects with normal occlusions, Vig and Cohen (1979) found that the most marked changes in the relationship of the lower lip to the upper incisors occurred between 9 and 13 years of age. After 13 years of age, lower lip coverage of the upper incisors remained almost constant. This confirms the present findings, where the average age of the patients at the start of treatment was 13.4 years. The average change in lip line height (0.6 mm), although significant, was not considered to be clinically relevant. Therefore, it is not possible to provide an answer to the question as to whether or not lip line height plays a role in stability following upper incisor proclination.

Moreover, no difference was found between the two retention regimes and the post-treatment upper incisor inclination changes but these conclusions must be interpreted with caution due to the small sample size in both groups.

Conclusions

1. Upper incisor inclination can be measured reliably on dental casts and is a valid alternative to measurements carried out on lateral cephalograms.
2. Upper incisor inclination in Class II division 2 subjects was relatively stable after treatment.
3. The type of retention did not appear to have an influence on the long-term stability of upper incisors.
4. The changes in lip line height during and after treatment were too small to be of clinical relevance.

Address for correspondence

Professor G. De Pauw
Department of Orthodontics
University Hospital Ghent
De Pintelaan 185
9000 Ghent
Belgium
E-mail: guy.depauw@UGent.be

References

- Almeida M A, Phillips C, Kula K, Tulloch C J F 1995 Stability of the palatal rugae as landmarks for analysis of dental casts. *Angle Orthodontist* 65: 43–48
- Bailey L J, Esmailnejad A, Almeida M A 1996 Stability of the palatal rugae as landmarks for analysis of dental casts in extraction and nonextraction cases. *Angle Orthodontist* 66: 73–78
- Ballard C F 1956 Morphology and treatment of Class II, division 2 occlusions. *Transactions of the European Orthodontic Society* pp.44–54
- Baumrind S, Frantz R C 1971a The reliability of head film measurements. 1. Landmark identification. *American Journal of Orthodontics* 60: 111–127
- Baumrind S, Frantz R C 1971b The reliability of head film measurements. 2. Conventional angular and linear measurements. *American Journal of Orthodontics* 60: 505–517
- Bennett D T, Smales F C 1968 Orientated study models. *Dental Practitioner* 18: 353–355

- Berg R 1983 Stability of deep overbite correction. *European Journal of Orthodontics* 5: 75–83
- Binda S K R, Kuijpers-Jagtman A M, Maertens J K M, van 't Hof M A 1994 A long-term cephalometric evaluation of treated Class II division 2 malocclusions. *European Journal of Orthodontics* 16: 301–308
- Canut J A, Arias S 1999 A long-term evaluation of treated Class II division 2 malocclusions: a retrospective study model analysis. *European Journal of Orthodontics* 21: 377–386
- Carey C W 1952 Diagnosis and case analysis in orthodontics. *American Journal of Orthodontics* 38: 149–161
- Dahlberg G 1940 Statistical methods for medical and biological students. Interscience Publications, New York
- Dippenaar A M 2003 Utilising radiographic incisor crown markers to determine incisor inclination on lateral headfilms—an experimental study on extracted teeth. Thesis, University of Pretoria
- Fletcher G G T 1975 The retroclined upper incisor. *British Journal of Orthodontics* 2: 207–216
- Hasstedt C W 1956 A serial cephalometric study of the effects of orthodontic treatment on incisal overbite and the soft tissue profile. Thesis, University of Washington
- Hatton M E, Grainger R M 1958 Reliability of measurements from cephalograms at the Burlington Orthodontic Research Center. *Journal of Dental Research* 87: 853–859
- Hoggan B R, Sadowsky C 2001 The use of palatal rugae for assessment of anteroposterior tooth movements. *American Journal of Orthodontics and Dentofacial Orthopedics* 119: 482–488
- Houston W J B 1983 The analysis of errors in orthodontic measurements. *American Journal of Orthodontics* 83: 382–390
- Houston W J B, Mayer R E, McElroy D, Sherriff M 1986 Sources of error in measurements from cephalometric radiographs. *European Journal of Orthodontics* 8: 149–151
- Jacobson A 1995 Radiographic cephalometry. Quintessence, Chicago, pp. 1–5, 197–299
- Kamoen A, Dermaut L, Verbeeck R 2001 The clinical significance or error measurement in the interpretation of treatment results. *European Journal of Orthodontics* 23: 569–578
- Kim T-W, Little R M 1999 Postretention assessment of deep overbite correction in Class II division 2 malocclusion. *Angle Orthodontist* 69: 175–186
- Lapatki B G, Mager A S, Schulte-Mönting J, Jonas I E 2002 The importance of the level of the lip line and resting lip pressure in Class II, division 2 malocclusion. *Journal of Dental Research* 81: 323–328
- Lear C S L 1976 Three dimensional analysis of changes in location of crowns and apices of maxillary incisors. *Angle Orthodontist* 46: 338–344
- Lebret L 1962 Growth changes of the palate. *Journal of Dental Research* 41: 1391–1404
- Luffingham J K 1982 The lower lip and the maxillary central incisor. *European Journal of Orthodontics* 4: 263–268
- Lundström A 1955 Inter-maxillary tooth width ratio and tooth alignment in occlusion. *Acta Odontologica Scandinavica* 12: 266–292
- Midtgård J, Björk G, Linder-Aronson S 1974 Reproducibility of cephalometric landmarks and errors of measurements of cephalometric cranial distances. *Angle Orthodontist* 44: 56–61
- Mills J R E 1973 The problem of overbite in Class II, division 2 malocclusion. *British Journal of Orthodontics* 1: 34–48
- Nicol W A 1954 The morphology of the lips in relation to the incisor teeth. *Transactions of the British Society for the Study of Orthodontics* pp. 25–28
- Nicol W A 1955 The relationship of the lip line to the incisor teeth. *Transactions of the British Society for the Study of Orthodontics* pp. 75–81
- Nicol W A 1963 The lower lip and the upper incisor teeth in Angle's Class II, division 2 malocclusion. *Dental Practitioner* 14: 179–182
- Payne G W 1964 A cephalometric analysis of the effects of growth on certain anatomical facial planes after orthodontic treatment. Thesis, University of Washington
- Peavy D C, Kendrick G S 1967 The effects of tooth movement on the palatine rugae. *Journal of Prosthetic Dentistry* 18: 536–542
- Perera P S G 1981 Orientating dental casts to cephalometric radiographs. *Angle Orthodontist* 51: 246–251
- Proffit W R 1978 Equilibrium theory revisited: factors influencing position of teeth. *Angle Orthodontist* 48: 175–186
- Richmond S 1987 Recording the dental cast in three dimensions. *American Journal of Orthodontics and Dentofacial Orthopedics* 92: 199–206
- Richmond S, Jones M L 1985 A comparison of two and three dimensional incisor angles. *British Journal of Orthodontics* 12: 90–96
- Richmond S, Klufas M L, Sywanyk M 1998 Assessing incisor inclination: a non-invasive technique. *European Journal of Orthodontics* 20: 721–726
- Ridley D R 1960 Some factors concerned with the reduction of excessive incisor overbite in Angle's Class II, division 2 malocclusion. *Transactions of the British Society for the Study of Orthodontics* pp. 118–140
- Riedel R A 1960 A review of the retention problem. *Angle Orthodontist* 30: 179–199
- Sandler P J 1988 Effect of patient repositioning on cephalometric measurements. *British Journal of Orthodontics* 15: 17–22
- Schudy F F 1968 The control of vertical overbite in clinical orthodontics. *Angle Orthodontist* 38: 19–39
- Schweitzer M, Pancherz H 2001 The incisor-lip relationship in Herbst/multibracket appliance treatment of Class II, division 2 malocclusions. *Angle Orthodontist* 71: 358–363
- Selwyn-Barnett B J 1991 Rationale of treatment for Class II, division 2 malocclusion. *British Journal of Orthodontics* 18: 173–181
- Simmons J D, Moore R N, Erickson L C 1987 A longitudinal study of anteroposterior growth changes in the palatine rugae. *Journal of Dental Research* 66: 1512–1515
- Simons M E, Joondeph D R 1973 Change in overbite: a ten-year post-retention study. *American Journal of Orthodontics* 64: 349–367
- Tng T T H, Chan T C K, Hägg U, Cooke M S 1994 Validity of cephalometric landmarks. An experimental study on human skulls. *European Journal of Orthodontics* 16: 110–120
- van der Linden F P G M 1978 Changes in the position of posterior teeth in relation to rugae points. *American Journal of Orthodontics* 74: 142–161
- van der Linden F P G M 1983 Development of the dentition. Quintessence Publishing Co., Inc., Chicago
- van der Linden F G P M 1986 Facial growth and facial orthopedics. Quintessence Publishing Co., Inc., Chicago
- van der Linden F P G M, Boersma H 1988 Diagnose und Behandlungsplanung in der Kieferorthopädie. Band 3. Quintessenz Verlag, Berlin
- Vig P S, Cohen A M 1979 Vertical growth of the lips: a serial cephalometric study. *American Journal of Orthodontics* 75: 405–415
- Weinstein S, Haack D C, Morris L Y, Snyder B B, Attaway H E 1963 On an equilibrium theory of tooth position. *Angle Orthodontist* 33: 1–26

Copyright of European Journal of Orthodontics is the property of Oxford University Press / UK and its content may not be copied or emailed to multiple sites or posted to a listserv without the copyright holder's express written permission. However, users may print, download, or email articles for individual use.