

## The tissue reaction as related to the functional factor

Kaare Reitan

University of Bergen, Norway

(*Transactions of the European Orthodontic Society 1951, pp. 123–136*)

The tissue reaction following orthodontic tooth movement and its relation to functional influences has been a problem frequently discussed during the last 15 years. Earlier studies on tissue changes, those made by Sandstedt (1905), Oppenheim (1911), Schwarz (1932), Stuteville (1938), Gubler (1941) and others, did not include the functional factor to any great extent. As we know, it was Häupl (1938), Häupl and Psansky (1938) and Eschler (1939), who called attention to this factor as possibly being of importance in functional orthopaedics, treatment performed with Andresen plates, the so-called activators.

In a study, just recently published (Reitan, 1951), I have made an attempt to investigate the functional factor as related to treatment with fixed appliances as well as plates. One should assume that this is a problem of academic interest only, but it certainly also has its practical side. The problem touches upon fundamental principles of construction and application of orthodontic appliances as a whole. To-day I should like to draw some conclusions from my findings.

It is well known that a tooth moved by continuous forces will usually be slightly tipped, particularly in its initial movement. Bone resorption will occur at the pressure side, while there will be bone apposition at the tension side. A secondary pressure and tension side may be found in the apical region as well (Fig. 1).

Some of my experiments were performed with continuous forces in dogs. The active force was provided by springs coiled around high labial arches of the type described by Friel and McKeag (1939). The arches were anchored to the canines and the upper and lower second incisors in each dog were moved labially by forces measuring from 15 to 60 grams and with a duration varying from 12 to 48 hours.

The animals used for experiments were divided in two groups. One group of dogs were allowed free movement and normal function of the teeth. Another group of young dogs of the same age were treated orthodontically with the same type of appliances. But the jaws in these animals were immobilized by means of a wooden block or screen inserted behind the canines. This screen extended up to the roof of the palate and down to the floor of the lower jaw, thus preventing the tongue from coming in contact with the anterior teeth. The jaws were tied to this block and thus securely fixed. The lips were also held away from the teeth. In addition, the animals were kept sleeping as long as the experiments lasted by injections of various kinds or drugs. Hence, the material included two groups of

dogs, similarly treated, but of these one group had non-functioning teeth.

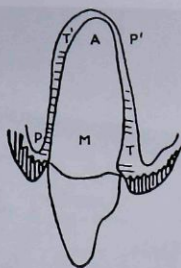
The histological sections were cut horizontally, including structures of the first and third incisors, these teeth serving as controls (Fig. 2). In sections taken from the marginal region, an evaluation could be made of how and when the earliest tissue changes were perceptible. By comparing the two groups of material, one could also observe to what extent these changes were influenced by external functional stimuli such as mastication and movement of lips and tongue.

It was found that the incidence of resorptive changes at the pressure side corresponded fairly well with the incidence of formative changes observed at the tension side. The tissue reaction at the tension side is of special interest. An examination of these structures reveals the formative changes as observed in the earliest stage of tooth movement.

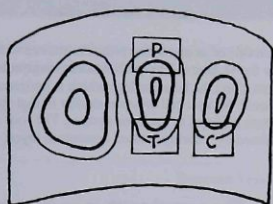
An initial bone formation in the supporting structures of teeth is usually characterized by cell proliferation and formation of osteoid tissue. At the tension side the proliferation of cells is readily recognized in histological sections. Figure 3 represents the control slide taken from the first incisor in one of the animals with jaws out of function. The cells are fibrocytes with rather small nuclei. There is a thin layer of preformed uncalcified osteoid along the bone surface. The tension side of the tooth moved is seen in Figure 4. It reveals an increase in cellular elements, and at the same time widening or apposition of osteoid tissue. Widened fibre bundles are confluent with the newly formed osteoid. The osteoid layer will calcify later on and then appears as bundle bone with Sharpey's fibres incorporated in its matrix.

The cells seen in this area have large nuclei (Fig. 5). They are young hypertrophied fibroblasts produced by the tension exerted on the fibres. Fibrils from their cytoplasm are connected to widened fibre bundles. In this initial stage, the cells multiply by mitotic cell division as seen in Figure 5.

It has been claimed that functional stimuli are of great importance for formation of new cells and osteoid tissue. This may be true, nevertheless, my own findings indicate that tension alone may precipitate such production, especially in young individuals. Hence, formative changes occur more or less independently of a functional factor. The incidence of increased cell proliferation is seen in Table 1. Sixteen teeth moved in animals with non-functioning teeth



**Figure 1** Pressure area, P, and tension area, T, created in the marginal region, M. Secondary pressure area, P', and tension area, T', in the apical region.

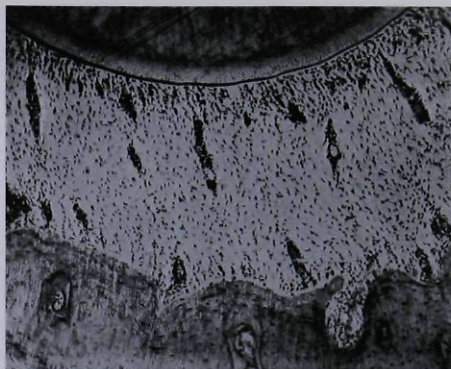


**Figure 2** Drawing of a section including the third, second and first upper right incisors. T, tension side and P, pressure side of the tooth moved. C, lingual control area of the first incisor.

revealed cell proliferation mostly after a period of 36 hours. Almost similar findings were made in animals whose teeth were in normal function. As to the formation of osteoid tissue, the incidence of such production was almost the same (Table 2). New osteoid tissue had been produced after periods of 36 and 48 hours in both groups. One may therefore state that the time factor is of greater importance than the amount of force applied.

In experiments of up to 2 weeks duration, structures at the tension side of non-functioning teeth revealed that the formative changes continued. There was production of osteoid spicules. The cells were typical osteoblasts arranged in chains along the newly formed tissue.

In experiments with non-functioning teeth, advanced bone resorption was obtained after two weeks duration. Osteoclasts were seen in lacunae along the bone surface. These findings tend to show that continuous pressure or tension exerted on teeth in young animals may lead to extensive changes in the form of bone resorption and apposition, even if the jaw mechanism is out of function. It is also shown that this reaction usually requires a period of more than 24 hours before the changes become manifest. Generally speaking, the periodontal tissues in young individuals react after an experimental duration of 48 hours provided continuous forces are used. Such findings may be observed in human material as well.



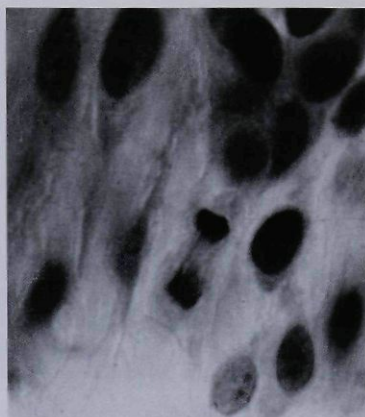
**Figure 3** Control area of the first incisor, area corresponding to C in Figure 2. The tooth is shown in the upper part of the picture. The cells seen in the periodontal space are fibrocytes with rather small nuclei. At the bone surface a thin preformed osteoid line bordering a layer of bundle bone.



**Figure 4** Tension side of the tooth moved, area indicated T in Figure 2. Large newly formed connective tissue cells are seen adjacent to the bone surface, which is bordered by a newly formed layer of osteoid tissue. The tooth was moved for 36 hours with a force of 45 grams in a dog whose jaws were out of function. (A.) Area shown in Fig. 5

The experiments on human material were performed in 12 year old patients. The control tooth in each experiment was taken from the opposite side of the jaw. First or second premolars of the upper jaw were used for these experiments. The tension side of an experimental tooth, moved with a force of 70 grams for 48 hours is seen in Figure 6. A definite increase in cellular elements is found in this region, with a corresponding widening of the osteoid layer along the bone surface. Mitotic cell division was observed in the marginal region.





**Figure 5** Newly formed cells, area marked, A, in Figure 4. These cells, with large hypertrophied nuclei, were formed as a result of the tension exerted on the fibres. A mitotic figure is shown slightly below the centre.

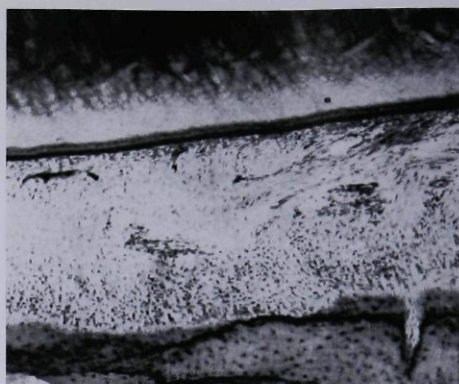**Table 1** A comparison of the incidence of cell production during the initial stage of tooth movement. It appears that no great difference exists between functioning and non-functioning structures.

Increase in the cell number at the tension side (Upper jaw)								
Non-functioning teeth				Functioning teeth				
	15g	30g	45g	60g	15g	30g	45g	60g
12 hours								
24 hours				+	+	+		+
36 hours	+	+	+		+		+	
48 hours	+	+	+	+		+	+	+

**Table 2** The incidence of newly formed osteoid is almost similar in functioning and non-functioning structures

Apposition of osteoid tissue at the tension side (Upper jaw)								
Non-functioning teeth				Functioning teeth				
	15g	30g	45g	60g	15g	30g	45g	60g
12 hours								
24 hours					+			
36 hours	+	+	+		+		+	+
48 hours	+	+	+	+	+	+	+	+

In other experiments, Andresen plates (also named activators) were used. With regard to the functional factor, it is of interest to decide whether variations in the tissue reaction exist where loose plates are used, compared with attached plates. The attached plates were provided with arrow attachments. The same number of loose and attached plates was applied, similarly expanded and used for similar



**Figure 6** Tension side of an upper first premolar moved with a continuous force of 70 grams for 48 hours. The tooth was cut longitudinally. Increase in cellular elements along the bone surface which is bordered by a layer of newly formed osteoid. Mitotic cell division similar to that shown in Figure 5, was found in areas adjacent to the bone surface. The root surface shown uppermost is bordered by a darkly stained cementum layer.

periods of time. The control tooth in each experiment was taken from the opposite side. The plates were ground, thus relieving the control teeth from contact with the palates.

The findings observed at the tension side incident to treatment with non-expanded activators are listed in Table 3. There is no increase in the cell number because little or no tension was exerted on the periodontal fibres. Concerning apposition of osteoid tissue, uncertain findings were seen in three instances. It is of interest to compare such findings with those obtained following treatments with fixed appliances. Table 4 indicates the findings made at the tension side in three experiments. Increase in the cell number was observed in two experiments. The finding in one instance was uncertain, but increase in osteoid tissue was found in all these experiments which included periods of 2, 3 and 4 days.

The changes taking place at the pressure side in experiments with non-expanded plates, are rather insignificant. With fixed appliances they were marked even after a short period of time. Bone resorption occurred after periods of 2, 3 and 4 days. There was no increase in the cell number. With gradually expanded activators, whether attached or not, five experiments revealed active bone resorption (Table 5).

These activators were all expanded. Concerning non-expanded activators, it is interesting to note that if a plate is non-expanded and really passive, neither resorption nor apposition will occur. It has been claimed that teeth may be moved even if the plate is passive. There is no such passive tooth movement from a histological point of view. In order to move a tooth, a sort of pressure or tension is always required. As seen from the present table, little or no

**Table 3** The findings observed at the tension side incident to application of non-expanded activators. There was no increase in the cell number. Uncertain findings were observed after 3 nights.

Non-expanded activators				
12 year old patients				
Type of plate	Tooth moved	Duration of experiment	Reaction Tension Side	
			Cell number	Osteoid tissue
Loose	4+	2 nights		
Attached	+4	2 nights		
Loose	+4	3 nights		
Attached	5+	3 nights	?	
Loose	+4	4 nights	+	
Attached	4+	4 nights	?	

**Table 4** It is uncertain whether there was any increase in the cell number in the experiment of 3 days duration.

Continuous force 70 g.				
12 year old patients				
Tooth moved	Duration of experiment	Reaction Tension Side		
		Cell number	Osteoid tissue	
+4	2 days	+	+	
+4	3 days	?	+	
+4	4 days	+	+	

difference in the tissue reaction is observed with regard to loose plates compared with attached plates. It is, however, interesting to note that there is an increased formation of cells in three cases.

This phenomenon occurred with attached plates in two instances. The findings are therefore not associated with the fact that the plates were loose and possibly subject to a greater movement than attached plates. On the other hand, it is as interesting to observe that incident to a pressure exerted by fixed appliances, such increase in the cell number is never found at the pressure side. In this connection I do not consider formation of osteoclasts as an increase in the cell number. In experiments in human material with fixed appliances, a beginning osteoclastic resorption was observed after 2 days, but no general increase in the cell number. On the contrary, the structures at the pressure side frequently revealed a slight decrease in cellular elements. It should be pointed out that a similar decrease may also be observed incident to a treatment with plates.

Figure 7 is taken from the pressure side of a tooth moved with continuous forces for 2 weeks in non-functioning structures. It is an animal experiment. Advanced resorptive changes are observed in this area, but no increase in the cell number, except for the osteoclasts.

**Table 5** While increase in the cell number at the pressure side is very seldom observed incident to treatment with fixed appliances, production of connective tissue cells may be obtained in experiments with plates especially after some duration. Here it occurred in three experiments.

Gradually expanded activators				
12 year old patients				
Type of plate	Tooth moved	Duration of experiment	Reaction Pressure Side	
			Cell number	Resorption
Loose	4+	5 nights		+
Attached	+4	5 nights	+	+
Loose	+4	6 nights		
Attached	+4	6 nights		
Loose	+4	8 nights		
Attached	+4	8 nights		+
Loose	+4	14 nights	+	+
Attached	+4	14 nights	+	+

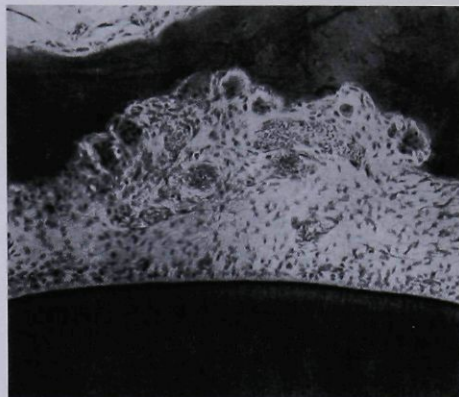
Figure 8 represents the pressure side of a tooth moved every night for 2 weeks with an attached activator. Only the bone surface with surrounding tissues is seen in this area. Decrease in the cell number was seen in some areas, but note the abundance of young connective tissue cells and osteoclasts in this zone. This occasional increase in the cell number may be attributed to nutritional factors. The nutrition of the structures involved is periodically improved as the plates are removed and not used during the day, furthermore, the intermittent action of the plate while *in situ* may have a stimulating effect. Even attached plates are frequently subject to a sort of movement while still held in place by the arrow attachments.

If a plate is heavily expanded, the structures at the pressure side may appear almost cell free due to the strong pressure exerted. At the same time, there may be cell proliferation and formation of osteoclasts in other areas, even in the middle of the periodontal space. If these teeth had been moved with fixed appliances, similar cell free areas might have been created, but no cell proliferation at the same time. The intermittent action of plates obviously improves the nutritional conditions at the pressure side in some instances according to the individual tissue reaction.

This formation of new cells at the pressure side is not frequently seen in the initial stage of tooth movement, but rather after the plate has been used for 2 weeks or more. Then cell proliferation frequently occurs after application of both types of plates, loose and attached, but seldom or never incident to treatment with continuous forces.

Considering the tension side, I have previously shown that treatment with continuous forces, implied formation of new cells and new osteoid tissue after a short period of time. This is not observed where plates are used. Formative changes at





**Figure 7** Animal experiment. Pressure side of a tooth moved in a non-functioning jaw for 2 weeks. There is no general increase in the cell number. Large osteoclasts are seen in lacunae along the bone surface.

the tension side are delayed incident to a treatment with plates. This delay is caused by what may be termed 'the daily relapse' of the tooth moved. The symbols listed in Table 6 indicate findings made at the tension side in experiments performed with expanded activators. Resorptive changes were found at the tension side in a few instances in the initial stage.

This resorption is caused by daily relapse of the tooth moved whereby the periodontal tissues at the pressure side are compressed. A reactive movement takes place as soon as the plate is removed. The relapse is due to a contraction of stretched fibre bundles and also interocclusal contact

during the day. Only after the periodontal space is sufficiently widened by resorption at the pressure side, apposition at the tension side may regularly be found, as seen in experiments of 8 and 14 night's duration.

Concerning the daily relapse, especially the free gingival fibres seem to be active during this secondary movement. Even some of the elastic fibres situated labially may be responsible for such reaction. This daily relapse must be considered a normal biological reaction of the complicated fibre system which constitutes the supporting structures of the teeth.

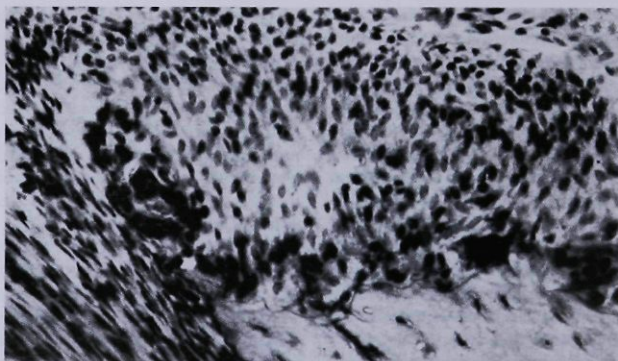
In experiments with heavily expanded activators, a similar reactive tooth movement may occur. Bone resorption was observed at the tension side in experiments of short duration but after 8 and 14 nights treatment, increase in the cell number and osteoid tissue was found.

According to these observations one may state that bone formation at the tension side may be delayed to begin with, due to the daily relapse of the tooth moved. Hence, more osteoid tissue would have been produced also in the initial stage provided plates were worn during the day as well.

As to the functional action of activators and other plates, my findings indicate that there is little or no difference in the tissue reaction with regard to the movement of individual teeth. Other studies have pointed out that activators may cause considerable changes in the jaw structures as a whole, including the muscles and the temporomandibular joint.

It has also been stated that this action is closely related to the fact that the plate is loose and not attached to the upper jaw. It is difficult to prove empirically whether there is a special increased action when the activator is loose, and less during application of attached activators.

However, provided this functional action on the jaw structures as a whole is obtained with activators, it must



**Figure 8** Experiment of 14 nights duration performed with an attached, gradually expanding activator. The bone crest is shown below bordered by multinucleated osteoclasts in their lacunae. Note the abundance of young connective tissue cells. Mitotic cell division was observed in this cell-rich area. Increase in the cell number at the pressure side is seldom observed incident to treatment with fixed appliances.

**Table 6** As seen in this table, resorption at the tension side occurred in three instances. The incidence of cell production and formation of osteoid at the tension side increased with the duration of the experiment because more space has been created by bone resorption at the pressure side.

Gradually expanded activators

12 year old patients

Type of plate	Tooth moved	Duration of experiment	Reaction Pressure Side	
			Cell number	Osteoid tissue
Loose	+4	5 nights		+
Attached	+4	5 nights	+	Resorption
Loose	+4	6 nights		Resorption
Attached	+4	6 nights		?
Loose	+4	8 nights		Resorption
Attached	+4	8 nights	+	+
Loose	+4	14 nights	+	+
Attached	+4	14 nights	+	+

be considered a separate problem, requiring further investigation, and only to some extent related to the movement of individual teeth.

The main points in this study may be summarized as follows:

1. Bone resorption and apposition may occur incident to orthodontic tooth movement, even if the structures involved are out of function.
2. There is no difference in the tissue reaction obtained with activators and attached plates, as far as movement of individual teeth is concerned.
3. Treatment with activators and other removable plates implies a daily relapse of the tooth moved, to some extent preventing formation of cells and osteoid tissue at the tension side in the initial stage.
4. The functional action of an activator is primarily related to the stimuli exerted on the temporomandibular joint, the muscles and the jaw structures as a whole. This may be regarded as a separate problem, only to some extent related to the movement of individual teeth.

## Discussion

Dr Grude: Some of you know we use the activator of Andresen and I am very grateful for the experiments of Dr Reitan to clear up the histological problems by using loose activators and attached plates and the comparison between these types. I should like to ask Dr Reitan how he decides between an attached plate and a loose plate.

When I use the activator as a loose plate I find that the important thing is what we call their 'working bite' — the height of the working bite. If I take a high working bite I get a stretch of the muscles, the masticatory muscles, and then I think that we have the same action of the plate as an

attached plate. The plate is not loose when we are taking a too high working bite. The patient has no possibility to relax the muscles when the plate is in the mouth.

I take a working bite as low as possible so that the lower jaw in rest position is not biting on the plate. Then the plate is what I call loose. Then I only get an action of the plate when the patient is swallowing or biting on the plate and I wonder how we can get results of this type by animal experiments.

Dr Anderson: Perhaps Dr Reitan could tell me how he decides that changes are taking place in the temporomandibular joint with activators. Did he do this by X-ray examination and if so, did he observe changes on the head of the condyle or in the fossa? I have done some work recently on that and we find it extremely difficult to X-ray those except by laminography. Would he please give me some information on how he came to this conclusion.

Dr Björk: I will say a few words and congratulate Dr Reitan on his excellent study. We most of us know the value in treatment of Andresen's appliance but we have been attached to a method of thinking which has nothing to do with scientific thinking and I think Dr Reitan has brought the discussion down to earth.

Dr Reitan: It is very difficult to decide, histologically, whether a plate has been loose or attached, judging from the tissue reaction, and that was just the point I stressed. Mechanically, a plate may be considered attached when held in place by some sort of attachments. It cannot fall down when the patient opens the mouth.

With regard to the action of the activator on the muscles and the jaw structures as a whole, it seems to me that this will be a problem for further investigation.

A comparison of the tissue reaction in animals and that obtained in human structures reveals that, above all, the age factor is of importance. Hence, when comparing animal and human material, one has to be careful in selecting tissues that correspond as far as the age factor is concerned, but that is also a problem for further investigation.

Considering the changes obtained in the temporomandibular joint incident to treatment with activators, my own X-rays indicate that there is possibly a slight displacement of the condyle in some cases. On the other hand, investigators like Häupl and Psansky (1938) contend that there are bone resorption and apposition at the tuberculum as well as at the head of the condyle. My own observations are not based on a very extensive material and I think we ought to ask Dr Björk about this particular side of the problem. I should also like to thank him for what he said in his discussion.

## References

- Eschler J 1939 Inwiefern stützen experimentelle Studien die Formgestaltung der parodontalen Gewebe und des Kieferknochens die Grundlage der Funktions-Kieferorthopädie. *Deutsch Zahn- Mund- und Kieferheilkunde* 6: 759
- Friel S H, McKeag H T A 1939 The design and construction of fixed orthodontic appliances in stainless steel. *Dental Record* 56: 359



- Gubler W 1941 Prinzipielles zur Frage der Verwendung aktiver Plattenapparate. Schweizerische Monatsschrift für Zahnheilkunde 51: 387
- Häupl K 1938 Gewebsumbau und Zahnverdrängung in der Funktions-Kieferorthopädie. Barth, Leipzig
- Häupl K, Psansky R 1938 Histologische Untersuchungen über die Wirkungsweise der in der Funktions-Kieferorthopädie verwendeten Apparate. Deutsch Zahn- Mund- und Kieferheilkunde 19: 641-648
- Oppenheim A 1911 Die Veränderungen der Gewebe insbesondere des Knochens bei Verschiebung der Zähne. Oesterreichisch-ungarische Vierteljahrsschrift für Zahnheilkunde 27: 302
- Reitan K 1951 The initial tissue reaction incident to orthodontic tooth movement as related to the influence of function. Acta Odontologica Scandinavica Supplementum 6
- Sandstedt C 1905 Einige Beiträge zur Theorie der Zahnregulierung. Nord tandläkare tidskrift 6: 1-25
- Schwarz A M 1932 Tissue changes incident to tooth movement. International Journal of Orthodontics and Oral Surgery 18: 331-352
- Stuteville O H 1938 A summary review of tissue changes incident to tooth movement. The Angle Orthodontist 8: 1-20

Copyright of European Journal of Orthodontics is the property of Oxford University Press / UK and its content may not be copied or emailed to multiple sites or posted to a listserv without the copyright holder's express written permission. However, users may print, download, or email articles for individual use.