

Survival of flexible, braided, bonded stainless steel lingual retainers: a historic cohort study

D. J. Lie Sam Foek*, M. Özcan**, G. J. Verkerke***, A. Sandham* and P. U. Dijkstra****

Departments of *Orthodontics, **Dentistry and Dental Hygiene, Clinical Dental Biomaterials, ***Biomedical Engineering, and ****Oral and Maxillofacial Surgery and Centre for Rehabilitation, University Medical Center Groningen, The Netherlands

SUMMARY The objectives of this study were to retrospectively evaluate the clinical survival rate of flexible, braided, rectangular bonded stainless steel lingual retainers, and to investigate the influence of gender, age of the patient, and operator experience on survival after orthodontic treatment at the Department of Orthodontics, University of Groningen, between the years 2002 and 2006.

The study group comprised of 277 patients [162 females: median age 14.8 years, interquartile range (IQR) 13.6–16.5 years and 115 males: median age 15.3 years, IQR 14.2–16.7 years]. After acid etching the lingual surfaces of each tooth, an adhesive resin was applied and retainers were bonded using a flowable resin composite. Data concerning, failures, gender, age of the patient, and operator experience were retrieved from the patient files that were updated by chart entries every 6 months or when failure was reported by the patient. The maximum follow-up period was 41.7 months. All 277 patients received flexible, braided, bonded mandibular canine-to-canine retainers. Eighteen failures were observed in the maxilla. A failure was recorded when there was debonding, fracture, or both, occurring in one arch. Only first failures were used for statistical analysis. When failures occurred in both jaws, these were considered as two separate incidences.

Ninety-nine debonding (35.7 per cent), two fractures (0.7 per cent), and four debonding and fracture (1.4 per cent) events were observed. No significant effect ($P > 0.05$) of gender (females: 41 per cent, males: 32 per cent) or patient age (<16 years: 37 per cent, ≥ 16 years 38.7 per cent) was observed. The failure rate did not differ due to operator experience ($n = 15$; less experienced: 38.0 per cent; moderately experienced: 28.9 per cent, professional: 46.7 per cent; $P > 0.05$; chi-square test). Kaplan–Meier survival curves showed a 63 per cent success rate for the bonded lingual retainers over a 41.7 month period.

Introduction

Bonded retainers are extensively used after orthodontic treatment with fixed appliances in order to maintain the achieved result by preventing secondary crowding of incisors after tooth alignment (Keim *et al.*, 2002; Zachrisson and Büyükyilmaz, 2005). Despite the various forms of retainers, the most commonly used are the thick mandibular canine-to-canine (3–3) bonded retainer bar (0.030 or 0.032 inch) and the thin 0.0215 inch, flexible, spiral wire retainers (Littlewood *et al.*, 2004, 2006; Zachrisson and Büyükyilmaz, 2005). These types of bonded retainers have been reported to have fairly high long-term (up to 15 years) success rates (Zachrisson, 1978, 1982, 1986, 1995, 1996; Dahl and Zachrisson, 1991; Bearn, 1995; Årtun *et al.*, 1997). Failure types reported in these studies were loosening (debonding) and wire breakage. For a thin flexible spiral wire in the mandible, failure rates of less than 10 per cent have been reported, particularly with the five-stranded Penta-One® wire up to 2–3 years (Årtun and Urbye, 1988; Dahl and Zachrisson, 1991; Bearn, 1995; Årtun *et al.*, 1997). However, given the importance of this phenomenon, relatively limited clinical research has been performed, with

reported mandibular failure rates ranging from 5.9 to 53 per cent (Dahl and Zachrisson, 1991; Årtun *et al.*, 1997; Andrén *et al.*, 1998; Lumsden *et al.*, 1999; Störmann and Ehmer, 2002). Although this wire type is the one most often recommended, the range of failures shows high variation, indicating that successful treatment maintenance with such wires cannot be achieved in the long-term.

When these flexible spiral wire retainers are placed meticulously, they have the advantage of allowing for safe retention of the treatment results. On the other hand, when correct retention is difficult or impossible to achieve with traditional removable appliances, flexible spiral wire retainers are considered appropriate, and they are independent of patient cooperation. They also allow slight movement of all bonded teeth and segments of teeth; they are highly efficient and, almost, invisible (Segner and Heinrich, 2000; Zachrisson and Büyükyilmaz, 2005). The disadvantages of flexible spiral wire retainers are that they may be subject to mechanical stress and, if too thin, or not placed passively onto the enamel surface, they may result in undesirable tooth movement (Årtun and Thylstrup, 1986; Dahl and Zachrisson, 1991; Årtun *et al.*, 1997).

Due to the limited number of clinical studies that have been conducted to date (Årtun *et al.*, 1997; Lumsden *et al.*, 1999; Zachrisson and Büyükyilmaz, 2005) and the large range in failure rates with twisted wires, an alternative flexible, braided wire retainer (Quad Cat® stainless steel, twisted wire, 0.022 × 0.016 inch, GAC International, Bohemia, New York, USA) is available for orthodontic treatment purposes. Unfortunately, limited clinical information is available concerning such braided wires (Southard and Southard, 1990; Zachrisson and Büyükyilmaz, 2005).

Therefore, the aims of this study were to analyse the survival rate of flexible, braided, rectangular, bonded, lingual stainless steel wire retainers by means of a historic cohort study, and to investigate the influence of gender, patient age, and operator experience on survival.

Subjects and methods

Sample

Initially, patient files, without pre-selection were retrieved from the Department of Orthodontics, Groningen, The Netherlands by undertaking a search of the computer program (OrtWin® 2.0, Netpoint, Kaatsheuvel, The Netherlands). All selected patients ($n = 277$) satisfied the inclusion criteria of having finished their orthodontic treatment with fixed appliances and having received a bonded retainer between December 2002 and May 2006.

One hundred and sixteen patients were treated with removable functional and fixed appliances (combined treatment) and 161 only with fixed appliances. All 277 patients [162 females: median age 14.8 years, interquartile range (IQR) 13.6–16.5 years and 115 males: median age 15.3 years, IQR 14.2–16.7 years] received a mandibular flexible bonded retainer from canine to canine (3-3). It is not known which proportion of the total sample also received a bonded retainer in the maxilla at baseline. A modified maxillary removable Hawley retainer was usually worn for a period of 1 year by some patients after completion of orthodontic treatment.

Application of retainers

The flexible, braided, rectangular, stainless steel wire retainers (Quad Cat®, 0.022 × 0.016 inch, GAC International) were initially prepared for the maxilla and mandible on plaster cast models by dental technicians (Ortholab Dental Technicians, Doorn, The Netherlands). Since such flexible retainers need to be bonded to each tooth (Zachrisson and Büyükyilmaz, 2005), the enamel was acid etched for 10 seconds per tooth with 38 per cent H₃PO₄ and rinsed thoroughly, before the bonding adhesive (Heliobond®, Ivoclar Vivadent, Schaan, Liechtenstein) was applied and air thinned. All retainers were bonded using a flowable resin composite (Tetric Flow®, Cavifill 210 A3, Ivoclar Vivadent) and light polymerized for 20 seconds per tooth using a

light-emitting diode polymerization device (Ortholux™, 3M Unitek, St Paul, Minnesota, USA) and placed by orthodontists ($n = 1$), postgraduate students ($n = 4$), dental hygienists ($n = 8$), or dental assistants ($n = 2$). Moisture control for the retainers were accomplished using cotton rolls and saliva ejectors. All subjects ($n = 277$) received a mandibular bonded retainer. Due to the retrospective nature of this study, the exact number of bonded retainers placed in the maxilla was unknown. If failure of a bonded retainer in the maxilla was reported, the assumption was made that there must have been a bonded retainer in the maxilla as well as in the mandible.

Follow-up

The patient data included the information derived from chart entries of clinical examinations carried out every 6 months, or when the patient reported a failure. The inclusion period for this retrospective cohort study was from December 2002 to May 2006, therefore the maximum follow-up period possible was 42 months.

Failure of a retainer occurs as a result of debonding, fracture, debonding and fracture, or retainer loss. Information was unavailable on the site of failure e.g. single tooth bond failure, enamel/adhesive failure, or adhesive wire failure. In all cases where debonding was recorded, rebonding was undertaken. When fracture and/or retainer loss occurred, a new retainer was made (Bond-A-Braid®, dead soft wire, Hilgers, Reliance Orthodontic Products Inc., Itasca, Illinois, USA) at the chairside and bonded to the enamel surfaces after cleaning the enamel of remnants of the adhesive and/or resin (Birnie, 2007).

In total, 87 failures occurred in the mandible (1 fracture, 82 debonding, and 4 debonding plus fractures). In the maxilla, 18 failures were observed (1 fracture and 17 debonding). Due to the delegation strategy at the department (system of work), different operators working under the supervision of one experienced orthodontist were allowed to place the retainers. The experience of the operators placing the retainers was categorized as 0–5 years (least experienced), 6–10 years (moderately experienced), 11–15 years (experienced), 16–20 years (most experienced), and 21 years or more (very experienced).

Statistical analysis

Statistical analysis was performed using the Statistical Package for Social Sciences (version 12.0, SPSS Inc., Chicago, Illinois, USA). Descriptive statistics and Kaplan–Meier curves were calculated. In the Kaplan–Meier curves, the cumulative survival rate of the retainers was compared against the time interval between placement of the retainers and occurrence of the first failure. Only first failures were counted and no distinctions were made in failure location in case of debonding. A reported failure in the maxilla or in the mandible was counted as a separate incidence. In addition, multiple failure sites in one retainer were counted as one

failure. Furthermore, failure was considered when there was debonding, fracture, debonding and fracture, or retainer loss. A chi-square test was used in order to analyse the influence of gender, age of the groups, and experience of the operators on the survival rate. *P* values less than 0.05 were considered to be statistically significant.

Results

The maximum follow-up period was 41.7 months (median 19.9 months, IQR 15.2–23.7, mean 19.1 months, SD 7.2). Table 1 shows a summary of the demographic characteristics of the patient population and the effect of confounding factors on the survival rate.

Of the total number of treated patients, 66.1 per cent were younger than 16 years and 33.9 per cent were older than 16 years; 58.5 per cent were female and 41.5 per cent were male. In total, 99 debonding (35.7 per cent), two fracture (0.7 per cent), and four debonding plus fracture (1.4 per cent) failures were observed. No significant effect of gender [females: 41 per cent (confidence interval, CI: 16.3–83.9), males: 32 per cent (CI: 24.8–41.8)], patient age [<16 years: 37 per cent (CI: 30.3–44.0), ≥ 16 years: 38.7 per cent (CI: 29.4–48.9)], and operator experience (least experienced: 38.5 per cent, moderately experienced: 28.9 per cent, very experienced: 46.7 per cent) on failure rate was found (chi-square test; $P > 0.05$; Figure 1).

Kaplan–Meier survival curves showed a gradual decrease in failure rate, being highest at 6 months at 78 per cent. According to the plot, if the retainers survived the first 2 years, they usually continued to function well. Figure 2 shows that the cumulative survival rate for the bonded lingual retainers was 63 per cent. Exact data for the mandibular definition indicated a survival rate of 68.4 per cent.

Discussion

Total survival rate for the flexible, lingual, braided bonded retainers was 63 per cent over an observation period of 41.7 months. The survival rate decreased during this time, with the highest number of failures being observed within the first 6 months after placement. This finding is in accordance with the results of Årtun *et al.* (1997) and Segner and Heinrici (2000). Although the retrospective design of the study contributed to the lack of data for the precise number of retainers placed in the maxilla, exact data concerning the failure rate for the mandible was found to be 31.6 per cent. These results are slightly lower than the findings of Andrén *et al.* (1998) who reported a failure rate of 35 per cent for the mandible. On the other hand, they were higher than the 18 per cent failure rate for the 0.0195 inch and lower than the 53 per cent failure rate for the 0.0215 inch retainer reported by Störmann and Ehmer (2002).

However, the failure rate found in this study was higher than the 27.2 per cent for the thin, flexible spiral wires

Table 1 Summary of the demographic characteristics of the patient population and the effect of confounding factors on the failure rate of lingual bonded retainers.

	Number of retainers placed	Failure (%)	95% confidence interval
Gender			
Females	162	41.4	34.1, 49.1
Males	115	33.3	25.3, 42.4
Age (years)*			
<16	181	37.0	30.3, 44.3
≥ 16	93	38.7	29.4, 48.9
Operator experience (years)†			
0–5	200	38.5	32.0, 45.4
6–10	—	—	—
11–15	—	—	—
16–20	45	28.9	17.7, 43.4
≥ 21	30	46.7	30.3, 63.9

*Data of three patients missing.

†Number of patients treated by operators ($n = 15$). Note that data of two patients were missing.

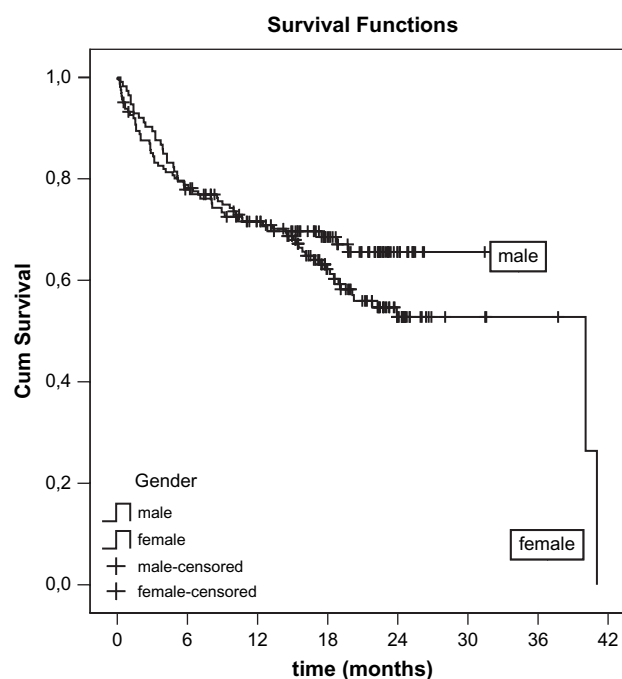


Figure 1 Cumulative survival rates of bonded lingual retainers for females ($n = 162$) and males ($n = 115$).

reported by Årtun *et al.* (1997). Similarly, Dahl and Zachrisson (1991) reported a failure rate of 10.3 per cent with the use of three-stranded spiral wire (Triflex or Wildcat) and 5.9 per cent with the five-stranded spiral wire (Penta-One). In their investigation, as in most previous studies (Zachrisson, 1982; Dahl and Zachrisson, 1991; Årtun *et al.*, 1997), the retainer wires were bonded with a chemically polymerized resin composite (Concise).

The failure rates recorded in the present investigation are less favourable than those published previously by Dahl

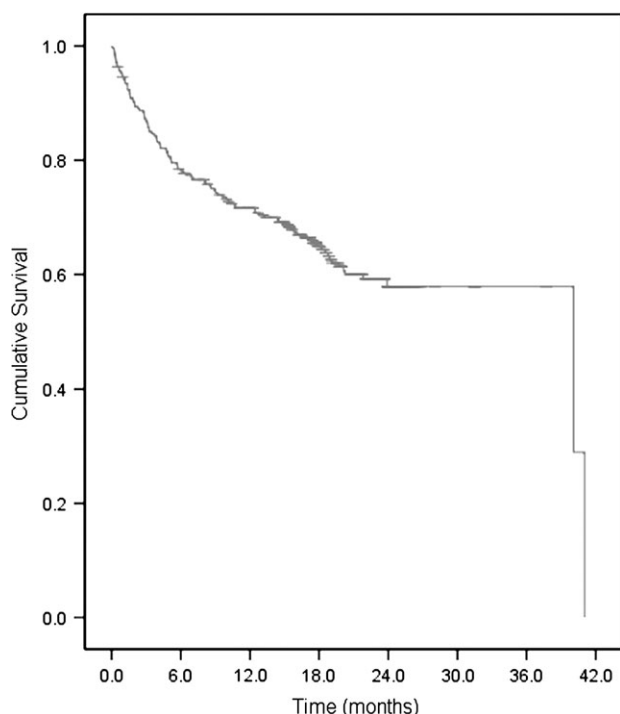


Figure 2 Kaplan-Meier survival curve showing a 63 per cent success rate for the bonded lingual retainers over a 41.7 month period.

and Zachrisson (1991) and Årtun *et al.* (1997). In both of those studies, all the retainers were bonded in private practice by one or two experienced operators, while in the present study the retainers were bonded by 15 different operators, with a great difference in experience. Similar to the study of Segner and Heinrici (2000) where the retainers were bonded by 28 different operators, in the present study bonding was undertaken by multiple operators. This may account for the difference in failure rates.

The position in the present study of the wire on the lingual surfaces of the teeth, being either more cervical or more incisal, is unknown. According to Andrén *et al.* (2001), a more incisal positioning of the retainer results in less flexibility.

Some studies (Dahl and Zachrisson, 1991; Bearn, 1995; Andrén *et al.*, 1998; Segner and Heinrici, 2000) reported higher failure rates for the maxilla compared with the mandible but this could not be verified in this investigation due to missing data for the maxilla. The fracture rate in the present study was found to be 0.2 per cent, but the true fracture rate might be slightly higher than the figures calculated due to the incomplete data.

A noticeable finding of the present investigation was that the failures occurred mostly in the first 6 months after the retainers were bonded. One explanation for this could be insufficient composite bond strength to enamel that is often technique sensitive. Factors such as a lack of moisture control or minute movements of the retainer wire during the setting process of the adhesive could impair ideal adhesion. *In vitro* and *in vivo* studies (Ibe and Segner, 1995; Hajrassie and

Khier, 2007) have also concluded that a certain percentage of bonding sites may be unsatisfactory, although the mean bond strength may be initially sufficient. The *in vitro* findings could be expected to apply even more strongly for *in vivo* placements due to a less favourable working environment. Such sites with insufficient bond strength will manifest themselves in the first week or months after bonding.

Other explanations for the early failures could be based on biological reasons. Tuverson (1980) suggested that rotational relapse may be due to small contact points at the axial part of the bonded teeth which seem to be unstable. Surbeck *et al.* (1998) commented that the presence of more crowded and irregular dentitions prior to treatment may not necessarily be a sole indicator of greater risk for relapse after treatment. In addition, factors such as orthodontic expansion, incomplete tooth alignment, and interdental spacing might be responsible for post-treatment relapse leading to failure of bonded retainers. Unfortunately, in retrospective studies, such aspects cannot always be identified.

Huang and Årtun (2001) found an association between a narrow intercanine width and relapse of the maxillary and mandibular incisors. Fudalej and Årtun (2007) concluded that neither forward nor backward rotational growth patterns, at the time of appliance removal, are associated with increased risk of post-retention relapse. Particularly, in adolescent orthodontic patients, the type of post-treatment growth is difficult to predict. The sample in the present study consisted mostly of adolescent patients which could perhaps explain the high rate of failure. On the other hand, Yoshida *et al.* (1999) suggested that rapid remodelling of the periodontal ligament and the surrounding alveolar bones could be the main cause of tooth relapse. While different factors play a role in post-treatment relapse, it is most likely that the forces exceed the adhesive strength of the bonded retainers causing them to fail.

Successful clinical outcomes are often reported by experienced orthodontists (Dahl and Zachrisson, 1991; Årtun *et al.*, 1997) especially in private practice settings. The experience of the operator is expected to be the most likely key factor influencing the failure rates. Higher failure rates could be expected when less experienced operators are involved. Interestingly, however, in the present study, neither different operators nor experience played a significant role in failure rate. Due to the considerable design differences of the retainers placed by different operators, a high failure rate ranging from 28.9 to 46.7 per cent between practitioners was observed. However, in clinical trials, particularly in dentistry, experience may not be always quantified in years of practice. Also in this study, the number of retainers bonded by the experienced operators decreased with the increase in delegation. It is also difficult to distinguish the transition between the least experienced and the experienced. Nevertheless, the findings of this research represent a more real-life clinical situation.

The results did not show significant differences in failure rates between genders and age, in agreement with the findings

of Lumsden *et al.* (1999) where the mean age of the subjects was 15.5 years. The results related to age were, however, lower than those reported by Dahl and Zachrisson (1991) where the mean age of the patient population was 31.2 years. It should, however, be noted that their sample size was only 17 for the mandible, whereas for the present study the total sample was 277. A direct comparison is therefore not possible since the reason for failures could be related to the relapse response in the adults or simply to the low power of the study.

Although previous investigations (Dahl and Zachrisson, 1991; Årtun *et al.*, 1997; Störmann and Ehmer, 2002) have shown a difference in failure rate when different types of retainers are used, no randomized controlled clinical trials have been performed to date. Future investigations should concentrate on this aspect. In the current study, moisture control was achieved using only saliva ejectors and cotton rolls. However, the survival rate of resin-bonded restorations has been reported to be higher when bonding procedures are performed under rubber dam isolation (Audenino *et al.*, 2006). Prospective studies should also perhaps concentrate on other confounding factors such as effective moisture control, light intensity of the polymerization device (Davidson and de Gee, 2000), and the composite and adhesive resin used.

Conclusions

The following conclusions can be drawn from this study:

1. The success rate of the flexible, braided, bonded lingual retainers was 63 per cent over 41.7 months.
2. The survival rate for the mandible was 68.4 per cent.
3. Most failures occurred during the first 6 months.
4. Gender and age of the patient and operator experience did not affect the failure rate.

Address for correspondence

Dave J. Lie Sam Foek
Department of Orthodontics
University Medical Center Groningen
Hanzeplein 1
Postbus 30001
Groningen 9700 RB
The Netherlands
E-mail: d.j.liesamfoek@dmo.umcg.nl

Acknowledgement

The authors would like to extend their gratitude to Dr M. W. J. Bierman for helpful discussions.

References

Andrén A, Asplund J, Azarmidohkt E, Svensson R, Varde P, Mohlin B
1998 A clinical evaluation of long term retention with bonded

retainers made from multi-strand wires. *Swedish Dental Journal* 22: 123–131

Årtun J, Thylstrup A 1986 Clinical and scanning electron microscopic study of surface changes of incipient caries lesions after debonding. *Scandinavian Journal of Dental Research* 94: 193–201

Årtun J, Urbye K S 1988 The effect of orthodontic treatment on periodontal bone support in patients with advanced loss of marginal periodontium. *American Journal of Orthodontics and Dentofacial Orthopedics* 93: 143–148

Årtun J, Spadafora A T, Shapiro P A 1997 A 3-year follow-up study of various types of orthodontic canine-to-canine retainers. *European Journal of Orthodontics* 19: 501–509

Audenino G, Giannella G, Morello G M, Ceccarelli M, Carossa S, Bassi F
2006 Resin-bonded fixed partial dentures: ten-year follow-up. *International Journal of Prosthodontics* 19: 22–23

Bearn D R 1995 Bonded orthodontic retainers: a review. *American Journal of Orthodontics and Dentofacial Orthopedics* 108: 207–213

Birnie D 2007 *Stability and retention. Excellence in Orthodontics*, London, pp. 411–432.

Dahl E H, Zachrisson B U 1991 Long term experience with direct bonded lingual retainers. *Journal of Clinical Orthodontics* 25: 619–630

Davidson C L, de Gee A J 2000 Light-curing units, polymerization, and clinical implications. *Journal of Adhesive Dentistry* 2: 167–173

Fudalej P, Årtun J 2007 Mandibular growth rotation effects on postretention stability of mandibular incisor alignment. *Angle Orthodontist* 77: 199–205

Hajrassie M, Khier S 2007 *In-vivo* and *in-vitro* comparison of bond strengths of orthodontic brackets bonded to enamel and debonded at various times. *American Journal of Orthodontics and Dentofacial Orthopedics* 131: 384–390

Huang L, Årtun J 2001 Is the postretention relapse of maxillary and mandibular incisor alignment related? *American Journal of Orthodontics and Dentofacial Orthopedics* 120: 9–19

Ibe D, Segner D 1995 Improvement in the adhesive strength of orthodontic brackets on unit-cast and fired dental alloys by microsandblasting. *Journal of Orofacial Orthopedics* 56: 110–117

Keim R G, Gottlieb E I, Nelson A H, Vogels 3rd D S 2002 JCO study of orthodontic diagnosis and treatment procedures. 1. Results and trends. *Journal of Clinical Orthodontics* 36: 553–568

Littlewood S J, Millett D T, Doubleday B, Bearn D R, Worthington H V
2004 Retention procedures for stabilising tooth position after treatment with orthodontic braces. *Cochrane Database of Systematic Reviews* 1: CD002283

Littlewood S J, Millett D T, Doubleday B, Bearn D R, Worthington H V
2006 Retention procedures for stabilising tooth position after treatment with orthodontic braces. *Cochrane Database of Systematic Reviews* 1: CD002283

Lumsden K W, Saidler G, McColl J H 1999 Breakage incidence with direct bonded lingual retainers. *British Journal of Orthodontics* 26: 191–194

Segner D, Heinrici B 2000 Bonded retainers-clinical reliability. *Journal of Orofacial Orthopedics* 61: 352–358

Southard K A, Southard T E 1990 Conservative management of anterior spacing and deep bite: a case report. *Quintessence International* 21: 801–811

Störmann I, Ehmer U 2002 A prospective randomized study of different retainer types. *Journal of Orofacial Orthopedics* 63: 42–50

Surbeck B T, Årtun J, Hawkins N R, Leroux B 1998 Associations between initial, posttreatment, and postretention alignment of maxillary anterior teeth. *American Journal of Orthodontics and Dentofacial Orthopedics* 113: 186–195

Tuverson D L 1980 Anterior interocclusal relations. Part II. *American Journal of Orthodontics* 78: 361–393

Yoshida Y, Sasaki T, Yokova K, Hiraide T, Shibasaki Y 1999 Cellular roles in relapse processes of experimentally—moved rat molars. *Journal of Electron Microscopy* 48: 147–157

- Zachrisson B U 1978 Improving orthodontic results in cases with maxillary incisors missing. *American Journal of Orthodontics* 73: 274–289
- Zachrisson B U 1982 The bonded lingual retainer and multiple spacing of anterior teeth. *Swedish Dental Journal* 15: 247–255
- Zachrisson B U 1986 Bonding in orthodontics. In: Graber L W (ed). *Orthodontics: current principles and techniques*. Mosby, St Louis, pp. 526–561.
- Zachrisson B U 1995 Third-generation mandibular bonded lingual 3-3 retainer. *Journal of Clinical Orthodontics* 29: 39–48
- Zachrisson B U 1996 Clinical implications of recent orthodontic-periodontic research findings. *Seminars in Orthodontics* 2: 4–12
- Zachrisson B U, Büyükyılmaz T 2005 Bonding in orthodontics. In: Graber L W (ed). *Orthodontics: current principles and techniques*, 4th edn. Mosby, St Louis, pp. 621–659

Copyright of European Journal of Orthodontics is the property of Oxford University Press / UK and its content may not be copied or emailed to multiple sites or posted to a listserv without the copyright holder's express written permission. However, users may print, download, or email articles for individual use.