

In vitro evaluation of a method for obtaining periapical radiographs for diagnosis of external apical root resorption

Aderson Gegler and Vania Fontanella

Dental Radiology, Federal University of Rio Grande do Sul, Porto Alegre, Brazil

SUMMARY This *in vitro* study was conducted to evaluate a method to obtain reproducible periapical radiographs, using individualized positioning devices, of upper central incisors submitted to simulated orthodontic movement. Linear measurements of tooth length were carried out on 29 extracted human central incisors. The teeth were radiographed in a tissue simulator, at different inclinations in the bucco-lingual direction (0 initial, 0 control, –10, –5, +5, and +10 degrees). The radiographs were digitized and quantitative analysis of tooth length was carried out using an electronic ruler.

The linear measurements of tooth length were reproducible ($r = 0.99$) for repeated measurements as well as in the comparison of the initial and control images at 0 degree, where measurements did not differ significantly (analysis of variance, $P = 0.827$) in radiographs with different angulations. These results show that the method proposed for obtaining *in vitro* periapical radiographs results in reproducible images of tooth length, even when orthodontic movement is simulated by inclination of the tooth up to 20 degrees in the bucco-lingual direction.

Introduction

External root resorption (ERR) has been related to orthodontic tooth movement (Tronstad and Debelian, 1998). The anterior teeth, especially the central incisors, are reported as those most often subject to trauma (Parker and Harris, 1998). Early detection of incipient ERR is mandatory for identifying teeth at risk of severe resorption (Levander and Malmgren, 1988). However, radiographs are not sufficiently sensitive for consistent diagnosis of ERR, as demonstrated by Laux *et al.* (2000), who compared the diagnosis of inflammatory apical ERR in radiographs versus histological sections of 104 teeth that showed apical lesions and found agreement for only 7 per cent.

The periapical technique is the method of choice for the longitudinal determination of ERR (Leach *et al.*, 2001). However, geometric variations related to vertical angulation can cause shortening or lengthening of the image, and thus interfere with diagnosis. Several studies have addressed radiographic geometry standardization accomplished through positioning devices (Dixon and Hildebold, 2005). Some of these devices use bite registration which are left uncoupled or are coupled to the tube head (Rosling *et al.*, 1975; Graf *et al.*, 1988; Rudolph and White, 1988; Zappa *et al.*, 1991). The rigidly coupled instruments have demonstrated good results (Hausmann *et al.*, 1996) but they are expensive, difficult to use, and time intensive.

The utilization of an individualized positioning device by means of occlusal registration of the teeth in the region of interest has been shown to be sufficient for geometric standardization (Crestani *et al.*, 2001; Souza, 2001; Maltz *et al.*, 2002). One of the problems in the standardization of images in orthodontic patients for the diagnosis of apical

ERR is tooth movement, which varies from one tooth to another. Therefore, it is necessary to test the geometric reproducibility of periapical radiographs obtained with individual positioners for the tooth being examined, which would not be influenced by modifications in the position of adjacent teeth. Thus, the aim of this study was to evaluate, by means of linear measurements of tooth length on images, a method aimed at geometric reproducibility of periapical radiographs of upper incisors submitted to simulated orthodontic movement.

Materials and methods

This study was approved by the Committee on Ethics in Research of the Faculty of Dentistry at Universidade Federal do Rio Grande do Sul.

The sample comprised 29 human upper central incisors which showed a visually intact apex, preserved crown, and no anomalies in shape or size. Brackets (Morelli, Sorocaba, Brazil) were placed, using glass ionomer cement (Fuji Ortho LC®, GC Corporation, Tokyo, Japan), on the buccal surface of the teeth, to simulate the clinical conditions.

Tissue block simulator

The experiment was carried out using a tissue block simulator fabricated from a maxilla from which the anterior portion was removed by horizontal osteotomy at the level of the floor of the nasal cavity and two vertical osteotomies at the canine abutment. This segment was divided into buccal and lingual halves which were then repositioned in a base of self-polymerizing acrylic resin. The space created between

the bony plates was filled with wax in order to allow the insertion of the tooth roots, up to where the amelodentinal junction coincided with height of the alveolar ridge, as well as later simulation of orthodontic movement.

Soft tissues were simulated by adding a 1 cm layer of self-polymerizing acrylic resin, buccal and lingual, external to the bony surfaces.

Occlusal registration

To reproduce the focus-object-film relationship for all periapical radiographs of the same tooth, occlusal registration



Figure 1 Radiographic technique without inclination of the tooth, in the bucco-lingual direction (0 degree).

was carried out in self-polymerizing acrylic resin which was individualized for each tooth and covered the lingual side up to the most prominent portion and the buccal side up to the incisal edge of the bracket. Each occlusal registration was fixed by means of self-polymerizing acrylic resin to the surface of a positioning device (Indusbello, Londrina, Brazil).

Radiographic projection

The radiographs were taken with Kodak Insight® No. 2 periapical film (Kodak, São Paulo, Brazil) and radiographic apparatus, Pro 70X Intra® with 70 kVp and 8 mA (Prodental Equipamentos Odontológicos Ltda, Ribeirão Preto, Brazil), such that the same angulations were reproduced utilizing an exposure time of 0.4 seconds.

Six exposures were performed for each tooth, the first with the long axis of the tooth at 90 degrees to the horizontal plane; this was considered as the initial 0 degree. The initial radiographs were repeated using the same 0 degree incidence for each tooth (Figure 1) in order to create a control group and to allow evaluation of the method error. Orthodontic movement was simulated by inclining the long axis of the tooth at -10 , -5 , $+5$, and $+10$ degrees in relation to the vertical plane, measured by means of the goniometer of the radiographic apparatus when the tube head was repositioned, such that the geometric relationship between the angle of incidence of the X-rays, tooth, and film was maintained (Figure 2).




Figure 2 Radiographic technique with inclination of the tooth, in the bucco-lingual direction, at -10 , -5 , $+5$, and $+10$ degrees.

The radiographs were processed using an automatic method (DentX 9000®, DentX, Elmsford, New York, USA), all in the same session, using new solutions and a cycle of 4.5 minutes.

Radiographic digitization

Digitization of the radiographs was carried out using an Epson Perfection 2450® scanner (Epson, Long Beach, California, USA) with a transparency adaptor. A black acrylic mask, standardizing the positioning of the film on the surface of the scanner, was used to limit the area of light incidence. The images were captured in their original size, with 300 dpi, 8 bit mode, providing 256 grey levels and stored on CD-ROM in Joint Photographic Experts Group format with 3:1 compression ratio. All radiographs were captured simultaneously, automatic adjustment of brightness and contrast was only undertaken for the initial radiograph.

Tooth measurement

Analysis of the images was performed by one observer (VF) who measured the tooth length for each of the images, at three different sessions, each with a 1 week interval. The measurements were carried out using the electronic ruler tool incorporated into the software, Adobe Photoshop® (version 10.0, Adobe Inc., San Jose, California, USA; Figure 3). Horizontal guides were drawn, one at the root apex and the other at the most apical part of the cervical limit of the bracket. The measurements were carried out by drawing a line perpendicular to the guides, to obtain the distance between them. The observer was allowed to adjust the brightness and contrast of each of the images, to obtain improved definition of anatomical reference structures and consequently greater precision in measurement. However, the examiner was blind to which groups the images belonged or whether or not there was a change in inclination.

Method error

Reproducibility of the measurements was evaluated by remeasuring 20 per cent of the sample, chosen at random, after a 1 week interval. The Pearson's correlation coefficient ($\alpha = 1$ per cent) and the *t*-test for the paired samples ($\alpha = 5$ per cent) demonstrated excellent agreement ($r = 0.999$) with no significant difference between them ($P = 0.662$). The mean values obtained were 17.58 ± 1.57 mm both for the initial and repeat measurements.

Since there was no difference in inclination with the initial incidence of 0 degree versus the repetitions for the control also at 0 degree, these images should not differ in length. Therefore, validation was determined by comparing the measurements of the initial and control radiographs, without modification of the inclination. The Pearson's correlation coefficient ($\alpha = 1$ per cent, $r = 0.999$) and the *t*-test for paired samples ($\alpha = 5$ per cent, $P = 0.284$) showed

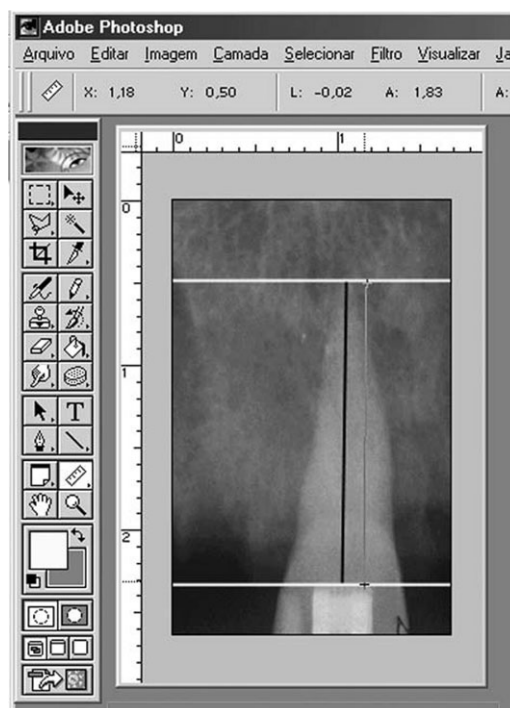


Figure 3 Measurement of root length using an electronic ruler.

no significant difference, suggesting internal validity in the study. The mean values for both the initial radiographs and those of the control group were 18.00 ± 1.90 mm.

Statistical analyses

Since these analyses involved quantitative data with parametric distribution, groups were compared using the analysis of variance. A randomized complete block design was used to establish any difference between the radiographic measurements obtained for the different inclinations. Significance was set at $P < 0.05$.

Results

There was no significant difference between the means of the radiographic measurements for any experimental group ($P = 0.827$), i.e. there was no difference between the measurements obtained with different inclinations (0, -5, +5, -10, and +10 degrees). The mean values and standard deviations are presented in Table 1.

Discussion

The present research was carried out *in vitro*, as in other studies that investigated ERR (Hintze *et al.*, 1992; Goldberg *et al.*, 1998; Nance *et al.*, 2000; Heo *et al.*, 2001; Holmes *et al.*, 2001), since a method for standardization of radiographic images should, for ethical reasons, be tested prior to clinical use. On the other hand, in an *in vivo* study it would not be

Table 1 Mean observed values for the measurement of each inclination group, submitted to analysis of variance.

Position (°)	Measurement (mm)	
	Mean	Standard deviation
-10	18.18	1.97
-5	18.19	1.98
0	18.18	1.96
+5	18.18	1.97
+10	18.20	1.98

possible to ensure that the teeth would not suffer some type of resorption. The sample consisted of upper central incisors because they are most affected by apical ERR associated with orthodontic treatment (Parker and Harris, 1998).

Only vertical inclination was varied, in contrast to the research by Goldberg *et al.*, (1998), Levander *et al.*, (1998), Heo *et al.*, (2001), and Holmes *et al.*, (2001), in which horizontal angulation was also varied, as only the geometric variation related to changes in the vertical plane leads to shortening or lengthening of the image (Leach *et al.*, 2001).

Individual occlusal registration of the positioner appliance, contrary to the method employed by Holmes *et al.* (2001), who utilized moulding material, was obtained in self-polymerizing acrylic resin, which has been shown to be sufficient for geometric standardization (Crestani *et al.*, 2001; Souza, 2001), even for prolonged periods (Maltz *et al.*, 2002).

The present study did not utilize jaws from cadavers (Holmes *et al.*, 2001) or dry jaws (Hintze *et al.*, 1992; Levander *et al.*, 1998; Nance *et al.*, 2000), as this would have limited the sample size. The use of teeth mounted in blocks of plaster (Heo *et al.*, 2001) was not considered because the absence of a bony trabeculae constitutes an important differential in relation to clinical situations, facilitating the diagnosis of apical ERR. A simulation of bony tissue of the maxilla was utilized, as in Goldberg *et al.* (1998), even though maintenance of the constant pattern of bony trabeculae can imply less variability in the sample compared with that found in cadavers and clinically.

Simulation of soft tissues was employed in the present study using 2 cm thick acrylic resin, which reproduces the effect of the tissues on the radiographic image when associated with dissected and dried bone (Braga *et al.*, 2002).

Levander *et al.* (1998) measured 92 upper incisors radiographed for diagnosis of apical ERR in patients. Apical ERR was considered based on the difference between measurements of the initial radiographs with those obtained following 3 and 6 months of treatment. It is important to note that these authors tested the accuracy of this model utilizing an extracted premolar, set in a block of acrylic, and by performing four successive apical drillings of 0.2 mm,

obtaining one radiograph after each. Besides the initial radiography, the horizontal angulation was varied at 30, 60, and 90 degrees, thus obtaining 20 radiographs, from which measurements were taken. The gold standard utilized was the measurement of the tooth at each drilling using a pachymeter, taking the mean of three repetitions. As in the present study, Levander *et al.* (1998) also repeated the measurement, but for all the sample (20 radiographs) and with a 1 month interval, finding a mean difference of 0.1 ± 0.05 mm between the actual size of the tooth and that determined from measurements of the images.

The results of the present research showed a high reproducibility for the initial and repeated measurements. The reason for the greater variation compared with that of Levander *et al.* (1998) is probably due to the fact that the authors utilized only one tooth, whereas in the present study 29 were used. Image measurements were used to compare the size of the teeth and not to analyse the relationship with the actual length of the tooth, since the periapical bisecting angle technique was used, which results in distortions between the image and the real size of the object.

It was observed that the means of the measurements obtained for each change in inclination did not differ significantly, i.e. the X-ray beam angle-object-film relationship was maintained. The small mean difference (0.02 mm) can be related to slight variation in projection or apex identification on the image, which would not be clinically relevant.

No reports were found in the scientific literature of investigations that examined the reproducibility of linear dimensions, utilizing modifications of tooth inclination but maintaining the film-object distance constant between radiographs. Studies were found that compared diagnosis between images with different inclinations, but only for the determination of geometric correlation (Gröndahl *et al.*, 1984; Hausmann *et al.*, 1991; Wenzel and Sewerin, 1991; Mol and Dunn, 2003), all of which showed positive results. This method was not used in the present study as the objective was only to observe the geometric reproducibility of the images taken with an individual positioner in cases of simulated tooth movement.

The results showed no difference in measurements among the groups with different inclinations (5, 10, 15, and 20 degrees). This is due to the fact that despite the different inclinations used when taking the radiographs, the geometric relationship was maintained by the individualized positioning device. Therefore, even though a particular tooth underwent orthodontic movement, the positioner with individualized occlusal registration should maintain this relationship, thereby providing geometric reproducibility between resulting images.

Conclusion

The method proposed to obtain periapical radiographs of upper central incisors resulted in reproducible images of

tooth length, even when orthodontic movement was simulated, i.e. inclining the tooth up to 20 degrees in the bucco-lingual direction.

Address for correspondence

Vania Fontanella
Rua Cel. Paulino Teixeira 169/403
90420-160 Porto Alegre, RS
Brazil
E-mail: vaniafontanella@terra.com.br

References

- Braga C P A, Machado L X, Gegler A, Mahl C E W, Fontanella V 2002 Materiais simuladores de tecidos moles na região posterior da mandíbula: avaliação por subtração radiográfica digital. In: Anais do Salão de Iniciação Científica UFRGS 14, p. 541
- Crestani M B, Silva A E, Larentis N L, Fontanella V 2001 Avaliação da padronização radiográfica para a subtração digital de imagens. Revista da Faculdade de Odontologia, Porto Alegre 42: 25–30
- Dixon D, Hildebold C F 2005 An overview of radiographic film holders. Dentomaxillofacial Radiology 34: 67–73
- Goldberg F, De Silvio A, Dreyer C 1998 Radiographic assessment of simulated external root resorption cavities in maxillary incisors. Endodontics and Dental Traumatology 14: 133–136
- Graf J M, Mounir A, Payot P, Cimasani G 1988 A simple paralleling instrument for superimposing radiographs of the molar regions. Oral Surgery, Oral Medicine, and Oral Pathology 66: 502–506
- Gröndahl K, Gröndahl H G, Webber R L 1984 Influence of variations in projection geometry on the detectability of periodontal bone lesions. A comparison between subtraction radiography and conventional radiographic techniques. Journal of Clinical Periodontology 11: 411–420
- Hausmann E, Allen K M, Piedmonte M R 1991 Influence of variations in projection geometry and lesion size on detection of computer-simulated crestal alveolar bone lesions by subtraction radiography. Journal of Periodontal Research 26: 48–51
- Hausmann E, Allen K, Loza J, Buchanan W, Cavanaugh Jr P F 1996 Validation of quantitative digital subtraction radiography using the electronically guided alignment device/impression technique. Journal of Periodontology 67: 895–899
- Heo M S, Lee S S, Lee K H, Choi H M, Choi S C, Park T W 2001 Quantitative analysis of apical root resorption by means of digital subtraction radiography. Oral Surgery, Oral Medicine, Oral Pathology, Oral Radiology, and Endodontics 91: 369–373
- Hintze H, Wenzel A, Andreasen F M, Sewerin I 1992 Digital subtraction radiography for assessment of simulated root resorption cavities. Performance of conventional and reverse contrast modes. Endodontics and Dental Traumatology 8: 149–154
- Holmes J P, Gulabivala K, van der Stelt P F 2001 Detection of simulated internal tooth resorption using conventional radiography and subtraction imaging. Dentomaxillofacial Radiology 30: 249–254
- Laux M, Abbott P V, Pajarola G, Nair P N 2000 Apical inflammatory root resorption: a correlative radiographic and histological assessment. International Endodontic Journal 33: 483–493
- Leach H A, Ireland A J, Whaites E J 2001 Radiographic diagnosis of root resorption in relation to orthodontics. British Dental Journal 190: 16–22
- Levander E, Malmgren O 1988 Evaluation of the risk of root resorption during orthodontic treatment: a study of upper incisors. European Journal of Orthodontics 10: 30–38
- Levander E, Bajka R, Malmgren O 1998 Early radiographic diagnosis of apical root resorption during orthodontic treatment: a study of maxillary incisors. European Journal of Orthodontics 20: 57–63
- Maltz M, de Oliveira E F, Fontanella V, Bianchi R 2002 A clinical, microbiologic, and radiographic study of deep caries lesions after incomplete caries removal. Quintessence International 33: 151–159
- Mol A, Dunn S M 2003 Effect of bone chip orientation on quantitative estimates of changes in bone mass using digital subtraction radiography. Journal of Periodontal Research 38: 296–302
- Nance R S, Tyndall D, Levin L G, Trope M 2000 Diagnosis of external root resorption using TACT (tuned-aperture computed tomography). Endodontics and Dental Traumatology 16: 24–28
- Parker R J, Harris E F 1998 Directions of orthodontic tooth movements associated with external apical root resorption of the maxillary central incisor. American Journal of Orthodontics and Dentofacial Orthopedics 114: 677–683
- Rosling B, Hollender L, Nymann S, Olsson G 1975 A radiographic method for assessing changes in alveolar bone height following periodontal therapy. Journal of Clinical Periodontology 2: 211–217
- Rudolph D J, White S C 1988 Film-holding instruments for intraoral subtraction radiography. Oral Surgery, Oral Medicine, and Oral Pathology 65: 767–772
- Souza D M 2001 Avaliação *in vitro* de Lesões de furcas mandibulares por uma técnica de subtração radiográfica. Thesis, Universidade Federal do Rio Grande do Sul, Porto Alegre
- Tronstad L, Debelian G J 1998 Reabsorções radiculares: etiologia, manifestações clínicas e terapia. In: Melo L L (ed.). Traumatismo alvéolo-dentário: etiologia, diagnóstico e tratamento. São Paulo: Artes Médicas, pp. 127–157.
- Wenzel A, Sewerin I 1991 Sources of noise in digital subtraction radiography. Oral Surgery, Oral Medicine, Oral Pathology, Oral Radiology, and Endodontics 71: 503–508
- Zappa U, Simona C, Graf H, Van Akin J 1991 *In vivo* determination of radiographic projection errors produced by a novel filmholder and an X-ray beam manipulator. Journal of Periodontology 62: 674–683

Copyright of European Journal of Orthodontics is the property of Oxford University Press / UK and its content may not be copied or emailed to multiple sites or posted to a listserv without the copyright holder's express written permission. However, users may print, download, or email articles for individual use.