

Non-syndromic concomitant hypodontia and supernumerary teeth in an orthodontic population

Margarita Varela, Patricia Arrieta and Cesar Ventureira

Unidad de Ortodoncia, Fundación Jiménez Díaz, Madrid, Spain

SUMMARY The simultaneous occurrence of hypodontia and supernumerary teeth in the same individual is termed 'concomitant hypo-hyperodontia' (CHH). There appears to be a correlation between CHH and some syndromes, but this anomaly is very rare in the general population. The aim of this study was to investigate the frequency of CHH in a large sample of non-syndromic orthodontic patients. The records of 2108 consecutive non-syndromic orthodontic patients aged from 7 to 16 years were examined retrospectively. Every patient had at least one panoramic radiograph. When the diagnosis of hypodontia and/or hyperodontia was made in a child under 10 years of age, a second panoramic film was taken 2–4 years later. Statistical analysis of the data was undertaken using a chi-square test.

Single or multiple hypodontia was diagnosed in 137 patients (6.5 per cent), 62 males and 75 females. One or more supernumerary teeth were found in 42 patients (2 per cent), 22 males and 20 females. CHH was diagnosed in seven subjects (0.33 per cent), four males and three females. In the CHH subpopulation, the total number of absent and supernumerary teeth was nine and eight, respectively. Hypodontia always occurred in the permanent dentition and was more frequent in the mandible than in the maxilla (four versus three teeth). Supernumerary teeth were more frequent in the permanent than in the primary dentition (six versus two teeth). Five supernumeraries were located in the maxilla and three in the mandible.

Introduction

Reports of the prevalence of hypodontia in the literature vary widely, ranging from 0.5 to 2.4 per cent for the primary and from 2.6 to 11.3 per cent for the permanent dentition (Polder *et al.*, 2004; Larmour *et al.*, 2005). These data exclude agenesis of one or more third molars, with a prevalence of 11.5 per cent (Sandhu and Kaur, 2005). The reported hypodontia gender ratio is approximately 2:3 (male:female, Polder *et al.*, 2004). In the Caucasian population, the most frequently absent teeth are the mandibular second premolars, followed by the maxillary lateral incisors (Polder *et al.*, 2004), but in some Asian populations, agenesis of the mandibular lateral incisors is more prevalent (Davis, 1987; Endo *et al.*, 2006). Hypodontia can be associated with other dental abnormalities, such as a cleft lip and palate (CLP) as well as with more than 50 syndromes (Ranta, 1988; Larmour *et al.*, 2005). The aetiology of hypodontia is multifactorial. The most supported theory suggests a polygenic mode of inheritance, with epistatic genes and environmental factors exerting some influence on the phenotypic expression of the genes involved (Thesleff, 2000).

Supernumerary teeth, also called hyperodontia, may occur in both dentitions, unilaterally or bilaterally, and in one or both jaws (Rajab and Hamdan, 2002; Fernández Montenegro *et al.*, 2006). A mesiodens is the most frequent type of supernumerary tooth (Kim and Lee, 2003; Russell and Folwarzna, 2003). Multiple supernumerary teeth are rare in individuals with no other associated diseases or

syndromes (Yusof, 1990). The reported prevalence of supernumerary teeth in the permanent dentition in the Caucasian population ranges from 0.1 to 3.8 per cent (Burzynski and Escobar, 1983) and from 0.3 to 0.8 per cent in the primary dentition (Ravn, 1971; Taylor, 1972). The wide range reported for the permanent dentition can be explained by differences in detection methods, population type, and age of the evaluated subjects. In the permanent dentition, supernumerary teeth are more frequent in males than in females, with a 2:1 ratio (M:F) in Caucasian populations (Rajab and Hamdan, 2002). In some Asian surveys, the predominance of male patients is 6.5:1 (Davis, 1987), but this sexual dimorphism is not observed in the primary dentition (Kinirons, 1982).

The crowns of supernumerary teeth may show either a normal appearance or different atypical shapes and their roots may be completely or incompletely developed (Garvey *et al.*, 1999). Approximately, two-thirds of primary and one-quarter of permanent supernumerary teeth erupt normally. The rest remain unerupted and may produce complications (Asaumi *et al.*, 2004; Tirologou *et al.*, 2005). Supernumerary teeth, particularly when multiple, can be associated with a CLP and with a small number of systemic syndromes, such as cleidocranial dysostosis and Gardner syndrome (Rajab and Hamdan, 2002). Several theories have been proposed to explain the aetiology of supernumerary teeth. The available data suggest a pattern of multifactorial inheritance that gives rise to hyperactivity of the dental lamina (Rajab and Hamdan, 2002).

Concomitant hypo-hyperodontia

The simultaneous occurrence of both conditions, hypodontia and supernumerary teeth, in the same individual is termed 'concomitant hypo-hyperodontia' (CHH) or oligopliodontia. In the general population, CHH is rare and published studies of its prevalence are scarce. Moreover, most of these studies are reports of single (Camilleri, 1967; Munns, 1967; Brook and Winter, 1970; Mercer, 1970; Nathanail, 1970; Low, 1977; Ferguson, 1984; Zhu *et al.*, 1996; Segura and Jiménez-Rubio, 1998; Matsumoto *et al.*, 2001; Sharma, 2001; Das *et al.*, 2006) or very few (Spyropoulos *et al.*, 1979) cases or surveys which present incomplete information or other methodological shortcomings (Werther and Rothemberg, 1939; Niswander and Sujaku, 1963; Horowitz, 1966). In surveys of the general population or of children attending general dental practices, the frequency of CHH ranges between 8 and 15 per 10 000 (Mercer, 1970; Brook, 1974). Its prevalence seems to be higher in certain Asian populations (40 per 10 000 in a Chinese survey; Davis, 1987). As in the case of both isolated hypodontia and hyperodontia, CHH is found more frequently in the permanent than in the mixed or primary dentitions (Ranta, 1988). There appears to be a correlation between CHH and CLP and with some syndromes such as Down (Kevin *et al.*, 1997; Acerbi *et al.*, 2001) and Ellis van Creveld (Varela and Ramos, 1996; Hattab *et al.*, 1998). These associations can be explained by the higher prevalence of isolated hypodontia and supernumerary teeth in these conditions.

The aetiology of CHH, a combination of two conditions that can be considered as opposite developmental disorders, is unknown. Genetic and environmental causes have been proposed and several attempts have been made to find a possible interpretation of the association of both numerical abnormalities. It may result from disturbances in migration, proliferation, and differentiation of neural crest cells or from interactions between the epithelial and mesenchymal cells during the initiation of odontogenesis (Ranta, 1988).

When hypodontia and hyperodontia are located in the same jaw and quadrant, the association could be considered a transposition (Segura and Jiménez-Rubio, 1998), which is the positional interchange of two adjacent teeth or the development and eruption of a tooth in a position normally occupied by a non-adjacent tooth (Peck and Peck, 1995). However, this theory can explain neither CHH in different quadrants nor many cases of CHH in the same quadrant with atypical morphologies.

The aim of this study was to determine the prevalence of non-syndromic CHH in a large sample of orthodontic patients and to ascertain the distribution frequencies of the teeth involved.

Subjects and method

The subjects were selected from those who attended for consultation at the Orthodontic Unit of Fundación Jiménez

Díaz, Madrid, Spain, during the period from January 1996 to December 2005. All patients aged between 7 and 16 years who had complete records were included in the sample. Those with a CLP or systemic syndromes were excluded. The developmental absence of one or more third molars was not considered a criterion for hypodontia. The population evaluated consisted of 2108 non-syndromic subjects, 903 male and 1205 female, aged from 7 to 16 years. The gender ratio was approximately 5:7. All the subjects were of Caucasian origin.

An intraoral examination had been undertaken in all patients and the radiographic records included at least one panoramic radiograph, which was supplemented when necessary by periapical, occlusal views, and a computed tomograph. The frequency and distribution of hypodontia, supernumerary teeth, and concomitance of these anomalies in an individual were recorded. When hyperodontia and/or hypodontia of a permanent tooth was diagnosed in a patient under 10 years of age, the radiographic examination was repeated after a period of 2–4 years to diagnose any new supernumerary teeth or to exclude the diagnosis of pseudohypodontia due to delayed formation of germs.

Statistical analysis

Statistical analysis of the data was undertaken using a chi-square test.

Results

CHH was found in seven of the 2108 patients (0.33 per cent), four males and three females. The gender ratio was 1.3:1 (M:F). The frequency of CHH was 0.44 per cent for males and 0.25 per cent for females. The differences by gender, although favouring males in both cases, were not statistically significant.

One or more supernumerary teeth were found in 42 individuals (2 per cent of the overall sample), of which 22 (52.4 per cent) were male and 20 (47.6 per cent) female. The gender ratio of the hyperodontia subpopulation was 1.1:1 (M:F). The proportion of patients with supernumerary teeth by gender was 2.43 per cent for males and 1.65 per cent for females. The difference was not statistically significant.

Agensis of one or more teeth, excluding the third molars, was present in 137 individuals (6.5 per cent of the overall sample), 62 males and 75 females. The gender ratio of hypodontia in this subpopulation was 1:1.2 (M:F). The proportion of hypodontia by gender was 6.5 per cent for males and 6.8 per cent for females.

The percentage of patients with hypodontia who presented concomitance of supernumerary teeth was 5.1 per cent (6.45 per cent males and 4.0 per cent females). The corresponding percentage of patients with hyperodontia and concomitance of agensis was 16.7 per cent (18.2 per cent males and 15

per cent females). Therefore, the likelihood of a patient of any gender with agenesis also having supernumerary teeth was approximately 1 in 18. The chance of a subject of any gender with supernumerary teeth also having missing teeth was 1 in 6.

Supernumerary teeth and hypodontia were located in the same dentition (permanent) in six of the seven subjects, in the same jaw in five and in the same quadrant in two. The overall number of supernumerary teeth was eight, three of them in the primary dentition. Two patients had a mesiodens, one of them impacted. The mesiodens of the other patient was completely erupted between the central incisors and was located to the right of the upper fraenulum. Hypodontia in this subject corresponded to the upper lateral incisor of the opposite quadrant (Figure 1A–C). The size and morphology of this supernumerary tooth was similar to that of a lateral or even a central incisor. Therefore, it could have been considered a supplemental supernumerary tooth. However, in view of its central position together with the somewhat irregular morphology of its vestibular surface, it was diagnosed as a mesiodens.

There were nine absent teeth in the CHH sample, all in the permanent dentition. Three of the absent teeth were upper lateral incisors and six lower second premolars.

The findings of the first panoramic radiograph were confirmed in the successive examinations in all subjects: No new germs of normal teeth in patients with hypodontia, or new supernumerary teeth in those with hyperodontia, were found after the initial diagnosis. The abnormalities found in the seven patients are listed in Table 1.

Discussion

The overall orthodontic sample in the present study included a higher proportion of females than males (around 5:7, M:F), which is a relatively common finding in most orthodontic surveys, and may be attributable to the higher value that society gives to aesthetics in females (Wijsbek, 2000). For that reason, in this survey, all the evaluations were carried out separately for both genders.

The prevalence of hypodontia and hyperodontia in this overall sample, of 7.3 and 2.3 per cent, respectively, is in the range of that recorded in other samples that excluded agenesis of third molars and systemic syndromes (Rajab and Hamdan, 2002; Polder *et al.*, 2004). However, the gender differences reported by other authors, where gender ratios of approximately 2:3 (M:F) were found for hypodontia (Larmour *et al.*, 2005) and 2:1 (M/F) for hyperodontia (Rajab and Hamdan, 2002), were not confirmed.

The frequency of CHH in this research was 33 per 10 000 higher than that in most published surveys, which report a range between 8 and 15 per 10 000 (Mercer, 1970; Brook, 1974). This finding is surprising as this sample did not include CLP, syndromic patients, or subjects with isolated third molar agenesis. The inclusion of patients with a CLP

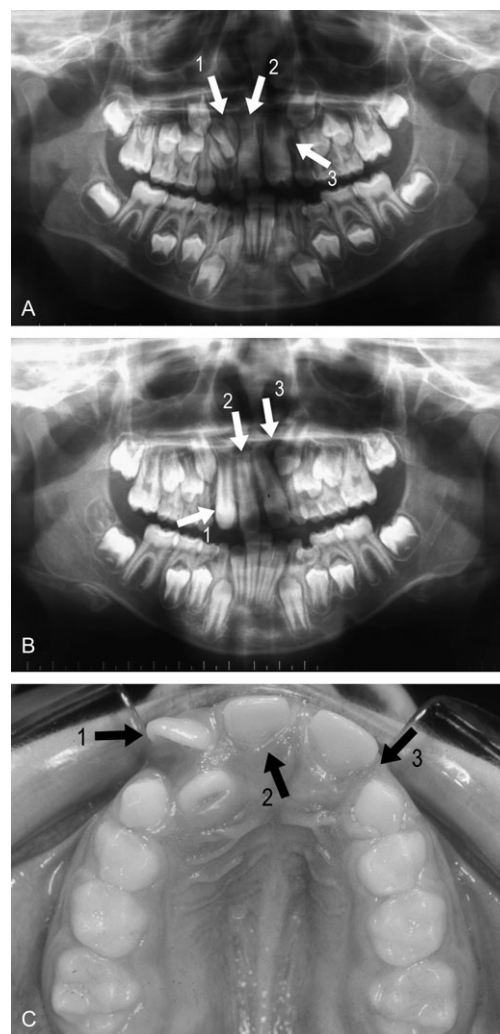


Figure 1 Patient number 5. (A) Panoramic radiograph in the early mixed dentition: agenesis of 22 (arrow 3) and mesiodens (arrow 2). The unerupted 11 (arrow 1) was first diagnosed as a supplemental lateral incisor and the mesiodens as the normal central incisor. (B) The panoramic radiograph obtained 2 years later shows that 11 (arrow 1) and 12 have erupted (the lateral incisor which has erupted palatally is not clearly seen because of superimposition): the supernumerary (arrow 2) is located between the central upper incisors. Anodontia of 22 is confirmed (arrow 3). (C) Occlusal view showing agenesis of 22 (arrow 3). The normal central incisors, 11 (arrow 1) and 21, and 12, have erupted palatally. The supernumerary appears between the central incisors on the right with respect to the fraenulum (arrow 2); The position of the fraenulum excludes a diagnosis of transposition of 21 and 22.

or with syndromes which are usually associated with numerical abnormalities of the teeth, such as Down (Acerbi *et al.*, 2001), may be responsible for the higher than average prevalence of CHH found in some surveys. For example, in a series of 11 patients with CHH (Ranta, 1988), nine had some type of clefting and only two were non-syndromic.

A higher than average CHH prevalence may also be found when the isolated agenesis of one or more third molars is accepted as the criterion for hypodontia even though the definition of hypodontia excludes third molar agenesis (Goodman *et al.*, 1994). For example, in a study of

Table 1 Summary of the numeric variation of the teeth in patients with concomitant hypo-hyperodontia.

Case number	Gender	Supernumerary teeth	Agenesis
1	Female	42	35
2	Male	Unrupted Maxillary Mesiodens*	35, 45
3	Male	12	35
4	Male	32	35, 45
5	Male	Erupted Maxillary Mesiodens	22
6	Female	62	22
7	Female	52, 12	22

*Previously extracted.

CHH in a sample of 4598 orthodontic patients, Gibson (1979) reported a frequency of 41 per 10000. However, included among the 20 patients with CHH were two with systemic syndromes and six with developmental absence of third molars. In the present study, the subjects, with very few exceptions, were aged between 7 and 16 years and third molar status was indeterminate in a large proportion. Therefore, this high prevalence could even be an underestimation. The same can be said for the survey of O'Dowling (1989) of 3056 orthodontic patients, where an even higher CHH prevalence (45 per 10000) was found. That author recognized that this figure could be higher if a more mature sample had been examined.

The consideration of congenital absence of third molars as hypodontia and the inclusion of syndromic patients in some surveys are not the only reasons that explain the discrepancies in the published frequencies. Racial differences and sampling variation, i.e. size, local factors, and preselection of the individuals, can also be responsible for these discrepancies (Gibson, 1979). Particularly, an orthodontic sample can include more patients with hypodontia, supernumerary teeth, or CHH than the general population or general dentistry samples because those numerical anomalies can be associated with irregularities of the anterior teeth that prompt referral to an orthodontist. In the survey by Gibson (1979), the anomaly had been accidentally discovered in half of the 20 patients with CHH, but in the remaining subjects, the irregularity of the anterior teeth secondary to the numerical anomaly had caused referral to the orthodontist. In the present sample, the orthodontic consultation was directly or indirectly related to CHH in four patients. Moreover, the higher than average proportion of CHH in this sample, in spite of the exclusion of cleft palate, syndromic patients, and subjects with isolated congenital absence of a third molar, could be explained by the type of practice from which the sample was obtained, namely a hospital-based orthodontic clinic, where a greater number of patients who require surgical treatment are

referred. The gender ratio of the patients with CHH was 4:3 (M:F), higher than the proportion recorded in other surveys, but the small size of the sample does not allow a specific conclusion to be reached.

Although it is usually possible to confirm anodontia of a permanent tooth, including second molars, in some very young children, a normal germ may often be radiographically visible only many years later (Moorrees *et al.*, 1963). To avoid misdiagnosis of hypodontia due to delayed formation of tooth germs, which might be erroneously considered as developmental absence in young subjects, radiographic examinations were repeated in every patient under 10 years of age who had one or more congenitally missing teeth observed at the first examination. However, no new normal germs appeared at the sites where agenesis had been initially diagnosed. A radiographic examination was also repeated 2 or 4 years after diagnosis of a supernumerary tooth in any patient under 10 years of age to determine if any supernumerary teeth had formed later, but the number remained unchanged.

In this sample, the risk of a subject with hypodontia also having one or more supernumerary teeth was approximately 1 in 18, while for a patient with a supernumerary tooth also having hypodontia was higher, reaching 1 in 6. Although the difference by gender favoured males in both cases, this difference was not statistically significant. These data suggest that the risk of having a CHH when a supernumerary tooth is diagnosed is significant, but this finding has not been reported by other authors. For example, Novak (1974) found five patients with hypodontia in a survey of 161 subjects with a supernumerary tooth; i.e. the frequency of CHH was 3.1 per cent of patients with supernumerary teeth. This corresponds to an approximate risk of only 1 in 30. Due to the morphology of the supernumerary tooth, similar to that of a normal lateral incisor, the CHH of patient number 5 in the present study was initially misdiagnosed as transposition of 22 and 21 (Figure 1A–C). However, this diagnosis was excluded because the supernumerary was located to the right of the midpalatal suture and the absent tooth was the upper left lateral incisor. The interpretation of this rare association as a form of transposition could only be accepted in those cases of CHH where both numerical abnormalities are present in the same dentition and in the same quadrant (Peck and Peck, 1995, Segura and Jiménez-Rubio, 1998). This finding was not present in any of the seven patients in this series.

Conclusion

The results confirm the low prevalence of CHH in this orthodontic non-syndromic population. Given the difficulty of obtaining a sufficient number of panoramic radiographs in the general population, orthodontic diagnostic records serve as a valuable source of information for the evaluation

of disturbances of dental development, although the prevalence may be overestimated in normal populations.

Address for correspondence

Dr Margarita Varela
Unidad de Ortodoncia
Fundación Jiménez Díaz
Avda Reyes Católicos 2
28040 Madrid
Spain
E-mail: memoriavarela@gmail.com

Acknowledgement

The authors are grateful to Dr Björn U. Zachrisson for generously proofreading the manuscript and for his help and valuable suggestions.

References

- Acerbi A G, Freitas C, Cury M H 2001 Prevalence of numeric anomalies in the permanent dentition of patients with Down syndrome. *Special Care in Dentistry* 21: 75–78
- Asaumi J I, *et al.* 2004 Radiographic examination of mesiodens and their associated complications. *Dento Maxillo Facial Radiology* 33: 125–127
- Brook A H 1974 Dental anomalies of number, form and size: their prevalence in British schoolchildren. *Journal of the International Association of Dentistry for Children* 5: 37–53
- Brook A H, Winter G B 1970 Letter to the editor. *British Dental Journal* 129: 309
- Burzynski N J, Escobar V H 1983 Classification and genetics of numeric anomalies of dentition. *Birth Defects Original Article Series* 19: 95–106
- Camilleri G E 1967 Concomitant hypodontia and hyperdontia: a case report. *British Dental Journal* 123: 338–339
- Das G, Sarkar S, Bhattacharya B, Saha N 2006 Coexistent partial anodontia and supernumerary tooth in the mandibular arch: a rare case. *Journal of the Indian Society of Pedodontics and Preventive Dentistry* 24: S33–S34
- Davis P J 1987 Hypodontia and hyperodontia of the permanent teeth in Hong Kong schoolchildren. *Community Dentistry and Oral Epidemiology* 15: 218–220
- Endo T, Ozoe R, Kubota M, Akiyama M, Shimooka S 2006 A survey of hypodontia in Japanese orthodontic patients. *American Journal of Orthodontics and Dentofacial Orthopedics* 129: 29–35
- Ferguson J W 1984 An unusual lateral incisor. *British Journal of Orthodontics* 11: 163–166
- Fernández Montenegro P, Valmaseda Castellón E, Berini Aytes L, Gay Escoda C 2006 Retrospective study of 145 supernumerary teeth. *Medicina Oral Patología, Oral y Cirugía Bucal* 11: 339–344
- Garvey M T, Barry H J, Blake M 1999 Supernumerary teeth an overview of the classification, diagnosis and treatment. *Journal (Canadian Dental Association)* 65: 612–616
- Gibson A C 1979 Concomitant hypo-hyperodontia. *British Journal of Orthodontics* 6: 101–105
- Goodman J R, Jones S P, Hobkirk J A, King P A 1994 Hypodontia: clinical features and the management of mild to moderate hypodontia. *Dental Update* 21: 381–384
- Hattab F N, Yassin O M, Jasa I S 1998 Oral manifestations of Ellis van-Creveld syndrome: report of two siblings with unusual dental anomalies. *The Journal of Clinical Pediatric Dentistry* 2: 159–165
- Horowitz J 1966 Aplasia and malocclusion: a survey and appraisal. *American Journal of Orthodontics* 52: 440–453
- Kevin M C, Chow B D S, O'Donnell D 1997 Concomitant occurrence of hypodontia and supernumerary teeth in a patient with Down syndrome. *Special Care in Dentistry* 17: 54–57
- Kim S G, Lee S H 2003 Mesiodens: a clinical and radiographic study. *Journal of Dentistry for Children* 70: 58–60
- Kinirons M J 1982 Unerupted premaxillary supernumerary teeth: a study of its occurrence in males and females. *British Dental Journal* 153: 110
- Larmour C J, Mossey P A, Thind B S, Stirrups D R 2005 Hypodontia. A retrospective review of prevalence and etiology. Part I. *Quintessence International* 36: 263–270
- Low T 1977 Hypodontia and supernumerary tooth: report of a case and its management. *British Journal of Orthodontics* 4: 187–190
- Matsumoto M, Nakagawa Y, Sobue S, Ooshima T 2001 Simultaneous presence of a congenitally missing premolar and supernumerary incisor in the same jaw: report of case. *ASDC Journal of Dentistry for Children* 68: 63–66
- Mercer A E 1970 Letter to the editor. *British Dental Journal* 129: 402
- Moorrees C F A, Fanning E A, Hunt E E 1963 Age variation of formation stages for ten permanent teeth. *Journal of Dental Research* 42: 1490–1502
- Munns D 1967 A case of partial anodontia and supernumerary teeth present in the same jaw. *Dental Practitioner and Dental Record* 18: 34–37
- Nathanail P 1970 Letter to the editor. *British Dental Journal* 129: 309
- Niswander J D, Sujaku C 1963 Congenital anomalies of teeth in Japanese children. *American Journal of Physical Anthropology* 21: 569–574
- Novak J 1974 Simultaneous occurrence of hypodontia and hyperodontia. *Sbornik Vedeckych Praci Lekarske Fakulty Karlovy Univerzity V Hradci Supplement* 17: 467–471
- O'Dowling I B 1989 Hypo-hyperodontia in an Irish population. *Journal of the Irish Dental Association* 35: 114–117
- Peck S, Peck L 1995 Classification of maxillary tooth transposition. *American Journal of Orthodontics and Dentofacial Orthopedics* 107: 505–517
- Polder B J, Van 't Hof M A, Van der Linden F P, Kuijpers-Jagtman A M 2004 A meta-analysis of the prevalence of dental agenesis of permanent teeth. *Community Dentistry and Oral Epidemiology* 112: 1313–1318
- Rajab L D, Hamdan M A M 2002 Supernumerary teeth: review of the literature and a survey of 152 cases. *International Journal of Paediatric Dentistry* 12: 244–254
- Ranta R 1988 Numeric anomalies of teeth in concomitant hypodontia and hyperdontia. *Journal of Craniofacial Genetics and Developmental Biology* 8: 245–251
- Ravn J J 1971 Aplasia, supernumerary teeth and fused teeth in the primary dentition. An epidemiologic study. *Scandinavian Journal of Dental Research* 79: 1–6
- Russell K A, Folwarczna M A 2003 Mesiodens. Diagnosis and management of a common supernumerary tooth. *Journal (Canadian Dental Association)* 69: 362–366
- Sandhu S, Kaur T 2005 Radiographic evaluation of the status of third molars in the Asian-Indian students. *Journal of Oral and Maxillofacial Surgery* 63: 640–645
- Segura J J, Jiménez-Rubio A 1998 Concomitant hypo-hyperodontia. *Oral Surgery, Oral Medicine, Oral Pathology, Oral Radiology, and Endodontics* 86: 473–475
- Sharma A 2001 A rare non-syndrome case of concomitant multiple supernumerary teeth and partial anodontia. *Journal of Clinical Pediatric Dentistry* 25: 167–169
- Spyropoulos N D, Patsakas A J, Angelopoulos A P 1979 Simultaneous presence of partial anodontia and supernumerary teeth. *Oral Surgery, Oral Medicine, and Oral Pathology* 48: 53–56

- Taylor G S 1972 Characteristics of supernumerary teeth in the primary and permanent dentition. *Dental Practitioner and Dental Record* 22: 203–208
- Thesleff I 2000 Genetic basis of tooth development and dental defects. *Acta Odontologica Scandinavica* 58: 191–194
- Tirologou S, Koch G, Kuroi J 2005 Location, complications and treatment of mesiodentes. A retrospective study in children. *Swedish Dental Journal* 29: 1–9
- Varela M, Ramos C 1996 Chondroectodermal dysplasia (Ellis van Creveld syndrome): a case report. *European Journal of Orthodontics* 18: 313–318
- Werther R, Rothemberg F 1939 Anodontia. *American Journal of Orthodontics* 25: 61–81
- Wijsbek H 2000 The pursuit of beauty: the enforcement of aesthetics or a freely adopted lifestyle. *Journal of Medical Ethics* 26: 454–458
- Yusof W Z 1990 Non syndrome multiple supernumerary teeth: literature review. *Journal of the Dental Canadian Association* 56: 147–149
- Zhu J F, Crevoisier R, Henry R J 1996 Congenitally missing permanent lateral incisors in conjunction with a supernumerary tooth: case report. *Journal of Clinical Pediatric Dentistry* 20: 87–95

Copyright of European Journal of Orthodontics is the property of Oxford University Press / UK and its content may not be copied or emailed to multiple sites or posted to a listserv without the copyright holder's express written permission. However, users may print, download, or email articles for individual use.