

Dentofacial effects of a modified tandem traction bow appliance

Zeynep Atalay and Tuba Tortop

Department of Orthodontics, Faculty of Dentistry, Gazi University, Ankara, Turkey

Correspondence to: Professor Tuba Tortop, Gazi Universitesi, Dis Hekimligi Fakultesi, Ortodonti Anabilim Dalı, 06510 Emek-Ankara, Turkey. E-mail: tubatortop@gazi.edu.tr

SUMMARY The aim of this study was to evaluate the dentofacial effects of a modified tandem traction bow appliance (modified TTBA) in skeletal Class III subjects, and the effect of age on treatment response. The material consisted of the pre-treatment/pre-observation and post-treatment/post-observation lateral cephalograms and hand-wrist films of 45 children with skeletal and dental Class III malocclusions. Thirty patients were treated with a modified TTBA. Two treatment groups of 15 patients each were formed: an early (nine girls, six boys; mean skeletal age: 8.18 ± 0.50 years) and a late treatment (5 girls, 10 boys; mean skeletal age: 11.75 ± 1.00 years) group. The remaining 15 children (5 girls, 10 boys; mean skeletal age: 7.90 ± 0.62 years) were observed without treatment for 8 months and served as a control for the early treatment group. Wilcoxon and Mann–Whitney U-tests were used for statistical analysis.

Significant forward maxillary movement was determined in both treatment groups ($P < 0.01$) while the decrease in SNB was significantly greater in the early treatment group compared with the control ($P < 0.01$). Upper molar tipping and sagittal displacement of point A (point A-T, NLFH-A) was found to be significantly greater in the late treatment group compared with the early treatment group ($P < 0.05$). In both treatment groups, dental and skeletal correction of the Class III malocclusion was achieved.

Introduction

Class III malocclusions are generally accepted as one of the most difficult and complex orthodontic anomalies to diagnose and treat. It has been shown that several combinations of skeletal and dental components within the facial skeleton can produce a Class III malocclusion. It might be due primarily to a retruded maxilla, a protruded mandible, or a combination of the two (Ellis and McNamara, 1984; Guyer *et al.*, 1986; McNamara and Brudon, 1993; Rakosi, 1997).

Facemask therapy is usually preferred for the treatment of subjects with skeletal and dental Class III malocclusions with a retruded maxilla, and it is known that if the patient is sufficiently motivated to wear a facemask, this type of therapy is quite successful (Ngan *et al.*, 1996; Suda *et al.*, 2000; Klempner, 2003). In several facemask studies, it has been reported that a positive overjet was obtained by forward movement of the maxilla, backward and downward rotation of the mandible, proclination of the maxillary incisors and retroclination of the mandibular incisors (Chong *et al.*, 1996; Gallagher *et al.*, 1998; MacDonald *et al.*, 1999; Ucuncu *et al.*, 2000; Westwood *et al.*, 2003; Ucem *et al.*, 2004; Ngan, 2005; Vaughn *et al.*, 2005; Godt *et al.*, 2008).

As timing is an essential issue in Class III treatment, many investigations have been conducted to evaluate the influence of age on the effects of maxillary protraction therapy. In some of these studies, it was reported that the best skeletal effect was possible with early treatment, while in others no statistically significant difference was found in

the treatment effects according to age (Baik, 1995; Merwin *et al.*, 1997; Kapust *et al.*, 1998; Saadia and Torres, 2000; Yuksel *et al.*, 2001; Franchi *et al.*, 2004).

There is an increasing interest in intraoral appliances for Class III malocclusion treatment, by reason of the postural rest position anterior to the occlusal position determined by functional analysis (Rakosi, 1997) or patient compliance required during facemask therapy due to its poor aesthetics. Research has been published relating to the dentofacial effects of intraoral appliances such as the Fränkel III (Ulgen and Firatli, 1994; Baik *et al.*, 2004), bionator III (Garattini *et al.*, 1998), removable mandibular retractor (Tollaro *et al.*, 1996; Baccetti and Tollaro, 1998), double-plate appliance (Ucem *et al.*, 2004), magnetic appliance (Tuncer and Uner, 2005), mini maxillary protraction appliance (Altug and Arslan, 2006), and Class III twin block (Kidner *et al.*, 2003).

Chun *et al.* (1999) introduced the tandem traction bow appliance (TTBA) for the treatment of growing Class III patients. They defined the TTBA as a more aesthetic and comfortable device compared with conventional appliances because it is removable, easy to maintain oral hygiene, and worn intraorally. In two published case reports, it has been suggested that TTBA and modified applications have a similar treatment effect to that of an expander–facemask combination (Chun *et al.*, 1999; Klempner, 2003).

A review of the literature showed that there were no statistical studies documenting the effects of TTBA and comparison with a control group. The aim of this study was to evaluate the dentofacial effects of a modified TTBA in skeletal Class III subjects and the effect of age on treatment response.

Materials and methods

This study was approved by the Health Science Institute of Gazi University.

The material consisted of the pre-treatment/pre-observation and post-treatment/post-observation lateral cephalograms and hand-wrist films of 45 children with skeletal and dental Class III malocclusions. None of the subjects had a history of previous orthodontic treatment. The inclusion criteria were as follows:

1. Skeletal Class III (ANB < 0 degree), due to maxillary retrusion, or a combination of maxillary retrusion and mandibular protrusion.
2. Angle Class III malocclusion with an anterior crossbite.
3. An optimum SN/GoGn angle (between 26 and 38 degrees).
4. Fully erupted maxillary incisors.
5. No congenitally missing teeth or congenital syndromes such as a cleft lip/palate.

Appliance construction

After dental casts were obtained, a wax construction bite was obtained with a 5- to 6-mm vertical opening at the molar region and without any sagittal activation. The modified TTBA comprised an upper splint, a lower splint, and a traction bow. The upper splint had Adams' clasps in the posterior region for retention and elastic hooks between the maxillary central and lateral incisors. The upper splint covered the palatal and occlusal surfaces, in addition to 1–2 mm of the buccal surfaces of the maxillary teeth. The lower splint covered the buccal and lingual surfaces of the mandibular teeth. Activator tubes were embedded in the posterior region of the lower splint. A conventional headgear facebow was modified and used as the traction bow. The outer bows of the face bow were cut to approximately 3 cm and shaped as a letter 'S' (Figure 1a). Two elastics that exerted a force of 400–500 g on one side were worn between the labial hooks and the traction bow. The elastic force was directed between 35 and 40 degrees to the occlusal plane by

arranging the position of the outer traction bows (Figure 1b). Chun *et al.* (1999) applied an elastic force directed at approximately 20 degrees to the occlusal plane. In the present study, the patients were instructed to wear the appliance approximately 14–16 hours a day.

The skeletal age of all patients was determined from hand-wrist films according to the atlas of Greulich and Pyle (1959). Patients with a skeletal age between 6 and 9 years were randomly divided into two groups of 15 patients. The mean skeletal age for the early treatment group (9 girls, 6 boys) was 8.18 ± 0.50 years. The average treatment time for this group was 9 months. Fifteen children (5 girls, 10 boys) with a mean skeletal age of 7.90 ± 0.62 years who were observed without treatment for 8 months served as the controls for the early treatment group. Fifteen patients (5 girls, 10 boys) with a skeletal age between 10 and 13 years formed the late treatment group. The mean skeletal age of this group was 11.75 ± 1.00 years and the average treatment time 11 months. For ethical reasons, it was not possible to form a control for the late treatment group.

Lateral cephalometric radiographs were taken before treatment and after a Class I molar relationship and a minimum overjet of 2 mm was obtained.

Pre- and post-treatment lateral cephalograms were traced by hand and measured by one author (Z.A.). Twenty-one parameters were evaluated (Figure 2).

Total and local superimpositions were carried out to evaluate the skeletal and dental changes. Total superimpositions were made on the best fit of the anterior cranial base (Figure 3a), local superimpositions on the best fit of the palatal structures for the maxilla (Figure 3b), and on the best fit of the posterior border of the symphysis and inferior border of the mandible (Figure 3c). For each superimposition, the pre-treatment tracing T-W line (T: the most superior point of the anterior wall of the sella turcica at the junction with tuberculum sella; W: the point where the middle cranial fossa is intersected by the sphenoid bone) was used as the horizontal reference line. A vertical line perpendicular to T-W at point T was used as the vertical reference plane. On the total superimposition, vertical and

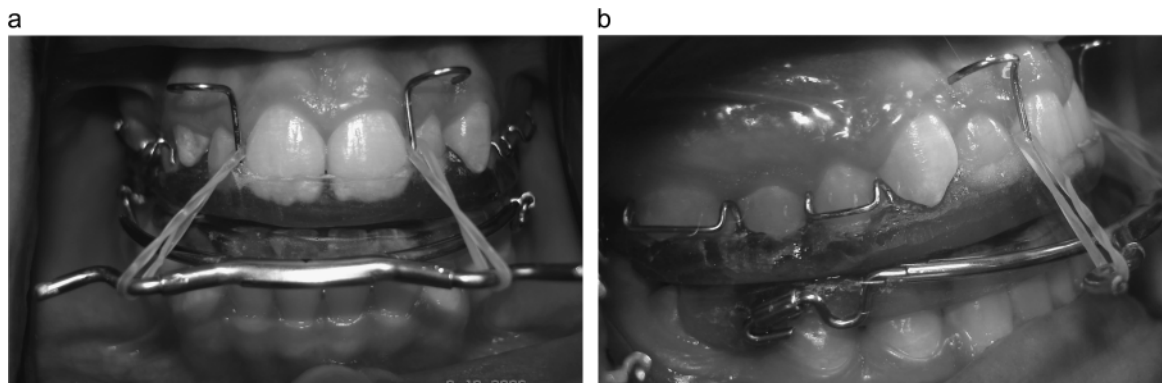


Figure 1 Anterior (a) and lateral (b) view of the modified TTBA.

horizontal changes in point A and Pg were measured. The vertical and horizontal changes of the maxillary and mandibular incisors and molars were evaluated on the local superimpositions (Figure 3a–3c).

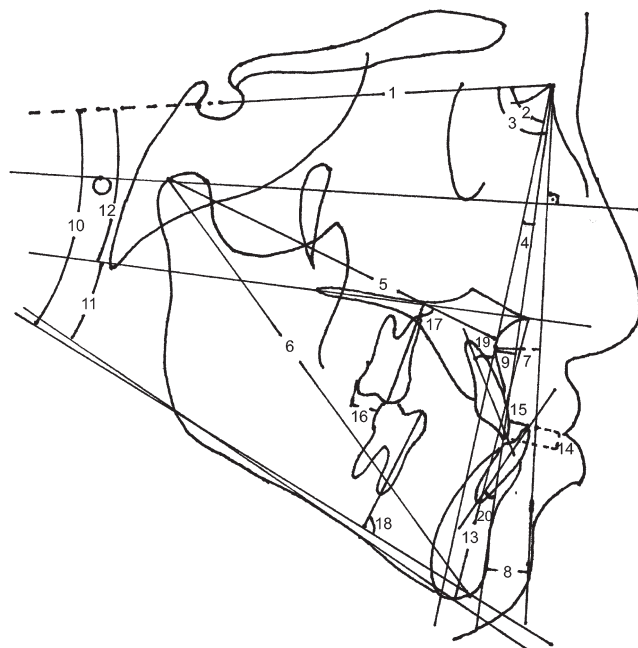


Figure 2 Cephalometric measurements used in the study: 1. SN, 2. SNA, 3. SNB, 4. ANB, 5. CoA, 6. CoGn, 7. NLFH-A, 8. NLFH-Pg, 9. N-PgLA, 10. SN/GoGn, 11. ANS-PNS/GoMe, 12. SN/ANS-PNS, 13. ANS-Me, 14. overbite, 15. overjet, 16. molar relation, 17. upper molar/ANS-PNS, 18. lower molar/GoMe, 19. upper incisor/NA, and 20. lower incisor/NB.

The pre- and post-treatment/observation lateral cephalometric radiographs of 15 subjects from the three groups were retraced, and superimpositions and measurements were repeated after 3 weeks by the same author. Method error coefficients were calculated and found to be within acceptable limits (range 0.98–1.00).

Statistical analysis was undertaken using the Statistical Package for Social Sciences, Windows version 16.0 (SPSS Inc., Chicago, Illinois, USA). Wilcoxon's test was used to evaluate the treatment effects and changes during the observation period in each group. Differences between the groups were determined by a Mann–Whitney U test.

Results

Statistical comparison of the pre-treatment values between the early and late treatment groups showed significant differences in CoA ($P < 0.05$), CoGn, and ANS-Me ($P < 0.01$). Between the early treatment and control group, significant differences were observed in the pre-treatment values of SNB and N-PgLA ($P < 0.05$; Table 1).

Early treatment group

Significant increases were observed in ANB, SN/GoGn, ANS-PNS/GoMe, ANSMe, overjet, and molar relationships ($P < 0.01$; Table 2). On total superimpositions, increases in points A-TW and A-T and on local superimpositions increases in upper molar-T, upper incisor-T and upper incisor-TW, and a decrease in lower incisor-T were statistically significant ($P < 0.01$; Table 3).

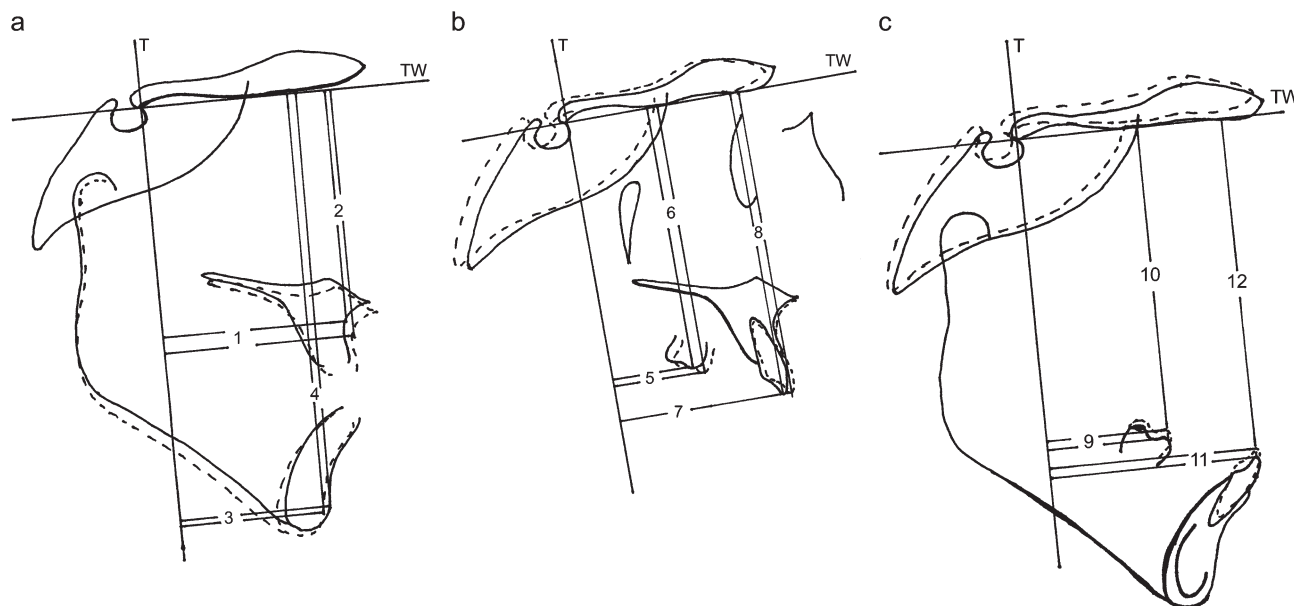


Figure 3 Measurements on (a) total superimposition—1. point A-T, 2. point A-TW, 3. pogonion-T, and 4. pogonion-TW; (b) maxillary local superimposition—5. upper molar-T, 6. upper molar-TW, 7. upper incisor-T, and 8. upper incisor-TW; and (c) mandibular local superimposition—9. lower molar-T, 10. lower molar-TW, 11. lower incisor-T, and 12. lower incisor-TW.

Table 1 Pre-treatment/pre-observation mean (X) and standard error of mean (Sx) values and statistical differences between the groups.

	1. Early treatment group (n = 15)		2. Late treatment group (n = 15)		3. Control group (n = 15)		P	
	X	Sx	X	Sx	X	Sx	1-2	1-3
1. SN (mm)	67.5	0.63	69.5	1.04	67.5	0.72		
2. SNA (dg)	78.1	0.62	77.5	1.19	76.8	0.71		
3. SNB (dg)	80.5	0.70	80.7	0.98	78.5	0.67		*
4. ANB (dg)	-2.3	0.28	-3.2	0.42	-1.73	0.22		
5. CoA (mm)	82.1	0.61	84.8	1.14	80.6	0.99	*	
6. CoGn (mm)	109.8	0.90	117.5	1.46	107.6	1.25	**	
7. NLFH-A (mm)	-3.4	0.43	-3.9	0.85	-3.3	0.73		
8. NLFH-Pg (mm)	-1.2	1.18	0.4	0.93	-3.2	1.22		
9. N-PgLA (mm)	-2.8	0.36	-4.0	0.46	-1.7	0.32		*
10. SN/Go-Gn (dg)	32.4	0.86	33.5	0.93	34.2	0.55		
11. ANS-PNS/Go-Me (dg)	26.0	1.16	27.8	1.02	28.7	0.73		
12. SN/ANS-PNS (dg)	8.1	0.73	7.9	0.80	7.5	0.61		
13. ANS-Me (mm)	60.7	1.09	66.8	1.43	63.5	0.90	**	
14. Overbite (mm)	2.3	0.53	3.2	0.55	2.6	0.64		
15. Overjet (mm)	-2.1	0.24	-2.5	0.35	-2.4	0.24		
17. Molar relation (mm)	-3.5	0.35	-5.0	0.77	-3.3	0.33		
18. Upper molar/ANS-PNS (dg)	104.6	1.69	104.2	1.16	106.5	1.31		
19. Lower molar/Go-Me (dg)	99.5	1.08	99.9	1.27	98.8	1.46		
20. Upper incisor/NA (dg)	21.5	1.44	24.7	1.28	20.5	1.75		
21. Lower incisor/NB (dg)	19.4	1.02	19.8	1.52	21.6	1.10		

* $P < 0.05$. ** $P < 0.01$.**Table 2** Mean (X) and standard error of mean (Sx) values of treatment/observation changes and statistical differences between the groups.

	1. Early treatment group (n = 15)			2. Late treatment group (n = 15)			3. Control group (n = 15)			P	
	X	Sx	P	X	Sx	P	X	Sx	P	1-2	1-3
1. SN (mm)	0.9	0.13	**	1.0	0.20	**	0.9	0.15	**		
2. SNA (dg)	0.7	0.28	*	1.5	0.45	**	0.5	0.24			
3. SNB (dg)	-1.1	0.32	**	-0.5	0.41		0.4	0.27			**
4. ANB (dg)	1.7	0.24	**	2.1	0.18	**	0.0	0.20			**
5. CoA (mm)	1.8	0.29	**	3.0	0.49	**	1.3	0.32	**		
6. CoGn (mm)	1.9	0.42	**	3.3	0.73	**	2.9	0.43	**		
7. NLFH-A (mm)	0.5	0.29		2.2	0.67	**	-0.1	0.59		*	
8. NLFH-Pg (mm)	-1.7	0.76	*	-0.9	0.80		0.50	0.77			
9. N-PgLA (mm)	1.4	0.20	**	1.5	0.33	**	-0.3	0.20			**
10. SN/Go-Gn (dg)	0.9	0.27	**	1.1	0.36	**	0.27	0.33			
11. ANS-PNS/Go-Me (dg)	1.9	0.42	**	2.0	0.58	**	0.8	0.35			*
12. SN/ANS-PNS (dg)	-0.7	0.34		-0.8	0.49		-0.1	0.30			
13. ANS-Me (mm)	2.8	0.49	**	4.1	0.63	**	1.4	0.38	**		*
14. Overbite (mm)	-1.2	0.52	*	-2.5	0.50	**	0.3	0.22			**
15. Overjet (mm)	3.6	0.36	**	4.4	0.34	**	0.3	0.23			**
17. Molar relation (mm)	2.7	0.39	**	3.6	0.69	**	-0.1	0.25			**
18. Upper molar/ANS-PNS (dg)	-0.5	0.66		-4.0	0.8	**	-0.4	0.99		**	
19. Lower molar/Go-Me (dg)	5.6	2.26		2.6	0.9	**	1.7	1.58			
20. Upper incisor/NA (dg)	2.9	0.71	**	3.5	0.59	**	0.6	0.80			*
21. Lower incisor/NB (dg)	-4.8	0.67	**	-3.6	0.81	**	0.1	0.47			**

* $P < 0.05$. ** $P < 0.01$.*Late treatment group*

Increases in ANB, SN/GoGn, ANS-PNS/Go-Me, ANS-Me, overjet, and molar relationships were statistically significant ($P < 0.01$; Table 2). On total superimposition, significant

increases were found in points A-T and A-TW ($P < 0.01$, $P < 0.05$, respectively). Decreases in lower molar-T and lower incisor-TW and an increase in upper incisor-T were significant ($P < 0.05$; Table 3).

Table 3 Mean (X) and standard error of mean (Sx) values of treatment/observation changes on superimpositions and statistical differences between the groups.

	1. Early treatment group (n = 15)					2. Late treatment group (n = 15)					3. Control group (n = 15)					P	
	Pre-treatment		Post-treatment		P	Pre-treatment		Post-treatment		P	Pre-observation		Post-observation		P	1-2	1-3
	X	Sx	X	Sx		X	Sx	X	Sx		X	Sx	X	Sx			
Total superimposition																	
1. Point A-T	49.3	0.86	50.8	0.88	**	51.1	1.61	53.6	1.74	**	48.3	1.35	49.0	1.34	*	*	*
2. Point A-TW	56.0	1.37	57.4	1.39	**	60.2	1.30	61.4	1.46	*	57.6	0.98	59.3	0.95	**		
3. Pogonion-T	48.1	4.28	47.8	4.71		47.6	2.07	47.3	2.49		38.1	2.43	39.2	2.39	**		
4. Pogonion-TW	102.9	1.72	106.4	1.77	**	112.1	2.08	116.5	2.26		106.0	1.28	109.2	1.24	**		
Local superimposition																	
5. Upper molar-T	18.6	1.07	19.4	1.11	**	22.9	1.34	24.3	1.37		17.3	1.58	17.6	1.66			
6. Upper molar-TW	65.8	1.01	66.1	1.04		72.4	1.43	74.1	1.51	**	66.4	1.12	67.5	1.01	**		
7. Upper incisor-T	47.7	1.11	48.0	1.22	**	51.3	2.06	52.9	2.11	*	45.5	1.55	46.2	1.59	**		
8. Upper incisor-TW	76.0	1.45	76.8	1.42	**	81.9	1.56	82.3	1.50	**	77.7	1.11	78.7	1.03	**		
9. Lower molar-T	22.7	1.01	21.9	1.13		28.6	1.53	28.2	1.46	*	20.7	1.58	21.1	1.63			*
10. Lower molar-TW	67.1	1.16	66.9	1.11		74.2	1.50	72.9	1.32	**	68.2	0.96	67.2	1.02	**	**	*
11. Lower incisor-T	51.1	1.17	49.6	1.17	**	54.8	1.88	53.6	1.85	**	48.7	1.71	49.1	1.75	*		**
12. Lower incisor-TW	74.2	1.47	73.5	1.63		79.3	1.52	78.0	1.50	*	77.0	1.17	76.2	1.13	**		

* $P < 0.05$. ** $P < 0.01$.

Control group

In this group, there was a statistically significant increase ($P < 0.01$) in ANS-Me during the observation period (Table 2). On total superimposition, points A-T and A-TW increased significantly ($P < 0.05$, $P < 0.01$, respectively). On mandibular local superimposition, lower molar-TW and lower incisor-TW showed significant decreases ($P < 0.01$), while lower incisor-T increased significantly ($P < 0.05$; Table 3).

Comparison of the early treatment group with the control group

The decrease in SNB was significantly different compared with the increase in the control group ($P < 0.01$). The increase in ANB and NPgLA in the early treatment group showed a significant difference compared with the control group ($P < 0.01$). Vertical dimensional evaluation showed that there were significant differences in ANS-PNS/GoMe and ANS-Me between the early treatment and control group ($P < 0.05$). Changes in overbite, overjet, and molar relationships in the early treatment group were significantly different compared with the control group ($P < 0.01$). Significant differences were observed in upper incisor/NA and lower incisor/NB between the early treatment and control group ($P < 0.05$, $P < 0.01$, respectively; Table 2).

The horizontal change in point A (point A-T) was significantly greater in the early treatment group compared with the control group ($P < 0.05$). On mandibular local superimposition, decreases in lower molar-T and lower incisor-T in the early treatment group were significantly different compared with those in the control group ($P < 0.05$, $P < 0.01$, respectively; Table 3).

Comparison of the treatment groups

The increase in NLFH-A in the late treatment group was significantly greater than in the early treatment group ($P < 0.05$). Decreases in upper molar tipping (upper molar/ANS-PNS) showed significant differences between the treatment groups (Table 2).

The increase in point A-T in the early treatment group was significantly different compared with that in the late treatment group ($P < 0.05$). On local superimpositions, comparison of the treatment groups showed that decreases in lower molar-TW were significantly different ($P < 0.01$; Table 3).

Discussion

This study aimed to evaluate the dentofacial effects of a modified TTBA in two different skeletal age groups, with a control group for the younger subjects.

The pre-treatment values of CoA, CoGn, and ANS-Me showed significant difference between the treatment groups. For these measurements, McNamara and Brudon (1993) determined different values for different age groups that were derived from the Bolton Standards and the Burlington Orthodontic Research Centre. As the treatment groups in the present study were formed from different age groups, such as 6–9 and 10–13 years, it is not surprising to find significant difference between the treatment groups at the beginning of treatment. The pre-treatment values relating to the inclusion criteria (i.e. ANB < 0 degree) showed no significant difference between the early treatment and control groups; however, a significantly smaller SNB angle and a greater N-PgLA dimension were observed in the control group compared with the early treatment group.

In several facemask studies, significant forward movement of the maxilla has been reported (Williams *et al.*, 1997; Kapust *et al.*, 1998; Nartallo-Turley and Turley, 1998; MacDonald *et al.*, 1999; Baccetti *et al.*, 2000; Saadia and Torres, 2000; Arman *et al.*, 2004; Ucem *et al.*, 2004; Tortop *et al.*, 2007; Vaughn *et al.*, 2005). Although Baccetti and Tollaro (1998) and Tollaro *et al.* (1996) found forward movement of point A during removable mandibular retractor application, no significant difference was observed in SNA with other functional appliances used in Class III treatment (Ulgen and Firatli, 1994; Baik *et al.*, 2004; Tuncer and Uner, 2005). The double-plate (Ucem *et al.*, 2004) and mini maxillary protraction (Altug and Arslan, 2006) appliances have a direct force vector that affects the maxilla, and both cause forward movement at point A. In the present study, a significant increase in point A-T indicated the forward sagittal effect of the modified TTBA in the maxilla in both treatment groups. On superimpositions, the forward displacement of point A was greater in the early treatment group than in the control group. In some studies, greater improvement of skeletal sagittal relationships was noted during early treatment compared with late treatment in Class III malocclusion subjects (Merwin *et al.*, 1997; Baccetti and Tollaro, 1998; Franchi *et al.*, 1998; Kapust *et al.*, 1998). Contrary to these findings, forward displacement of point A according to N \perp FH and sagittal displacement of point A on total superimpositions (point A-T) were smaller in the early treatment group compared with the late treatment group. This could be explained by the patients being close to their pubertal spurt in the late treatment group. In some studies, it has been suggested that responses to facemask therapy can occur in older children until the beginning of adolescence (Merwin *et al.*, 1997; Saadia and Torres, 2000; Franchi *et al.*, 2004). However, long-term evaluation showed a decrease in the percentage of successful outcomes after 10 years of age (Franchi *et al.*, 2004; Wells *et al.*, 2006).

In some facemask studies, counterclockwise rotation of the palatal plane has been reported (Baccetti *et al.*, 1998; Kapust *et al.*, 1998; MacDonald *et al.*, 1999; Vaughn *et al.*, 2005). Contrary to these findings, Westwood *et al.* (2003) found no significant difference during active treatment with a facemask. As there were non-significant changes in the palatal plane (SN/ANS-PNS) and a downward movement of point A (point A-TW) in the treatment groups in the present study, it is suggested that the force direction of the modified TTBA was successful in vertical control of the maxilla.

The only significant sagittal difference related to the mandible was in SNB. Although the modified TTBA is a tooth-borne appliance, it has a slight backward effect on the mandible. In several studies evaluating the effects of facemask therapy, increases in mandibular dimensions were found. The findings of most of these studies are in agreement concerning the decrease in SNB that indicates downward and backward rotation of the mandible (Takada *et al.*, 1993; Kapust *et al.*, 1998; Nartallo-Turley and Turley, 1998; MacDonald *et al.*, 1999; Cozza *et al.*, 2004; Vaughn *et al.*,

2005). A backward rotation associated with a reduction in mandibular position was among the findings of some removable appliances studies (Tollaro *et al.*, 1996; Baccetti and Tollaro, 1998; Garattini *et al.*, 1998; Kidner *et al.*, 2003; Tuncer and Uner, 2005). Chun *et al.* (1999) reported a 3 degree decrease in SNB with the TTBA but in the present study the mean differences in both treatment groups were less (early treatment group X = -1.1 degree; late treatment group X = -0.5 degree). While SN/GoGn angle increased significantly in both treatment groups, the change in the early treatment group was not significantly different when compared with the control group. The significant difference in ANS-PNS/Go-Me in the early treatment group might be a result of the non-significant changes in the palatal and mandibular planes. However, the increase in lower face height (ANS-Me) and the decrease in overbite in the early treatment group were significantly greater than in the control group. On superimposition, there was no significant difference in the vertical position of pogonion between the early treatment and control group. As vertical control of the modified TTBA is doubtful, the use of the appliance in high angle cases should be avoided.

As a result of the forward movement of the maxilla and the slight backward movement of the mandible, a significant increase was observed in ANB after TTBA treatment.

Upper incisor protrusion and labioversion in both groups were statistically significant but only labioversion in the early treatment group was significantly different compared with the control group. The lower incisors in both treatment groups were significantly retruded and tipped lingually. As a result of these dental changes and the skeletal changes, a positive overjet was obtained in both treatment groups while a negative overjet remained without a significant change in the control group.

Although there was no significant difference between the treatment groups, mesial movement of the upper molars in the early treatment group and uprighting of the lower molar in the late treatment group was found to be statistically significant. A significant increase was observed in molar relationship due to the dental and skeletal changes.

Conclusion

Satisfactory correction was obtained of the skeletal and dental Class III malocclusion in both treatment groups. Thus, it was concluded that the indications for treatment with a modified TTBA include subjects with a skeletal Class III (due to maxillary retrusion or a combination of maxillary retrusion and mandibular protrusion) and an optimum SN/GoGn angle. As the extraoral view of the appliance is more aesthetic compared with a facemask, it could be a good alternative for non-compliant patients.

The modified TTBA showed similar effects in both treatment groups except for upper molar tipping, sagittal displacement of point A (point A-T), and N \perp FH. However, despite the similar effects during different growth periods, a long-term evaluation would be of value.

References

- Altug Z, Arslan A D 2006 Skeletal and dental effects of a mini maxillary protraction appliance. *Angle Orthodontist* 76: 360–368
- Arman A, Toygar T U, Abuhijleh E 2004 Profile changes associated with different treatment approaches in Class III malocclusion. *Angle Orthodontist* 74: 733–740
- Baccetti T, Franchi L, McNamara J A 2000 Treatment and posttreatment craniofacial changes after rapid maxillary expansion and facemask therapy. *American Journal Orthodontics and Dentofacial Orthopedics* 118: 404–413
- Baccetti T, McGill J, Franchi L, McNamara J A, Tollaro I 1998 Skeletal effects of early treatment of Class III malocclusion with maxillary expansion and facemask therapy. *American Journal Orthodontics and Dentofacial Orthopedics* 113: 333–343
- Baccetti T, Tollaro I 1998 A retrospective comparison of functional appliance treatment of Class III malocclusions in the deciduous and mixed dentitions. *European Journal of Orthodontics* 20: 309–317
- Baik H S 1995 Clinical results of the maxillary protraction in Korean children. *American Journal Orthodontics and Dentofacial Orthopedics* 108: 583–592
- Baik H S, Jee S H, Lee K J, Oh T K 2004 Treatment effects of Fränkel functional regulator III in children with Class III malocclusions. *American Journal Orthodontics and Dentofacial Orthopedics* 125: 294–301
- Chong Y H, Ive J C, Årtun J 1996 Changes following the use of protraction headgear for early correction of Class III malocclusion. *Angle Orthodontist* 66: 351–362
- Chun Y, Jeong S G, Row J, Yang S J 1999 A new appliance for orthopedic correction of Class III malocclusion. *Journal of Clinical Orthodontics* 33: 705–711
- Cozza P, Marino A, Mucedero M 2004 An orthopaedic approach to the treatment of Class III malocclusions in the early mixed dentition. *European Journal of Orthodontics* 26: 191–199
- Ellis E, McNamara J A 1984 Components of adult Class III malocclusion. *Journal of Oral and Maxillofacial Surgery* 42: 295–305
- Franchi L, Baccetti T, McNamara J A 1998 Shape-coordinate analysis of skeletal changes induced by rapid maxillary expansion and facial mask therapy. *American Journal Orthodontics and Dentofacial Orthopedics* 114: 418–426
- Franchi L, Baccetti T, McNamara J A 2004 Postpubertal assessment of treatment timing for maxillary expansion and protraction therapy followed by fixed appliances. *American Journal Orthodontics and Dentofacial Orthopedics* 126: 555–568
- Gallagher R W, Miranda F, Buschang P H 1998 Maxillary protraction: treatment and posttreatment effects. *American Journal of Orthodontics and Dentofacial Orthopedics* 113: 612–619
- Garattini G, Levrini L, Crozzoli P, Levrini A 1998 Skeletal and dental modifications produced by the Bionator III appliance. *American Journal Orthodontics and Dentofacial Orthopedics* 114: 40–44
- Godt A, Zeyher C, Schatz Maier D, Göz G 2008 Early treatment to correct Class III relations with or without facemasks. *Angle Orthodontist* 78: 44–49
- Greulich W W, Pyle S I 1959 Radiographic atlas of skeletal development of the hand and wrist, 2nd edn. Stanford University Press, Stanford
- Guyer E C, Ellis E E, McNamara J A, Behrents R G 1986 Components of Class III malocclusion in juveniles and adolescents. *Angle Orthodontist* 56: 7–30
- Kapust A J, Sinclair P M, Turley P K 1998 Cephalometric effects of facemask-expansion therapy in Class III children: a comparison of three age groups. *American Journal Orthodontics and Dentofacial Orthopedics* 113: 204–212
- Kidner G, DiBiase A, DiBiase D 2003 Class III twin blocks: a case series. *Journal of Orthodontics* 30: 197–201
- Klempner L S 2003 Early orthopedic Class III treatment with a modified tandem appliance. *Journal of Clinical Orthodontics* 37: 218–223
- MacDonald K E, Kapust A J, Turley P K 1999 Cephalometric changes after the correction of Class III malocclusion with maxillary expansion/facemask therapy. *American Journal of Orthodontics and Dentofacial Orthopedics* 116: 13–24
- McNamara J A, Brudon W L 1993 Orthodontic and orthopedic treatment in mixed dentition. Needham Press, Ann Arbor
- Merwin D, Ngan P, Hägg U, Yiu C, Wei H Y S 1997 Timing for effective application of anteriorly directed orthopedic force to the maxilla. *American Journal Orthodontics and Dentofacial Orthopedics* 112: 292–299
- Nartallo-Turley P E, Turley P K 1998 Cephalometric effects of combined palatal expansion and facemask therapy on Class III malocclusion. *Angle Orthodontist* 68: 217–224
- Ngan P 2005 Early treatment of Class III malocclusion. *Seminars in Orthodontics* 11: 140–145
- Ngan P, Hägg U, Yiu C, Merwin D, Wei S H Y 1996 Treatment response to maxillary expansion and protraction. *European Journal of Orthodontics* 18: 151–168
- Rakosi T 1997 Treatment of Class III malocclusions. In: Graber T M, Rakosi T, Petrovic A G (eds). *Dentofacial orthopedics with functional appliances*, Chapter 21. 2nd edn, Mosby, St Louis
- Saadia M, Torres E 2000 Sagittal changes after maxillary protraction with expansion in Class III patients in the primary, mixed and late mixed dentitions: a longitudinal retrospective study. *American Journal Orthodontics and Dentofacial Orthopedics* 117: 669–680
- Suda N, Ishii-Suzuki M, Hirose K, Hiyama S, Suzuki S, Kuroda T 2000 Effective treatment plan for maxillary protraction: is the bone age useful to determine the treatment plan? *American Journal Orthodontics and Dentofacial Orthopedics* 118: 56–62
- Takada K, Petdachai S, Dakuda M 1993 Changes in the dentofacial morphology in skeletal Class III children by a modified protraction headgear and chin cup: a longitudinal cephalometric appraisal. *European Journal of Orthodontics* 15: 211–221
- Tollaro I, Baccetti T, Franchi L 1996 Craniofacial changes induced by early functional treatment of Class III malocclusion. *American Journal Orthodontics and Dentofacial Orthopedics* 109: 310–318
- Tortop T, Keykubat A, Yuksel S 2007 Facemask therapy with and without expansion. *American Journal Orthodontics and Dentofacial Orthopedics* 132: 467–474
- Tuncer C, Uner O 2005 Effects of a magnetic appliance in functional Class III patients. *Angle Orthodontist* 75: 768–777
- Ucem T T, Ucuncu N, Yuksel S 2004 Comparison of double plate appliance and facemask therapy in treating Class III malocclusions. *American Journal Orthodontics and Dentofacial Orthopedics* 126: 672–679
- Ucuncu N, Ucem T T, Yuksel S 2000 A comparison of chin cap and maxillary protraction appliance in the treatment of skeletal Class III malocclusions. *European Journal of Orthodontics* 22: 43–51
- Ulgen M, Firatli S 1994 The effects of the Fränkel's function regulator on the Class III malocclusion. *American Journal Orthodontics and Dentofacial Orthopedics* 105: 561–567
- Vaughn G A, Mason B, Moon H B, Turley P 2005 The effects of maxillary protraction therapy with or without rapid palatal expansion: a prospective, randomized clinical trial. *American Journal Orthodontics and Dentofacial Orthopedics* 128: 299–309
- Wells A P, Sarver D M, Proffit W R 2006 Long-term efficacy of reverse pull headgear therapy. *Angle Orthodontist* 76: 915–922
- Westwood P V, McNamara J A, Baccetti T, Franchi L, Sarver D M 2003 Long-term effects of Class III treatment with rapid maxillary expansion and facemask therapy followed by fixed appliances. *American Journal Orthodontics and Dentofacial Orthopedics* 123: 306–320
- Williams M D, Sarver D M, Sadowsky P L, Bradley E 1997 Combined rapid maxillary expansion and protraction facemask in the treatment of Class III malocclusions in growing children: a prospective long-term study. *Seminars in Orthodontics* 3: 265–274
- Yuksel S, Ucem T T, Keykubat A 2001 Early and late facemask therapy. *European Journal of Orthodontics* 23: 559–568

Copyright of European Journal of Orthodontics is the property of Oxford University Press / UK and its content may not be copied or emailed to multiple sites or posted to a listserv without the copyright holder's express written permission. However, users may print, download, or email articles for individual use.