

Assessment of dental anomalies on panoramic radiographs: inter- and intraexaminer agreement

Katrien Van Parys*, Irene H. A. Aartman**, Reinder Kuitert* and Andrej Zentner*

Departments of *Orthodontics and **Social Dentistry and Behavioural Sciences, Academic Centre for Dentistry Amsterdam (ACTA), University of Amsterdam and VU University Amsterdam, The Netherlands

Correspondence to: Katrien Van Parys, Department of Orthodontics, Academic Centre for Dentistry Amsterdam (ACTA), Gustav Mahlerlaan 3004, 1081 LA Amsterdam, The Netherlands. E-mail: K.v.Parys@acta.nl

SUMMARY The presence of dental anomalies has been rated radiographically in a number of studies. However, since the reliability of the assessment of these anomalies has rarely been investigated, the aim of this study was to examine inter- and intraexaminer agreement in identifying morphological dental anomalies, such as tooth agenesis, dilacerated, pipette-shaped, blunt, pointed, and short roots. Pre-treatment panoramic radiographs of 40 patients (13 males and 27 females; mean age 27.7 ± 10.8 years) treated between 1983 and 2008 were selected. Four examiners independently assessed the radiographs twice. For a dilacerated root and agenesis, a definition was given. For pipette-shaped, blunt, or pointed roots, a drawing was shown, and for a short root, a ratio was used to identify the anomaly.

Intraexaminer agreement of the assessments of the dental anomalies was presented by Cohen's Kappa and varied between -0.01 for short roots and 1.00 for agenesis. With respect to short roots, three of the examiners did not rate them to be present on at least one measurement occasion. This implies that intraexaminer agreement could not be calculated for these three examiners. Interexaminer agreement for dilacerated roots varied between 0.14 and 0.50 , for pipette-shaped roots between -0.01 and 0.33 , for blunt roots between 0.05 and 0.32 , and for pointed roots between 0.17 and 0.37 . All values for agenesis were 1.00 . It can be concluded that assessing agenesis on panoramic radiographs is reliable. Rating the presence of dilacerated, pipette-shaped, blunt, pointed, and short roots on panoramic radiographs, however, does not result in a reliable assessment.

Introduction

Several studies have related dental morphological anomalies to root resorption during orthodontic treatment (Lind, 1972; Levander and Malmgren, 1988; Kjær, 1995; Mirabella and Årtun, 1995; Thongudomporn and Freer, 1998a; Lee *et al.*, 1999; Sameshima and Sinclair, 2001; Kook *et al.*, 2003; Mavragani *et al.*, 2006). Many methods have been used to assess the presence or absence of a dental anomaly. Most studies have used the drawings of Levander and Malmgren (1988) to assess a dental anomaly, such as a short root, a blunt root, a root with an apical bend, or a root with a pipette-shaped apex (Kjær 1995; Levander *et al.*, 1998; Thongudomporn and Freer, 1998a; Nigul and Jagomagi, 2006; Figure 1). Mirabella and Årtun (1995) and Årtun *et al.* (2009) assessed dental anomalies using different drawings (Figure 2). In some studies, on the other hand, the assessments of anomalies were based on definitions without drawings (Lee *et al.*, 1999; Hamasha *et al.*, 2002; Kook *et al.*, 2003; Albashaireh and Khader, 2006; Mavragani *et al.*, 2006), and, in a few investigations, the anomalies were not even defined but the assessments were based on the terms blunt, eroded, pointed, bent, and bottle-shaped root only (Sameshima and Sinclair, 2001, 2004; Apajalahti *et al.*, 2002). This

variety in assessment methods seems to indicate a lack of consensus.

Although these assessments have been conducted in a number of studies, the reliability of the assessment of these anomalies has rarely been investigated. Thongudomporn and Freer (1998a) reported a relationship between anomalous dental morphology and root resorption during orthodontic treatment. They found 99.9 per cent intraexaminer agreement in assessing anomalous dental morphologies, such as agenesis, impaction, dilaceration, ectopic eruption, invagination, peg-shaped lateral incisor, thin or pipette-shaped roots, short or blunt roots, and taurodontism. Those authors referred to the drawings of Levander and Malmgren (1988) and to the definitions by Lind (1972), Jorgenson (1980) and Langlais *et al.* (1995) and assessed the pre-treatment panoramic radiographs of 16 randomly selected subjects on two separate occasions with a washout period of 2 weeks. Such a high percentage of intraexaminer agreement probably referred to all anomalies in a cumulative manner; it appears that no distinction was made between individual anomaly types. Sameshima and Sinclair (2001) scored 10 sets of 24 teeth twice approximately 2 weeks apart. They defined six categories of root shape in

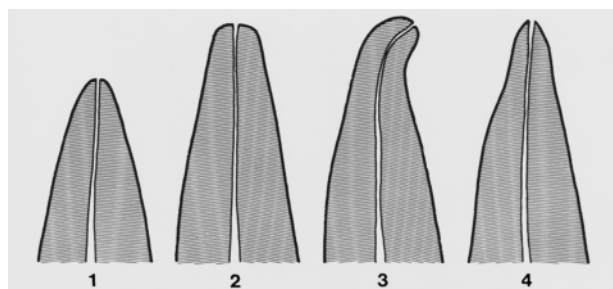


Figure 1 Deviating root forms (after Levander and Malmgren, 1988). (1): Short root, (2): blunt root, (3): root with an apical bend, and (4): root with an apical pipette shape.

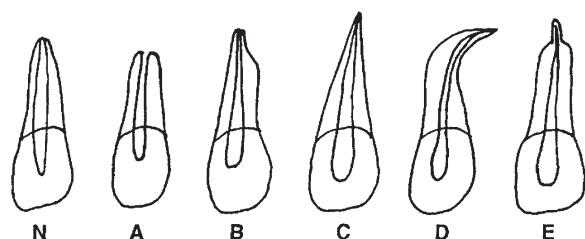


Figure 2 Criteria for subjective scoring of root form as normal (N), blunt (A), eroded (B), pointed (C), bent (D), and bottle shaped (E); after Mirabella and Årtun (1995).

terms of normal, blunt, pipette-shaped, pointed, dilacerated, and incomplete roots. The agreement was tested with an intraclass correlation coefficient generated by Cohen's Kappa test. Coefficients were higher (>0.90) for anterior than for posterior ($0.6-0.7$) teeth. Using a slightly different definition, Hamasha *et al.* (2002) found 100 per cent intraexaminer agreement for dilacerated roots. They re-examined a sample of 100 periapical radiographs containing three dilacerated roots 2 months after the first examination. Recently, Uslu *et al.* (2009) evaluated agenesis, dilacerations, and short or blunt roots among other anomalies on panoramic and periapical radiographs, dental casts, intraoral photographs, and dental histories. The records of 20 randomly selected subjects were re-examined at least 2 weeks after the initial examination by the same clinician, and a Cohen's Kappa coefficient of 1.0 for all previously mentioned anomalies was reported. It appears from the published literature that, although intraexaminer reliability of some dental anomalies has been investigated, interexaminer reliability has never been adequately addressed.

When the relationship between dental anomalies and root resorption is investigated, it is important first to examine the reliability of the assessment of each individual type of these dental anomalies. Therefore, the aim of the present study was to assess inter- and intraexaminer agreement of the identification on panoramic radiographs of dental anomalies, namely tooth agenesis, pipette-shaped root apices, dilacerated, blunt, pointed, and short roots.

Materials and methods

Sample

The study was conducted using panoramic radiographs of patients treated between 1983 and 2008 at the Department of Orthodontics, Academic Centre for Dentistry Amsterdam, The Netherlands. To ensure complete root formation of all teeth, except the third molars, and also to enable the diagnosis of congenitally absent teeth, all radiographs of subjects older than 15 years before the start of treatment with fixed appliances were selected, resulting in a group of 607 patients. Next, a random selection of these 607 patient files took place until 40 patients were included, based on the following exclusion criteria: (1) previous fixed appliance treatment, (2) jaw surgery, (3) poor quality of the panoramic radiograph and no visibility of the periodontal ligament of every tooth, (4) developmental anomalies such as syndromes or clefts, (5) treatment duration <18 months, and (6) anterior restorations performed between the pre- and post-orthodontic panoramic radiograph recordings. The mean age of these 40 patients (13 males and 27 females) was 27.7 ± 10.8 years (range 16.1–51.3 years). The quality of all the selected panoramic radiographs can be considered as equal.

The examiners

Four examiners independently assessed the radiographs twice with a minimum washout period of 1 week. Examiner 1 was a postgraduate student in the third year of orthodontic specialist education, examiner 2 was a specialist orthodontist with 6 months of clinical experience, examiner 3 was an orthodontic specialist with 30 years of clinical experience, and examiner 4 was an orthodontic specialist with 35 years of clinical experience. In summary, examiners 1 and 2 were less experienced and examiners 3 and 4 were more experienced.

Methods

The selection and definitions of the anomalies were based on the literature relevant to the relationship between root resorption during orthodontic treatment and dental anomalies. The following anomalies have been suggested to be related to excessive root resorption during orthodontic treatment and were assessed in the present study as follows.

Dilacerated root. A root was considered as having a dilaceration towards the mesial or distal direction if there was a 45 degree or larger angle between the long axis of the apical part of the root and the long axis of the crown. The long axis was determined using a small ruler, aligned along the pulp of the crown and the pulp of the apical part of the root. When the angle was borderline, a cephalometric protractor was used. A dilaceration towards the buccal or lingual direction was identified by assessing the appearance

of the apical part of the root. If there was a round opaque area with a dark shadow in its central region cast by the apical foramen and the root canal gave a 'bull's eye' appearance, a dilaceration was recorded (Hamasha *et al.*, 2002). The presence of a dilaceration was scored as 1 and absence as 0.

Agenesis. Agenesis of the central and lateral incisors, canines, first and second premolars, first, second, and third molars was diagnosed using panoramic radiographs. Subsequently, the agenesis was confirmed by longitudinal patient records of no history of extraction of that particular tooth, as verified by examiner 1, and was scored as 1. When the tooth was present score 0 was given.

Pipette-shaped, blunt, and pointed roots. A pipette-shaped or blunt root was defined as drawn by Levander and Malmgren (1988, Figure 1). A pointed root was defined as drawn by Mirabella and Årtun (1995, Figure 2). When the root of the tooth was similar to the drawing, it was scored as 1 and when the root appeared normal, it was scored as 0.

Short root. A short root was defined as the root length (RL)/crown length (CL) ratio ≤ 1 . When $RL/CL \leq 1$, a short root was present and was scored as 1 and when $RL/CL > 1$, a short root was absent and was scored as 0 (Lind, 1972). RL was defined as the distance between the most apical point of the root and the midpoint of the most apical and proximal points of the cemento-enamel junction (CEJ). For teeth with two or more roots, the most apical point was the midpoint of a line connecting the most apical points of the two, or the two smallest, roots. CL was defined as the distance between the midpoint of the most apical and proximal points of the CEJ and the middle of the largest mesio-distal distance of the crown, projected on the incisal/occlusal edge. RL was most often longer than CL and no digital calliper was necessary. In cases of doubt, the examiners measured the RL and CL with an electronic digital calliper (ETC Europe, Heiloo, The Netherlands; 0–150 mm/0.01 mm).

After reading a written explanation of the measurement methods, the examiners scored all permanent teeth (excluding the third molars) in relation to the presence or absence of a dilacerated root, pipette-shaped root apex, blunt root, pointed root, and short root on the panoramic radiographs. When agenesis was scored, third molars were included.

Statistical analysis

Intra- and interexaminer agreement was evaluated by calculating Cohen's Kappa. According to Bulman and Osborn (1989), values of Cohen's Kappa below 0.40 were considered as poor agreement, between 0.41 and 0.60 as moderate agreement, between 0.61 and 0.80 as substantial agreement, and between 0.81 and 1.00 as good agreement. Because of

the low prevalence of all dental anomalies investigated (ranging from 0.1 to 5.9 per cent), a minimum of 0.80 was considered as a limit for a reliable assessment. For analysis, the Statistical Package for Social Sciences, Windows version 15.0 (SPSS Inc., Chicago, Illinois, USA) was used.

Results

Table 1 shows the intraexaminer agreement of the assessments of the dental anomalies. Cohen's Kappa varied between -0.01 for short roots and 1.00 for agenesis. With respect to short roots, three of the examiners did not rate them to be present on at least one measurement occasion. This implies that intraexaminer agreement could not be calculated for these three examiners.

Cohen's Kappa values for interexaminer agreement of the first measurements are presented in Table 2. The values

Table 1 Intraexaminer agreement (Cohen's Kappa) for the anomalies assessed by the four examiners.

	Examiner 1	Examiner 2	Examiner 3	Examiner 4
Dilacerated roots	0.47	0.28	0.67	0.50
Agenesis	1.00	1.00	1.00	1.00
Pipette-shaped roots	0.80	0.31	-0.01	1.00
Blunt roots	0.62	0.43	-0.01	0.62
Pointed roots	0.66	0.41	0.29	0.66
Short roots	-0.01	/	/	/

/, no statistics are computed because no short roots were present.

Table 2 Interexaminer agreement (Cohen's Kappa) for the anomalies assessed by the four examiners on the first measurement occasion.

	Examiner 1	Examiner 3	Examiner 4
Dilacerated roots			
Examiner 3	0.20		
Examiner 4	0.14	0.33	
Examiner 2	0.16	0.50	0.25
Agenesis			
Examiner 3	1.00		
Examiner 4	1.00	1.00	
Examiner 2	1.00	1.00	1.00
Pipette-shaped roots			
Examiner 3	0.30		
Examiner 4	-0.01	0.33	
Examiner 2	0.14	0.05	-0.01
Blunt roots			
Examiner 3	0.20		
Examiner 4	0.22	0.32	
Examiner 2	0.14	0.05	0.14
Pointed roots			
Examiner 3	0.37		
Examiner 4	0.17	0.22	
Examiner 2	0.20	0.17	0.30
Short roots			
Examiner 3	/		
Examiner 4	/	/	
Examiner 2	/	/	/

for dilacerated roots varied between 0.14 and 0.50, for pipette-shaped roots between -0.01 and 0.33, for blunt roots between 0.05 and 0.32, and for pointed roots between 0.17 and 0.37. All values for agenesis were 1.00. The assessment of interexaminer agreement on the second occasion showed the same results.

The prevalence of the selected dental anomalies in the sample was calculated as the mean prevalence of the first measurements of the four examiners and the results are presented in Table 3. Short roots were least prevalent at 0.1 per cent, and pointed roots were the most prevalent at 5.9 per cent.

Discussion

The results of this study showed poor reliability for the assessment on panoramic radiographs of dilacerated, pipette-shaped, blunt, pointed, and short roots. On the other hand, identification of tooth agenesis was very reliable. Intraexaminer reliability for pipette-shaped roots for examiners 1 and 4 was also good, resulting in values of 0.80 and 1.00, respectively; however, interexaminer reliability between examiners 1 and 4 for pipette-shaped roots was -0.01. It appears therefore that examiners 1 and 4 were consistent in assessing pipette-shaped roots but did not rate the same roots as pipette shaped. Moreover, examiner 4 measured only one tooth twice as being pipette shaped. On the basis of these findings, the assessment of pipette-shaped, dilacerated, blunt, pointed, and short roots on panoramic radiographs is not reliable.

These findings contrast with the results of previous studies. For instance, [Thongudomporn and Freer \(1998a\)](#) reported 99.9 per cent intraexaminer agreement for the assessment of anomalous dental morphologies on panoramic radiographs when the drawings of [Levander and Malmgren \(1988\)](#) were used. Those authors did not report the agreement per anomaly, instead they pooled thin and pipette-shaped roots and short and blunt roots, whereas the present study assessed individual anomaly types separately. Furthermore, [Thongudomporn and Freer \(1998a\)](#) assessed a wider variety

of anomalies. Nevertheless, these differences do not explain such large discrepancies in percentage agreement. [Sameshima and Sinclair \(2001\)](#) also reported higher intraexaminer reliability coefficients. Having defined six categories of root shape by the terms normal, blunt, pipette shaped, pointed, dilacerated, and incomplete roots, they carried out the assessment on periapical radiographs without distinguishing between the anomalous types when examining intraexaminer agreement. As discussed by [Sameshima and Asgarifar \(2001\)](#), it is more difficult to assess root shape on panoramic radiographs than on periapical films, which might be a reasonable explanation for the discrepancy in reliability coefficients between the study of [Sameshima and Sinclair \(2001\)](#) and the findings of the present research. [Uslu et al. \(2009\)](#) reported perfect interexaminer agreement in assessing agenesis, dilacerations, and short or blunt roots on panoramic and periapical radiographs, dental casts, intraoral photographs, and dental histories. The use of a combination of several sources of information most probably contributed to these results.

In the present research, and in agreement with previously reported studies, identification of tooth agenesis, based on a panoramic radiograph and dental history, was scored as very reliable. [Endo et al. \(2006\)](#) reassessed 10 per cent of 3358 panoramic radiographs of children with and without hypodontia 1 month after the initial survey and obtained 100 per cent agreement in identifying hypodontia.

An important factor in the assessment of anomalies is the source of information. Panoramic and cephalometric records are the routine pre-treatment radiographs for orthodontic treatment. It would be ideal if all relevant information for the orthodontic treatment plan could be obtained from these two radiographs. [Sameshima and Asgarifar \(2001\)](#) compared periapical and panoramic radiographs concerning the assessment of abnormal root shape using the drawings of [Levander and Malmgren \(1988\)](#) and found a higher prevalence of abnormal root shape on periapical films than on panoramic radiographs. As most studies ([Muhammed and Manson-Hing, 1982](#); [Rohlin et al., 1989](#); [Gher and Richardson, 1995](#)) suggest a superiority of periapical over

Table 3 Prevalence of the anomalies.

Anomaly	Prevalence (%) in the present study	Prevalence (%) reported in the literature
Dilacerated roots	0.4	1.8 (Thongudomporn and Freer, 1998b) 13.0 (Ng'ang'a and Ng'ang'a, 2003) 3.8 (Hamasha et al., 2002)
Agenesis	3.2	8.1 (Thongudomporn and Freer, 1998b)
Pipette-shaped roots	1.1	20.7 (for thin or pipette-shaped roots; Thongudomporn and Freer, 1998b) 7.0 (Ng'ang'a and Ng'ang'a, 2003)
Blunt roots	4.4	23.4 (for short or blunt roots; Thongudomporn and Freer, 1998b) 7.0 (Ng'ang'a and Ng'ang'a, 2003)
Pointed roots	5.9	20.7 (for thin or pipette-shaped roots; Thongudomporn and Freer, 1998b)
Short roots	0.1	23.4 (for short or blunt roots; Thongudomporn and Freer, 1998b) 1.3 (Apajalahti et al., 2002) 12.5 (Ng'ang'a and Ng'ang'a, 2003)

over panoramic radiographs in delivering detail, periapical radiographs appear more suitable for assessing root anomalies.

This finding is also supported by the prevalence data obtained in the present study. Although the aim was not to determine the prevalence of dental anomalies, the low prevalence might give an explanation for the contradictory findings but might also reflect the unsuitability of panoramic radiographs to show these abnormalities. A comparison between the prevalence calculated in the present investigation and that reported in previous studies is shown in Table 3. [Thongudomporn and Freer \(1998b\)](#) found a higher prevalence of short or blunt roots (23.4 per cent) than this study (4.5 per cent as the sum of 4.4 per cent blunt roots and 0.1 per cent short roots). Both thin and pipette-shaped roots were more prevalent in the study of [Thongudomporn and Freer \(1998b\)](#) (20.7 per cent) than reported here (7.0 per cent as the sum of 1.1 per cent pipette-shaped roots and 5.9 per cent pointed roots). The prevalence of dilacerated roots and agenesis, 0.4 and 3.2 per cent, respectively, was lower in the present study but was of a comparable magnitude with that reported by [Thongudomporn and Freer \(1998b\)](#) of 1.8 and 8.1 per cent, respectively. [Apajalahti et al. \(2002\)](#) scored short roots on panoramic radiographs using a slightly different definition. Short roots were scored when the root-to-crown ratio was ≤ 1 for at least one pair of permanent teeth bilaterally. Because of this definition, a lower prevalence might be expected, which in fact was higher (1.3 per cent) than that in the present study (0.1 per cent). [Ng'ang'a and Ng'ang'a \(2003\)](#) calculated a prevalence of 12.5 per cent for short roots, 7.0 per cent for blunt roots, 13.0 per cent for roots with an apical bend, and 7.0 per cent for pipette-shaped roots, when assessed on periapical films. These prevalence rates were higher than those in the present research, namely 0.1, 4.4, 1.8, and 1.1, respectively. The most likely reasons for these differences are the definitions of anomalies, the use of periapical radiographs, the ethnicity of the sample, or sample selection in general. Thus, as the present study showed that the assessments of all anomalies on panoramic radiographs were unreliable, the prevalence values found, as well as in other studies using panoramic radiographs, might be questioned.

The examiners identified the anomalies after reading a written explanation. It is possible that the examiners had different interpretations of the definitions and drawings. This might also be an explanation for the low interexaminer agreement. Possibly, more calibration would have improved interexaminer agreement; however, one can doubt the generalizability of an assessment method for which an intensive calibration is necessary in order to achieve a reasonable agreement.

Nevertheless, despite the differences in the methods used, namely periapical versus panoramic radiographs, and (or as a consequence of) the differences in prevalence, the

present findings with regard to intra- and interexaminer agreement of the assessment of dental anomalies are disappointing. The discrepancies in the results combined with some uncertainties from previous studies require more investigations of the reliability of assessments on panoramic radiographs. It also remains to be seen in future studies whether other imaging techniques, such as digital radiographs or cone beam computed tomography, provide more reliable results with respect to the assessment of dental anomalies.

Conclusions

Assessing agenesis on panoramic radiographs is reliable. However, rating the presence of dilacerated, pipette-shaped, blunt, pointed, and short roots on panoramic radiographs does not result in a reliable assessment.

References

- Albashaireh Z S M, Khader Y S 2006 The prevalence and pattern of hypodontia of the permanent teeth and crown size and shape deformity affecting upper lateral incisors in a sample of Jordanian dental patients. *Community Dental Health* 23: 239–243
- Apajalahti S, Hölta P, Turtola L, Pirinen S 2002 Prevalence of short root anomaly in healthy young adults. *Acta Odontologica Scandinavica* 60: 56–59
- Årtun J, Van 't Hullenaar R, Doppel D, Kuijpers-Jagtman A M 2009 Identification of orthodontic patients at risk of severe apical root resorption. *American Journal of Orthodontics and Dentofacial Orthopedics* 135: 448–455
- Bulman J S, Osborn J F 1989 Measuring diagnostic consistency. *British Dental Journal* 166: 377–381
- Endo T, Ozoe R, Kubota M, Akiyama M, Shimooka S 2006 A survey of hypodontia in Japanese orthodontic patients. *American Journal of Orthodontics and Dentofacial Orthopedics* 129: 29–35
- Gher M E, Richardson A C 1995 The accuracy of dental radiographic techniques used for evaluation of implant fixture placement. *International Journal of Periodontal and Restorative Dentistry* 15: 268–283
- Hamasha A A, Al-Khateeb T, Darwzeh A 2002 Prevalence of dilacerations in Jordanian adults. *International Endodontic Journal* 35: 910–912
- Jorgenson R J 1980 Clinician's view of hypodontia. *Journal of the American Dental Association* 101: 283–286
- Kjær I 1995 Morphological characteristics of dentitions developing excessive root resorption during orthodontic treatment. *European Journal of Orthodontics* 16: 25–34
- Kook Y A, Park S, Sameshima G T 2003 Peg-shaped and small lateral incisors not at higher risk for root resorption. *American Journal of Orthodontics and Dentofacial Orthopedics* 123: 253–258
- Langlais R P, Langland O E, Nortje C J 1995 Diagnostic imaging of the jaws. Williams and Wilkins, Baltimore
- Lee R Y, Årtun J, Alonzo T A 1999 Are dental anomalies risk factors for apical root resorption in orthodontic patients? *American Journal of Orthodontics and Dentofacial Orthopedics* 116: 187–195
- Levander E, Malmgren O 1988 Evaluation of the risk of root resorption during orthodontic treatment: a study of the upper incisors. *European Journal of Orthodontics* 10: 30–38
- Levander E, Malmgren O, Stenback K 1998 Apical root resorption during orthodontic treatment of patients with multiple aplasia: a study of maxillary incisors. *European Journal of Orthodontics* 20: 427–434
- Lind V 1972 Short root anomaly. *Scandinavian Journal of Dental Research* 80: 85–93

- Mavragani M, Apisariyakul J, Brudvik P, Selvig K A 2006 Is mild dental invagination a risk factor for apical root resorption in orthodontic patients? *European Journal of Orthodontics* 28: 307–312
- Mirabella A D, Årtun J 1995 Risk factors for apical root resorption of maxillary anterior teeth in adult orthodontic patients. *American Journal of Orthodontics and Dentofacial Orthopedics* 108: 48–55
- Muhammed A H, Manson-Hing L R 1982 A comparison of panoramic and intraoral radiographic surveys in evaluating a dental clinic population. *Oral Surgery* 54: 108–117
- Ng'ang'a P M, Ng'ang'a R N 2003 Maxillary incisor root forms in orthodontic patients in Nairobi, Kenya. *East African Medical Journal* 80: 101–104
- Nigul K, Jagomagi T 2006 Factors related to apical root resorption of maxillary incisors in orthodontic patients. *Stomatologija* 8: 76–79
- Rohlin M, Kullendorff B, Ahlqvist M, Henrikson C O, Hollender L, Sternstrom B 1989 Comparison between panoramic periapical radiography in the diagnosis of periapical bone lesions. *Dentomaxillofacial Radiology* 18: 151–155
- Sameshima G T, Asgarifar K O 2001 Assessment of root resorption and root shape: periapical vs panoramic films. *Angle Orthodontist* 71: 185–189
- Sameshima G T, Sinclair P M 2001 Predicting and preventing root resorption: Part I. Diagnostic factors. *American Journal of Orthodontics and Dentofacial Orthopedics* 119: 505–510
- Sameshima G T, Sinclair P M 2004 Characteristics of patients with severe root resorption. *Orthodontics and Craniofacial Research* 7: 108–114
- Thongudomporn U, Freer T J 1998a Anomalous dental morphology and root resorption during orthodontic treatment: a pilot study. *Australian Orthodontic Journal* 15: 162–167
- Thongudomporn U, Freer T J 1998b Prevalence of dental anomalies in orthodontic patients. *Australian Dental Journal* 43: 395–398
- Uslu O, Akcam M O, Evergen S, Cebeci I 2009 Prevalence of dental anomalies in various malocclusions. *American Journal of Orthodontics and Dentofacial Orthopedics* 135: 328–335

Copyright of European Journal of Orthodontics is the property of Oxford University Press / UK and its content may not be copied or emailed to multiple sites or posted to a listserv without the copyright holder's express written permission. However, users may print, download, or email articles for individual use.