

An association between sella turcica bridging and dental transposition

Rosalia Leonardi*, Mauro Farella** and Martyn T. Cobourne***

*Department of Orthodontics and Clinical Gnathology, University of Catania, Catania, Italy, **Discipline of Orthodontics, Department of Oral Sciences, University of Otago, Otago, New Zealand and ***Department of Orthodontics and Craniofacial Development, King's College London Dental Institute, London, UK

Correspondence to: Professor Rosalia Leonardi, Sezione di Odontostomatologia II, Dipartimento di Specialita' Medico-Chirurgiche, Università di Catania-Azienda Policlinico, via S. Sofia n.78., 95123 Catania, Italy.
E-mail: rleonard@unict.it

SUMMARY The aim of the present study was to determine any association between tooth transposition and bridging of the sella turcica, given the evidence of common embryonic origins associated with these structures and a genetic basis underlying these two conditions. Clinical records of subjects demonstrating dental transposition and normal controls were collected from several hospital orthodontic departments and specialist orthodontic practices. All cases and controls were documented with good quality lateral cephalometric radiographs and dental panoramic tomograms (DPTs). The study sample consisted of 21 Caucasian subjects (7 males and 14 females; mean age 14.5 years; SD 2.2 years), demonstrating either maxillary or mandibular dental transposition. The control group, matched for age and gender to the study sample, comprised 70 Caucasians (31 males and 39 females; mean age 13.8 years; SD 1.8 years) without dental anomalies randomly selected from subjects referred for orthodontic treatment within the same departments. The extent of sella turcica bridging was quantified from each profile radiograph using comparative measurement of length and diameter.

Sella turcica bridging was found more frequently in subjects diagnosed with dental transposition than in the controls, with the difference being statistically significant [chi-square = 7.4; degrees of freedom (df) = 2; $P = 0.025$; Fisher's exact test; $P = 0.042$]. The increased frequency of complete and partial bridging of the sella turcica in subjects with dental transposition provides further evidence of a genetic basis to this condition. As calcification and bridging of this region can present during early childhood, it may act as a useful diagnostic predictor of susceptibility to local dental problems.

Introduction

Tooth transposition has been defined as a form of ectopic eruption, involving the positional interchange of two adjacent teeth or the development and eruption of a tooth into a position normally occupied by a non-adjacent tooth (Peck *et al.*, 1993). The aetiological basis of this anomaly is still not completely understood; however, there is good evidence to suggest a genetic basis (Chattopadhyay and Srinivas, 1996; Shapira and Kufinec, 2001; Ely *et al.*, 2006). Dental transposition is often seen in association with other congenital dental anomalies, such as hypodontia and peg-shaped or diminutive lateral maxillary incisors (Peck *et al.*, 1993, 1998; Plunkett *et al.*, 1998; Ely *et al.*, 2006); there is a marked female predilection (Peck *et al.*, 1998; Plunkett *et al.*, 1998; Ely *et al.*, 2006) and unilateral left-sided dominance (Peck *et al.*, 1993; Plunkett *et al.*, 1998). However, environmental factors can also contribute to the occurrence of transposition, including retained primary teeth (Laptook and Silling, 1983) and previous dental trauma (Dayal *et al.*, 1983). Therefore, a multifactorial model has been suggested, with a genetic predisposition existing under the varying influence of local environmental

factors (Peck *et al.*, 1993; Plunkett *et al.*, 1998; Ely *et al.*, 2006). More recently, a number of localized dental anomalies, such as hypodontia and palatal displacement of the maxillary canine, have been associated with calcification of the interclinoid ligament (ICL) or sella turcica bridging (Leonardi *et al.*, 2006). The presence of intracranial clinical calcifications in addition to those affecting the dentition is highly suggestive of a genetic aetiology underlying both tooth anomalies and those in a broader area of the orofacial field (Pirinen *et al.*, 1996). Indeed, several studies conducted on the shape of the sella turcica have described significant shape variation associated with this structure (Tetradis and Kantor, 1999); moreover, they have concluded that the morphological appearance is established early in embryonic development (Kjær *et al.*, 1998; Nielsen *et al.*, 2005).

Calcification of the ICL, or sella turcica bridging, has been shown to occur in up to 1.1–13 per cent of the general population (Bergland *et al.*, 1968; Cederberg *et al.*, 2003; Axelsson *et al.*, 2004a; Alkofide, 2007) with an increased prevalence in those with severe craniofacial disproportion (Becktor *et al.*, 2000; Jones *et al.*, 2005). However, a clear

distinction between a true bony union of the anterior and posterior process (sella turcica bridge) and 'overlapping' on lateral radiographs is difficult to determine (Axelsson *et al.*, 2004a). In addition, sella turcica bridging is also seen in association with inherited developmental conditions that can affect the craniofacial region, such as nevoid basal cell carcinoma syndrome (NBCCS) and Williams syndrome (Kimonis *et al.*, 1997; Axelsson *et al.*, 2004b). Given the evidence for a genetic basis underlying both dental transposition and sella turcica bridging and the common embryonic origins associated with these tissues, the aim of this study was to determine any possible association between these two conditions. The null hypothesis was that no association between the two conditions would exist and might only be expected by chance.

Subjects and methods

Study population

The clinical records of subjects affected by dental transposition were collected from various hospital orthodontic departments and specialist practices in London, the south-east of England, and Catania, Italy. A diagnosis of tooth transposition was made on the basis of clinical examination and confirmed radiographically. This study sample consisted of 21 Caucasians (7 males and 14 females; mean age 14.5 years; SD 2.2 years) having either maxillary or mandibular dental transposition. Dental panoramic tomograms (DPTs) were used to confirm the presence of a true transposition, involving both the crown and root of the affected teeth. Malocclusion type was not a criterion for sample selection. However, exclusion criteria included subjects with severe craniofacial deviations, who required combined surgical-orthodontic treatment (Becktor *et al.*, 2000), the presence of a cleft lip and palate, craniofacial syndromes, a history of facial trauma, or multi-reagent chemotherapy.

Control group

The control group comprised 70 Caucasian subjects (31 males and 39 females; mean age 13.8 years; SD 1.8 years) without dental anomalies, who were randomly selected from those referred for orthodontic treatment within the same departments during the previous 3 years. Forty-one per cent of the subjects had a skeletal Class I relationship, 55 per cent a Class II, and 4 per cent a Class III. Classification of skeletal type was based on ANB angle (Alkofide, 2007). The exclusion criteria were the same as for the study population.

Cephalometric tracing of sella turcica

All cases and controls were documented with lateral skull cephalometric radiographs and dental panoramic

tomograms. Only radiographs that had the clearest reproduction of the sella turcica area were selected. In order to quantify the extent of a sella turcica bridge from each profile radiograph. The contour of the pituitary fossa from the tip of the dorsum sellae to the tuberculum sella, was traced on Ultraphan transparent acetate sheets in a darkened room on a laminator using a Pentel 0.5 mm lead pencil and measured manually by one observer (RL). The sella turcica length (distance from tuberculum sella to the tip of the dorsum sella) and antero-posterior greatest diameter (distance from tuberculum sella to the furthest point on the inner wall of the pituitary fossa) were measured (Figure 1). It should be emphasised that the length measurement is representative of ICL calcification, and as such, is not a real bone measurement but a measurement between calcified areas.

All measurements were made to the nearest 0.1 mm using a calliper. Sella turcica length and diameter were compared using a standardized scoring scale (Leonardi *et al.*, 2006). Briefly, if the length was greater than or equal to three-quarters of the greatest antero-posterior diameter, sella was scored as type I (no calcification); type II if the length was less than or equal to three-quarters (ICL partially calcified); and type III for a radiographically visible diaphragma sella (ICL completely calcified; Figure 2). The greatest postero-anterior sella turcica diameter measurement was divided by four and the value obtained was compared with sella turcica length.

Reliability of measurements

Duplicate tracings of 10 radiographs were made on two separate occasions by the same author (RL) with a 2 week interval between tracings and the random error was assessed (Houston, 1983). The mean difference between the first and second measurements was not significant. Sella measurement errors for length and diameter were considered minor as they ranged from 0.15 to 0.25 mm.

Statistical analyses

Data were analysed by means of conventional descriptive statistics. Chi-square and Fisher's exact tests were used for subsequent analyses. Bonferroni correction was used for *post hoc* multiple comparisons. The strength of association

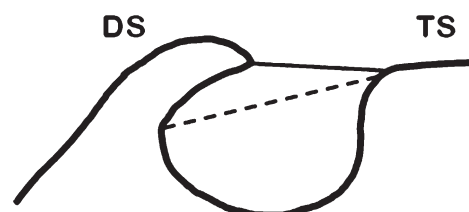


Figure 1 Normal sella turcica morphology and reference lines used for determining bridging. TS, tuberculum sella; DS, dorsum sella. The black line represents sella turcica length, while the dashed line represents the greatest antero-posterior diameter.

between sella turcica bridging and dental transposition was estimated using the odds ratio (± 95 per cent confidence interval). Statistical analyses were carried out by means of the Statistical Package for Social Science (Release 15.0; SPSS Inc., Chicago, Illinois, USA) with a probability level of 0.05 considered statistically significant.

Results

All subjects in the study sample were diagnosed with unilateral transposition, predominantly affecting the maxilla with the exception of one subject demonstrating maxillary bilateral transposition. In 12 of the 21 subjects, maxillary canine first premolar transposition was found, whereas in 6 of 21, transposition involved the maxillary canine and lateral incisor. In the remaining three subjects, a transposition between the mandibular canine and lateral incisor was present.

The overall proportions of types I, II, and III sella calcification (Figures 2 and 3) differed significantly between the subjects and the controls (chi-square = 7.4; $df = 2$; $P = 0.025$; Fisher's exact test; $P = 0.042$). *Post hoc* comparisons indicated that a type III sella was more frequent in cases than in controls ($P < 0.05$) Figure 4.

The absolute and relative frequencies of anomalies associated with sella turcica in the samples are shown in Figure 4. In subsequent analyses, subjects with a partial or complete calcification of the ICL were grouped in a single category including all sella turcica anomalies (i.e. type II + type III). The proportion of these anomalies was still

significantly higher in the dental transposition cases than in the controls (57.1 per cent versus 31.4 per cent; chi-square = 4.6; $df = 1$; $P = 0.033$), with an odds ratio (95 per cent confidence interval) of 2.9 (1.1–7.9).

Discussion

This study describes a previously unreported but clear association between sella turcica bridging and dental transposition. The pituitary gland originates in the embryo as a result of interaction between two ectodermal tissues; neural ectoderm gives rise to the posterior pituitary, whereas a portion of the oral ectoderm develops into the anterior pituitary gland (Treier and Rosenfeld, 1996; Burrows *et al.*, 1999; Sheng and Westphal, 1999). The pituitary fossa itself is situated within the body of the sphenoid bone and differentiates directly from the hypophyseal cartilage of the early chondrocranium. The hypophyseal cartilage is derived from cranial neural crest cells; however, the body of the sphenoid has been shown to include a mesodermal contribution in its more posterior region, at least in the mouse (McBratney-Owen *et al.*, 2008). Teeth develop within the frontonasal process and the maxillary and mandibular processes of the first branchial arch as a result of molecular interaction between the oral epithelium and underlying neural crest cells that migrate into these regions. The establishment of patterning along the dental axis is thought to take place very early in the developmental process, with fixed domains of homeobox gene expression being

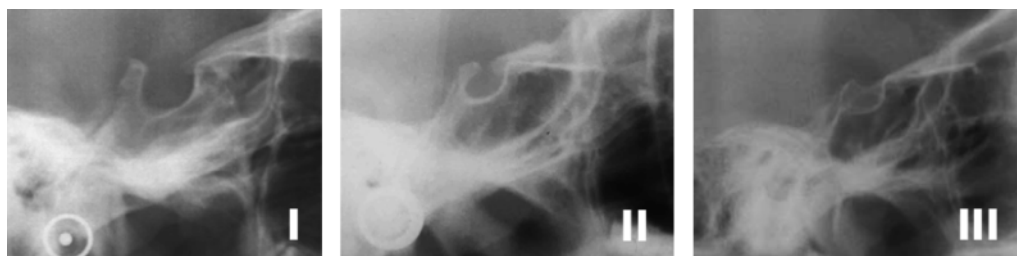

Figure 2 Type I [no calcification of interclinoid ligament (ICL)], type II (ICL partially calcified), and type III (ICL completely calcified).

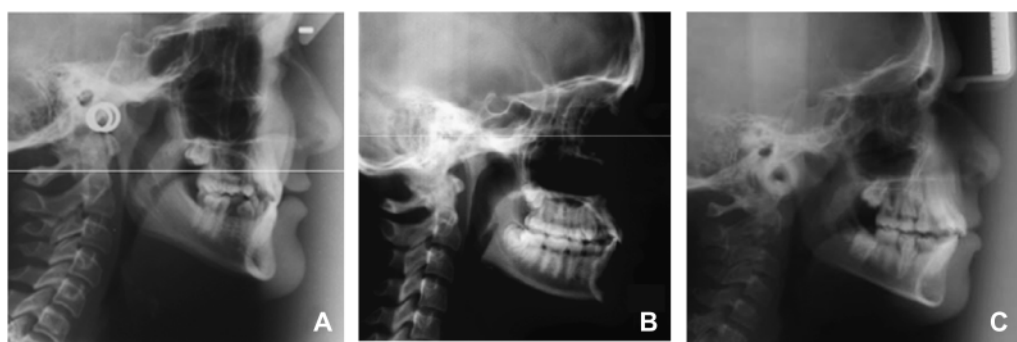


Figure 3 Lateral cephalometric radiographs of patients with (A) dental transposition and bridging of the sella turcica (B) dental transposition and partial bridging of the sella turcica and (C) dental transposition and no calcification of sella, although a cervical fusion between C2 and C3 can be observed (C).

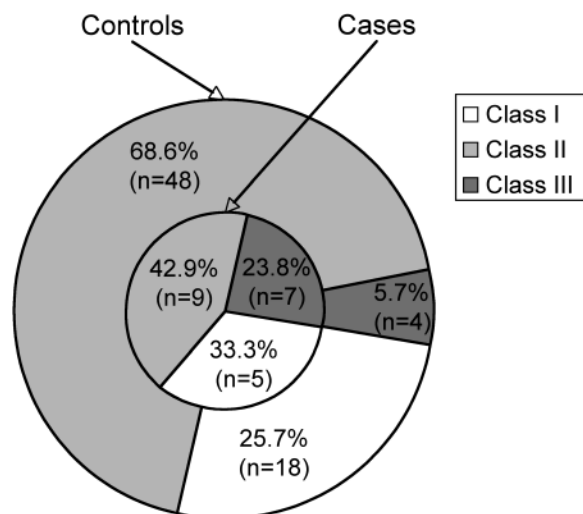


Figure 4 Absolute frequencies of sella anomalies in patients and controls. Type I [no calcification of interclinoid ligament (ICL)], type II (ICL partially calcified) and type III (ICL completely calcified).

established within neural crest cells as a result of signalling from the epithelium (Sharpe, 1995, 2001). A number of common molecular pathways are involved during the early stages of pituitary (Ericson *et al.*, 1998; Sheng and Westphal, 1999; Dassule *et al.*, 2000; Treier *et al.*, 2001), dental (Neubuser *et al.*, 1997; Dassule *et al.*, 2000; Gritli-Linde *et al.*, 2002), and skull (Kim *et al.*, 1998) development, which include signalling mediated through bone morphogenetic proteins, fibroblast growth factors, and hedgehog proteins. Moreover, disruption in these signalling pathways can give rise to inherited syndromic conditions that can include calcification of the sella turcica as part of the clinical spectrum of the disease. A good example of this is provided by NBCCS or Gorlin-Goltz syndrome, an autosomal dominant hamartomatous disorder characterized by multiple basal cell carcinomas affecting the skin, medulloblastoma, multiple and recurrent odontogenic keratocysts of the jaws, spine and rib anomalies, and craniofacial defects, which include calcification of the dura mater and sella (Evans *et al.*, 1993; Shanley *et al.*, 1994; Gorlin, 1995; Kimonis *et al.*, 1997). The gene mutated in NBCCS has been identified as *PATCHED-1* (Wicking *et al.*, 1997; Lindström *et al.*, 2006), which is the principal receptor for the sonic hedgehog ligand (Goodrich *et al.*, 1996; Johnson *et al.*, 1996).

The present investigation analysed the frequency of sella turcica bridging in a sample of subjects affected by dental transposition. The rationale came from previous observations demonstrating an increased prevalence of localized dental anomalies and extremes of craniofacial skeletal variation in subjects with this condition (Becktor *et al.*, 2000; Leonardi *et al.*, 2006). Furthermore, it has been demonstrated that anomalies associated with sella turcica can be a feature of human craniofacial syndromes (Kimonis *et al.*, 1997). The increased frequency of complete

and partial calcification of sella, in subjects with dental transposition, provides further evidence of a genetic basis for these conditions and some commonality in the molecular pathways involved. Indeed, as calcification in this region can appear during early childhood, it may provide an aid to the early diagnosis of some conditions or act as a diagnostic predictor of susceptibility for localized dental problems. Certainly, the findings of this study indicate that subjects with calcification in the region of sella are at potential risk of developing dental transposition. However, care should be taken in making a diagnosis of sella turcica bridging as the appearance of fusion between the anterior and posterior clinoid processes can be due to radiographic superimposition of these structures and not necessarily real bony fusion (Becktor *et al.*, 2000; Axelsson *et al.*, 2004a). In the present study, if this had occurred, it might have been expected to affect both subject samples, which was not the case. Moreover, even though the majority of sella turcica bridges are detectable early in life, in some cases, calcification develops over time and might only be observed on lateral cephalometric radiographs taken at a later stage.

While this association may potentially improve early diagnosis of orthodontic problems, particularly in alerting the clinician to possible ectopic tooth development, some caution must be exercised. The only way of diagnosing early calcification of the sella turcica is with a lateral skull radiograph and current guidelines would suggest that in children under 10 years of age, this form of radiograph is only justified in the presence of a severe skeletal discrepancy, which may require early treatment or monitoring (Isaacson *et al.*, 2008). However, the results of this investigation would suggest that in some cases, particularly where there may be a family history of tooth impaction or early occlusal indications of potential ectopic eruption, some consideration might be given towards radiographic examination of sella as a further predictor. This may allow the instigation of suitable measures to prevent subsequent tooth impaction or transposition (Ericson *et al.*, 1998; Shapira and Kuflinec, 2001).

References

- Alkofide E A 2007 The shape and size of the sella turcica in skeletal Class I, Class II, and Class III Saudi subjects. *European Journal of Orthodontics* 29: 457–463
- Axelsson S, Storhaug K, Kjær I 2004a Post-natal size and morphology of the sella turcica. Longitudinal cephalometric standards for Norwegians between 6 and 21 years of age. *European Journal of Orthodontics* 26: 597–604
- Axelsson S, Storhaug K, Kjær I 2004b Post-natal size and morphology of the sella turcica in Williams syndrome. *European Journal of Orthodontics* 26: 613–621
- Becktor J P, Einersen S, Kjær I 2000 A sella turcica bridge in subjects with severe craniofacial deviations. *European Journal of Orthodontics* 22: 69–74
- Bergland R M, Ray B S, Torack R M 1968 Anatomical variations in the pituitary gland and adjacent structures in 225 human autopsy cases. *Journal of Neurosurgery* 28: 93–99

- Burrows H L, Douglas K R, Seasholtz A F, Camper S A 1999 Genealogy of the anterior pituitary gland: tracing a family tree. *Trends in Endocrinology and Metabolism* 10: 343–352
- Cederberg R A, Benson B W, Nunn M, English J D 2003 Calcification of the interclinoid and petroclinoid ligaments of sella turcica: a radiographic study of the prevalence. *Orthodontics and Craniofacial Research* 6: 227–232
- Chattopadhyay A, Srinivas K 1996 Transposition of teeth and genetic etiology. *Angle Orthodontist* 66: 147–152
- Dassule H R, Lewis P, Bei M, Maas R, McMahon A P 2000 Sonic hedgehog regulates growth and morphogenesis of the tooth. *Development* 127: 4775–4785
- Dayal P K, Shodhan K H, Dave C J 1983 Transposition of canine with traumatic etiology. *Journal of the Indian Dental Association* 55: 283–285
- Ely N J, Sherriff M, Cobourne M T 2006 Dental transposition as a disorder of genetic origin. *European Journal of Orthodontics* 28: 145–151
- Ericson J, Norlin S, Jessell T M, Edlund T 1998 Integrated FGF and BMP signaling controls the progression of progenitor cell differentiation and the emergence of pattern in the embryonic anterior pituitary. *Development* 125: 1005–1015
- Evans D G, Ladusans E J, Rimmer S, Burnell L D, Thakker N, Farndon P A 1993 Complications of the naevoid basal cell carcinoma syndrome: results of a population based study. *Journal of Medical Genetics* 30: 460–464
- Goodrich L V, Johnson R L, Milenkovic L, McMahon J A, Scott M P 1996 Conservation of the hedgehog/patched signaling pathway from flies to mice: induction of a mouse patched gene by hedgehog. *Genes and Development* 10: 301–312
- Gorlin R J 1995 Nevroid basal cell carcinoma syndrome. *Dermatological Clinics* 13: 113–125
- Gritli-Linde A, Bei M, Maas R, Zhang X M, Linde A, McMahon A P 2002 Shh signaling within the dental epithelium is necessary for cell proliferation, growth and polarization. *Development* 129: 5323–5337
- Houston W J B 1983 The analysis of errors in orthodontic measurements. *American Journal of Orthodontics* 83: 382–390
- Isaacson K G, Thom A R, Horner K, Whaites E 2008 Orthodontic radiographs. Guidelines, 3rd edn. British Orthodontic Society, London
- Johnson R L *et al.* 1996 Human homolog of patched, a candidate gene for the basal cell nevus syndrome. *Science* 272: 1668–1671
- Jones R M, Faqir A, Millett D T, Moos K F, McHugh S 2005 Bridging and dimensions of sella turcica in subjects treated by surgical-orthodontic means or orthodontics only. *Angle Orthodontist* 75: 714–718
- Kim H J, Rice D P, Kettunen P J, Thesleff I 1998 FGF-, BMP- and Shh-mediated signalling pathways in the regulation of cranial suture morphogenesis and calvarial bone development. *Development* 125: 1241–1251
- Kimonis V E *et al.* 1997 Clinical manifestations in 105 persons with nevroid basal cell carcinoma syndrome. *American Journal of Medical Genetics* 69: 299–308
- Kjær I, Wagner A, Madsen P, Blichfeldt S, Rasmussen K, Russell B 1998 The sella turcica in children with lumbosacral myelomeningocele. *European Journal of Orthodontics* 20: 443–448
- Laptook T, Silling G 1983 Canine transposition—approaches to treatment. *Journal of the American Dental Association* 107: 746–748
- Leonardi R, Barbato E, Vichi M, Caltabiano M 2006 A sella turcica bridge in subjects with dental anomalies. *European Journal of Orthodontics* 28: 580–585
- Lindström E, Shimokawa T, Toftgård R, Zaphiropoulos P G 2006 PTCH mutations: distribution and analyses. *Human Mutation* 27: 215–219
- McBratney-Owen B, Iseki S, Bamforth S D, Olsen B R, Morriss-Kay G M 2008 Development and tissue origins of the mammalian cranial base. *Developmental Biology* 322: 121–132
- Neubuser A, Peters H, Balling R, Martin G R 1997 Antagonistic interactions between FGF and BMP signaling pathways: a mechanism for positioning the sites of tooth formation. *Cell* 90: 247–255
- Nielsen B W, Molsted K, Kjær I 2005 Maxillary and sella turcica morphology in newborns with cleft lip and palate. *Cleft Palate–Craniofacial Journal* 42: 610–617
- Peck L, Peck S, Attia Y 1993 Maxillary canine-first premolar transposition, associated dental anomalies and genetic basis. *Angle Orthodontist* 63: 99–109
- Peck S, Peck L, Kataja M 1998 Mandibular lateral incisor-canine transposition, concomitant dental anomalies, and genetic control. *Angle Orthodontist* 68: 455–466
- Pirinen S, Arte S, Apajalahti S 1996 Palatal displacement of canine is genetic and related to congenital absence of teeth. *Journal of Dental Research* 75: 1742–1746
- Plunkett D J, Dysart P S, Kardos T B, Herbison G P 1998 A study of transposed canines in a sample of orthodontic patients. *British Journal of Orthodontics* 25: 203–208
- Shanley S *et al.* 1994 Nevroid basal cell carcinoma syndrome: review of 118 affected individuals. *American Journal of Medical Genetics* 50: 282–290
- Shapira Y, Kuftinec M M 2001 Maxillary tooth transpositions: characteristic features and accompanying dental anomalies. *American Journal of Orthodontics and Dentofacial Orthopedics* 119: 127–134
- Sharpe P T 1995 Homeobox genes and orofacial development. *Connective Tissue Research* 32: 17–25
- Sharpe P T 2001 Neural crest and tooth morphogenesis. *Advances in Dental Research* 15: 4–7
- Sheng H Z, Westphal H 1999 Early steps in pituitary organogenesis. *Trends in Genetics* 15: 236–240
- Tetradis S, Kantor M L 1999 Prevalence of skeletal and dental anomalies and normal variants seen in cephalometric and other radiographs of orthodontic patients. *American Journal of Orthodontics and Dentofacial Orthopedics* 116: 572–577
- Treier M, Rosenfeld M G 1996 The hypothalamic-pituitary axis: co-development of two organs. *Current Opinion in Cell Biology* 8: 833–843
- Treier M *et al.* 2001 Hedgehog signaling is required for pituitary gland development. *Development* 128: 377–386
- Wicking C *et al.* 1997 Most germ-line mutations in the nevroid basal cell carcinoma syndrome lead to a premature termination of the PATCHED protein, and no genotype-phenotype correlations are evident. *American Journal of Human Genetics* 60: 21–26

Copyright of European Journal of Orthodontics is the property of Oxford University Press / UK and its content may not be copied or emailed to multiple sites or posted to a listserv without the copyright holder's express written permission. However, users may print, download, or email articles for individual use.