

Identification of a novel *RUNX2* gene mutation in an Italian family with cleidocranial dysplasia

Cristiano Marchisella*, Francesca Rolando*, Lucia Anna Muscarella**, Leopoldo Zelante**, Pietro Bracco* and Maria Rosaria Piemontese**

*Departments of Orthodontics and Gnathology-Masticatory Function, University of Turin, Turin, Italy and

**Servizio di Genetica Medica, Dipartimento dell'Età Evolutiva, IRCCS Ospedale 'Casa Sollievo della Sofferenza', San Giovanni Rotondo, Italy

Correspondence to: Cristiano Marchisella, Via Orazio Antinori 8, 10128 Torino, Italy. E-mail: c.marchisella@tiscali.it

SUMMARY Cleidocranial dysplasia (CCD) is a rare, well-defined skeletal disorder with autosomal dominant inheritance and complete penetrance. Although it involves the whole skeletal system, the main clinical manifestations of CCD are malformations of the skull and clavicles, which lead to a typical appearance of the face and shoulders. Dental aspects are particularly evident and often eruption difficulties are the first indication for the patient, who does not present any other problem. It has been established that insufficiency of the RUNX-related transcription factor, the core-binding factor alpha 1 (CBFA1) protein, causes CCD. This protein is essential in skeletal development by regulating osteoblast differentiation and chondrocyte maturation. CBFA1 protein is encoded by the *RUNX2* gene located on chromosome 6p21.

The molecular characterization of the novel *RUNX2* gene mutation c.580 + 1G > A in an Italian family (a 27-year-old female, her 54-year-old mother and 24-year-old sister) affected by the typical CCD phenotype, which was proven to alter splicing of the *RUNX2* messenger RNA, underscoring the contribution of novel altered splicing mechanism to the aetiology of this disease is presented.

Introduction

Cleidocranial dysplasia (CCD, MIM#119600) is a rare, well-defined skeletal disorder with autosomal dominant inheritance and complete penetrance. Although it affects the whole skeletal system (Spranger, 1974; Gorlin *et al.*, 1990), the main clinical manifestations of CCD are malformations of the skull and clavicles, which lead to the typical and striking appearance of the face and shoulders (De Giorgi, 1971): brachycephalia with a wide forehead, frontal and parietal bossing, hypertelorism, deficiencies in the nasal and lachrymal bones with a depressed nasal bridge and a broad base of the nose, hypoplastic malar areas with deficient pneumatization of the paranasal sinuses, and open skull sutures with late closure of wide fontanelles and wormian bones (Chitayat *et al.*, 1992; Gorlin and Goldman, 1977). Other associated skeletal defects are: hypoplasia of the pelvis with a wide symphysis pubis, often necessitating caesarean section in pregnant females, spina bifida, and delayed and deficient ossification of long bones, which accounts for a short and broad body build, usually apparent between the ages of 4 and 8 years, while birth weight and length are normal (Gorlin *et al.*, 1990; Jensen, 1990; Chitayat *et al.*, 1992; Richardson and Deussen, 1994).

Oral and dental aspects are particularly evident and often eruption difficulties of the permanent incisors are the first indication for a patient, who does not present any other problem (Calabrese, 1974) and sometimes may not be aware of the condition until about 10 years of age (Jensen

and Kreiborg, 1990). Dental treatment is difficult and time consuming, often requiring surgical, orthodontic, and prosthodontic intervention.

It has been established that haploinsufficiency of an osteoblast-specific transcription factor, core-binding factor alpha 1 (CBFA1), causes CCD and is essential in skeletal development by regulating osteoblast differentiation and chondrocyte maturation (Lee *et al.*, 1997; Mundlos *et al.*, 1997; Inada *et al.*, 1999; Kim *et al.*, 1999; Enomoto *et al.*, 2000; Takeda *et al.*, 2001; Ueta *et al.*, 2001; Lee and Zhou, 2004). CBFA1 is encoded by the *RUNX2* gene (GeneBank#AF001450; previously earlier synonyms are PEBP2A1 and AML3), located on chromosome 6p21.

Forty-six different human mutations of the *RUNX2* gene have been described in the literature, including familial and sporadic cases (Otto *et al.*, 2002; Lo Muzio *et al.*, 2007). Genotype–phenotype correlation is not clear; according to some authors, skeletal growth and dental development could be related to the type of changes in the *RUNX2* gene (Zhou *et al.*, 1999; Yoshida *et al.*, 2002), while others found no phenotypical difference between patients, and reported that the observed variability is within the spectrum of the gene (Quack *et al.*, 1999; Golan *et al.*, 2002).

The genetic basis of CCD was found when Lee *et al.* (1997) and Mundlos *et al.* (1997) identified a microdeletion of the short arm of chromosome 6p21, within a region containing *CBFA1*, the master gene whose protein product is known to be involved in early prenatal osteogenesis and

bone remodelling. Previous studies on mice had highlighted a possible role of the different transcription factors belonging to Runt family in skeletal development. In particular, *RUNX2* seemed to act as potent inducer of the late stages of chondrocyte and osteoblast differentiation (Lee *et al.*, 1997; Mundlos *et al.*, 1997; Inada *et al.*, 1999; Kim *et al.*, 1999; Enomoto *et al.*, 2000; Takeda *et al.*, 2001; Ueta *et al.*, 2001; Lee and Zhou, 2004), with important functions in human endochondral ossification (Zheng *et al.*, 2005). Further genetic screening of human ortholog gene, *RUNX2*, revealed heterozygous mutations associated with CCD.

The aim of this presentation is to report the molecular characterization of a novel *RUNX2* gene mutation in an Italian family showing a typical CCD phenotype, which emphasizes the contribution of a novel altered splicing mechanism to the aetiology of this disease.

Subjects and methods

The index case was a 27-year-old female patient referred for treatment to the Ortognatodonzia Service of 'San Giovanni Battista' Hospital, Torino, Italy. Treatment was directed to orthodontic traction of the impacted teeth visible on a Panorex (Figure 1A) and a three-dimensional computed tomography (Figure 1B).

Intra and extraoral appearance was suggestive of CCD: a large number of unerupted teeth, a brachycephal aspect of the face, sloping shoulders, and a short and broad body build. CCD was confirmed by a chest radiograph showing clavicular hypoplasia (Figure 1C) and by a familial history of CCD in the 54-year-old mother and the 24-year-old sister, both radiographically examined to confirm the diagnosis. All three patients were referred to the Medical Genetics Service of IRCCS 'Casa Sollievo della Sofferenza' Hospital for *RUNX2* gene analysis.

After written informed consent, peripheral blood was collected from the three patients. DNA was extracted from lymphocyte using a standard phenol–chloroform protocol (Sambrook *et al.*, 1989) and a mutation in the *RUNX2* gene was performed. Polymerase chain reaction (PCR) amplifications for all seven *RUNX2* coding regions, including the exon–intron boundaries, in all subjects were established as previously described by Mundlos *et al.* (1997). Amplifications were carried out in 25 µl reaction volume containing 2.5 µl 10× PCR buffer (Applied Biosystems, Foster City, California, USA), 0.25 mM/ l deoxynucleoside-3-phosphates, 20 pmol of each primer, 1 U AmpliTaq Gold DNA polymerase (Applied Biosystems), and 100 ng of DNA. Cycling conditions consisted of an initial 12 minutes denaturation at 95°C, followed by 35 cycles at 95°C for 30 seconds, annealing at 60°C for 30 seconds, and extension at 72°C for 30 seconds, with final extension at 72°C for 7 minutes. PCR products were visualized by ethidium bromide staining on 2 per cent agarose gel, purified using the GFX PCR and Band

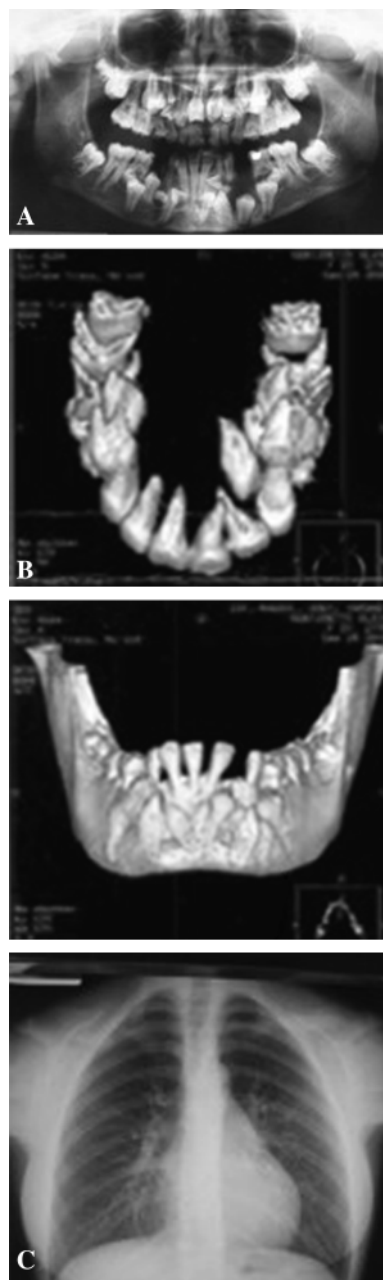


Figure 1 (A) Panorex radiograph. (B) Three-dimensional computed tomographic reconstruction. (C) Chest radiograph of the index case.

Purification Kit (GE Healthcare, Amersham, Buckinghamshire, UK) and then sequenced using the BigDye Terminator Cycle Sequencing Kit v.1.1 (Applied Biosystems). Sequencing reactions were loaded on ABI 3100 capillaries (Applied Biosystems) and analysed using the Sequencing Analysis software v2.0 (Applied Biosystems).

Whole blood RNA was collected in a PAXgene RNA tube (PreAnalytix; Qiagen Sciences, Germantown, Maryland, USA) and extracted using the corresponding RNA purification kit (PAXgene Blood RNA kit, PreAnalytix;

Qiagen) following the manufacturer's instructions. Complementary DNA (cDNA) synthesis was performed with the QuantiTect Reverse Transcription Kit (Qiagen) according to the manufacturer's instructions and the reverse transcription (RT)-PCR was performed using the following primers: forward 5'-ACAACCGCACCATGGTGGAGAT-3' and reverse 5'-AGAGAACAACCTAGGTTTAGAGTC-3', located in exons 1 and 4, respectively, with a PCR product of 437 bp. The RT-PCR products were purified and sequenced using the PCR forward primers.

Results

Sequence analysis of the *RUNX2* gene revealed, in the index case, a heterozygotic nucleotide change, not previously detected, in the intron 2 (Figure 2A and 2B) described as c.580 + 1G > A and consisting of a transition G > A of the first base of the splicing acceptor site. The presence of mutation was also investigated in the other two affected family members, the mother and the sister (Figure 2A).

Falling into the splicing donor site of intron 2, the *RUNX2* c.580 + 1G > A mutation suggested a possible interference with messenger RNA (mRNA) splicing. The *RUNX2* mRNA extracted from the blood cells of the index case was analysed. The variation was shown to alter splicing of the *RUNX2* mRNA since sequencing of the RT-PCR product obtained from the *RUNX2* cDNA of the index case (Figure 3A) revealed the complete exclusion of the exon 2 and the junction of exon 1 to exon 3 (Figure 3B and 3C) leading to a premature predicted stop codon at position 184.

Discussion

A novel splicing mutation of the *RUNX2* gene, affecting the donor site of intron 2 and leading to the complete skipping

of exon 2 is reported. The final outcome of this aberrant splicing process is the expected truncation of the *RUNX2* protein of 323 amino acids. This genomic variation represents a classic example of splicing errors, described as a frequent molecular cause of several human disease phenotypes (Kim *et al.*, 1999; Enomoto *et al.*, 2000) and stresses the importance of carefully examining all point mutations, deletions, and splicing site substitutions including intronic ones to determine whether they may activate a canonical/noncanonical cryptic splice site. Mutations resulting in exon skipping account for 15–20 per cent of mutations leading to human disease (Takeda *et al.*, 2001) and, therefore, cDNA analysis is essential for full evaluation of the effect of putative splicing mutations, as well as of nucleotide changes close to the exon/intron boundaries in the *RUNX2* gene.

CCD is a severe rare bone disorder characterized by skeletal system malformations due to an abnormal osteoblast differentiation and chondrocyte maturation (Lee *et al.*, 1997; Mundlos *et al.*, 1997; Inada *et al.*, 1999; Kim *et al.*, 1999; Enomoto *et al.*, 2000; Takeda *et al.*, 2001; Ueta *et al.*, 2001; Lee and Zhou, 2004). While the primary dentition seems to develop normally, the permanent dentition presents an evident delay in eruption with ectopia, malformations mostly involving the roots and supernumerary teeth (Jensen and Kreiborg, 1990; Richardson and Deussen, 1994). According to Jensen and Kreiborg (1990), the greatest frequency of supernumerary teeth (22 per cent) is observed in the maxillary incisor region and the lowest in the molar region (5 per cent for upper and lower jaws).

These defects are caused by derangement of ossification and bone resorption, which, although affecting the entire skeleton, tend to express themselves most strongly in bones ossifying in membrane. The extreme delay or arrest of physiologic root resorption and exfoliation of the primary

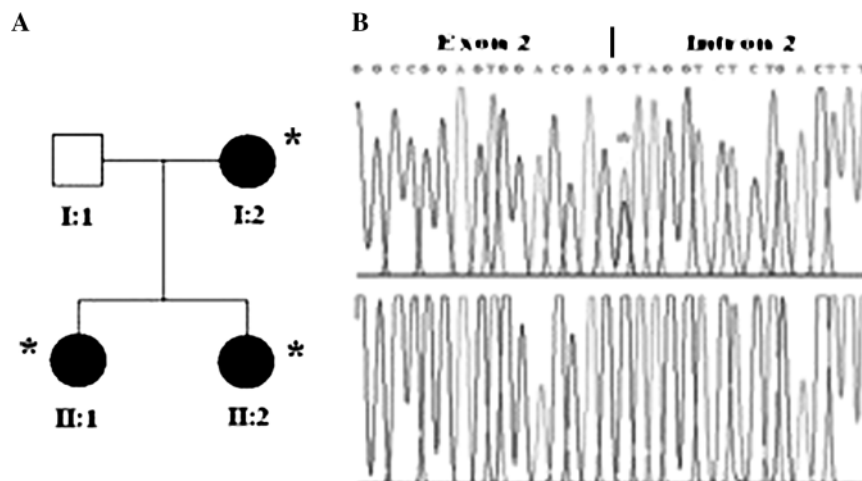


Figure 2 (A) Pedigree of the family: Filled circles, affected, subjects I:two mother, II:one index case, and II:two sister; open square, I:one unaffected father and asterisk indicates the presence of the mutation. (B) Sequencing profile of normal (bottom) and mutated (top) DNA, showing the c.580 + 1G > A mutation.

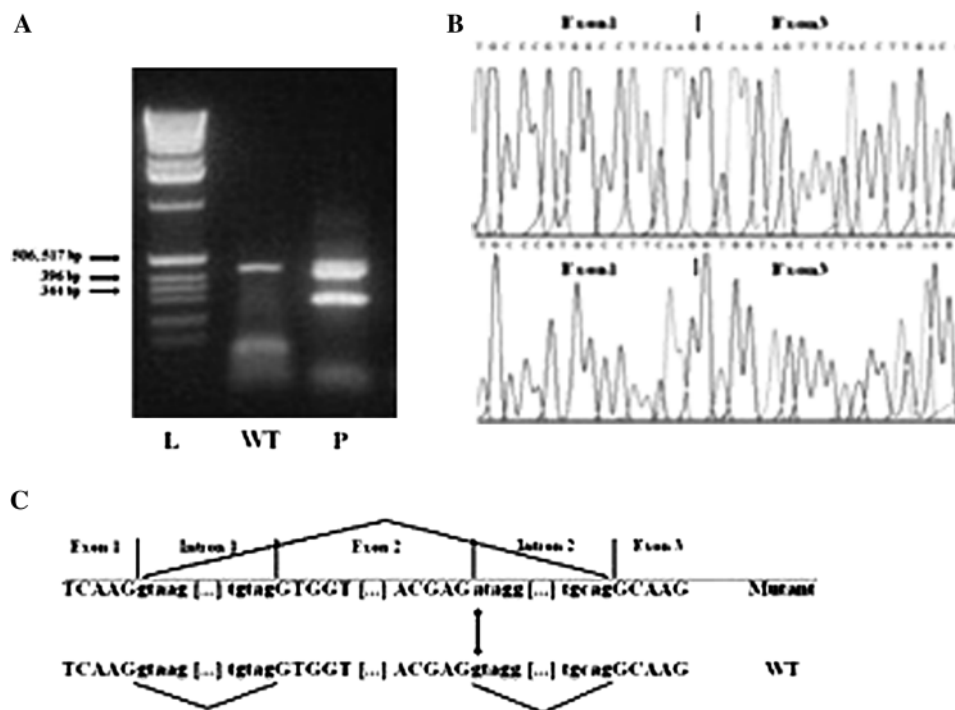


Figure 3 (A) Gel picture of the reverse transcription polymerase chain reaction of the mutated complementary (cDNA) from the index case indicating the loss of 157 bp from the total amplicon of 437 bp. L, ladder; P, probands (index case); WT, wild-type control cDNA. (B) Sequencing profile of normal (bottom) and mutated (top) cDNA, showing skipping of the exon 2. (C) Diagram showing fusion of exon 1 to exon 3.

teeth are probably related to the generalized reduced bone resorption observed in the jaws of CCD subjects (Kreiborg *et al.*, 1981). The formation of supernumerary teeth can be explained by incomplete or severely delayed resorption of the dental lamina, which is then reactivated at the time of crown completion of the normal permanent teeth. This hypothesis has previously been suggested (Hitchin and Fairley, 1974; Migliorisi and Blenkinsopp, 1980).

Conclusions

A molecular genetic screening programme would be helpful in the management of CCD patients. The dentist has a key role in identifying CCD patients and arranging a mutation search by a genetic counselling.

Acknowledgement

We acknowledge the assistance of the family who participated in this study.

References

- Calabrese B 1974 Disostosi cleido-cranica in padre e figlio. *La Clinica Ortopedica* 25: 127–130
- Chitayat D, Hodgkinson K A, Azouz E M 1992 Intrafamilial variability in cleidocranial dysplasia: a three generation family. *American Journal of Medical Genetics* 42: 298–303

- De Giorgi G 1971 Sulla etio-patogenesi della displasia cleido-cranica. *La Chirurgia degli Organi di Movimento* 60: 97–103
- Enomoto H *et al.* 2000 Cbfa1 is a positive regulatory factor in chondrocyte maturation. *The Journal of Biological Chemistry* 275: 8695–8702
- Golan I *et al.* 2002 Evidence of intrafamilial variability of CBFA1/RUNX2 expression in cleidocranial dysplasia—a family study. *Journal of Orofacial Orthopedics* 3: 190–198
- Gorlin R J, Cohen M M, Levin L S 1990 Syndromes affecting bone: other skeletal disorders. In: *Syndromes of the head and the neck*, 3rd edn. Oxford University Press, Oxford, pp. 249–253.
- Gorlin R J, Goldman H M (eds) 1977 Thoma's oral pathology, 2nd edn. C.V. Mosby Company, St Louis
- Hitchin A D, Fairley J M 1974 Dental management in cleido-cranial dysostosis. *British Journal of Oral Surgery* 12: 46–55
- Inada M *et al.* 1999 Maturation disturbance of chondrocytes in Cbfa1-deficient mice. *Developmental Dynamics* 214: 279–290
- Jensen B L 1990 Somatic development in cleidocranial dysplasia. *American Journal of Medical Genetics* 35: 69–74
- Jensen B L, Kreiborg S 1990 Development of the dentition in cleidocranial dysplasia. *Journal of Oral Pathology & Medicine* 19: 89–93
- Kim I S, Otto F, Zabel B, Mundlos S 1999 Regulation of chondrocyte differentiation by Cbfa1. *Mechanisms of Development* 80: 159–170
- Kreiborg S, Jensen B L, Björk A, Skieller V 1981 Abnormalities of the cranial base in cleidocranial dysostosis. *American Journal of Orthodontics* 79: 549–557
- Lee B, Zhou G 2004 RUNX2 and cleidocranial dysplasia. In: Epstein C J, Erickson R P, Wynshaw-Boris A (eds). *Inborn errors of development* Oxford University Press, New York, pp. 331–339
- Lee B *et al.* 1997 Missense mutations abolishing DNA binding of the osteoblast-specific transcription factor OSF2/CBFA1 in cleidocranial dysplasia. *Nature Genetics* 16: 307–310

- Lo Muzio L *et al.* 2007 A novel mutation of gene CBFA1/RUNX2 in cleidocranial dysplasia. *Annals of Clinical and Laboratory Sciences* 37: 115–120
- Migliorisi J A, Blenkinsopp P T 1980 Oral surgical management of cleidocranial dysostosis. *British Journal of Oral Surgery* 18: 212–220
- Mundlos S *et al.* 1997 Mutations involving the transcription factor CBFA1 cause cleidocranial dysplasia. *Cell* 89: 773–779
- Otto F, Kanegane H, Mundlos S 2002 Mutations in the RUNX2 gene in patients with cleidocranial dysplasia. *Human Mutation* 19: 209–216
- Quack I, Vonderstrass B, Stock M 1999 Mutation analysis of core binding factor A1 in patients with cleidocranial dysplasia. *American Journal of Human Genetics* 65: 1268–1278
- Richardson A, Deussen F F 1994 Facial and dental anomalies in cleidocranial dysplasia: a study of 17 cases. *International Journal of Paediatric Dentistry* 4: 225–231
- Sambrook J, Fritsch E F, Maniatis T 1989 Molecular cloning: a laboratory manual, 2nd edn. Cold Spring Harbor Laboratory, Cold Spring Harbor
- Spranger J 1974 Cleidocranial dysplasia. In: Spranger J, Langer L O, Wiedemann H R (eds). *Bone dysplasias* Fischer Verlag, Stuttgart, p. 254
- Takeda S, Bonnamy J P, Owen M J, Ducy P, Karsenty G 2001 Continuous expression of Cbfa1 in nonhypertrophic chondrocytes uncovers its ability to induce hypertrophic chondrocyte differentiation and partially rescues Cbfa1-deficient mice. *Genes & Development* 15: 467–481
- Ueta C *et al.* 2001 Skeletal malformations caused by overexpression of Cbfl or its dominant negative form in chondrocytes. *The Journal of Cell Biology* 153: 87–100
- Yoshida T *et al.* 2002 Functional analysis of RUNX2 mutations in Japanese patients with cleidocranial dysplasia demonstrates novel genotype-phenotype correlations. *American Journal of Human Genetics* 71: 724–738
- Zheng Q *et al.* 2005 Dysregulation of chondrogenesis in human cleidocranial dysplasia. *American Journal of Human Genetics* 77: 305–312
- Zhou G *et al.* 1999 CBFA1 mutation analysis and functional correlations with phenotypic variability in cleidocranial dysplasia. *Human Molecular Genetics* 8: 2311–2316

Copyright of European Journal of Orthodontics is the property of Oxford University Press / UK and its content may not be copied or emailed to multiple sites or posted to a listserv without the copyright holder's express written permission. However, users may print, download, or email articles for individual use.