

# Relationship between dental anomalies and orthodontic root resorption of upper incisors

Katrien Van Parys\*, Irene H.A. Aartman\*\*, Reinder Kuitert\* and Andrej Zentner\*

Departments of \*Orthodontics and \*\*Social Dentistry and Behavioural Sciences, Academic Centre for Dentistry Amsterdam, University of Amsterdam and VU University Amsterdam, The Netherlands

*Correspondence to:* Irene H. A. Aartman, Department of Social Dentistry and Behavioural Sciences, Academic Centre for Dentistry Amsterdam, Gustav Mahlerlaan 3004, 1081 LA Amsterdam, The Netherlands.  
E-mail: I.Aartman@acta.nl

**SUMMARY** The aim of this study was to examine the potential relationship between the occurrence of orthodontic root resorption and presence of dental anomalies such as tooth agenesis and pipette-shaped roots. Dental anomalies and root resorption were assessed on dental panoramic tomographs (DPT) of 88 subjects, 27 males and 61 females, mean age 28.4 (SD = 11.3 years), selected from orthodontic patients on the basis of the following exclusion criteria: previous fixed appliance treatment, bad quality of the DPTs and no visibility of the periodontal ligament of every tooth, and younger than 15 years of age at the onset of treatment with fixed edgewise appliance lasting at least 18 months. A pipette-shaped root was identified as defined by a drawing. Tooth agenesis was assessed on DPTs and from subjects' dental history. Root resorption was calculated as the difference between the root length before and after treatment, with and without a correction factor (crown length post-treatment/crown length pre-treatment). If one of the four upper incisors showed root resorption of  $\geq 2.3$  mm with both formulas, the patient was scored as having root resorption. Chi-square tests indicated that there was no relationship between orthodontic root resorption and agenesis ( $P = 0.885$ ) nor between orthodontic root resorption and pipette-shaped roots ( $P = 0.800$ ). There was no relationship between having one of the anomalies and root resorption either ( $P = 0.750$ ). In the present study, it was not possible to confirm on DPTs a relationship between orthodontic root resorption and dental anomalies, such as agenesis and pipette-shaped roots.

## Introduction

Several studies have addressed the potential relationship between the occurrence of root resorption during orthodontic treatment and abnormal dental morphology such as agenesis, pipette-shaped, blunt, pointed, short, long, dilacerated, and narrow roots, small and peg-shaped lateral incisors, invagination, and taurodontism (Lind, 1972; Levander and Malmgren, 1988; Kjær, 1995; Mirabella and Årtun, 1995; Thongudomporn and Freer, 1998; Lee *et al.*, 1999; Sameshima and Sinclair, 2001; Kook *et al.*, 2003; Sameshima and Sinclair, 2004; Mavragani *et al.*, 2006). Some investigations confirmed a relationship while others did not.

Studying this matter revealed a few difficulties. For example, Mirabella and Årtun (1995) defined various anomalies by the term 'abnormal root shape' without specifying the anomalies. Sameshima and Sinclair (2001) used only the terms normal, blunted, pipette or bottle-shaped, pointed, dilacerated, and incomplete root shape without referring to a definition. Thus, the definitions of dental anomalies and root resorption vary (Lind, 1972; Kjær, 1995; Mirabella and Årtun, 1995; Thongudomporn and Freer, 1998; Sameshima and Sinclair, 2001). Next, Kjær (1995) reported only the prevalence of anomalies in a group of patients with root resorption.

Other studies did not confirm a relationship between root resorption and dental anomalies. Lee *et al.* (1999) compared two matched groups: one consisting of 84 patients with the presence of at least one dental anomaly (in which 79 per cent was <18 years of age and 21 per cent was >18 years of age) and 1 of 84 patients without such an anomaly (in which 74 per cent was <18 years of age and 26 per cent was >18 years of age). A two sample *t*-test revealed no difference in mean root resorption between the patients in the two groups ( $P = 0.88$ ). Kook *et al.* (2003) showed by means of stepwise linear regression analysis that peg-shaped and small laterals were not at higher risk for root resorption. Finally, Mavragani *et al.* (2006) concluded that dental invagination is not a risk factor for orthodontic apical root resorption. The authors compared 49 orthodontic patients with at least 1 maxillary incisor invagination with 42 patients who were free of dental invaginations.

Although the assessment of various anomalies has been conducted in a number of studies, the reliability of the assessment of these anomalies has rarely been investigated. In an earlier study, a poor interexaminer and intraexaminer reliability of the assessment of dilacerated, blunt, pointed, and short roots on dental panoramic tomographs (DPTs) was reported (Van Parys *et al.*, 2010). Only intraexaminer reliability of the assessments of pipette-shaped roots of two

examiners was good and interexaminer and intraexaminer reliability of agenesis was excellent. On the basis of these findings, it was decided to exclude dilacerated, blunt, pointed, and short roots from the present investigation of the potential relationship between abnormal dental morphology and orthodontic root resorption. Therefore, the aim of this study was to determine the relationship between orthodontic root resorption on one hand and the presence of tooth agenesis and pipette-shaped roots on the other, as identified on DPTs.

## Materials and methods

### Sample

The study subjects (27 males and 61 females) were selected from patients of the Department of Orthodontics, Academic Centre for Dentistry Amsterdam, treated between 1984 and 2008. All subjects were treated with fixed edgewise appliances and had to be 15 years or older to enable the diagnosis of congenitally absent teeth and to ensure complete root formation of all teeth with the exception of third molars, resulting in a group of 607 patients. To start, a group of 40 patients, with the same exclusion criteria, was selected for a previous study (Van Parys *et al.*, 2010). Next, a random selection took place until 88 patients were included. In both studies, patient files were excluded based on the following criteria: 1. previous fixed appliance treatment, 2. jaw surgery, 3. poor quality of the DPT and no visibility of the periodontal ligament of every tooth, 4. developmental anomalies such as syndromes or clefts, 5. treatment duration <18 months, and 6. anterior restorations performed between the pre- and post-orthodontic DPT recordings. The mean age at the onset of treatment of the study was  $28.4 \pm 11.3$  years (range 15.0–55.4 years).

### Methods

The selection and definitions of the anomalies were based on the relevant literature. As discussed above, the morphological dental anomalies suggested to be related to excessive orthodontic root resorption are tooth agenesis, dilacerated, pipette-shaped, blunt, pointed, and short roots. As the results of a previous investigation (Van Parys *et al.*, 2010) suggested that most of the anomalies cannot be reliably assessed on DPTs, only agenesis and pipette-shaped roots were investigated in this study. These anomalies were assessed on all teeth as follows.

**Agenesis.** Agenesis of central and lateral incisors, canines, first and second premolars, and first, second, and third molars was diagnosed using DPTs. Subsequently, agenesis was confirmed by longitudinal patient records without history of extraction of that particular tooth and was scored as 1. When the tooth was present or extracted, score 0 was given. When a patient showed an agenesis on at least one tooth, the patient was designated as having an agenesis.

**Pipette-shaped roots.** A pipette-shaped root was defined as drawn by Levander and Malmgren (1988) (Figure 1) and was scored on all teeth except third molars. When the radiographic appearance of the root of the tooth was similar to the drawing, it was scored as 1; in all other cases, it was scored as 0. When a patient showed a pipette-shaped root on at least one tooth, the patient was scored as having a pipette-shaped root.

Root resorption was assessed on four upper incisors implying a combination of two formulas.

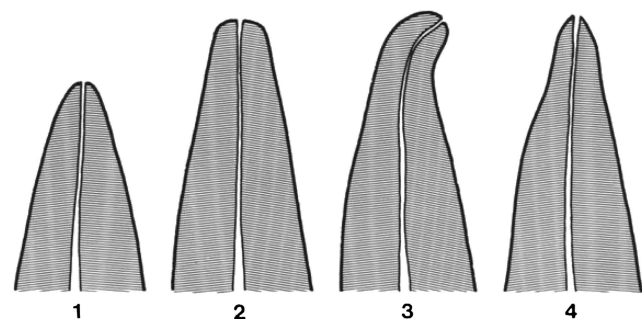
$$\text{Root length T1} \times \text{crown length T2/crown length T1} - \text{root length T2 (1)}$$

$$\text{Root length T1} - \text{root length T2 (2)}$$

where T1 = pre-treatment and T2 = post-treatment.

Root length was defined as the distance between the most apical point of the root and the midpoint of the most apical and proximal points of the cemento-enamel junction (CEJ). Crown length was defined as the distance between the midpoint of the most apical and proximal points of the CEJ and the middle of the largest mesio-distal distance of the crown, projected on the incisal/occlusal edge. One examiner assessed the root length and the crown length of all the teeth of the 88 patients twice with a washout period of at least 2 weeks. The mean of these two measurements was used in the formula when measuring the amount of root resorption. The intraexaminer reliability was assessed using the intraclass correlation coefficient (ICC).

However, in assessment of root resorption with the first formula (including the correction factor), it appeared that approximately 30 per cent of the roots elongated during orthodontic treatment. For this reason, a second formula, without correction factor, was also used for measuring root resorption. According to the meta-analysis by Segal *et al.* (2004), the mean root resorption in eight studies was  $1.421 \pm 0.448$  mm. Therefore, taking into account 2 SDs, a patient was scored as having root resorption when one of the four upper incisors scored  $\geq 2.3$  mm in both formulas.



**Figure 1** Deviating root forms [after Levander and Malmgren (1988)]. 1, short root; 2, blunt root; 3, root with apical bend; and 4, root with apical pipette shape.

### Statistical analysis

Chi-square tests were used to assess the relationship between root resorption and agenesis and between root resorption and pipette-shaped roots. For analysis, the Statistical Package for Social Sciences Windows, version 15.0 (SPSS Inc., Chicago, Illinois, USA) was used.

### Results

The intraexaminer reliability of the two measurements of root length and crown length, both pre- and post-treatment, is shown in Table 1. The ICCs varied between 0.87 and 0.98. The assessments of root length and crown length were reliable. The results concerning the relationship are shown in Tables 2 and 3. Chi-square tests suggested that there was no relationship between root resorption and agenesis ( $\chi^2 = 0.021$ ,  $df = 1$ ,  $P = 0.885$ ) nor between root resorption and pipette-shaped roots ( $\chi^2 = 0.064$ ,  $df = 1$ ,  $P = 0.800$ ). None of the patients showed both anomalies. There was no relationship between having at least one of the anomalies and root resorption either ( $\chi^2 = 0.102$ ,  $df = 1$ ,  $P = 0.750$ ).

**Table 1** Intraclass correlation coefficients of root length and crown length, pre- (T1) and post-treatment (T2).

Tooth number	12	11	21	22
Root length, T1	0.91	0.92	0.95	0.94
Crown length, T1	0.87	0.92	0.94	0.89
Root length, T2	0.97	0.98	0.98	0.97
Crown length, T2	0.89	0.94	0.94	0.90

**Table 2** Number of patients with and without root resorption in relation to agenesis.

	Agenesis present ( <i>n</i> )	Agenesis absent ( <i>n</i> )	
Root resorption present ( <i>n</i> )	6	33	39
Root resorption absent ( <i>n</i> )	7	42	49
	13	75	88

$P > 0.05$ .

**Table 3** Number of patients with and without root resorption in relation to pipette-shaped roots.

	Pipette-shaped root present ( <i>n</i> )	Pipette-shaped root absent ( <i>n</i> )	
Root resorption present ( <i>n</i> )	8	31	39
Root resorption absent ( <i>n</i> )	9	40	49
	17	71	88

$P > 0.05$ .

### Discussion

The results of this study showed that there was no relationship between root resorption after orthodontic treatment with full fixed edgewise appliance and the dental anomalies agenesis and pipette-shaped roots in the study subjects. This finding is in line with some studies but in disagreement with others. A number of explanations will be given.

Firstly, the ages of the patients in which the amount of root resorption is assessed vary across studies. In the present study, patients had to be 15 years or older, but for example, in the study of Kjær (1995) younger patients were included. Next, in other studies, the variation and number of anomalies incorporated were higher (Kjær, 1995; Mirabella and Årtun, 1995; Thongudomporn and Freer, 1998; Lee *et al.*, 1999; Sameshima and Sinclair, 2001), or the prevalence of the anomalies was not the same in the patients selected for the study (e.g. Thongudomporn and Freer, 1998). Unfortunately, in the present study, the prevalence of pipette-shaped roots was too low to assess whether a relationship was present between pipette-shape roots and root resorption on the same tooth.

Indeed, a shortcoming of this study in general is the low prevalence of patients with an anomaly (13 of the 88 patients with agenesis and 17 of the 88 patients with pipette-shaped roots). However, since there is not even a tendency to a relationship between root resorption and an anomaly, it is doubtful that a relationship would have been found when the prevalences were higher.

Most studies used different methods to measure root resorption, such as drawings and various kinds of calculations (Levander and Malmgren, 1988; Lupi *et al.*, 1996; Lee *et al.*, 1999; Sameshima and Sinclair, 2001). For example, Levander and Malmgren (1988), Thongudomporn and Freer (1998), and Sameshima and Sinclair (2001) used drawings with a visual scale to assess root resorption and found that the degree of root resorption in teeth with pipette-shaped roots was higher than in those with normal root appearance.

With respect to intraexaminer reliability of the assessment of root resorption, Thongudomporn and Freer (1998) graded it as acceptable (87.9 per cent agreement) and Levander and Malmgren (1988) as 'good'. As shown in Table 1, the reliability of the measurements of root resorption in the present study was satisfactory. However, comparison of calculations using the formulas with and without the correction factor resulted in different values (Tables 4 and 5). The proportion of study subjects with calculated tooth elongation was lower without the correction factor. In addition, the lack of validity of DPTs in assessing root resorption is also illustrated by the improbable albeit apparent root length increase. Also Sameshima and Sinclair (2001) reported root elongation. They reported the same results as this study when comparing formulas with and

**Table 4** Root resorption per upper incisor (root length T1  $\times$  crown length T2/crown length T1 – root length T2).

	Root resorption 12	Root resorption 11	Root resorption 21	Root resorption 22
N, valid	82	86	86	77
N, missing	6	2	2	11
Mean (mm)	0.8	0.7	1.2	1.2
SD (mm)	2.3	2.3	2.3	2.3
Minimum (=root elongation; mm)	-5.2	-4.7	-4.2	-4.5
Maximum (=root resorption; mm)	6.6	7.6	7.4	8.3
Percentage of subjects with elongation	37.8	36.0	33.7	24.7

**Table 5** Root resorption per upper incisor (root length T1 – root length T2).

	Root resorption 12	Root resorption 11	Root resorption 21	Root resorption 22
N, valid	82	86	86	77
N, missing	6	2	2	11
Mean (mm)	1.8	1.8	2.1	2.0
SD (mm)	1.9	2.5	2.5	1.9
Minimum (=root elongation; mm)	-2.5	-5.7	-4.8	-1.8
Maximum (=root resorption; mm)	6.0	10.2	10.7	7.2
Percentage of subjects with elongation	11.0	19.8	14.0	16.9

without a correction factor: the formula without the correction factor resulted in less observed root resorption and less variance. They suggested that errors in accurately finding endpoints of the line defining the CEJ might account for the decreased precision. The elongation of 30 per cent of the teeth in the present study may be explained by this measurement error. On the other hand, a correction factor seems to be necessary because of the possible different magnification factors used, the different positions of the patient, and the different techniques used. Thus, not only a previous study casted doubt on the validity of the method used for measuring root resorption on DPTs but the results of the present study suggest the same.

Although panoramic and cephalometric records are the routinely made orthodontic pre-treatment radiographs, they show a number of artefacts, and it appears that the exclusion criterion 'bad quality of the DPT and no visibility of the periodontal ligament of every tooth' as used in the present investigation was not sufficient. A three-dimensional process such as root resorption seems not completely assessable on two-dimensional images. A cone-beam

computed tomography (CBCT) could be more useful in this matter. It seems that, when measured on DPT's, root resorption is underestimated in comparison with CBCT (Dudic *et al.* 2009).

## Conclusions

In the present study, it was not possible to confirm a relationship between root resorption and the dental anomalies agenesis and pipette-shaped roots. It remains unclear whether this is due to an absence of a relationship or to the limitations of the present study. Future studies should first focus on developing a valid and reliable measurement method of root resorption.

## References

- Dudic A, Giannopoulou C, Leuzinger M, Kiliaridis S 2009 Detection of apical root resorption after orthodontic treatment by using panoramic radiography and cone-beam computed tomography of super-high resolution. *American Journal of Orthodontics and Dentofacial Orthopedics* 135: 434–437
- Kjær I 1995 Morphological characteristics of dentitions developing excessive root resorption during orthodontic treatment. *European Journal of Orthodontics* 16: 25–34
- Kook Y A, Park S, Sameshima G T 2003 Peg-shaped and small lateral incisors not at higher risk for root resorption. *American Journal of Orthodontics and Dentofacial Orthopedics* 123: 253–258
- Lee R Y, Årtun J, Alonzo T A 1999 Are dental anomalies risk factors for apical root resorption in orthodontic patients? *American Journal of Orthodontics and Dentofacial Orthopedics* 116: 187–195
- Levander E, Malmgren O 1988 Evaluation of the risk of root resorption during orthodontic treatment: a study of the upper incisors. *European Journal of Orthodontics* 10: 30–38
- Lind V 1972 Short root anomaly. *Scandinavian Journal of Dental research* 80: 85–93
- Lupi J E, Handelman C S, Sadowsky C 1996 Prevalence and severity of apical root resorption and alveolar bone loss in orthodontically treated adults. *American Journal of Orthodontics and Dentofacial Orthopedics* 109: 28–37
- Mavragani M, Apisariyakul J, Brudvik P, Selvig K A 2006 Is mild dental invagination a risk factor for apical root resorption in orthodontic patients? *European Journal of Orthodontics* 28: 307–312
- Mirabella A D, Årtun J 1995 Risk factors for apical root resorption of maxillary anterior teeth in adult orthodontic patients. *American Journal of Orthodontics and Dentofacial Orthopedics* 108: 48–55
- Sameshima G T, Sinclair P M 2001 Predicting and preventing root resorption: part I. Diagnostic factors. *American Journal of Orthodontics and Dentofacial Orthopedics* 119: 505–510
- Sameshima G T, Sinclair P M 2004 Characteristics of patients with severe root resorption. *Orthodontics and Craniofacial Research* 7: 108–114
- Segal G R, Schiffman P H, Tuncay O C 2004 Meta analysis of the treatment-related factors of external apical root resorption. *Orthodontics and Craniofacial Research* 7: 71–78
- Thongudomporn U, Freer T J 1998 Anomalous dental morphology and root resorption during orthodontic treatment: a pilot study. *Australian Orthodontic Journal* 15: 162–167
- Van Parys K, Aartman I H A, Kuitert R, Zentner A 2010 Assessment of dental anomalies on panoramic radiographs: inter- and intra-examiner agreement. *European Journal of Orthodontics* Aug 26 [Epub ahead of print] doi:10.1093/ejo/cjq061

Copyright of European Journal of Orthodontics is the property of Oxford University Press / USA and its content may not be copied or emailed to multiple sites or posted to a listserv without the copyright holder's express written permission. However, users may print, download, or email articles for individual use.