

# Posterior crossbite and temporomandibular disorders (TMDs): need for orthodontic treatment?

Birgit Thilander\* and Krister Bjerklín\*\*

\*Department of Orthodontics, Institute of Odontology, The Sahlgrenska Academy, University of Gothenburg and

\*\*Department of Orthodontics, The Institute for Postgraduate Dental Education, Jönköping, Sweden

*Correspondence to:* Birgit Thilander, Department of Orthodontics, Institute of Odontology, The Sahlgrenska Academy, University of Gothenburg, Medicinaregatan 12, Box 450, SE 40530 Gothenburg, Sweden.

E-mail: birgit.thilander@odontologi.gu.se

**SUMMARY** The aim of this work was to update the bibliography regarding the concept of ‘temporomandibular disorder (TMD)’ and ‘posterior crossbite’ and try to find out if there is any association between some special signs/symptoms of TMD and type of posterior crossbite. A literature search from 1970 to 2009, due to specified criterion, resulted in 14 publications that were found to be relevant for the present systematic review. An association between TMD and posterior crossbite (Yes-group) was reported as often as absence of such a relationship (No-group). The samples in the two groups showed similarities as well as differences with respect to number, gender, and age. Most articles reported only on ‘presence’ or ‘absence’ of crossbite and only few on type of crossbite opposite to a thorough account of clinical signs and symptoms of TMD. This review seems, however, to state that a functional posterior crossbite (mandibular guidance with midline deviation) is associated with headache, temporomandibular joint and muscular pain, and clicking. As evident from the discussion, such type needs orthodontic treatment to rehabilitate the asymmetric muscular activity between the crossbite and non-crossbite sides and the changed condyle/temporal relationship caused by mandibular deviation. Whether this treatment also will avoid future TMD problems can be answered only after clinical follow-up studies have been performed.

## Introduction

A desire for aesthetic improvement of dental anomalies is the main reason for orthodontic treatment. Besides those aesthetic–psychological motives, there is a need for treatment of some malocclusions on prophylactic reasons, as for instance proclined maxillary incisors to avoid trauma. Moreover, any association between temporomandibular disorders (TMDs) and some malocclusions (e.g. posterior crossbite) should indicate need of orthodontic treatment to avoid future problems in joints and masticatory muscles.

As evident from previous reviews (Seligman and Pullinger, 1991; Dibbets *et al.*, 1993; Vanderas, 1993; McNamara *et al.*, 1995; Luther 1998), different opinions have been presented about an association between posterior crossbite and TMD, varying between ‘yes it is’, ‘no it is not’, and ‘maybe it is’. Differences as regards selection of subjects (age and number) and methods (examination or questionnaire) together with different and vague definitions of ‘TMD’ and ‘crossbite’ may account for these controversial opinions.

Many publications during the last 50 year period give a vague impression as regards the ‘concept of TMD’ as summarized by the American Academy of Orofacial Pain (de Leeuw, 2008). The original terminology ‘Costen syndrome’ [an isolated group of symptoms around the ear and temporomandibular joints (TMJs)] was changed to ‘TMJ dysfunction syndrome’ as well as ‘functional TMJ disturbances’. Because the symptoms are not restricted to the

joints, those terms were considered to be too limited and that a broader term should be used, such as CMD (cranio-mandibular) or TMD (temporomandibular) or MPD (myofacial pain). The abbreviation D stands for either ‘dysfunction’ or ‘disorder’.

Anyhow, TMD is a generic term for a number of clinical signs and symptoms involving the masticatory muscles, the TMJs, and associated structures. Epidemiological studies have reported that functional disturbances of the masticatory system are common, usually of mild character, seem to exhibit a female preponderance, and seem to increase with age. Clinical signs (clicking, disk displacement, and tenderness of masticatory muscles on palpation) and symptoms (especially headache) are frequently reported, and significant associations exist between different signs. An uncertain relationship between signs and symptoms has been questioned as the subjects’ complaints might be seen as unreliable especially in children. Furthermore, difficulty exists in defining signs and symptoms qualitatively. Differences in degree between mild, moderate, and severe signs are very difficult to estimate, especially as regards symptoms.

Finally, the terms dysfunction and ‘parafunction’ (clenching, grinding, and dental wear) are often confused. Strictly defined dysfunction is a partial disturbance, impairment, or abnormality of the functioning of an organ, whereas parafunction is a disordered or perverted function, which can cause a dysfunction. This situation is made even more

confusing by the fact that parafunctions are sometimes included in subjective symptoms and sometimes as clinical signs.

Thus, we agree with Luther (1998) in his critical review on orthodontics and TMJ that 'more information with respect to etiology, diagnosis, and assessment of TMD is still needed'. This request deserves attention for the diagnosis crossbite as well.

A literature search on 'crossbite' will result in a malocclusion with different localization such as 'anterior', 'posterior', 'lateral', and even 'buccal' crossbite, each of them often in combination with another dental anomaly. To classify these different malocclusion types in the same category, termed crossbite may explain the controversial opinions on its possible association with TMD. In the present paper, 'posterior crossbite' or its synonym 'lateral crossbite', defined as a section of teeth in crossbite position, is used.

The prevalence of posterior crossbite varies between 4 and 23 per cent in different populations. This wide range may be explained by differences in populations, but above all, that some studies focus on different age groups. Only few studies on the prevalence of malocclusion in large samples at different dental development periods have been published (Helm, 1970; Myllärniemi, 1970; Thilander *et al.*, 2001). It is quite obvious from these studies that posterior crossbite is more frequent in the primary dentition, due to sucking habits (e.g. Larsson, 1978; Øgaard *et al.*, 1994), which may suggest that a crossbite in some young children is self-correcting (Leighton, 1966; Thilander *et al.*, 1984; Kuroi and Berglund, 1992). According to Helm (1970), the frequency increases in girls from mixed to permanent dentition.

The great majority of posterior crossbite are unilateral and are of three distinct types due to disproportion between the jaws in basal (skeletal) or dentoalveolar width or associated with a forced guidance of the mandible (functional type). A distinction between these different types and their possible association with TMD is generally neglected in previous publications.

The contradictory opinions discussed above are of no help to the clinician in making the decision to treat or not to treat children with posterior crossbite to avoid possible future TMD problems. The aim with the present study hence was to update the bibliography with special interest to analyse if those publications have focused on differential diagnosis of TMD as well as of posterior crossbite, which might answer the issue: is there any association between some special sign/symptom of TMD and the type of posterior crossbite, which will call for orthodontic treatment?

## Material and methods

### Literature search

A search in the MEDLINE database from January 1970 to August 2009 was made. Various combinations of the

following MeSH terms were used: temporomandibular disorders OR dysfunction (TMD/CMD) AND malocclusions OR posterior crossbite. The inclusion criteria were studies in the English language, human studies, posterior crossbite, lateral crossbite, TMDs, randomized controlled trials (RCTs) or retrospective studies with controlled or reference group, controlled clinical trials, and prospective studies. Exclusion criteria were case reports, review studies, studies with unclear diagnosis or poorly defined patient material, cleft/lip and/or palate or other syndromes, diagnoses, treatment strategies, and treatment appliances.

In total, 210 articles were found. Among them, 116 focused on different treatment strategies in general or with various orthodontic appliances and their treatment results and were excluded. The abstracts of the remaining 94 articles were studied, but most of them did not fulfil the inclusion criteria and were excluded. Reading the remaining 26 full articles, no RCT study was found, which hardly is to be expected in such type of studies.

Half of the articles were found to be review papers or presentations of TMJ signs and symptoms but not related to crossbite. The literature search thus resulted in 14 articles, which fulfilled the criteria for the present systematic review (Table 1).

Moreover, manual searching was carried out on the following journals for the same period: *Journal of Orofacial Orthopedics/Fortschritte der Kieferorthopädie*, *European Journal of Orthodontics*, *Angle Orthodontics*, *American Journal of Orthodontics and Dentofacial Orthopedics*, *Orthodontics and Craniofacial Research*, and *International Journal of Jaw Functional Orthopedics*. No additional information to the Medline database was found.

## Results

As seen from Table 1, an association between TMD and posterior crossbite was reported in eight papers against five with absence of such a relationship. The samples in the two groups showed similarities as well as differences with respect to their structure. Thus, males and females were included in both groups. The number of subjects varied between rather few and many (a range of 27–4724 in the 'Yes'-group and 337–3428 in the 'No'-group). The ages 10–16 years were prevalent in both groups, while young children (5–8 years old) and adults (20–54 years of age) were found only in the Yes-group.

'Presence' or 'absence' of crossbite is in general simply given; a distinction between unilateral and bilateral type is unusual, and the difference between skeletal, dentoalveolar, and functional types is rare. Thus, we are informed that bilateral crossbite is reported in only 2 of the 14 articles, showing a tendency, not significant, to TMD (Mohlin *et al.*, 2004) but did not differ from the unilateral type as regards mandibular dysfunction (Mohlin and Thilander, 1984). Unilateral crossbite with mandibular guidance including

**Table 1** Temporomandibular disorder (TMD) signs and symptoms in patients with posterior crossbite.

Authors	Subjects	Age, years	Methods, TMD/posterior crossbite	Association of posterior crossbite and TMD
de Boer and Steenks (1997)	27 children	5–6	Clinical examination. Functional unilateral posterior crossbite, joint sounds, pain during movements of the mandible, headache, muscle tiredness, and TMD symptoms reported both by the child and by the parents were registered.	‘Yes’ Absence of functional disturbances when the crossbite was corrected but it does not guarantee the absence of functional disturbances at a later age.
Demir <i>et al.</i> (2005)	716 subjects	10–19	Clinical examination. Tenderness on palpation of masseter, temporalis, and lateral and medial pterygoid muscles were registered. Presence of anterior and posterior crossbites, excessive overjet, open bite, deep bite, and functional shift were registered.	‘No’ Significant associations with muscle tenderness and all occlusal factors except posterior crossbite were found.
Egermark I <i>et al.</i> (2003)	320 subjects	35	Clinical examination. Malocclusion registration, movement of the mandible, mouth opening, TMJ sounds, locking or luxation, pain on mandibular movement, and TMJ or muscle pain and registration of morphological malocclusions. A questionnaire, based on the masticatory system, TMJ clicking, mouth opening, tiredness in jaws, headache, and oral parafunction.	‘Yes’ TMD signs and symptoms are correlated with unilateral posterior crossbite.
Farella <i>et al.</i> (2007)	1291 subjects	Mean 12.3 years (range 10.1–16.1)	Orthodontic and TMJ functional examination by two dentists. Chi-square tests and multiple logistic regression were used for analyses.	‘No’ No association, at least not in young adolescents.
Keeling <i>et al.</i> (1994)	3428 subjects	6–12	Registration of malocclusion, TMJ sounds, clicking, crepitus. Registration of anterior or posterior crossbite.	‘No’ No association with posterior crossbite.
Lambourne <i>et al.</i> (2007)	50 subjects	8–16	Morphological malocclusions were registered on plaster models. Headache reported from dental records. Patients with documented frequent headaches were selected. A matched control group with no history of headache.	‘Yes’ Increased risk for headache significant associated with posterior crossbite.
Lieberman <i>et al.</i> (1985)	369 subjects	10–18	Overjet, overbite, and open bite registered in millimetre. Presence of anterior and posterior crossbite was registered as well. Clinical examination of joint sounds and muscle sensitivity.	‘No’ No correlation with posterior crossbite.
Mohlin and Thilander (1984)	389 men	21–54	Malocclusion registered on dental casts. Clinical examination of TMD signs and symptoms.	‘Yes’ No strong correlation was found between malocclusion and mandibular dysfunction. Crossbite and frontal open bite were more prevalent in patients with mandibular dysfunction than has been found in other studies.
	272 women	20–46	The relationship between malocclusions and mandibular dysfunction. Regression analyses.	No difference was found between unilateral and bilateral crossbite as regards influence of mandibular dysfunction.
Mohlin <i>et al.</i> (2004)	337 subjects	30	Anamnestic and clinical records of TMD and PAR scores were registered.	‘No’ Bilateral crossbite, however, showed a tendency to TMD but not significant. Only a few subjects were found to have a unilateral crossbite. Crowding of teeth was the only malocclusion trait with significant correlation to TMD.
Pahkala and Qvarnström (2004)	157 subjects	7.6, 10.15, and 19	Clinical examination at four times in a longitudinal study. Palpation on masticatory muscles was recorded as ‘yes’ if pain was reported by the patient. Clicking or crepitation, deviation and maxinal opening, molar relation, overjet, overbite, crossbite, and scissors bite. Multiple logistic regression was used.	‘No’ No association, crossbite and TMD. Only a large overjet seemed to increase the risk of TMD.

**Table 1** (continued).

Authors	Subjects	Age, years	Methods, TMD/posterior crossbite	Association of posterior crossbite and TMD
Pullinger <i>et al.</i> (1993)	328 individuals and 147 controls	—	Clinical examination of 11 occlusal variables was studied. The individuals were also examined for disk displacement with reduction and without reduction and TMJ osteoarthritis with disk displacement history and without any known earlier history. Muscle tenderness at palpation. A multiple logistic regression analysis was used to compute the odds ratios for 11 common occlusal features.	'Yes' Crossbite was significantly associated with clicking. Unilateral posterior crossbite occurred most frequently in the disk displacement without reduction group (23%).
Sonnesen <i>et al.</i> (1998)	104 subjects	7–13	A clinical examination of TMJ with regard to tenderness, clicking, or grating sounds was performed. Malocclusion data were taken from the patients dental records, molar occlusion, overjet, overbite, unilateral or bilateral posterior crossbite, scissors bite, and midline displacement. Interview with the child and the parents about functional disorders and pain.	'Yes' The most prevalent symptoms of TMD were the occurrence of weekly headache and bruxism, tenderness in anterior temporal and occipital muscles and profound masseter. TMD signs and symptoms were significantly associated with unilateral crossbite.
Thilander <i>et al.</i> (2002)	4724 subjects	5–17	Clinical examination registered functional occlusion, dental wear, mandibular mobility, TMJ, and muscular pain and headache. Associations between malocclusions (Thilander <i>et al.</i> , 2001) and TMD were given.	'Yes' Significant associations was found as regards TMJ and muscular pain, clicking and headache. The prevalence of dysfunction was 45.7% for posterior crossbite though generally of mild type. Moderate and severe dysfunction was 10.3%.
Vanderas and Papagiannoulis (2002)	314 subjects	6–8	Posterior and anterior crossbite, open bite, deep bite, and overjet were registered. Clinical examination of TMJ and masticatory muscles tenderness as well as registration of mouth opening, deviation of the mandible, and joint sounds was performed. Also, a questionnaire to the parents, to evaluate TMD signs and symptoms.	'Yes' Posterior crossbite had a significant impact on TMJ tenderness.

Yes or No is evaluation of the results reported in the articles. This evaluation is made from the material, selection, and number as well as the methods including the number of TMD variables used.

midline deviation is reported in three of the articles (de Boer and Steenks, 1997; Sonnesen *et al.*, 1998; Thilander *et al.*, 2002). Finally, in some papers, the prevalence of malocclusion was taken from the subjects' dental record (school or private dentist).

Even if 'clinical signs and symptoms' were reported as often in the articles belonging to the Yes- and No-groups, more signs and symptoms were found in the former group. Moreover, differences as regards the type of sign and symptom existed between them.

Thus, 'TMJ and muscle tenderness' on palpation showed significant association with posterior crossbite according to some authors (de Boer and Steenks, 1997; Thilander *et al.*, 2002; Vanderas and Papagiannoulis, 2002; Egermark *et al.*, 2003) but not to others (Lieberman *et al.*, 1985; Keeling *et al.*, 1994; Demir *et al.*, 2005; Farella *et al.*, 2007).

'TMJ sounds and clicking' were reported significant correlated with posterior crossbite (Pullinger *et al.*, 1993; de Boer and Steenks, 1997; Thilander *et al.*, 2002; Egermark *et al.*, 2003) opposite to statement from other articles (Lieberman *et al.*, 1985; Pahkala and Qvarnström, 2004).

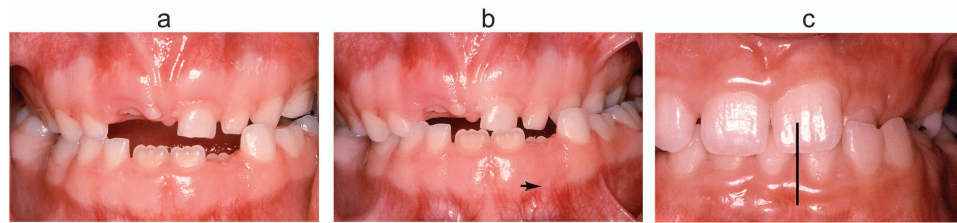
According to Pullinger *et al.* (1993), unilateral posterior crossbite occurred most frequently in subjects with disc displacement without reduction.

'Headache', above all, was reported as a factor in some articles as a factor with significant association with posterior crossbite (Sonnesen *et al.*, 1998; Egermark *et al.*, 2003; Lambourne *et al.*, 2007).

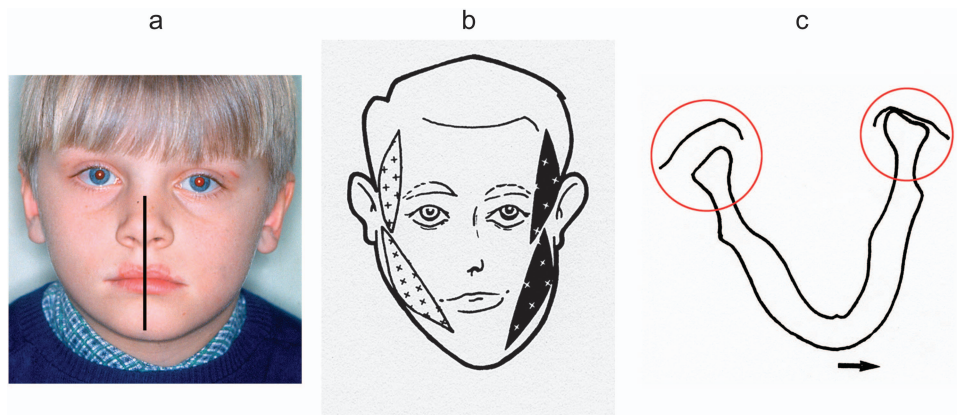
## Discussion

The present updated review, based on publications selected due to specified criterion, is in agreement with earlier reviews, i.e. positive as well as negative association between TMD and posterior crossbite were found. Of interest to note is the overall interest in the different TMD variables, whereas type of crossbite was ignored. However, functional crossbite (mandibular guidance including midline deviation; Figure 1) is mentioned in some articles (Pullinger *et al.*, 1993; de Boer and Steenks, 1997; Thilander *et al.*, 2002). In addition, joint sounds, clicking, muscle tenderness, and headache were significantly correlated to this type of posterior crossbite.





**Figure 1** A 6-year-old boy with functional posterior crossbite. Arrow indicates mandibular sliding movement from retroposition (a) to intercuspal relationship and (b). The same boy 3 years later (not orthodontically treated) with increased midline deviation (c).



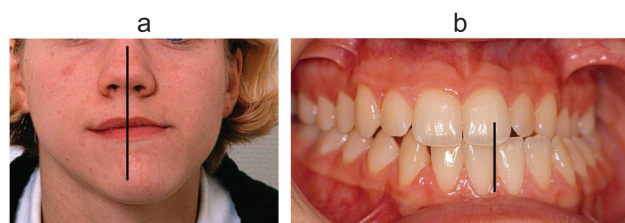
**Figure 2** The 9-year-old boy from Figure 1c showing facial asymmetry (a) and asymmetric activity of the temporal masseter muscles at the mandibular sliding to intercuspal relationship (b). Drawing illustrating the changed condylar position in relation to the temporal bony component (c).

Pullinger *et al.* (1993) also have reported that disk displacement without reduction is an important factor in this type. Thus, those findings indicate an association between functional unilateral posterior crossbite and some signs and symptoms of TMD (TMJ pain, muscular tenderness, clicking, and headache), which deserves attention in the orthodontic treatment plan, especially as the frequencies of TMD and posterior crossbite increase with age.

A forced guidance of the mandible will result in asymmetric activity of the masticatory muscles (Figure 2a and 2b), significantly lower on the non-crossbite side (Troelstrup and Möller, 1970; Ingervall and Thilander, 1975; Ferrario *et al.*, 2002) probably due to differences in thickness of the muscles on the crossbite and non-crossbite sides (Rasheed *et al.*, 1996). The asymmetric muscle activity was documented not only in intermaxillary position but even in rest position (Ingervall and Thilander, 1975), which suggests that the relaxed mandible was still displaced to the side of the forced bite caused by a neuromuscular adaptation to the intercuspal relationship (ICP). This hypothesis is based on the fact that treatment of the malocclusion will change growth and development of the muscles and hence eliminates their asymmetric activity (Pinto *et al.*, 2001; Kecik *et al.*, 2007).

Moreover, the maximum bite force in children with unilateral crossbite is significant lower than in controls (Troelstrup and Möller, 1970; Ingervall and Thilander, 1975; Sonnesen *et al.*, 1998; Castelo *et al.*, 2007). It has also been shown that treatment of the malocclusion will present symmetrical bite force and masticatory capacity between the crossbite and non-crossbite sides (Tsarapatsani *et al.*, 1999). Thus, rehabilitation of the asymmetric muscle activity in the functional crossbite is of importance.

Finally, when the mandible is displaced into ICP, the condyle on the non-crossbite side will move in a downward, medial direction, and the one on the crossbite side in an upward, lateral direction (Figure 2a and 2c), resulting in a changed condylar position in the glenoid fossae and may cause TMJ pain and clicking. Moreover, such changed condylar/temporal relationship will have an influence on the remodelling processes in those areas (Thilander *et al.*, 1976; Thilander, 1995; Hesse *et al.*, 1997; Nerder *et al.*, 1999; Pinto *et al.*, 2001; Kecik *et al.*, 2007). Thus, early treatment from growth-adaptive reason is indicated. Left untreated; there is a great risk that the functional crossbite in young ages will be transformed to a cranial skeletal malocclusion in later ages (Figure 3).



**Figure 3** A functional crossbite transformed to a skeletal malocclusion in a 25-year-old woman. Facial asymmetry (a), midline deviation (b).

## Conclusions

The present updated bibliography as regards the concept TMD and diagnosis posterior crossbite indicates an association between a unilateral posterior crossbite with mandibular deviation and some signs and symptoms of TMD (TMJ muscular pain, clicking, and headache). Should this indicate need for orthodontic treatment, as was questioned in the introduction? Need for orthodontic treatment of a functional unilateral posterior crossbite shall first of all focus on rehabilitation of the asymmetric muscular activity and the changed condylar position in the glenoid fossae due to the mandibular displacement. Whether this also should involve a prophylactic measure to avoid future problems in joints and masticatory muscles can only be answered after clinical follow-up studies have been performed.

## References

- Castelo P, Duarte Gavião M B, Pereira L J, Bonjardim L R 2007 Masticatory muscle thickness, bite force, and occlusal contacts in young children with unilateral posterior crossbite. *European Journal of Orthodontics* 29: 149–156
- de Boer M, Steenks M H 1997 Functional unilateral posterior crossbite. Orthodontic and functional aspects. *Journal of Oral Rehabilitation* 24: 614–623
- de Leeuw R 2008 Orofacial pain: guidelines for assessment, diagnosis, and management/the America Academy of Orofacial Pain, 4th edn. Quintessence Publishing Co., Inc., Cop, Chicago
- Demir A, Uysal T, Basciftci F A, Guray E 2005 The association of occlusal factors with masticatory muscle tenderness in 10- to 19- year old Turkish subjects. *Angle Orthodontist* 75: 40–46
- Dibbets J M, van der Weele L T, Meng H P 1993 The relationships between orthodontics and temporomandibular joint dysfunction. A review of the literature and longitudinal study. *Schweizer Monatsschrift für Zahnmedizin* 103: 162–168
- Egermark I, Magnusson T, Carlsson G E 2003 A 20-year follow-up of signs and symptoms of temporomandibular disorders and malocclusions in subjects with and without orthodontic treatment in childhood. *Angle Orthodontist* 73: 109–115
- Farella M, Michelotti A, Iodice G, Milani S, Martina R 2007 Unilateral posterior crossbite is not associated with TMJ clicking in young adolescents. *Journal of Dental Research* 86: 137–141
- Ferrario V F, Serrao G, Dellavia C, Caruso E, Sforza C 2002 Relationship between the number of occlusal contacts and masticatory muscle activity in healthy young adults. *Cranio: the Journal of Craniomandibular Practice* 20: 91–98
- Helm S 1970 Prevalence of malocclusion in relation to development of the dentition. An epidemiological study of Danish school children. *Acta Odontologica Scandinavica* 28: Supplementum 58, 62–65
- Hesse K L, Artun J, Joondeph D R, Kennedy D B 1997 Changes in condylar position and occlusion associated with maxillary expansion for correction of functional unilateral posterior crossbite. *American Journal of Orthodontics and Dentofacial Orthopedics* 111: 410–418
- Ingervall B, Thilander B 1975 Activity of temporal and masseter muscles in children with a lateral forced bite. *Angle Orthodontist* 45: 249–258
- Kecik D, Kocadereli I, Saatci I 2007 Evaluation of the treatment changes of functional posterior crossbite in the mixed dentition. *American Journal of Orthodontics and Dentofacial Orthopedics* 131: 202–215
- Keeling S D, McGorray S, Wheeler T T, King G J 1994 Risk factors associated with temporomandibular joint sounds in children 6 to 12 years of age. *American Journal of Orthodontics and Dentofacial Orthopedics* 105: 279–287
- Kuroi J, Berglund L 1992 Longitudinal study and cost-benefit analysis of the effect of early treatment of posterior cross-bite in the primary dentition. *European Journal of Orthodontics* 14: 173–179
- Lambourne C, Lampasso J, Buchanan W C Jr, Dunford R, McCall W 2007 Malocclusion as a risk factor in the etiology of headaches in children and adolescents. *American Journal of Orthodontics and Dentofacial Orthopedics* 32: 754–761
- Larsson E 1978 Dummy- and finger-sucking habits with special attention to their significance for facial growth and occlusion. 7. The effect of earlier dummy- and finger-sucking habit in 16-year-old children compared with children without earlier sucking habit. *Swedish Dental Journal* 2: 23–33
- Leighton B C 1966 The early development of crossbites. *Dental Practitioner and Dental Record* 17: 145–152
- Lieberman M A, Gazit E, Fuchs C, Lilos P 1985 Mandibular dysfunction in 10-18 year old school children as related to morphological malocclusion. *Journal of Oral Rehabilitation* 12: 209–214
- Luther F 1998 Orthodontics and the temporomandibular joint: where are we now? Part 2. Functional occlusion, malocclusion, and TMD. *Angle Orthodontist* 68: 305–318
- McNamara J, Seligman D, Okeson J 1995 Occlusion, orthodontic treatment and, temporomandibular disorders: a review. *Journal of Orofacial Pain* 9: 73–90
- Mohlin B, Derweduwen K, Pilley R, Kingdon A, Shaw W C, Kenealy P 2004 Malocclusion and temporomandibular disorder: a comparison of adolescents with moderate to severe dysfunction with those without signs and symptoms of temporomandibular disorder and their further development to 30 years of age. *Angle Orthodontist* 74: 319–327
- Mohlin B, Thilander B 1984 The importance of the relationship between malocclusion and mandibular dysfunction and some clinical applications in adults. *European Journal of Orthodontics* 6: 192–204
- Myllärniemi S 1970 Malocclusion in Finnish rural children. An epidemiological study of different stages of dental development. *Souomen Hammaslääkäriseuran Toimituksia* 66(Suppl 5)
- Nerder P H, Bakke M, Solow B 1999 The functional shift of the mandible in unilateral posterior crossbite and the adaptation of the temporomandibular joints: a pilot study. *European Journal of Orthodontics* 21: 155–166
- Øgaard B, Larsson E, Lindsten R 1994 The effect of sucking habits, cohort, sex, intercanine archwidths, and breast or bottle feeding on posterior crossbite in Norwegian and Swedish 3-year-old children. *American Journal of Orthodontics and Dentofacial Orthopedics* 106: 161–166
- Pahkala R, Qvarnström M 2004 Can temporomandibular dysfunction signs be predicted by early morphological or functional variables? *European Journal of Orthodontics* 26: 367–373
- Pinto A S, Buschang P H, Throckmorton G S, Chen P 2001 Morphological and positional asymmetries of young children with functional unilateral posterior crossbite. *American Journal of Orthodontics and Dentofacial Orthopedics* 120: 513–520
- Pullingar A G, Seligman D A, Gornbein J A 1993 A multiple logistic regression analysis of the risk and relative odds of temporomandibular disorders as a function of common occlusal features. *Journal of Dental Research* 72: 968–979

- Rasheed S A, Prabhu N T, Munshi A K 1996 Electromyographic and ultrasonographic observations of masseter and anterior temporalis muscles in children. *Journal of Clinical Pediatric Dentistry* 20: 127–132
- Seligman D, Pullinger A 1991 The role of intercuspal occlusal relationships in temporomandibular disorders: a review. *Journal of Craniomandibular Disorders: Facial and Orofacial Pain* 5: 96–106 and 265–278
- Sonnesen L, Bakke M, Solow B 1998 Malocclusion traits and symptoms and signs of temporomandibular disorders in children with severe malocclusion. *European Journal of Orthodontics* 20: 543–559
- Thilander B 1995 Basic mechanisms in craniofacial growth. *Acta Odontologica Scandinavica* 53: 144–151
- Thilander B, Carlsson G E, Ingervall B 1976 Postnatal development of the human temporomandibular joint. A histological study. *Acta Odontologica Scandinavica* 34: 117–126
- Thilander B, Pena L, Infante C, Parada S S, de Mayorga C 2001 Prevalence of malocclusion and orthodontic treatment need in children and adolescents in Bogota, Colombia. An epidemiological study related to different stages of dental development. *European Journal of Orthodontics* 23: 153–167
- Thilander B, Rubio G, Pena L, de Mayorga C 2002 Prevalence of temporomandibular dysfunction and its association with malocclusion in children and adolescents: An epidemiologic study related to specified stages of dental development. *Angle Orthodontist* 72: 146–154
- Thilander B, Wahlund S, Lennartsson B 1984 The effect of early interceptive treatment in children with posterior cross-bite. *European Journal of Orthodontics* 6: 25–34
- Troelstrup B, Møller E 1970 Electromyography of the temporals and masseter muscles in children with unilateral crossbite. *Scandinavian Journal of Dental Research* 78: 425
- Tsarapatsani P, Tullberg M, Lindner A, Huggare J 1999 Long-term follow-up of early treatment of unilateral forced posterior cross-bite. Orofacial status. *Acta Odontologica Scandinavica* 57: 97–104
- Vanderas A P 1993 Relationship between malocclusion and craniomandibular dysfunction in children and adolescents: a review. *Pediatric Dentistry* 15: 317–322
- Vanderas A P, Papagiannoulis L 2002 Multifactorial analysis of the aetiology of craniomandibular dysfunction in children. *International Journal of Paediatric Dentistry* 12: 336–346

Copyright of European Journal of Orthodontics is the property of Oxford University Press / USA and its content may not be copied or emailed to multiple sites or posted to a listserv without the copyright holder's express written permission. However, users may print, download, or email articles for individual use.