

---

# Endodontic treatment of primary teeth using a combination of antibacterial drugs

T. Takushige<sup>1,3</sup>, E. V. Cruz<sup>2</sup>, A. Asgor Moral<sup>1,2</sup> & E. Hoshino<sup>1,2</sup>

<sup>1</sup>Department of Oral Microbiology, <sup>2</sup>Cariology Research Unit, Niigata University School of Dentistry, Niigata, and <sup>3</sup>Takushige Dental Clinic, Sendai, Japan

---

## Abstract

**Takushige T, Cruz EV, Asgor Moral A, Hoshino E.**

Endodontic treatment of primary teeth using a combination of antibacterial drugs. *International Endodontic Journal*, **37**, 132–138, 2004.

**Aim** To evaluate the clinical outcome of 'Lesion Sterilization and Tissue Repair' (LSTR) therapy for endodontic treatment of primary teeth.

**Methodology** A mixture of metronidazole, ciprofloxacin, and minocycline (3Mix) in ointment (macrogol mixed with propylene glycol: MP) or in a root canal sealer was used to disinfect infected root canals of 56 patients aged 4–18 years. Out of a total of 87 primary teeth, 81 cases had physiologic root resorption. A total of 54 radiolucent periradicular lesions were present. The root canals were not prepared before or after disinfection. 3Mix medicament (3Mix-MP/3Mix-sealer) was placed at orifices of root canals or on the bottom of pulp chambers, and then sealed with glass-ionomer cement and further reinforced by a composite resin inlay prepared using a direct method and cemented with resin.

**Results** In all cases, clinical symptoms such as gingival swelling (52 cases), sinus tracts (22 cases), induced dull pain (3 cases), spontaneous dull pain (26 cases), and pain on biting (46 cases) disappeared after treatment, although in four cases clinical signs and symptoms were finally resolved only after retreatment using the same procedures. Thus, gingival abscesses and fistulae, if present, disappeared after a few days. Successor permanent teeth erupted without any disorders, or were found radiographically to be normal and in the process of eruption. All the cases were evaluated as successful. The mean function time of the primary teeth was 680 days (range: 68–2390 days), except for one case in which the successor permanent tooth was congenitally missing.

**Conclusion** Primary teeth with periradicular lesions with or without physiologic root resorption were treated successfully by the LSTR endodontic therapy.

**Keywords:** endodontic treatment, LSTR therapy, 3Mix-MP, NIET, primary teeth.

Received 10 December 2001; accepted 15 October 2003

---

## Introduction

Teeth with infected root canals, particularly those in which the infection has reached the periradicular tissues, are a common problem in the primary dentition. Early loss of primary teeth can cause a number of problems, including space loss for successor permanent teeth (Camp 1994). Thus, it is important that the primary dentition is maintained in the dental arch, provided

that it can be restored to function and remain free from disease (Camp 1994). An intact tooth successfully disinfected and with a restored clinical crown is a superior space maintainer than an appliance (Belanger 1988).

In recent years, the Cariology Research Unit of the Niigata University School of Dentistry has developed the concept of 'Lesion Sterilization and Tissue Repair (LSTR)' therapy (Hoshino 1990, Iwaku *et al.* 1996, Hoshino & Takushige 1998) that employs the use of a mixture of antibacterial drugs for disinfection of oral infectious lesions, including dentinal, pulpal, and periapical lesions. Repair of damaged tissues can be expected if lesions are disinfected.

Bacterial constituents of carious dentine (Hoshino 1985), pulps (Hoshino *et al.* 1992), infected root dentine,

---

Correspondence: Dr Hoshino Etsuro, Department of Oral Health Science (Division of Oral Ecology in Health and Infection), Niigata University Graduate School of Medical and Dental Sciences, Gakkochi-dori 2, Niigata 951-8514, Japan (Tel.: +81 25 227 2838; fax: +81 25 227 0806; e-mail: hoshino@dent.niigata-u.ac.jp).

and necrotic pulps (Ando & Hoshino 1990, Sato *et al.* 1993b), periapical lesions and infected cementum (Kiryu *et al.* 1994) have been analyzed under strict anaerobic conditions to understand the target bacteria in LSTR endodontic treatment. In addition, bacteria in dental plaque (Hoshino *et al.* 1989b), tongue plaque (Hori *et al.* 1999), denture plaque (Hoshino & Sato 1988), saliva (Sato *et al.* 1993a), periodontal pockets (Uematsu & Hoshino 1992), and osteomyelitis (Hoshino *et al.* 1984) have also been analyzed with the strict anaerobic procedures because they were possible sources of bacteria in endodontic lesions. According to these and other results such as those of bacterial isolation and identification from caries (Edwardsson 1974) and endodontic lesions (Wittgow & Sabiston 1975, Sundqvist 1976, Zavisoski *et al.* 1980, Yoshida *et al.* 1987), antibacterial drugs were selected. Metronidazole was the first choice because it has a wide bactericidal spectrum against anaerobes (Ingham *et al.* 1975), which were common in oral sites. However, some bacteria in lesions were resistant to metronidazole and, thus, two other antibacterial drugs, e.g. ciprofloxacin and minocycline, should be mixed with metronidazole (3Mix; Sato *et al.* 1993c) in an effort to eliminate all the bacteria. Finally, extensive *in vitro* and *in situ* studies have been conducted showing the mixed drugs (3Mix) to be effective against oral bacteria (Hoshino *et al.* 1988; 1989a; 1991; 1996, Kiryu *et al.* 1994, Sato *et al.* 1996, Hori *et al.* 1997, Takushige & Hoshino 1998), including those in endodontic lesions of primary teeth (Sato *et al.* 1992, 1993c). Thus, the drug mixture could eliminate all the possible bacteria from lesions, indicating that LSTR therapy may be useful in endodontic treatment of infected primary teeth.

The aim of the present study was to clinically evaluate LSTR therapy in endodontic treatment of infected primary teeth, including those with physiologic root resorption.

## Materials and methods

### Patients and teeth involved in this study

Eighty-seven infected primary teeth in 56 patients, 4–18 years old, were included (Tables 1 and 2). The patients received dental treatment between 1989 and 1997 at the Takushige Dental Clinic (Sendai, Japan). Prior to inclusion, they were informed of the aim and expected clinical results, as well as the advantages and the disadvantages of the treatment. The patients provided written consent and were then treated by one of four dentists.

**Table 1** Patient's age at treatment

| Age (years)  | No. of cases |
|--------------|--------------|
| 4            | 1            |
| 5            | 6            |
| 6            | 8            |
| 7            | 9            |
| 8            | 21           |
| 9            | 19           |
| 10           | 14           |
| 11           | 7            |
| 12           | 1            |
| 18           | 1            |
| Total number | 87           |

**Table 2** Number and position of teeth treated by LSTR 3Mix endodontic therapy

| Maxillary teeth |              | Mandibular teeth |              |
|-----------------|--------------|------------------|--------------|
| Teeth*          | No. of cases | Teeth*           | No. of cases |
| 55              | 11           | 85               | 11           |
| 54              | 12           | 84               | 16           |
| 63              | 1            | 83               | 1            |
| 64              | 11           | 74               | 11           |
| 65              | 6            | 75               | 7            |
| Total           | 41           |                  | 46           |

\*Expressed by FDI two-digit system.

### Clinical and radiographic observation before LSTR endodontic treatment

Of the 87 cases, 81 exhibited varying degrees of physiologic root resorption according to the age of the patients (Table 3). Varying degrees of gingival swelling were observed in 52 cases and fistulae in 22 cases (Table 4). Patients felt dull pain in 29 cases, including 26 cases with spontaneous dull pain, and pain on biting in 46 cases

**Table 3** Cases with physiologic root resorption and the clinical results after LSTR 3Mix endodontic treatment

| Degree of physiologic root resorption* | Number of cases |            |
|--|-----------------|------------|
|  | Treated         | Successful |
| Over 3/4                               | 6               | 6          |
| 1/2 to 3/4                             | 7               | 7          |
| 1/4 to 1/2                             | 25              | 25         |
| Less than 1/4                          | 43              | 43         |
| No resorption                          | 6               | 6          |
| Total                                  | 87              | 87         |

\*Over 3/4' means more than three-fourths of the root canal was disappeared.

\*Physiologic root resorption at the time of first treatment expressed by the position of root canal opening to the periradicular area because of the resorption.

**Table 4** Cases with gingival swelling/fistula, and the clinical results after LSTR 3Mix endodontic treatment

| Swelling (diameter)/fistula | No. of cases |            |
|-----------------------------|--------------|------------|
|                             | Treated      | Successful |
| + (1–5 mm)                  | 30           | 30         |
| ++ (6–10 mm)                | 16           | 16         |
| +++ (11–15 mm)              | 6            | 6          |
| Fistula                     | 22           | 22         |
| No swelling                 | 13           | 13         |
| Total                       | 87           | 87         |

**Table 5** Cases with clinical pain and the clinical results after LSTR 3Mix endodontic treatment

| Types of pain         | No. of cases |            |
|-----------------------|--------------|------------|
|                       | Treated      | Successful |
| Induced dull pain     | 3            | 3          |
| Spontaneous dull pain | 26           | 26         |
| Pain on biting        | 46           | 46         |
| No pain experienced   | 41           | 41         |
| Total                 | 87           | 87         |

**Table 6** Cases with alveolar bone resorption\* and the clinical results after LSTR 3Mix endodontic treatment

| Degrees of alveolar bone resorption | No. of cases |            |
|-------------------------------------|--------------|------------|
|                                     | Treated      | Successful |
| Complete                            | 47           | 47         |
| Partial (about 1/2)                 | 7            | 7          |
| None observed                       | 33           | 33         |
| Total                               | 87           | 87         |

\*Resorption observed between the affected primary teeth and successor permanent teeth.

(Table 5). Radiographic examination revealed radiolucent areas between the root(s) of infected primary tooth and the successor tooth in 54 cases, with 47 cases demonstrating complete loss of the alveolar bone (Table 6). Thus, most of the primary teeth involved in this study were those with radiolucent periradicular lesions with physiologic root resorption.

#### Preparation of 3Mix-MP/3Mix-sealer

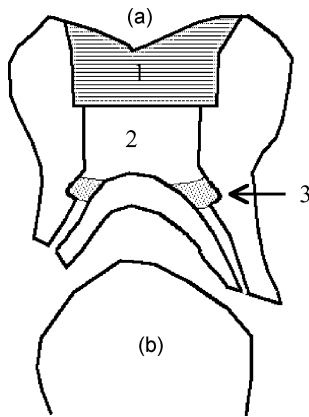
Commercially prepared chemotherapeutic agents, namely, ciprofloxacin (Ciproxan<sup>®</sup>, Bayer-Japan, Osaka, Japan), metronidazole (Trichocide<sup>®</sup>, Green Cross, Osaka, Japan), and minocycline (Minomycine<sup>®</sup>, Ledea-Japan, Tokyo, Japan) were used. The clinical procedures have been described elsewhere (Hoshino 1990, Hori *et al.*

1997, Hoshino & Takushige 1998). In short: after removal of the enteric coating and the capsules that enclose the drug products, each of the drugs was pulverized using porcelain mortars and pestles, and then stored in tightly capped porcelain containers to prevent exposure to light and moisture. Each drug in the porcelain container was separately kept in a refrigerator at a temperature of approximately 16 °C. Care was taken not to open the containers before they had reached room temperature. The powdered antibacterial drugs were mixed in a ratio (potency) of 1 : 3 : 3 (3Mix). The 3Mix was prepared in one of the two ways: the first preparation was used with a mixture of macrogol (M; Solbase<sup>®</sup>, Meiji, Tokyo, Japan) and propylene glycol (P) to prepare an ointment material (MP). The drug mixture and the ointment were then thoroughly mixed to form 3Mix-MP. The second preparation was the mixture of canal sealer (Finapex, Kyocera, Kyoto, Japan) and the antibacterial medication (3Mix-sealer). 3Mix-sealer was used in the early stage of this study before it was known about the efficient penetration of propylene glycol into dentine as a vehicle carrying the drugs (Cruz *et al.* 2002).

#### Clinical procedure of LSTR in the endodontic treatment of primary teeth with 3Mix-MP or 3Mix-sealer

Acute and chronic clinical symptoms such as the presence of abscess formation, fistulae (sinus tracts), gingival swelling, purulent exudate, and pain were recorded. Preoperative radiographs were taken prior to treatment.

Access opening was performed and the necrotic pulp and previous restoration, if any, were removed with a bur. The walls of the access cavity were chemically cleaned with 35% phosphoric acid solution. Before applying 3Mix-MP or 3Mix-sealer, the orifice of the root canal was enlarged to create a medication cavity (diameter 1 mm and depth 2 mm) (Figs 1 and 2-c) as a receptacle for the medication. Haemorrhage, if present, was controlled by applying cotton pellets immersed in 10% NaOCl. The medication cavity was then half-filled with 3Mix-MP or 3Mix-sealer. If receptacles of a suitable size could not be prepared, the pulpal floor was covered with the equivalent amount of 3Mix-MP or 3Mix-sealer. 3Mix drugs in both preparations were then sealed with glass-ionomer cement and further reinforced by a direct bonded resin inlay. In most cases (80%), the treatment was completed in one visit. Another visit was required when the cavities were restored by metal inlays luted with resin cement.



**Figure 1** The schema of LSTR 3Mix-MP NIET for infected deciduous teeth. (a) Deciduous teeth with physiologic root resorption: (1) Resin inlay made by direct method and fixed by resin cement; (2) Glass-ionomer cement filling; (3) 3Mix-MP in the prepared medication cavity. (b) The succedaneous permanent teeth.

#### Clinical evaluation of LSTR endodontic treatment

Resolution or improvement of clinical symptoms was checked after treatment. Within a month (mainly within 10 days) after the treatment, the first clinical evaluation was carried out as a short-term evaluation. Long-term evaluation was completed when the patients visited the clinic for other treatment or at the time of recalls (mean observation period 680 days; maximum, 2390 days). Teeth, if treated successfully, were firmly attached in the jaw, in function and without pain or infection, replaced by the successor permanent teeth or in the normal process of replacement as evidenced by the radiograph. Furthermore, radiolucent lesions had to be reduced in size or resolved. After clinical successes were evaluated as described above, normal replacement by successor permanent teeth was finally confirmed. Normal exfoliation of the treated primary teeth was checked by asking patients and their parents at the time of recalls.

#### Results

##### Clinical observation after LSTR endodontic treatment

In 83 out of 87 cases, the clinical symptoms improved following a single application of the 3Mix drug. Thus, gingival swelling and fistulae disappeared (Table 4) within a few days of the drug application. Pain disappeared (Table 5), and all the teeth functioned normally

after treatment. In the remaining four cases, retreatment with 3Mix-MP method was performed because gingival swelling was observed before the successor permanent teeth erupted. In two cases, the pulpal floor was partly resorbed by physiologically several months after the first treatment, and the pulpal cavities were connected to the oral cavities. In the retreatment, the pulpal floor was closed with resin before 3Mix-MP was placed. The other two patients were younger and treated in the early stage of the study, and patient management was a problem; the patients could not keep their mouth open for a sufficient time, resulting in probable insufficient sealing of the cavities. After retreatment in the four cases, the clinical symptoms improved. Thus, the four teeth were also categorized as successful. Finally, normal exfoliation of the treated primary teeth and replacement by the successor permanent teeth was confirmed (mean: 680 days after treatment; range: 68–2390 days), except for one case with a congenitally missing tooth.

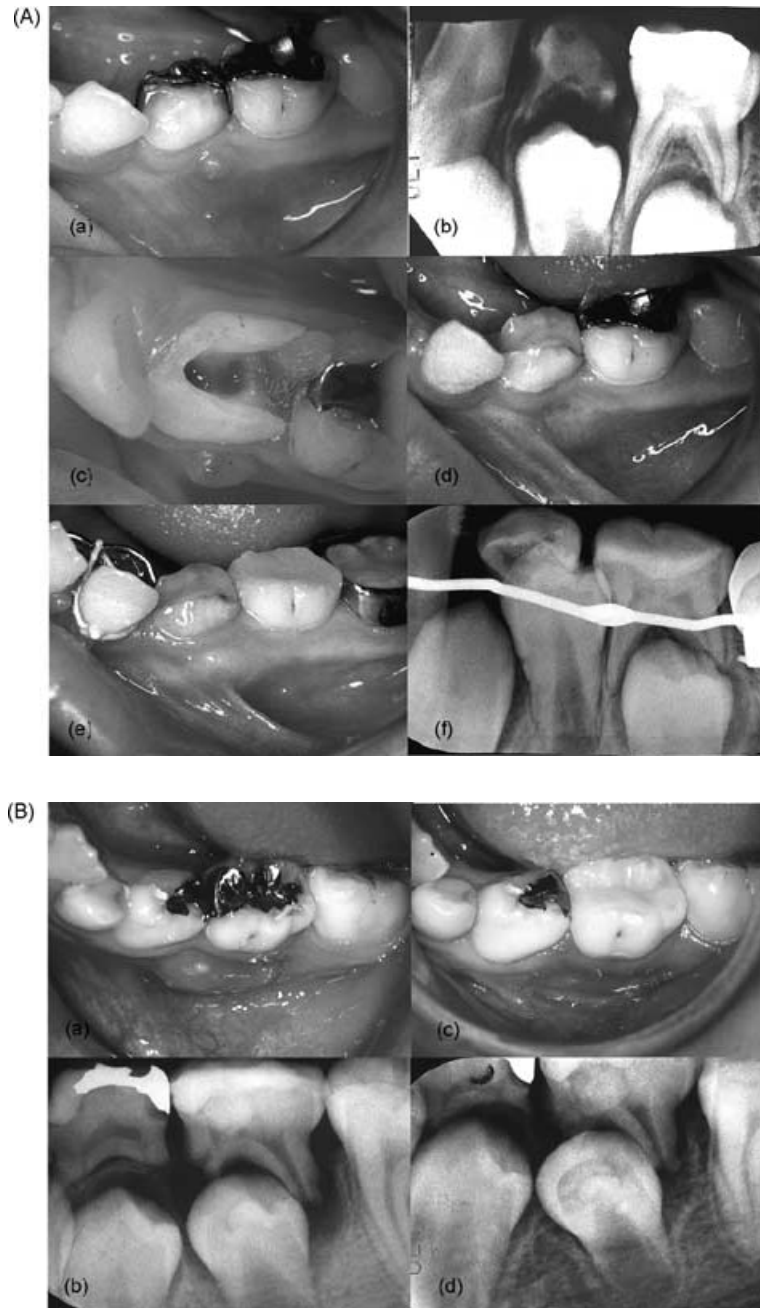
It should be also noted that 70 out of 87 cases (80%) were completed and successful in a single treatment. In some cases, changes of clinical symptoms were observed several times before completing final restorations, even though there were no clinical complaints, especially in the early stage of this study when 3Mix-sealer method was adapted. Thus, numbers of visits did not relate to the severity of the clinical signs or symptoms, e.g. fistula formation or large radiolucent periradicular lesions, and even of physiologic root absorption. In several cases, the pulpal chambers had been exposed to the peripheral tissue because of physiologic resorption, but after the LSTR treatment the teeth remained in normal function.

#### Discussion

The results demonstrate that primary teeth with periradicular lesions, including those at the stage of physiologic root resorption, were conserved by the LSTR endodontic therapy.

Extraction and placement of a space maintainer is often suggested in the case of infected root canals of primary teeth (Koch *et al.* 1991). Furthermore, endodontic treatment at the stage of physiologic root resorption is contraindicated by some authorities (Belanger 1988, Koch *et al.* 1991, Camp 1994, McDonald & Avery 1994).

It was clearly demonstrated in this study that the use of the 3Mix drug in primary teeth with periradicular involvement gave excellent clinical results, even



**Figure 2** Clinical cases of LSTR 3Mix-MP NIET. (A) A clinical case. (a,b) Before treatment. Note that gingival swelling and sinus tract are obvious in (a). The radiograph (b) reveals that the mandibular left deciduous first molar is in the stage of physiologic root resorption. (c) Medication cavities prepared at orifice of the root canals. (d) A week after the treatment. Note that gingival swelling and sinus tract had been disappeared. (d,f) After 351 days, the deciduous tooth is going to be replaced by the succedaneous permanent tooth normally. (B) Another clinical case. (a,b) Before the treatment. Note that gingival abscess is obvious in (a). The radiograph (b) reveals that the mandibular left deciduous second molar, in the stage of physiologic root resorption, needs endodontic treatment. (c) Gingival abscess had disappeared by 11th day after treatment. (d) After 225 days, the succedaneous permanent tooth was in the normal process of eruption.

in a single visit. Root canals, especially those of primary teeth at the stage of physiologic root resorption, cannot always be prepared and obturated. As mentioned above, the present therapy apparently depends on the elimination of bacteria from the root canal system but not on mechanical procedures. Therefore the clinical procedure is simple and does not require long chair-time or multiple visits. This treatment has been

designated as non-instrumentation endodontic treatment (NIET).

Excellent clinical results of LSTR-NIET in the treatment of infected primary teeth may be ascribed by the bactericidal efficacy of the mixture of drugs (3Mix). Previous studies have clearly demonstrated that 3Mix is capable of eliminating bacteria from infected dental tissues in both permanent and primary teeth (Hoshino

et al. 1988, 1989a, 1991, 1996, Sato et al. 1992, 1993c, 1996, Kiryu et al. 1994, Hori et al. 1997, Takushige & Hoshino 1998). It was also demonstrated *in situ* that the drug mixture could be carried quickly and efficiently by propylene glycol (P of 3Mix-MP; Cruz et al. 2002) and thus penetrated into the endodontic lesions of primary teeth and killed all the cultivable bacteria within 1 day, indicating that lesions can be 'sterilized' by topical application of the 3Mix drug (Sato et al. 1992, 1993c), as well as permanent teeth (Sato et al. 1996). 3Mix-MP should be used rather than 3Mix-sealer.

Caution should be taken in general when dentists give local or systemic drugs. Although the volumes of the drugs applied in LSTR therapy is small and there were no reports of side-effects, care should be taken if children are sensitive to chemicals or antibiotics.

## Conclusion

Within the limitations of this study, LSTR therapy using 3Mix-MP, i.e. a mixture of metronidazole, ciprofloxacin, and minocycline (3Mix), and macrogol and propylene glycol (MP), provided an excellent outcome in treatment of infected root canals of primary teeth with periradicular lesions and those with physiologic root resorption.

## Acknowledgements

This study was supported in part by Grants-in-aid for Scientific Research (12557182, 14406028) from the Ministry of Education, Culture, Sports, Science and Technology.

## References

- Ando N, Hoshino E (1990) Predominant obligate anaerobes invading the deep layers of root canal dentine. *International Endodontic Journal* **23**, 20–7.
- Belanger GK (1988) Pulp therapy for the primary dentition. In: Pinkham JR, ed. *Pediatric Dentistry*. Philadelphia, PA, USA: Saunders, pp. 257–67.
- Camp JH (1994) Pediatric endodontic treatment. In: Cohen S, Burns RC, eds. *Pathways of the Pulp*, 6th edn. St Louis, MO, USA: Mosby, pp. 633–71.
- Cruz EV, Kota K, Huque J, Iwaku M, Hoshino E (2002) Penetration of propylene glycol through dentine. *International Endodontic Journal* **35**, 330–6.
- Edwardsson S (1974) Bacteriological studies on deep areas of carious dentine. *Odontologisk Revy* **25** (Suppl. 32), 1–143.
- Hori R, Kohno S, Hoshino E (1997) Bactericidal eradication from carious lesions of prepared abutments by an antibacterial temporary cement. *Journal of Prosthetic Dentistry* **77**, 348–52.
- Hori R, Kohno S, Hoshino E (1999) Tongue microflora in edentulous geriatric denture-wearers. *Microbial Ecology in Health and Disease* **11**, 89–95.
- Hoshino E (1985) Predominant obligate anaerobes in human carious dentine. *Journal of Dental Research* **64**, 1195–8.
- Hoshino E (1990) Sterilization of carious lesions by drugs. *Journal of the Japanese Association for Dental Science* **9**, 32–7.
- Hoshino E, Sato Mi (1988) Composition of bacterial deposits on full denture. *Japanese Journal of Prosthetic Dentistry* **32**, 762–6.
- Hoshino E, Takushige T (1998) LSTR 3Mix-MP method – better and efficient clinical procedures of lesion sterilization and tissue repair (LSTR) therapy. *Dental Review* **666**, 57–106.
- Hoshino E, Echigo S, Yamada T, Teshima T (1984) Isolation of *Propionibacterium acnes* from sclerosing osteomyelitis of mandibles. *Japanese Journal of Oral Biology* **26**, 48–51.
- Hoshino E, Kota K, Sato Mi, Iwaku M (1988) Bactericidal efficacy of metronidazole against bacteria of human carious dentine *in vitro*. *Caries Research* **22**, 280–2.
- Hoshino E, Iwaku M, Sato Mi, Ando N, Kota K (1989a) Bactericidal efficacy of metronidazole against bacteria of human carious dentine *in vivo*. *Caries Research* **23**, 78–80.
- Hoshino E, Sato Mi, Sasano T, Kota K (1989b) Characterization of bacterial deposits formed *in vivo* on hydrogen-ion-sensitive field transistor electrodes and enamel surfaces. *Japanese Journal of Oral Biology* **31**, 102–6.
- Hoshino E, Sato Mi, Uematsu H, Kota K (1991) Bactericidal efficacy of metronidazole against bacteria of human periodontal pockets *in vitro*. *Japanese Journal of Oral Biology* **33**, 483–9.
- Hoshino E, Ando N, Sato Mi, Kota K (1992) Bacterial invasion of non-exposed dental pulp. *International Endodontic Journal* **25**, 2–5.
- Hoshino E, Kurihara-Ando N, Sato I et al. (1996) *In vitro* antimicrobial susceptibility of bacteria taken from infected root dentine to a mixture of ciprofloxacin, metronidazole and minocycline. *International Endodontic Journal* **29**, 125–30.
- Ingham HR, Selkon JB, Hale JH (1975) The antibacterial activity of metronidazole. *Journal of Antimicrobial Chemotherapy* **1**, 355–61.
- Iwaku M, Hoshino E, Kota K (1996) *Lesion Sterilization and Tissue Repair (LSTR) Therapy: New Pulpal Treatment. How to Conserve Infected Pulp*. Tokyo, Japan: Nihon-Shika-Hyoron.
- Kiryu T, Hoshino E, Iwaku M (1994) Bacteria invading periapical cementum. *Journal of Endodontics* **20**, 169–72.
- Koch G, Modeér T, Poulsen S, Rasmussen P (1991) *Pedodontics*. Copenhagen, Denmark: Munksgaard.
- McDonald RE, Avery DR (1994) *Dentistry for the Child and Adolescent*, 6th edn. St Louis, MO, USA: Mosby.
- Sato I, Kurihara-Ando N, Kota K, Iwaku M, Hoshino E (1996) Sterilization of infected root-canal dentine by topical application of a mixture of ciprofloxacin, metronidazole and minocycline *in situ*. *International Endodontic Journal* **29**, 118–24.
- Sato Ma, Hoshino E, Nomura S, Ishioka K (1993a) Salivary microflora of geriatric edentulous persons wearing dentures. *Microbial Ecology in Health and Disease* **6**, 293–9.

- Sato T, Hoshino E, Uematsu H, Kota K, Iwaku M, Noda T (1992) Bactericidal efficacy of a mixture of ciprofloxacin, metronidazole, minocycline and rifampicin against bacteria of carious and endodontic lesions of human deciduous teeth *in vitro*. *Microbial Ecology in Health and Disease* **5**, 171–7.
- Sato T, Hoshino E, Uematsu H, Noda T (1993b) Predominant obligate anaerobes in necrotic pulps of human deciduous teeth. *Microbial Ecology in Health and Disease* **6**, 269–75.
- Sato T, Hoshino E, Uematsu H, Noda T (1993c) *In vitro* antimicrobial susceptibility to combinations of drugs of bacteria from carious and endodontic lesions of human deciduous teeth. *Oral Microbiology and Immunology* **8**, 172–6.
- Sundqvist G (1976) *Bacteriological Studies of Necrotic Dental Pulps*. Umeå, Sweden: Umeå University.
- Takushige T, Hoshino E (1998) Clinical evaluation of 3Mix-MP method in endodontic treatment. *Japanese Journal of Conservative Dentistry* **41**, 970–4.
- Uematsu H, Hoshino E (1992) Predominant obligate anaerobes in human periodontal pockets. *Journal of Periodontal Research* **27**, 15–9.
- Wittgow WC, Sabiston CB (1975) Microorganisms from pulpal chambers of intact teeth with necrotic pulps. *Journal of Endodontics* **1**, 168–71.
- Yoshida M, Fukushima H, Yamada K, Ogawa K, Toda T, Sagawa H (1987) Correlation between clinical symptoms and microorganisms isolated from root canals of teeth with periapical pathosis. *Journal of Endodontics* **13**, 24–8.
- Zavistoski J, Dzink J, Onderdonk A, Bartlett J (1980) Quantitative bacteriology of endodontic infections. *Oral Surgery, Oral Medicine and Oral Pathology* **49**, 171–4.

This document is a scanned copy of a printed document. No warranty is given about the accuracy of the copy. Users should refer to the original published version of the material.