



CASE REPORT

Endodontic treatment of dens invaginatus type III with three root canals and open apical foramen

M. Jung

Policlinic for Operative and Preventive Dentistry, Justus-Liebig-University, Giessen, Germany

Abstract

Jung M. Endodontic treatment of dens invaginatus type III with three root canals and open apical foramen. *International Endodontic Journal*, **37**, 205–213, 2004.

Aim To describe the conservative endodontic treatment and the 1-year follow-up of a permanent maxillary lateral incisor with dens invaginatus.

Summary Frequently, the root canal treatment of invaginated teeth is challenging because of problems associated with gaining access to the root canals and with variations of canal morphology associated with this type of malformation. The present case describes the complex root canal treatment of dens invaginatus in a maxillary lateral incisor with three root canals (Oehler type III), incomplete apex formation, necrotic pulp and abscess formation. After gaining access to two root canals and the invagination with the help of a dental operating-microscope, the canals and the invagination were instrumented and calcium hydroxide dressing was applied for 6 months. Apexification and osseous bone repair were achieved, and the canals were filled with gutta-percha. A follow-up after 1 year showed that the tooth was free of any clinical symptoms and the periapical condition was normal.

Key learning points

- The present case demonstrates that conservative root canal treatment can be performed successfully even in severe cases of dens invaginatus.
- The use of a dental operating microscope can help in the management of complicated cases of invaginated teeth through conventional root canal treatment.

Keywords: apexification, case report, conservative endodontic treatment, dens invaginatus.

Received 2 June 2003; accepted 13 November 2003

Introduction

Dens invaginatus is a malformation occurring in permanent, deciduous (Holan 1998, Eden *et al.* 2002) or supernumerary teeth (Ruprecht *et al.* 1986, Serrano 1991, Jiménez-Rubio

Correspondence: Priv.-Doz. Dr Martin Jung, Policlinic for Operative and Preventive Dentistry, Faculty of Dentistry, Justus-Liebig-University, Schlangenzahl 14, D-35392 Giessen, Germany (Tel.: +49 641 9946187; fax: +49 641 9946169; e-mail: martin.jung@dentist.med.uni-giessen.de).

et al. 1997, Holtzman 1998). Dens invaginatus is of clinical relevance; its prevalence varies considerably and is estimated to range between 0.25 and 10% depending on the type of classification. Boyne (1952) reported the prevalence of dens invaginatus to be 0.4% of the examined teeth. Ruprecht *et al.* (1986) found 1.7% of the examined patients to have dental invagination, whereas 7.74% of the radiographic surveys (Thomas 1974) and 9.66% of the dental films (Gotoh *et al.* 1979) showed dens invaginatus. In another study (Ruprecht *et al.* 1987), the prevalence was reported to be 10% of the patients under examination.

The anomaly arises most commonly in the maxillary lateral incisor and less frequently in the central incisors. It also occurs in posterior teeth, extending from the occlusal pit. Bilateral occurrence of invaginated teeth (43%) is a frequent finding (Grahnen *et al.* 1959). A multiple occurrence of dens invaginatus has been reported (Jiménez-Rubio *et al.* 1997).

Because of its radiographic appearance, dens invaginatus is also referred to as 'dens in dente'; other terminology used for this type of malformation include dilated composite odontome (Hunter 1951), dents telescopes (Augsburger & Brandebura 1978) or gestant anomaly (Sousa & Bramante 1998).

Dens invaginatus is regarded as a developmental abnormality resulting from an invagination of the dental papilla during the soft-tissue stage of tooth formation. Early reports describing dens invaginatus were by Salter (1855) and by 'Socrates' (1856). Since that time, several theories have been proposed with respect to the aetiology of invaginated teeth. These include constriction of the dental arch on the enamel organ, a retardation or acceleration of growth of the internal enamel epithelium, a distortion of the enamel organ during tooth development or inadequate nutrition of a portion of a single tooth germ as causative factors (Sousa & Bramante 1998).

The clinical appearance of dens invaginatus varies considerably. The crown of affected teeth can be of normal morphology (Tarján & Rózsa 1999), but can also be associated with unusual forms, for example a greater labio-lingual diameter (Sousa & Bramante 1998), peg-shaped (Chen *et al.* 1998), barrel-shaped and conical (Sauveur *et al.* 1997), and talon cusp (Gonçalves *et al.* 2002). A deep foramen caecum might be a first clinical sign, indicating the presence of an invaginated tooth.

Deep invaginations are difficult to access and clean. Frequently, structural defects exist in the depth of invagination pits (Oehlers 1957). As a consequence, the early development of caries and the subsequent necrosis of the dental pulp, as well as abscess and cyst formation, are clinical implications associated with dens invaginatus. Several case reports seem to corroborate this assumption (Boyne 1952, Nedley & Powers 1997, Sauveur *et al.* 1997, Walvekar & Behbehani 1997, Holan 1998, Holtzman 1998, Pitt Ford 1998, Tarján & Rózsa 1999, Yeh *et al.* 1999, Eden *et al.* 2002, Girsch & McClammy 2002, Gonçalves *et al.* 2002, Tsurumachi *et al.* 2002). Furthermore displacement and retention of adjacent teeth have been described (Schaefer 1955). On the other hand, dens invaginatus has been questioned as a predilective site of caries (Gotoh *et al.* 1979), and the prevalence of apical pathosis in the teeth with dental invagination was not significantly different from a control group (Ruprecht *et al.* 1987).

In order to characterize the degree of malformation associated with dens invaginatus, the classification by Oehlers (1957) is widely used. Type I represents an enamel-lined invagination, remaining confined to the coronal part of the tooth; type II describes the extension of the invagination into the root, beyond the cemento-enamel junction, ending as a blind sac. The latter type may or may not communicate with the dental pulp. Type III includes penetration of the root by the invagination to form an additional apical or lateral foramen; usually, there is no communication with the dental pulp.

Dens invaginatus is diagnosed radiographically. Depending on the degree of malformation and on the presence of clinical symptoms, there are different treatment modalities.

Even without symptoms, dental treatment of dens invaginatus is considered necessary because access of irritants to the invagination may result in immediate or eventual contact with the dental pulp (Rotstein *et al.* 1987, Sousa & Bramante 1998). Prophylactic treatment of the invagination includes the application of fissure sealants. Conservative restorative therapy employs the placement of direct fillings (Szajkis & Kaufman 1993, Hülsmann 1997). The importance of follow-up is stressed because conservative and prophylactic treatment of invaginated teeth can be associated with a high failure rate of 11.3% (Ridell *et al.* 2001).

If prophylactic or restorative treatment is not possible, conventional root canal treatment is the method of choice (Hülsmann 1997, Sousa & Bramante 1998). Depending on the type and degree of malformation, endodontic therapy may be confined to the invagination, thus preserving the vitality of the pulp (Kaufman *et al.* 1984, Fristad & Molven 1998, Holtzman 1998, Pitt Ford 1998, Tarján & Rózsa 1999, Gonçalves *et al.* 2002). In other cases, therapy must include both the invagination and the root canals (Walvekar & Behbehani 1997, Chen *et al.* 1998, Yeh *et al.* 1999, Tsurumachi *et al.* 2002). The removal of the dens invaginatus with the help of an operating microscope and subsequent root canal treatment have also been described (Girsch & McClammy 2002).

If endodontic treatment fails or is deemed impossible, apical surgery is possible (Sauveur *et al.* 1997; Fröner *et al.* 1999). In severe cases, intentional reimplantation is proposed (Nedley & Powers 1997). Extraction of dens invaginatus is only indicated in supernumerary teeth or if endodontic therapy and apical surgery have failed or are not possible.

Report

A 12-year-old male was referred by his dentist because of pain and swelling arising from the maxillary right lateral incisor. The patient's medical history was noncontributory. The oral hygiene condition was moderate; the intraoral soft tissues were free of pathological signs except in the labial area of the maxillary right lateral incisor, where a slight swelling was noticed. The occlusion was normal with no missing teeth; the patient had no caries. All of the teeth except for the maxillary right lateral incisor responded normally to thermal stimulation. There were no dental restorations, but all of the first molars had fissure sealants.

The maxillary right lateral incisor did not respond to thermal stimulation and was tender to vertical percussion. There was no history of trauma; the periodontal probing depths were less than 3 mm. The clinical crown, especially the facio-palatal diameter, was larger compared to the lateral incisor on the left side (Fig. 1). The palatal surface was convex, and

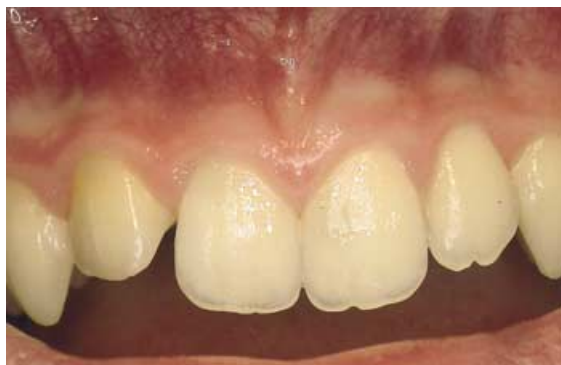

Figure 1 The maxillary right lateral incisor with dens invaginatus malformation; the clinical crown of the tooth is mildly barrel-shaped and larger than the contralateral incisor.

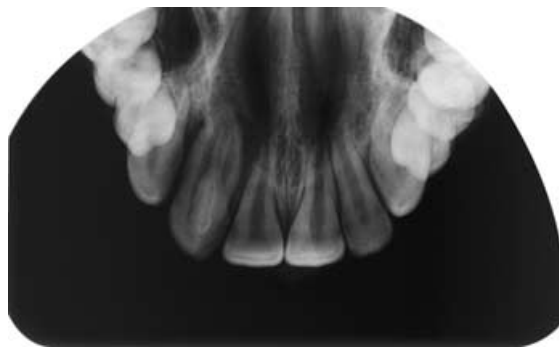


Figure 2 Occlusal radiograph showing the dens invaginatus malformation of the upper right lateral incisor; the left lateral incisor has no signs of pathology or malformation.

the foramen caecum was represented by a black spot. Radiographic examination of the maxillary anterior teeth exhibited dens invaginatus of the right lateral incisor. The left lateral and central incisors were normal (Fig. 2). A periapical radiograph of the right lateral incisor revealed an invagination extending to the apex, incomplete apex formation and a periapical radiolucency (Fig. 3).

A diagnosis of dens invaginatus (Oehlers type III) with apical pathosis and submucous abscess formation was established. The patient and his parents were informed of the long-term prognosis of the tooth, and a decision was made to perform conventional root canal treatment.

After local anaesthesia, incision and drainage of the abscess, the acute symptoms and signs subsided within 1 day. During the following appointment, the tooth was isolated with rubber dam, and access to the invagination and one regular root canal was gained. After copious irrigation with H_2O_2 (3%) and NaOCl (5%), $\text{Ca}(\text{OH})_2$ (Calxyl, OCO Products, Dirnstein, Germany) was used as a temporary dressing, and the tooth was restored with Cavit W (3M Espe, Seefeld, Germany). Ten days later, an opening to a third canal was

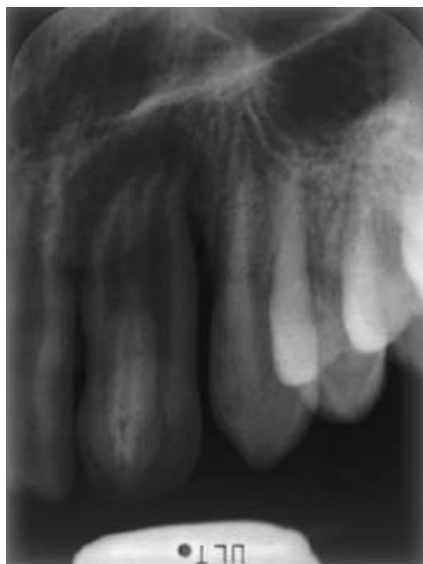

Figure 3 Dental radiograph of the right lateral incisor revealing an invagination extending to the apex and forming a separate foramen.

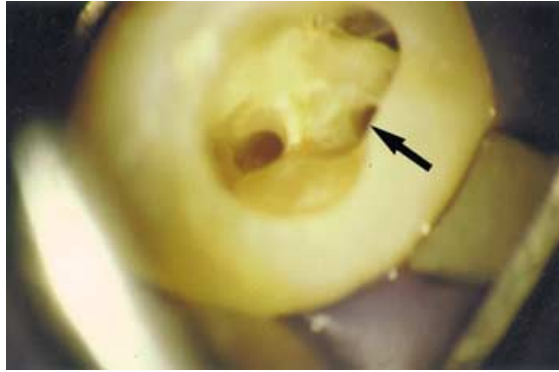


Figure 4 The configuration of the three canals of dens invaginatus through the operating microscope: two regular root canals laterally and the invagination (arrow) in the middle at the palatal margin.

detected, which was identified as a second regular canal (Fig. 4) with the help of the dental operating microscope OPMI S151 (Carl Zeiss, Oberkochen, Germany). Access to the three canals was widened using ProFile O.S. nos. 2 and 3 (Dentsply Maillefer, Ballaigues, Switzerland). The working length of the three canals was established radiographically (Fig. 5), and the canals were shaped to size 40 (master apical file) with stepback performed to size 55 (final file). After irrigation with H_2O_2 and NaOCl, the canals were dried but a persistent exudate from the apical region into the regular root canals was noticed. Again, Calxyl was placed into the canals as a dressing, and the access opening was filled with glass-ionomer cement (Ketac-fil, 3M Espe). After 4 weeks, the $Ca(OH)_2$ dressing was changed. Two months later, the tooth was reopened and the canals were irrigated and dried. Exudate had decreased, and after the placement of another Calxyl dressing, the tooth was closed with Ketac-fil for another 3 months. When the patient returned, the exudate had stopped and it was noticed clinically that the root canals were not accessible any more to the complete working length. A radiographic control revealed the formation of a hard-tissue barrier at the apex. The periapical radiolucent area had disappeared, and osseous repair was

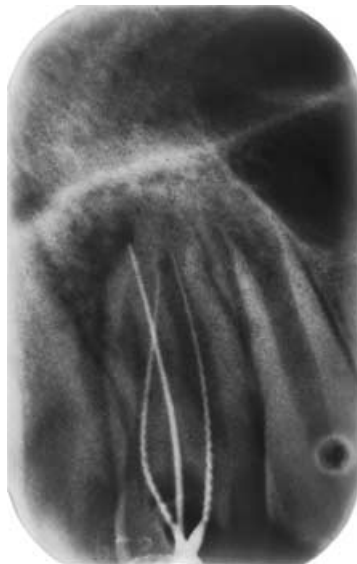

Figure 5 Radiographic assessment of the working length with two H-files of ISO-size 15 in the regular canals and one K-file (size 20) in the invagination canal.

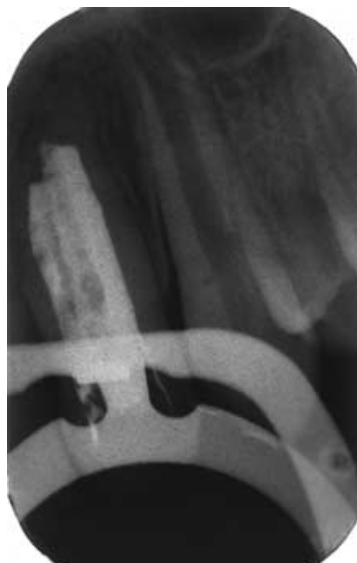


Figure 6 Dental film after obturation of the three canals with gutta-percha and sealer; apical hard-tissue formation (apexification) is confirmed.

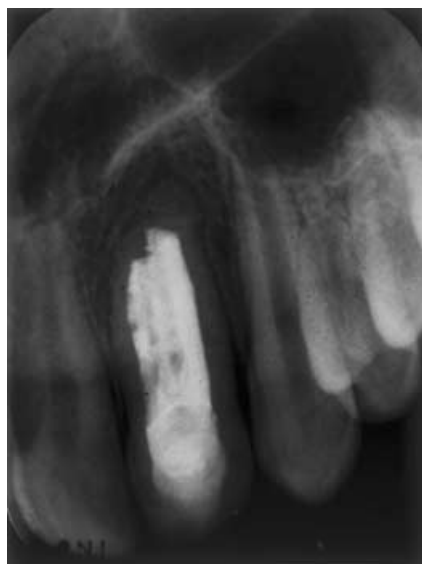

Figure 7 Radiographic follow-up of the invaginated lateral incisor after 1 year shows that apical conditions are normal.

evident. After applying AH Plus (Dentsply Maillefer) as a sealer, the root canals were filled with gutta-percha using a standard lateral condensation technique. A periapical radiograph showed that the canals were filled to the level of the newly formed apical barrier (Fig. 6). A Ketac-fil base was placed, and the access cavity was restored with a composite restoration (Herculite XRV, Kerr Manufacturing Company, Romulus, MI, USA). After 1 year, the patient returned for a follow-up examination. The tooth was free of pain, and clinical conditions were normal with respect to percussion and probing depth. A periapical radiograph showed no signs of apical pathosis (Fig. 7).

Discussion

Root canal treatment of invaginated teeth is frequently associated with problems arising from complex variations of root canal morphology or from a difficult access to the regular and invaginated canals (Hülsmann 1997, Sousa & Bramante 1998). This was also true in the present case. Two canal orifices, one regular and one invagination opening, were found without additional help. However, a third canal, which was located mesially, was detected with a dental operating microscope. The benefits of using a microscope when treating dens invaginatus have been emphasized by Girsch & McClammy (2002). Another factor, which impeded root canal treatment, was the incomplete apex formation of the maxillary lateral incisor at the beginning of the treatment. Probably, the development of periapical inflammation and necrosis of the pulp had inhibited regular root completion.

An incomplete apex may lead to problems with respect to overfilling or with respect to achieving an apical seal. In these cases, Ca(OH)_2 is recommended as an intracanal dressing (Tarján & Rózsa 1999, Yeh *et al.* 1999). Apart from its antimicrobial activity and lipopolysaccharide detoxification (Sjögren *et al.* 1991, Safavi & Nichols 1994), Ca(OH)_2 encourages apexification (Tarján & Rózsa 1999, Yeh *et al.* 1999, Gonçalves *et al.* 2002). In the current case, apexification was impeded by apical inflammation leading to continuing exudation into the root canals. This required repeated changes of the Ca(OH)_2 dressing over a 6-month period until apexification occurred.

The current case of dens invaginatus was classified as Oehlers type III because the radiographic examination showed that the invagination extended through the complete root canal and had formed an additional apical foramen. Thus, without any history of caries or trauma, irritants and microorganisms from the oral cavity had access to the apical tissue and caused inflammation. It is likely that the pulp became necrotic in a second step by retrograde infection. However, direct infection of the pulp through communication with the invagination canal cannot be completely excluded.

Whereas in some cases the isolated endodontic treatment of the invagination canal had been sufficient and maintained the vitality of the pulp (Fristad & Molven 1998, Holtzman 1998, Pitt Ford 1998, Gonçalves *et al.* 2002), this was not possible in the case presented here as there was pulpal necrosis at the time of initial presentation.

Dens invaginatus is a phenomenon that frequently occurs bilaterally. In this case, radiographic examination proved that only one lateral incisor in the maxilla was affected.

The conventional root canal treatment of dens invaginatus with two canals has been described frequently (Chen *et al.* 1998, Yeh *et al.* 1999, Tsurumachi *et al.* 2002). Root canal treatment of dens invaginatus with incomplete root formation has proved to be successful (Ferguson *et al.* 1980, Tarján & Rózsa 1999, Yeh *et al.* 1999). The present case demonstrates that root canal treatment of dens invaginatus can be successful in more complicated cases characterized by an invagination extending to the apex, two root canals with incomplete apex formation, and loss of vitality together with the presence of periapical inflammation and abscess formation.

Conclusions

Conventional root canal treatment can be performed even in complicated cases of dens invaginatus. The use of an operating microscope facilitates the identification of the complex anatomy in such cases.

Disclaimer

Whilst this clinical article has been subjected to Editorial review, the opinions expressed, unless specifically indicated, are those of the author. The views expressed do not

necessarily represent best practice, or the view of the IEJ Editorial Board, or of its affiliated Specialist Societies.

References

- Augsburger R, Brandebura J (1978) Bilateral dens invaginatus with associated radicular cysts. *Oral Surgery, Oral Medicine, Oral Pathology* **46**, 260–4.
- Boyne PJ (1952) Dens in dente: report of three cases. *Journal of the American Dental Association* **45**, 208–9.
- Chen YHM, Tseng CC, Harn WM (1998) Dens invaginatus. *Oral Surgery, Oral Medicine, Oral Pathology, Oral Radiology and Endodontics* **86**, 347–52.
- Eden EK, Koca H, Sen BH (2002) Dens invaginatus in a primary molar: report of case. *Journal of Dentistry for Children* **69**, 49–53.
- Ferguson FS, Friedman S, Frazzto V (1980) Successful apexification technique in an immature tooth with dens in dente. *Oral Surgery, Oral Medicine, Oral Pathology* **49**, 356–9.
- Fristad I, Molven O (1998) Root resorption and apical breakdown during orthodontic treatment of a maxillary lateral incisor with dens invaginatus. *Endodontics and Dental Traumatology* **14**, 241–4.
- Fröner IC, da Costa Rocha LF, da Costa WF, da Rocha Barros VM, Morello D (1999) Complex treatment of dens invaginatus type III in maxillary lateral incisor. *Endodontics and Dental Traumatology* **15**, 88–90.
- Girsch WJ, McClammy TV (2002) Microscopic removal of dens invaginatus. *Journal of Endodontics* **28**, 336–9.
- Gonçalves A, Gonçalves M, Oliveira DP, Gonçalves N (2002) Dens invaginatus type III: report of a case and 10-year radiographic follow-up. *International Endodontic Journal* **35**, 873–9.
- Gotoh T, Kawahara K, Imai K, Kishi K, Fujiki Y (1979) Clinical and radiographic study of dens invaginatus. *Oral Surgery, Oral Medicine, Oral Pathology* **48**, 81–91.
- Grahnén H, Lindahl B, Omnell K (1959) Dens invaginatus. I. A clinical, roentgenological and genetical study of permanent upper lateral incisors. *Odontologisk Revy* **10**, 115–37.
- Holan G (1998) Dens invaginatus in a primary canine: a case report. *International Journal of Paediatric Dentistry* **8**, 61–4.
- Holtzman L (1998) Conservative treatment of supernumerary maxillary incisor with dens invaginatus. *Journal of Endodontics* **24**, 378–80.
- Hülsmann M (1997) Dens invaginatus: aetiology, classification, prevalence, diagnosis and treatment considerations. *International Endodontic Journal* **30**, 79–90.
- Hunter HA (1951) Dilated composite odontome. *Oral Surgery, Oral Medicine, Oral Pathology* **4**, 668–73.
- Jiménez-Rubio A, Segura JJ, Jiménez-Planas A, Llamas R (1997) Multiple dens invaginatus affecting maxillary lateral incisors and a supernumerary tooth. *Endodontics and Dental Traumatology* **13**, 196–8.
- Kaufman AY, Kaffe I, Littner MM (1984) Vitality preservation of an anomalous maxillary central incisor after endodontic therapy. *Oral Surgery, Oral Medicine, Oral Pathology* **57**, 668–72.
- Nedley MP, Powers GK (1997) Intentional extraction and reimplantation of an immature invaginated central incisor. *Journal of Dentistry for Children* **64**, 417–20.
- Oehlers FAC (1957) Dens invaginatus (dilated composite odontome). *Oral Surgery, Oral Medicine, Oral Pathology* **10**, 1204–18.
- Pitt Ford HE (1998) Peri-radicular inflammation related to dens invaginatus treated without damaging the dental pulp: a case report. *International Journal of Paediatric Dentistry* **8**, 283–6.
- Ridell K, Mejäre I, Matsson L (2001) Dens invaginatus: a retrospective study of prophylactic invagination treatment. *International Journal of Paediatric Dentistry* **11**, 92–7.
- Rotstein I, Stabholz A, Heling I, Friedman S (1987) Clinical considerations in the treatment of dens invaginatus. *Endodontics and Dental Traumatology* **3**, 249–54.
- Ruprecht A, Batniji S, Sastry KARH, El-Newehi E (1986) The incidence of dental invagination. *Journal of Pedodontics* **10**, 265–72.
- Ruprecht A, Sastry KARH, Batniji S, Lambourne A (1987) The clinical significance of dental invagination. *Journal of Pedodontics* **11**, 176–81.

- Safavi KE, Nichols FC (1994) Alteration of biological properties of bacterial lipopolysaccharide by calcium hydroxide treatment. *Journal of Endodontics* **20**, 127–9.
- Salter SJA (1855) Warty teeth. *Transactions of the Pathological Society of London* **6**, 173–7.
- Sauveur G, Roth F, Sobel M, Boucher Y (1997) Surgical treatment of a periradicular lesion on an invaginated maxillary lateral incisor (dens in dente). *International Endodontic Journal* **30**, 145–9.
- Schaefer H (1955) Zur Klinik des dens in dente. *Deutsche Zahnärztliche Zeitschrift* **10**, 988–93.
- Serrano J (1991) Triple dens invaginatus in a mesiodens. *Oral Surgery, Oral Medicine, Oral Pathology, Oral Radiology and Endodontics* **71**, 648–9.
- Sjögren U, Figdor D, Spangberg L, Sundqvist G (1991) The antimicrobial effect of calcium hydroxide as a short-term intracanal dressing. *International Endodontic Journal* **24**, 119–25.
- Socrates (1856) Tooth within a tooth. *Dental Register of the West* **10**, 355–6.
- Sousa SMG, Bramante CM (1998) Dens invaginatus: treatment choices. *Endodontics and Dental Traumatology* **14**, 152–8.
- Szajkis S, Kaufman AY (1993) Root invagination treatment: a conservative approach in endodontics. *Journal of Endodontics* **19**, 576–8.
- Tarján I, Rózsa N (1999) Endodontic treatment of immature tooth with dens invaginatus: a case report. *International Journal of Paediatric Dentistry* **9**, 53–6.
- Thomas JG (1974) A study of dens in dente. *Oral Surgery, Oral Medicine, Oral Pathology* **38**, 653–5.
- Tsurumachi T, Hayashi M, Takeichi O (2002) Non-surgical root canal treatment of dens invaginatus type 2 in a maxillary lateral incisor. *International Endodontic Journal* **35**, 309–14.
- Walvekar SV, Behbehani JM (1997) Three root canals and dens formation in a maxillary lateral incisor: a case report. *Journal of Endodontics* **23**, 185–6.
- Yeh SC, Lin YT, Lu SY (1999) Dens invaginatus in the maxillary lateral incisor. *Oral Surgery, Oral Medicine, Oral Pathology, Oral Radiology and Endodontics* **87**, 628–31.

This document is a scanned copy of a printed document. No warranty is given about the accuracy of the copy. Users should refer to the original published version of the material.