
A comparison between clearing and radiographic techniques in the study of the root-canal anatomy of maxillary first and second molars

O. E. Omer, R. M. Al Shalabi, M. Jennings, J. Glennon & N. M. Claffey

Department of Restorative Dentistry and Periodontology, School of Dental Science, Trinity College, Dublin, Ireland

Abstract

Omer OE, Al Shalabi RM, Jennings M, Glennon J, Claffey NM. A comparison between clearing and radiographic techniques in the study of the root-canal anatomy of maxillary first and second molars. *International Endodontic Journal*, **37**, 291–296, 2004.

Aim To compare a clearing technique with conventional radiography in studying certain features of the root-canal system of maxillary right first and second molars. A secondary aim was to assess interexaminer agreement for these features using radiographs.

Methodology Eighty-three recently extracted permanent maxillary right first molars and 40 recently extracted maxillary right second molars from an Irish population were included. Standard periapical radiographs were taken from a buccolingual and mesiodistal direction. The specimens were then decoronated, demineralized in 10% hydrochloric acid for 8 days and then cleared using methyl salicylate. The cleared teeth were examined using a dissecting microscope ($\times 20$), and data relating to number of roots, canal type following Vertucci's classification, presence of lateral canals, presence of transverse anastomoses and position/number of apical foramina were collected. The radiographs were examined by two independent trained endodontists

using an X-ray viewer and a magnifying lens ($\times 2$) in a dark room for the same features studied using the clearing technique.

Results The Kappa values for the agreement between the radiographic examiners A and B and the clearing technique and between the two examiners for the number of roots were 0.60, 0.64 and 0.53; for the root-canal type, 0.37, 0.41 and 0.42; for the number of roots with lateral canals, 0.21, 0.18 and 0.14; and for the transverse anastomoses, 0.29 for radiographic Examiner A. Radiographic Examiner B did not feel capable of accurately recognizing transverse anastomoses from the radiographs. For the position/number of apical foramina, the Kappa values were 0.33 and 0.24, respectively. In general, the Kappa values were low to modest for all comparisons.

Conclusions It is concluded that the agreement between the two radiographic examiners and the agreement between either radiographic examiner and the clearing technique were poor to moderate, indicating the limited value of radiographs alone when studying certain aspects of the root-canal system.

Keywords: clearing technique, radiography, root-canal anatomy.

Received 29 July 2002; accepted 21 July 2003

Introduction

Successful root-canal treatment depends on adequate cleaning, shaping and filling of the root-canal system.

However, in order to achieve this, it is imperative that the operator has a detailed knowledge of the root-canal morphology of each individual tooth being treated.

Conventional radiography has traditionally been used in the various stages of root-canal treatment. However, whilst conventional radiography may demonstrate the main features, it is unlikely to show the complexities of root-canal anatomy. Previous studies have suggested that radiographic images are not reliable in the detection

Correspondence: Dr O. E. Omer, Department of Restorative Dentistry & Periodontology, School of Dental Science, Trinity College, Dublin, Ireland (Tel.: +353 1 6127312; fax: +353 1 6127297; e-mail: oomer@tcd.ie).

of multiple canals (Nattress & Martin 1991) and lateral canals (Altman *et al.* 1970), and could not distinguish centrally placed apical foramina from those eccentrically located (Blaskovich-Subat *et al.* 1992). In general, discrepancies were found in results between *in vitro* and *in vivo* studies of root-canal anatomy (Pomeranz & Fishelberg 1974, Ibarrola *et al.* 1997). Additionally, radiographs were also reported to be open to a wide range of interpretations in assessing the success of endodontic treatment (Goldman *et al.* 1972; 1974). In comparison, the technique of clearing teeth has considerable value in studying the anatomy of the root-canal system because unlike radiographic images, it gives a three-dimensional view of the pulp cavity in relation to the exterior of the teeth and allows a thorough examination of the pulp chambers and root canals (Barker *et al.* 1969, Vertucci 1978, Walker 1988, Saunders & Saunders 1992, Ibarrola *et al.* 1997, Gulabivala *et al.* 2001). The clearing technique was also used in the study of apical leakage (Scott *et al.* 1989). However, the clearing technique remains useful only as a teaching/research tool with little or no clinical applicability.

The aim of this investigation was to compare a clearing technique with conventional radiography in studying certain features of the root-canal system. A secondary aim was to assess interexaminer agreement for these features using radiographs.

Materials and methods

Eighty-three recently extracted permanent maxillary right first molars and 40 recently extracted maxillary right second molars from an Irish population, sequentially attending the Accident and Emergency Department in the Dublin Dental Hospital, were included in this investigation. Ethnicity was confirmed by questioning.

The extracted teeth were fixed in 10% formal saline, placed into small containers and labelled for identification. Standard periapical views were taken of all the teeth using an apparatus similar to that described by Walker (1986). The apparatus consisted essentially of a Perspex base upon which were mounted a standard film-holding device, a beam-aiming device and a support for the tooth to be radiographed. Each tooth was secured to the mounting table using beading wax and oriented in a standard position by placing the buccal groove in relation to a mark on the table that corresponded to the pointer on the apparatus registering 90° on the protractor attached to the Perspex base. The first radiograph for each tooth was taken in a buccolingual direction;

the pointer was then positioned at 125°, and a second radiograph was taken in a mesiodistal direction. The films used were Kodak 'EKTASPEED' (Eastman Kodak, NY, USA) and were exposed for 0.25 s using an X-ray machine (Gendex Dental system, Monza, Italy) set at 65 kV and 7.5 mA. All teeth were radiographed using a 16-cm cone, the end of which was standardized at 70 mm from the tooth. All exposed films were developed and fixed in an automatic processor (Durr-Dental, Bissingen, Germany).

The teeth were then decoronated at the amelocemental junction; organic debris was removed from the canal system by placing the teeth in 5% sodium hypochlorite solution for 24 h, washed under running water and allowed to dry for 24 h. India ink was then drawn through the canal system by applying negative pressure at the apical end. The teeth were then decalcified in 10% hydrochloric acid for 8 days at room temperature, and complete decalcification was verified by taking radiographs of the teeth, which were then dehydrated in successive solution of 95% alcohol for 36 h followed by 100% alcohol for further 36 h. The teeth were then placed in methyl salicylate, which rendered them transparent.

The cleared teeth were examined under a dissecting microscope (×20), and data relating to number of roots, canal type, presence of lateral canals, presence of transverse anastomoses and apical foramina position/number were collected using a standard format. The classification of the root-canal system used was based on that described by Vertucci (1984), as detailed in Fig. 1.

The radiographs were examined by two independent trained endodontists, other than the investigator who evaluated the cleared specimens, using an X-ray viewer and magnifying lens (×2) in a dark room. They were asked to collect data relating to the number of roots and the root-canal system, using similar format as that used for the cleared teeth. The data collected by the endodontists from the radiographs were compared to that obtained using the clearing technique. If any one endodontist was reluctant to interpret anatomical features because of lack of clarity in the radiographic image, the data for the comparisons affected were excluded.

All data were entered in a spreadsheet (Excel, Microsoft Corporation, WA, USA). Kappa values for agreement for the presence or absence of root-canal features between the outcome of the clearing technique examination compared to the radiographic examinations and between the two radiographic examiners were computed.

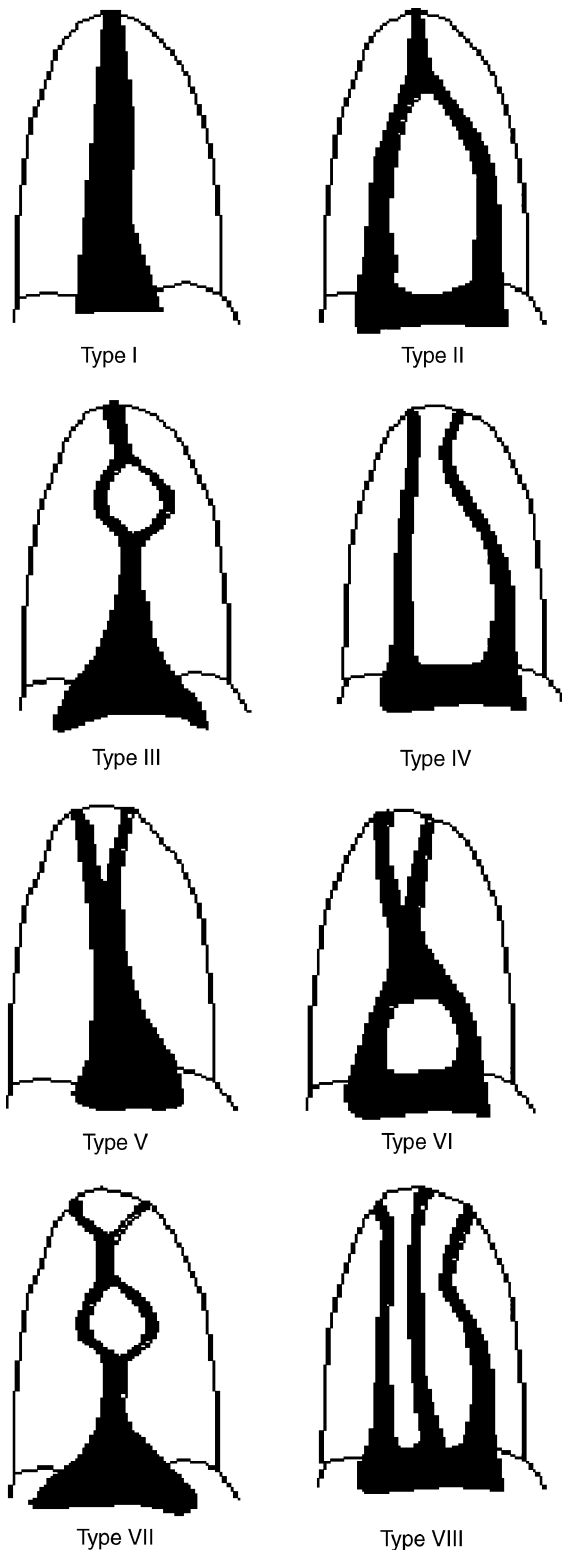


Figure 1 Vertucci's classification of the root-canal system.

Results

Number of roots

The number of teeth with two and three roots detected by the clearing technique and radiographic examination (examiners A and B) are detailed in Tables 1 and 2. The agreement between radiographic Examiner A and radiographic Examiner B is detailed in Table 3. The kappa levels indicated a moderate level of agreement between the clearing technique and either radiographic Examiner A or radiographic Examiner B ($\kappa = 0.60$ and 0.64 , respectively) and as a poorer value between the two radiographic examiners ($\kappa = 0.53$).

Table 1 Agreement between the clearing technique and radiographic examination (Examiner A) for the number of roots detected

	Clearing technique		
	Two roots	Three roots	Total
Radiographic examination			
Two roots	7	8	15
Three roots	0	101	101
Total	7	109	116
κ	0.60		
SE	0.12		

Table 2 Agreement between the clearing technique and the radiographic examination (Examiner B) for the number of roots detected

	Clearing technique		
	Two roots	Three roots	Total
Radiographic examination			
Two roots	5	2	7
Three roots	3	97	100
Total	8	99	107
κ	0.64		
SE	0.15		

Table 3 Agreement between radiographic Examiner A and radiographic Examiner B for the number of roots detected

	Examiner A		
	Two roots	Three roots	Total
Examiner B			
Two roots	6	0	6
Three roots	9	88	97
Total	15	88	103
κ	0.53		
SE	0.13		

Table 4 Agreement between the clearing technique and the radiographic examination (Examiner A) for the types of canals detected

	Clearing technique						Total
	I	II	III	IV	V	VI	
Radiographic examination							
I	238	11	1	11	6	6	273
II	2	2	0	8	3	7	22
III	0	1	0	3	0	0	4
IV	2	0	0	8	1	2	13
V	3	0	0	5	2	1	11
VI	0	1	0	1	0	2	4
Total	245	15	1	36	12	18	327
κ	0.37						
SE	0.04						

Table 5 Agreement between the clearing technique and the radiographic examination (Examiner B) for the types of canals detected

	Clearing technique					Total
	I	II	III	IV	V	
Radiographic examination						
I	245	11	1	16	10	283
II	1	3	0	5	1	10
III	2	0	0	0	0	2
IV	0	1	0	14	1	16
V	1	0	0	1	1	3
Total	249	15	1	36	13	314
κ	0.41					
SE	0.06					

Root-canal type

Tables 4 and 5 display the result for agreement between the clearing technique and radiographic examination (examiners A and B). The low Kappa values obtained indicated a poor level of agreement ($\kappa = 0.37$ and 0.41 , respectively). Table 6 displays the result for agreement

Table 6 Agreement between radiographic Examiner A and radiographic Examiner B for root-canal type

	Examiner A					Total
	I	II	III	IV	V	
Examiner B						
I	253	10	1	4	5	273
II	5	2	2	0	0	9
III	1	0	0	0	1	2
IV	3	3	0	7	1	14
V	0	0	0	0	3	3
Total	262	15	3	11	10	301
κ	0.42					
SE	0.07					

between radiographic Examiner A and radiographic Examiner B. The Kappa value was also low, indicating a poor level of agreement ($\kappa = 0.42$).

Number of roots with lateral canals

The number of roots with lateral canals found by radiographic Examiner A was 36 whereas the number disclosed by the clearing technique was 67. The Kappa value ($\kappa = 0.21$) was low, indicating a poor level of agreement. The number of roots with lateral canals found by radiographic Examiner B was 98. However, as was the case with radiographic Examiner A, the Kappa value was low ($\kappa = 0.18$), indicating a low level of agreement. The level of agreement between the two examiners with respect to the presence of lateral canals was poor ($\kappa = 0.14$).

Number of roots with transverse anastomoses

The number of roots with transverse anastomoses reported by radiographic Examiner A was 11 whereas the number disclosed by the clearing technique was 37. The Kappa value was low ($\kappa = 0.29$), indicating a poor level of agreement. The radiographic Examiner B did not feel capable of accurately recognizing transverse anastomoses, and hence no further analysis was carried out.

Position/number of apical foramina

The number of roots with central apical foramina found by radiographic examiners A and B were 168 and 284, respectively, whilst that disclosed by the clearing technique was 146. The Kappa values (0.33 and 0.24) were low, indicating a poor level of agreement between the clearing technique and the radiographic examination.

Discussion

Conventional radiography is commonly used in the various stages of endodontic treatment notwithstanding the numerous shortcomings of this method. These include the fact that a radiographic image is a two-dimensional representation for a three-dimensional object and that it is open to a wide range of interpretations (Goldman *et al.* 1972).

The dental X-ray films used in this investigation (Kodak EKTASPEED, Eastman Kodak, NY, USA) were chosen because they are routinely used in clinical endodontics, although it could be argued that D-speed films,

which expose subjects to higher levels of radiation, may have provided higher resolution (Ludlow & Platin 1995, Price 1995, Svenson *et al.* 1997).

The agreement between the clearing technique results and either radiographic Examiner A or radiographic Examiner B were mostly low. In general, the kappa values were poor to modest for all comparisons. These Kappa values can then be interpreted as indicating that neither radiographic examiner was reliable in reflecting the morphological characteristics determined using the clearing technique.

It was of interest to note in relation to roots with transverse anastomoses that radiographic Examiner A reported 11 roots with transverse anastomoses whilst radiographic Examiner B failed to detect any roots with transverse anastomoses. The number of such roots disclosed using the clearing technique was 37. This indicates the wide range of interpretations to which radiographic images are prone. Of all the features studied, the least agreement between the two radiographic examiners and the clearing technique appeared to be in relation to the presence of lateral canals ($\kappa = 0.21$ and 0.18) and the highest was in relation to the number of roots present ($\kappa = 0.60$ and 0.64). The high agreement in relation to the number of the roots present could be attributed to an understandable bias of the examiners that these teeth morphotypes generally have three roots and possibly to the ease of detecting this feature radiographically compared to the other less easily detectable features of the root-canal system studied.

It was also of interest to note the relatively poor agreement between radiographic Examiner A and radiographic Examiner B for all variables compared, in spite of the examination of standardized radiographs of each tooth exposed at different angles *in vitro*. This, combined with the fact that neither radiographic examiner had high levels of agreement with the results of the clearing technique, would tend to suggest that the inability of radiographic technique and interpretation to describe root-canal morphology results from a deficiency in the technique. Other studies, albeit using different tooth morphotypes and study designs, have, in general, reported similar limitations of radiographs in studying certain features of the root-canal system (Altman *et al.* 1970, Goldman *et al.* 1972; 1974, Pineda & Kuttler 1972, Pineda 1973, Nattress & Martin 1991).

A limitation of the study was the lack of data on intraexaminer reproducibility, although it could be argued that trained/experienced endodontists are relatively consistent in radiographic interpretation. It is important to note that the clearing technique is a teach-

ing/research tool and has little or no clinical applicability. However, although radiographs remain important in clinical endodontics, their limitations in defining certain aspects of root-canal anatomy are noteworthy.

Conclusions

It is concluded that the agreement between the two radiographic examiners and the agreement between either radiographic examiner and the clearing technique were, in most cases, poor to moderate. This indicates some limitations in the value of radiographs alone in describing certain aspects of root-canal morphology. However, the clearing technique remains useful only as a teaching/research tool with little or no clinical applicability.

Acknowledgements

The authors wish to acknowledge the help of Dr A. Kelly with the statistical analysis of the data and Mrs A. Hagan for the secretarial help when preparing this paper.

References

- Altman M, Guttuso J, Seidberg BH, Langeland K (1970) Apical root canal anatomy of human maxillary central incisors. *Oral Surgery, Oral Medicine and Oral Pathology* **30**, 694–9.
- Barker BCW, Locket BC, Parsons KC (1969) The demonstration of root canal anatomy. *Australian Dental Journal* **14**, 37–41.
- Blaskovich-Subat V, Maricic B, Sutalo J (1992) Asymmetry of the root canal foramen. *International Endodontics Journal* **25**, 158–64.
- Goldman M, Pearson AH, Darzenta N (1972) Endodontic success – who's reading the radiograph? *Oral Surgery, Oral Medicine and Oral Pathology* **33**, 432–7.
- Goldman M, Pearson AH, Darzenta N (1974) Reliability of radiographic interpretations. *Oral Surgery, Oral Medicine and Oral Pathology* **38**, 287–93.
- Gulabivala K, Aung TH, Alavi A, Ng YL (2001) Root canal morphology of Burmese mandibular molars. *International Endodontic Journal* **33**, 359–70.
- Ibarrola JL, Knowles KL, Ludlow MO, McKinley IB (1997) Factors affecting the negotiability of second mesiobuccal canals in maxillary molars. *Journal of Endodontics* **23**, 236–8.
- Ludlow JB, Platin E (1995) Densitometric comparisons of Ultraspeed, Ektaspeed and Ektaspeed plus intraoral films for two processing conditions. *Oral Surgery, Oral Medicine, Oral Pathology, Oral Radiology and Endodontics* **79**, 105–13.
- Nattress BR, Martin DM (1991) Predictability of radiographic diagnosis of variation in root canal anatomy in mandibular incisor and premolar teeth. *International Endodontics Journal* **24**, 58–62.

- Pineda F (1973) Roentgenographic investigation of the mesio-buccal root of the maxillary first molar. *Oral Surgery, Oral Medicine and Oral Pathology* **36**, 253–60.
- Pineda F, Kuttler Y (1972) Mesiodistal and buccolingual roentgenographic investigation of 7,275 root canals. *Oral Surgery, Oral Medicine and Oral Pathology* **33**, 101–10.
- Pomeranz H, Fishelberg G (1974) The second mesiobuccal canal of maxillary molars. *Journal of the American Dental Association* **88**, 119–24.
- Price C (1995) Sensitometric evaluation of a new E speed dental radiographic film. *Dentomaxillofacial Radiology* **24**, 30–6.
- Saunders WP, Saunders EM (1992) Effect of non-cutting tipped instruments on the quality of root canal preparation using a modified double-flared technique. *Journal of Endodontics* **18**, 32–6.
- Scott GM, Garry RH, Frank RP (1989) Does cold burnishing gutta-percha create a better apical seal. *Journal of Endodontics* **15**, 204–9.
- Svenson B, Welander U, Shi X-Q, Stamatakis H, Tronje G (1997) A sensitometric comparison of four dental X-ray films and their diagnostic accuracy. *Dentomaxillofacial Radiology* **26**, 230–5.
- Vertucci FJ (1978) Root canal morphology of mandibular premolars. *Journal of the American Dental Association* **97**, 47–50.
- Vertucci FJ (1984) Root canal anatomy of the human permanent teeth. *Oral Surgery, Oral Medicine and Oral Pathology* **58**, 589–99.
- Walker RT (1986) Device for the radiographic examination of teeth *in vitro*. *International Endodontics Journal* **19**, 315–7.
- Walker RT (1988) The root canal anatomy of mandibular incisors in a Southern Chinese population. *International Endodontics Journal* **21**, 218–23.

This document is a scanned copy of a printed document. No warranty is given about the accuracy of the copy. Users should refer to the original published version of the material.