

# Root canal morphology of mandibular incisors in a Jordanian population

A. A. Al-Qudah & L. A. Awawdeh

Faculty of Dentistry, Department of Restorative Dentistry, Jordan University of Science and Technology, Irbid, Jordan

## Abstract

**Al-Qudah AA, Awawdeh LA.** Root canal morphology of mandibular incisors in a Jordanian population. *International Endodontic Journal*, **39**, 873–877, 2006.

**Aim** To investigate the root canal morphology of mandibular incisors in a Jordanian population using a canal staining and tooth-clearing technique.

**Methodology** Four hundred and fifty extracted mandibular incisors were collected from dental clinics within north Jordan. Following pulp tissue removal and staining of the canal systems, the teeth were decalcified with 5% nitric acid, dehydrated with ascending concentrations of alcohol and rendered clear by immersion in methyl salicylate. Cleared teeth were examined by eye and the following features were evaluated:

(i) number and type of root canals; (ii) presence and location of lateral canals and intercanal communications; (iii) location of apical foramina; and (iv) frequency of apical deltas.

**Results** The majority of mandibular incisors had a single canal (73.8% of teeth possessed a Type I canal system). Although 26.2% of the roots possessed two canals, only 8.7% had two separate apical foramina.

**Conclusions** The prevalence of two canals in this group of mandibular incisors was 26.2% and is within the range of previous studies performed on populations of different racial origin.

**Keywords:** mandibular incisors, morphology, root canal.

Received 19 February 2006; accepted 27 April 2006

## Introduction

A clear knowledge of the anatomy of root canal systems is an essential prerequisite to carrying out root canal preparation. Many of the problems encountered during root canal treatment occur because of inadequate understanding of the pulp space anatomy. This applies to mandibular incisor teeth as many dentists fail to recognize the presence of a second canal.

Current knowledge of pulp space anatomy is based on research findings and individual case reports. Many studies have examined the root canal systems of mandibular incisors. Rankine-Wilson & Henry (1965) filled the root canals of mandibular anterior teeth with radio-opaque material, sectioned them in a horizontal

plane, and exposed radiographs. They reported two canals in 40.5% of mandibular incisors. Later, Vertucci (1974) used the clearing technique to study the root canal morphology of 300 extracted mandibular anterior teeth. Two canals were found in 30% of mandibular central incisors and in 25% of mandibular lateral incisors. Mauger *et al.* (1998) evaluated the canal morphology at different root levels in one hundred mandibular incisors and reported that 98–100% of the teeth had one canal in the area 1–3 mm from the apex.

There is a lack of consistency in the reported prevalence of second canals in mandibular incisors (Vertucci 1974, Kaffe *et al.* 1985, Walker 1988, Mauger *et al.* 1998, Sert *et al.* 2004). The differences may be related to study design (*in vivo* versus *ex vivo*), technique of canal identification (radiographic examination, sectioning and clearing) or to racial divergence. Many studies have reported that root canal systems vary according to race (Walker 1988, Haddad *et al.* 1999, Weine *et al.* 1999, Sert & Bayirli 2004).

Correspondence: Dr Aladdin Al-Qudah, Faculty of Dentistry, Department of Restorative Dentistry, Jordan University of Science and Technology, PO Box 3030, 22110 Irbid, Jordan (Fax: +962 2 7095115; e-mail: aqudah@just.edu.jo).

Descriptions of the frequently occurring root canal systems of permanent teeth are based largely on studies conducted in Europe and North America, and relate to teeth of mainly Caucasoid origin. These descriptions may not be fully applicable to teeth of non-Caucasoid origin. There are no published reports on the root canal anatomy of mandibular incisors in Jordan or other Middle Eastern countries. Jordan is in the Middle East with an estimated population of 5.8 million. Approximately, 92% of people living in Jordan are Jordanian and 98% are Arabs.

The purpose of this study was to examine the root canal morphology of mandibular incisors in a Jordanian population using a canal staining and root clearing technique.

## Materials and methods

Four hundred and fifty extracted mandibular incisors were randomly collected from general dental clinics within north Jordan. The gender and age of patients was not known and no attempt was made to differentiate between central and lateral incisors. The teeth were placed in 3.25% sodium hypochlorite (Hypex Bleach, Jordan Chemical industries Co., Amman, Jordan) for 1 h, after which any remaining soft tissue or calculus was removed by scaling. Access cavities were prepared and the pulp tissue removed by immersion in 3.25% sodium hypochlorite overnight, before placement in an ultrasonic bath. The teeth were then rinsed in running tap water for 2 h and dried overnight. An endodontic irrigation syringe with gauge 27 needle (BU Kwang Medical Inc., Seoul, Korea) was used to inject Indian ink (Sanford rotring GmbH, Hamburg, Germany) into the root canal system. The root apex was then immediately placed over small vacuum holes, connected to a central suction system, until the ink exited at the apical foramen.

The teeth were demineralized by immersion in 5% nitric acid for 4 days at room temperature (21 °C). The acid solution was changed every day. The teeth were washed under the running tap water for 4 h, dried and dehydrated using ascending concentrations of ethyl alcohol (70%, 96% and 99%) for 12 h each. Finally, the dehydrated teeth were placed in methyl salicylate, which rendered them transparent after about 2 h.

The transparent specimens were examined by the naked eye, and the following observations were made: (i) number and type of root canals; (ii) presence and location of lateral canals and intercanal communications; (iii) location of apical foramina; and (iv) fre-

quency of apical deltas. The canal configurations were categorized into the first five types of Vertucci's classification (2005) as follows:

Type I. A single canal is present from the pulp chamber to the apex.

Type II. Two separate canals leave the pulp chamber, but join to form one canal to the site of exiting.

Type III. One canal leaves the pulp chamber, divides into two within the root, and then merges to exit in one canal.

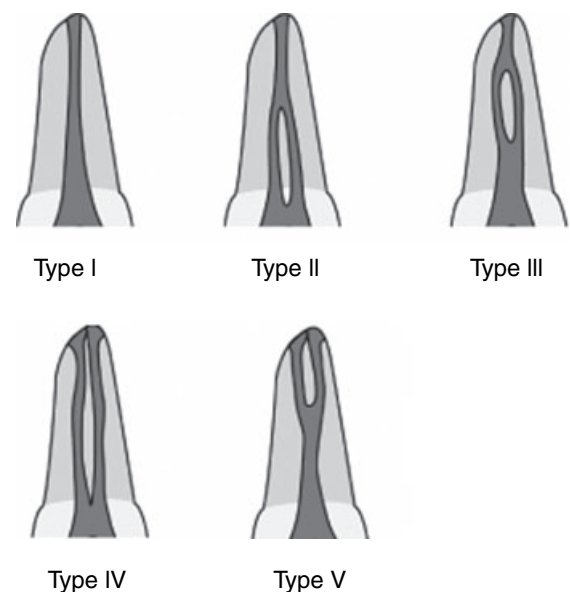
Type IV. Two separate and distinct canals are present from the pulp chamber to the apex.

Type V. Single canal leaving the pulp chamber but dividing into two separate canals with two separate apical foramina.

The five canal configurations are shown in Fig. 1.

## Results

Results are summarized in Tables 1–3. All teeth had one root. Table 1 shows the number and percentage of each canal type in the mandibular incisor teeth. Of 450 teeth, 332 (73.8%) had a single canal. Although 26.2% of the roots possessed two separate canals, only 8.7 had two separate apical foramina (Types IV and V). Figure 2 shows transparent teeth specimens, demonstrating the five canal configurations observed.



**Figure 1** Classification of root canal morphology (Vertucci 2005).

**Table 1** Number and percentage of canal system types in mandibular incisors ( $n = 450$ )

	Type of root canal				
	Type I	Type II	Type III	Type IV	Type V
No. (%)	332 (73.8)	49 (10.9)	30 (6.7)	23 (5.1)	16 (3.6)

**Table 2** Number and percentage of roots with lateral canals and intercanal communications ( $n = 450$ )

	Roots with lateral canals	Position of lateral canals			Intercanal communication
		Coronal	Middle	Apical	
No. (%)	28 (6.2)	4 (0.9)	6 (1.3)	18 (4.0)	83 (18.4)

**Table 3** Number and frequency of roots with central and lateral foramina and roots with apical deltas ( $n = 450$ )

	Position of apical foramina		Apical deltas
	Central	Lateral	
No. (%)	235 (52.2)	215 (47.8)	8 (1.8)


**Figure 2** Canal configurations observed in this study. From left to right: Types I, II, III, IV and V.

Table 2 shows the number and percentage of lateral canals and intercanal communications as well as position of lateral canals. Lateral canals were present in only 6.2% of roots. There was an increasing prevalence of lateral canals towards the apical third of the root with approximately 64% occurring in the apical part of the roots. A lateral canal in the apical third of the root is clearly shown in Fig. 3. Intercanal communications were found in 83 teeth (18.4%).

**Figure 3** A lateral canal in the apical third of the root.

Table 3 describes the frequency of roots with centrally and laterally located foramina as well as frequency of apical deltas. More than half of the roots (52.2%) had centrally located foramina. Apical deltas were observed in only eight teeth (1.8%).

## Discussion

A variety of techniques have been used to study root canal morphology including radiographic examination (Kaffe *et al.* 1985), root sectioning (Mauger *et al.* 1998) and staining and clearing techniques (Robertson *et al.* 1980). It has been reported that fine details of the root canal system can be visualized by staining and clearing (Gulabivala *et al.* 2002) and this method was used in the present study.

The literature on mandibular incisors reveals that 11–68% of mandibular incisors possess two canals, although many merge into one canal in the apical 1–3 mm of the root (Madeira & Hetem 1973, Vertucci 1974, Kartal & Yanikoglu 1992, Miyashita *et al.* 1997, Mauger *et al.* 1998, Sert *et al.* 2004). Vertucci (1974) examined the root canal morphology of 300 mandibular anterior teeth and reported a second canal in 27.5% of mandibular incisors. Miyashita *et al.* (1997) reported that 12.4% of mandibular incisors contained two canals, but only 3% had two foramina. Sert *et al.* (2004) noted that two canals were present in 68% of mandibular central incisors. The differences between these morphology studies may be related to variations of examination methods, classification systems, sample sizes and ethnic background of tooth sources.

This study examined the root canal morphology of extracted mandibular incisors collected from dental

clinics within north Jordan. Therefore, the sample may not be fully representative of the Jordanian population. However, root canal morphology may not vary in a young nation of the same ethnic origin. Therefore, the data presented in this paper is expected to apply to the Jordanian population.

It was found that 73.8% of the mandibular incisors possessed a single root canal. Although two canals were found in 26.2% of teeth, 67% of these canals joined and exited in a single foramen. Only 8.7% of canals in the teeth exited in two separate foramina (Types IV and V). Therefore, the frequency of two canals in the present study was within the range of previous reports.

The results of this investigation indicate that two canals occur in about one-fourth (26.2%) of mandibular incisors. This proportion is not found clinically by practitioners during root canal treatment (Neo & Chee 1990). This is due to failure of the dentist to recognize the presence of the second canal and the need for access cavities to have appropriate inciso-gingival extension to facilitate the location of lingual canals.

Of the teeth with two canals, the Type II configuration was most prevalent, followed by Types III, IV and V. Preparation and filling of Types I and IV canal systems is relatively straightforward because each of the canals in these configurations is separate and distinct between orifice and apex. However, Type II, III and V systems are different because there are areas in the root where the two canals share space and others where the canals are separate. This requires an individualized procedure for preparation and filling in each of these conditions to obtain the most desirable results.

In the present study, lateral canals were observed only in 6.2% of teeth and were found most frequently in the apical third of the canal. This is consistent with the findings of Miyashita *et al.* (1997) but much lower than that reported by Vertucci (1984). Intercanal communications were observed in 18.4% of all teeth and in 70.2% of teeth with two canals. The high percentage of intercanal communications in teeth with two canals may be of clinical significance, because it may be difficult to debride and fill these communications adequately. The apical foramen was found to coincide with the apical root tip in 52.2% of teeth. This is higher than reported in previous studies that demonstrated that the apical foramen coincided with the anatomical apex in 17–46% of cases (Pineda & Kuttler 1972, Caliskan *et al.* 1995, Sert *et al.* 2004, Vertucci 2005). This finding may be of significance in working length determination which often depends on

the average position of apical constriction relative to root apex. If the position of the foramen is more apical than previously reported, then the position of the apical constriction and working length determination may vary accordingly.

## Conclusions

Overall, 26.2% of mandibular incisors in this north Jordanian population had two canals. In the teeth with two canals, the Type II canal system was the most prevalent and Type V was the least prevalent.

The high percentage of intercanal communications and centrally located apical foramina is of clinical relevance.

## Acknowledgements

The authors wish to thank Blackwell publishing Ltd. for giving permission to reprint the first five canal configurations in Fig. 8 of the following Ref. 'Vertucci (2005)'.

## References

- Caliskan MK, Pehlivan Y, Sepetcioglu F, Türkün M, Tuncer SS (1995) Root canal morphology of human permanent teeth in a Turkish population. *Journal of Endodontics* **21**, 200–4.
- Gulabivala K, Opananon A, Ng Y-L, Alavi A (2002) Root and canal morphology of Thai mandibular molars. *International Endodontic Journal* **35**, 56–62.
- Haddad GY, Nehme WB, Ounsi HF (1999) Diagnosis, classification and frequency of C-shaped canals in mandibular second molars in the Lebanese population. *Journal of Endodontics* **25**, 268–71.
- Kaffe I, Kaufman A, Littner MM, Lazarson A (1985) Radiographic study of root canal system of mandibular anterior teeth. *International Endodontic Journal* **18**, 253–9.
- Kartal N, Yanikoglu F (1992) Root canal morphology of mandibular incisors. *Journal of Endodontics* **18**, 562–4.
- Madeira MC, Hetem S (1973) Incidence of bifurcations in mandibular incisors. *Oral Surgery, Oral Medicine and Oral Pathology* **36**, 589–91.
- Mauger MJ, Schindler WG, Walker WA (1998) An evaluation of canal morphology at different levels of root resection in mandibular incisors. *Journal of Endodontics* **24**, 607–9.
- Miyashita M, Kasahara E, Yasuda E, Yamamoto A (1997) Root canal system of the mandibular incisor. *Journal of Endodontics* **23**, 479–84.
- Neo J, Chee LF (1990) A retrospective clinical study of endodontically treated mandibular incisors in a selected Chinese population. *Oral Surgery, Oral Medicine and Oral Pathology* **70**, 782–3.

- Pineda F, Kuttler Y (1972) Mesiodistal and buccolingual roentgenographic investigation of 7275 root canals. *Oral Surgery, Oral Medicine and Oral Pathology* **33**, 101–10.
- Rankine-Wilson RW, Henry P (1965) The bifurcated root canal in lower anterior teeth. *Journal of the American Dental Association* **70**, 1162–5.
- Robertson D, Leeb J, McKee M, Brewer E (1980) A clearing technique for the study of root canal systems. *Journal of Endodontics* **6**, 421–4.
- Sert S, Bayirli GS (2004) Evaluation of the root canal configurations of the mandibular and maxillary permanent teeth by gender in the Turkish population. *Journal of Endodontics* **30**, 391–8.
- Sert S, Aslanalp V, Tanalp J (2004) Investigation of the root canal configurations of mandibular permanent teeth in the Turkish population. *International Endodontic Journal* **37**, 494–9.
- Vertucci FJ (1974) Root canal anatomy of the mandibular anterior teeth. *Journal of the American Dental Association* **89**, 369–71.
- Vertucci FJ (1984) Root canal anatomy of the human permanent teeth. *Oral Surgery, Oral Medicine and Oral Pathology* **58**, 589–99.
- Vertucci FJ (2005) Root canal morphology and its relationship to endodontic procedures. *Endodontic Topics* **10**, 3–29.
- Walker RT (1988) The root canal anatomy of mandibular incisors in a southern Chinese population. *International Endodontic Journal* **21**, 218–23.
- Weine FS, Hayami S, Hata G, Toda T (1999) Canal configuration of the mesiobuccal root of the maxillary first molar of a Japanese sub-population. *International Endodontic Journal* **32**, 79–87.

This document is a scanned copy of a printed document. No warranty is given about the accuracy of the copy. Users should refer to the original published version of the material.