



## CASE REPORT

# Apical plug technique using mineral trioxide aggregate: results from a case series

**R. Pace, V. Giuliani, L. Pini Prato, T. Baccetti & G. Pagavino**

Department of Endodontics, The University of Florence, Florence, Italy

### Abstract

Pace R, Giuliani V, Pini Prato L, Baccetti T, Pagavino G. Apical plug technique using mineral trioxide aggregate: results from a case series. *International Endodontic Journal*, **40**, 478–484, 2007.

**Aim** To examine the clinical and radiographic appearance of teeth that suffered premature interruption of root development and were treated by an mineral trioxide aggregate (MTA) apical plug technique.

**Summary** Eleven teeth with immature root apices in 11 patients were treated nonsurgically by the manual application of MTA in the apical portion of the root canal under microscopic vision. Follow-up evaluations were performed at 1–2 years after treatment.

### Key learning points

- Mineral trioxide aggregate appears to be a valid material to obtain periradicular healing in teeth with open apices and necrotic pulps.
- Ten out of 11 cases were associated with periradicular health at follow-up evaluation.

**Keywords:** mineral trioxide aggregate, necrotic pulp, one visit apexification, open apices.

Received 9 June 2006; accepted 23 November 2006

### Introduction

One of the aims of root canal treatment is to fill completely the root canal system in order to prevent re-infection. In teeth with incomplete root development as a consequence of pulp necrosis through trauma or caries, the absence of a natural constriction at the end of the root canal makes control of filling materials difficult (Seltzer 1988). Because of the lack of an apical constriction, an alternative to standard root canal treatment, apexification or root-end-closure, has been advocated (Seltzer 1988).

Correspondence: Dr Valentina Giuliani, Dipartimento di Odontostomatologia, The University of Florence, Viale Morgagni 85 Firenze 50139, Italy (Tel.: +39055354265; fax: +39055321144; e-mail: valesoho@libero.it).

Apexification can be defined as a 'method to induce a calcified barrier in a root with an open apex or the continued apical development of teeth with incomplete roots and a necrotic pulp' (American Association of Endodontists 2003). Calcium hydroxide has been the first choice material for apexification (Rafter 2005), with repeated changes over the course of 5–20 months to induce the formation of a calcific barrier (Sheehy & Roberts 1997). The unpredictable and often lengthy course of this treatment modality presents challenges, including the vulnerability of the temporary coronal restoration to re-infection (Magura *et al.* 1991). Moreover, the treatment requires a high level of patient compliance.

For these reasons, one visit apexification has been suggested (Morse *et al.* 1990). Mineral trioxide aggregate (MTA) has been proposed as a material suitable for one visit apexification (Torabinejad & Chiaviani 1993, Shabahang & Torabinejad 2000, Maroto *et al.* 2003), as it combines biocompatibility (Koh *et al.* 1998, Holland *et al.* 1999), and a bacteriostatic action (Torabinejad *et al.* 1995a), with favourable sealing ability when used to repair root/pulp chamber perforations (Arens & Torabinejad 1996, Holland *et al.* 2001) or as root-end filling material (Torabinejad *et al.* 1995b, Xavier *et al.* 2005). MTA offers a barrier at the end of the root canal (apical plug) in teeth with necrotic pulps and open apices (Torabinejad & Chiaviani 1993) that permits vertical condensation of warm gutta-percha in the remainder of the canal. Some authors (Aminoshariae *et al.* 2003, Al-Kahtani *et al.* 2005) suggest that the success of the apical plug technique could be influenced by the intracanal delivery technique. Aminoshariae *et al.* (2003) obtained satisfactory adaptation of MTA using hand methods rather than by ultrasonic condensation, which was shown by Lawley *et al.* (2004) to be superior. Moreover, the use of an operating microscope may allow better control of the placement of the MTA at the end of the root canal (Aminoshariae *et al.* 2003). Previous reports of MTA in root-end-closure have included relatively few cases, treated by nonstandardised methods (Shabahang & Torabinejad 2000, Giuliani *et al.* 2002, Maroto *et al.* 2003).

The aim of this report was to present the short-term follow-up results in 11 consecutively treated teeth with nonvital pulps and open root apices which were managed with an MTA apical plug technique, placed under the operating microscope.

### Materials and methods

This report includes eleven maxillary incisors in eleven subjects aged between 11 and 32 years who suffered a traumatic injury, and presented at the Endodontic Clinic of the School of Dentistry of the University of Florence, Italy. The patients were selected as follows: the minimum time between the trauma and the first visit was 2 years, and all patients presented with incomplete development of the tooth involved.

Clinical and radiographic examinations were performed (Table 1). Ethical approval was sought and granted. Informed consent was obtained from all subjects.

The teeth were isolated with a rubber dam. A conventional access cavity was prepared in the palatal surface of the incisors. The cavities were widened with CPR ultrasonic tips (Dentsply Tulsa, Tulsa, OK, USA) to enhance the visibility of the root canal. The canal was then gently cleaned with manual instruments and 5% NaOCl irrigation (Nicolor 5 OGNA, Milan, Italy). The working length was measured radiographically with a K-file and recorded for reference (Table 2).

The canals were dried with sterile paper points and filled with calcium hydroxide (Ultracalx Ultradent Inc., South Jordan, UT, USA) placed using intracanal Capillary Tips (Ultradent Inc.), and the access cavity was sealed with Cavit (3M ESPE AG, Seefeld, Germany). After 1 week, the calcium hydroxide was removed by rinsing with alternating solutions of NaOCl 5% and EDTA 17% (OGNA). A final rinse with sterile water was performed. Once the canal was dry at the working length, with no exudate, the MTA

**Table 1** Descriptive data at the first visit

Patient number	Sex	Tooth	Age of patient (years)	Age at trauma (years)	Clinical examination
1	F	21	15	7	Buccal sinus tract
2	M	11	16	8	Buccal sinus tract
3	F	22	16	8	No
4	F	11	12	7	Buccal sinus tract
5	F	22	15	7	Buccal sinus tract
6	M	21	13	7	No
7	F	21	11	9	Buccal sinus tract
8	F	11	29	7	Buccal sinus tract
9	F	11	30	9	Buccal sinus tract
10	M	21	12	8	Buccal sinus tract
11	M	21	32	8	No

**Table 2** Working length and time needed before mineral trioxide aggregate (MTA) apical plug

Patient number	Working length (mm)	Number of intracanal medications with calcium hydroxide	Amount of time with intracanal medication (days)
1	18	1	7
2	22.5	1	7
3	22	1	7
4	23	1	7
5	17	3	14
6	23	1	7
7	20	1	7
8	19	1	7
9	21	1	7
10	22	1	7
11	21	1	7

(Dentsply Tulsa) apical plug was placed. When canals could not be dried, calcium hydroxide dressings were repeated until no exudate was present. Table 2 outlines the number of calcium hydroxide medications, and the time needed to obtain a dry canal.

Mineral trioxide aggregate apical plugs were placed in the apical portion of canals with a thickness of 3–5 mm, as recommended by the manufacturer, using an MTA Endo Gun (Dentsply Maillefer, Ballaigues, Switzerland) and posterior pluggers sized according to the apical diameter under  $\times 10$  magnification. A sterile sponge pellet moistened with sterile water was placed over the canal orifice and the access cavity was sealed temporarily.

Correct placement of MTA was confirmed radiographically. After one week, the canals were back-filled with injection-moulded thermoplastic gutta-percha (Obtura Corp., Fenton, MO, USA) and sealer (Pulp Canal Sealer Kerr, Romulus, MI, USA). At the same appointment, the teeth were restored with dentine and enamel-bonded composite.

Cases were reviewed radiographically using the paralleling technique at the first visit, after performing the apical plug, after the filling of the canal and coronal restoration, and at the 12 and 24 month follow-up appointments. Healing was identified when a reduction or disappearance of the periapical radiolucent area could be seen, and if the periodontal ligament space was normal in teeth without initial apical periodontitis. Clinically, treatment was considered successful when symptoms such as pain, swelling, buccal sinus tract, or tenderness to apical and gingival palpation or percussion, were absent.

In the absence of clinical signs and/or symptoms, healing was classified according to the radiographic appearance against the following criteria: (i) complete healing: complete regeneration of the periodontal ligament space; (ii) incomplete healing: substantial

reduction (more than 50%) in the diameter of the periapical lesion; and (iii) unsatisfactory healing: no reduction or an increase in the diameter of the periapical lesion.

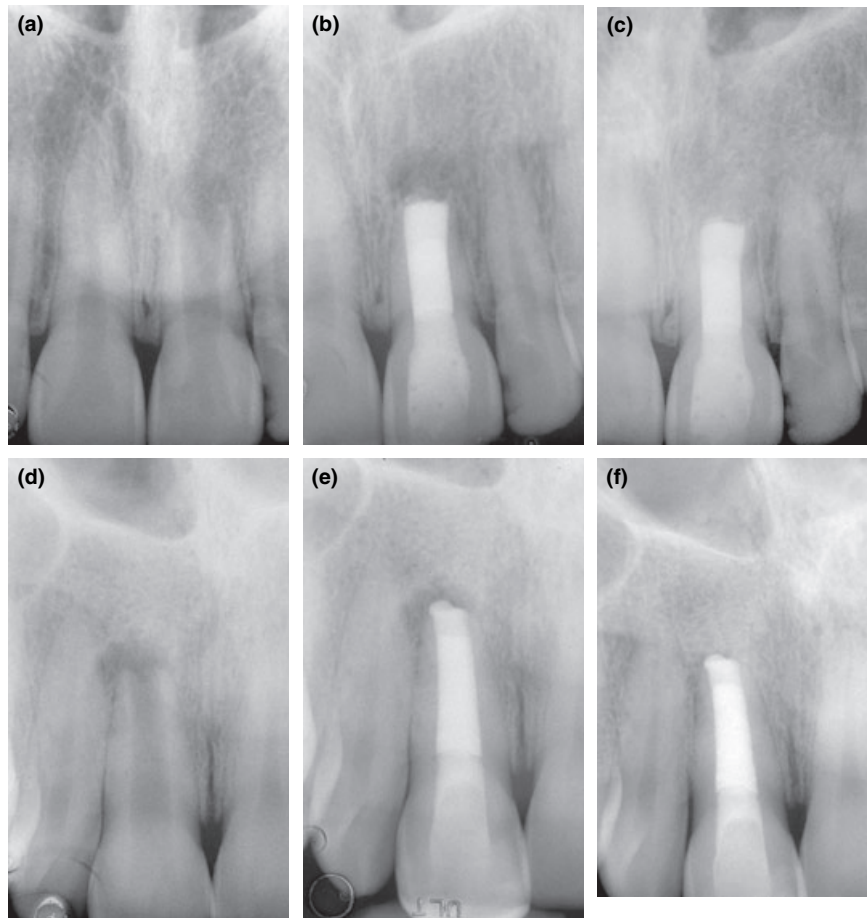
### Results

At the 12-month clinical examination, all teeth were free from symptoms, buccal sinus tracts, and swelling. Radiographic examination revealed incomplete resolution of the periapical lesion in all cases (Fig. 1b,e).

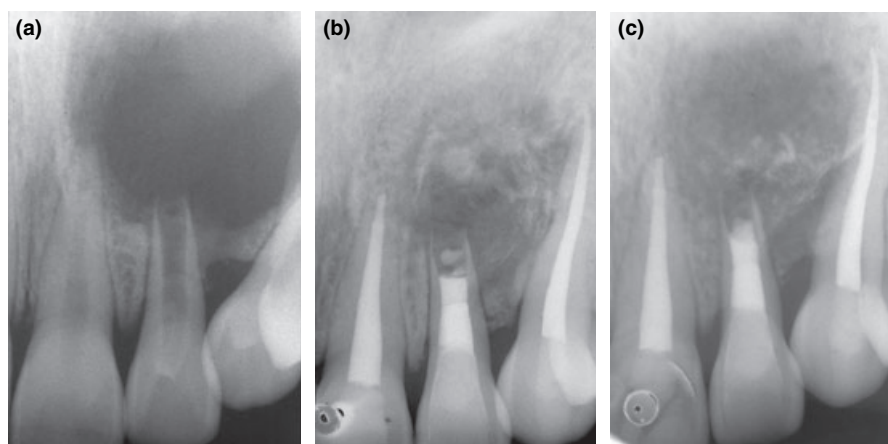
At the 24-month follow-up, ten teeth displayed complete healing (Fig. 1c,f), in both clinical and radiographic terms. In one tooth (patient no. 5), although the clinical symptoms disappeared and the tooth was in adequate clinical function, the radiographic follow-up revealed incomplete healing but not substantial reduction (more than 50%) in the size of the periapical lesion (Fig. 2a–c).

### Discussion

In general, the outcomes in this case series are similar to previously reported cases of successful MTA apical plug procedures in teeth with necrotic pulps and open apices



**Figure 1** Two clinical cases. (a and d) Pre-treatment observations. (b and e) Incomplete healing at 1-year follow-up. (c and f) Complete healing at 2-year follow-up.



**Figure 2** The clinical case with incomplete healing at 2-year follow-up. (a) Pre-treatment observation. Note the very large apical lesion. (b) Incomplete healing at 1-year follow-up. (c) Still incomplete healing at 2-year follow-up.

(Shabahang & Torabinejad 2000, Giuliani *et al.* 2002, Maroto *et al.* 2003). In teeth with these clinical conditions, the outcome of conventional gutta-percha fillings would be uncertain, whereas MTA has the potential to provide predictable results (de Leimburg *et al.* 2004). In the present study, the 2-year follow-up evaluation revealed complete healing in 10 out of 11 cases. In all these cases the preoperative clinical examination revealed apical periodontitis with a buccal sinus tract of endodontic origin. At the first visit, the age of all patients was greater than 11 years, *i.e.* beyond the expected age of complete root formation in maxillary incisors.

At the 2-year follow-up examination, one case (patient no. 5) displayed incomplete healing. In this patient, the preoperative radiolucency was extensive, involving the maxillary left central incisor, lateral incisor and canine. At the first visit the patient had a large buccal swelling and two episodes of medication with calcium hydroxide were required during a time interval of 14 days in order to obtain a dry canal. This tooth with incomplete healing at the 2-year radiographic follow-up, also revealed incomplete adaptation of MTA at the working length of the root canal. It can be assumed that the very large preoperative apical lesion would need a longer period of time to heal.

In all other cases presented in this study, only one intracanal medication with calcium hydroxide was performed before the canal was dry and ready for filling. The use of calcium hydroxide is still controversial. Hachmeister *et al.* (2002) showed that remains of calcium hydroxide that remain on the canal walls had no significant effect on MTA leakage or displacement resistance. On the contrary, Porkaew *et al.* (1998) suggested that remnants of calcium hydroxide on the canal walls may react to form calcium carbonate, and interfere with the seal produced. In the present work, complete removal of calcium hydroxide from the canal walls was accomplished by alternate irrigation with NaOCl 5% and EDTA 17% (Calt & Seper 1999). However, recent data (Ham *et al.* 2005) suggest that the combination of MTA and calcium hydroxide in apexification procedures may favourably influence the regeneration of the periodontium. As postulated by Al-Kahtani *et al.* (2005) the type of intracanal delivery technique may contribute to the final success of treatment in one visit apexification. The placement of the apical plug can be accomplished using different methods. It must be further emphasized that orthograde delivery placement of the apical plug is more technique sensitive than the retrograde method. The laboratory study by Hachmeister

*et al.* (2002) showed that when MTA was used as a root-end filling material and condensed against a physical barrier, the sealing ability was superior than when MTA was used as an orthograde apical plug. In teeth with necrotic pulps and open apices, the irregular dentinal walls and the divergent apices make the adaptation of MTA more difficult. Aminoshariae *et al.* (2003) suggested from their laboratory study that hand condensation resulted in better adaptation and fewer voids than ultrasonic compaction. In the present study, the MTA apical plugs were placed by a standardized hand condensation technique in all cases. To check for the correct position and to avoid marginal gaps at the dentine interface, microscopic vision (×10) was utilized during delivery and compaction.

The apical plug created with MTA can be interpreted as an artificial barrier to condense the subsequent root canal filling material, in order to prevent reinfection of the canal system. Some authors have postulated that possible leakage of MTA could be influenced by the thickness of the apical plug. A recent study (de Leimburg *et al.* 2004) reported that the orthograde use of MTA provided an adequate seal against bacterial infiltration regardless of the thickness of the apical plug. This result is in agreement with Hachmeister *et al.* (2002) who underlined that the thickness of the apical plug may have a significant impact only on displacement resistance. In the present study, the thickness of the MTA apical plug varied from 3 mm to 5 mm. In teeth with a short root canal the thickness of the apical plug was reduced to 3 mm to allow for the subsequent filling of the more superficial portion of the canal with resin materials.

Based on the results of this investigation, the nonsurgical management of teeth with necrotic pulps and incomplete apex formation with MTA was successful. In one out of 11 cases, radiographic healing was incomplete, a finding which may have been influenced by the initial severity of the lesion and the architecture of the root-end.

## Conclusions

Orthograde MTA plugs placed by hand under microscopic vision resulted in a successful outcome at 2 years. Radiographic and clinical healing occurred in 10 out of 11 teeth; in one case healing was incomplete. This may be influenced by the initial severity of the lesion that probably required a longer healing period. Future controlled and randomized studies on the use of MTA as apical plug would lend further support to this treatment option.

## Disclaimer

Whilst this article has been subjected to Editorial review, the opinions expressed, unless specifically indicated, are those of the author. The views expressed do not necessarily represent best practice, or the views of the IEJ Editorial Board, or of its affiliated Specialist Societies.

## References

- Al-Kahtani A, Shostad S, Schifferle R, Bhambhani S (2005) In-vitro evaluation of microleakage of an orthograde apical plug of mineral trioxide aggregate in permanent teeth with simulated immature apices. *Journal of Endodontics* **31**, 117–9.
- American Association of Endodontists (2003) *Glossary of Endodontic Terms*, 7th edn. Chicago: American Association of Endodontists.
- Aminoshariae A, Hartwell GR, Moon PC (2003) Placement of mineral trioxide aggregate using two different techniques. *Journal of Endodontics* **29**, 679–82.

- Arens DE, Torabinejad M (1996) Repair of furcal perforations with mineral trioxide aggregate: two case reports. *Oral Surgery, Oral Medicine, Oral Pathology, Oral Radiology, and Endodontics* **82**, 84–8.
- Calt S, Seper A (1999) Dentinal tubule penetration of root canal sealers after root canal dressing with calcium hydroxide. *Journal of Endodontics* **25**, 431–3.
- Giuliani V, Baccetti T, Pace R, Pagavino G (2002) The use of MTA in teeth with necrotic pulps and open apices. *Dental Traumatology* **18**, 217–21.
- Hachmeister DR, Schindler G, Walker WA, Thomas DD (2002) The sealing ability and retention characteristics of mineral trioxide aggregate in a model of apexification. *Journal of Endodontics* **28**, 386–90.
- Ham KA, Witherspoon DE, Gutmann JL, Ravindranath S, Gait TC, Opperman LA (2005) Preliminary evaluation of BMP-2 expression and histological characteristics during apexification with calcium hydroxide and mineral trioxide aggregate. *Journal of Endodontics* **31**, 275–9.
- Holland R, de Souza V, Nery MJ, Otoboni Filho JA, Bernabe PF, Dezan Junior E (1999) Reaction of rat connective tissue to implanted dentin tubes filled with mineral trioxide aggregate or calcium hydroxide. *Journal of Endodontics* **25**, 161–6.
- Holland R, Filho JA, de Souza V, Nery MJ, Bernabe PF, Junior ED (2001) Mineral trioxide aggregate repair of lateral root perforations. *Journal of Endodontics* **27**, 281–4.
- Koh ET, McDonald F, Pitt Ford TR, Torabinejad M (1998) Cellular response to mineral trioxide aggregate. *Journal of Endodontics* **24**, 543–7.
- Lawley GR, Schindler WG, Walker WA III, Kolodrubetz D (2004) Evaluation of ultrasonically placed MTA and fracture resistance with intracanal composite resin in a model of apexification. *Journal of Endodontics* **30**, 167–72.
- de Leimburg ML, Angeretti A, Ceruti P, Lendini M, Pasqualini D, Berutti E (2004) MTA obturation of pulpless teeth with open apices: bacterial leakage as detected by polymerase chain reaction assay. *Journal of Endodontics* **30**, 883–6.
- Magura ME, Kafrawy AH, Brown CE Jr, Newton C (1991) Human saliva coronal microleakage in obturated root canals: an in vitro study. *Journal of Endodontics* **17**, 324–31.
- Maroto M, Barberia E, Planells P, Vera V (2003) Treatment of a non-vital immature incisor with mineral trioxide aggregate (MTA). *Dental Traumatology* **19**, 217–21.
- Morse DR, O'Larnic J, Yesilsoy C (1990) Apexification: review of the literature. *Quintessence International* **21**, 589–98.
- Porkaew P, Rettief H, Barfield RD, Lacefield WR, Soon S (1998) Effects of calcium hydroxide paste as an intracanal medicament on apical seal. *Journal of Endodontics* **24**, 176–9.
- Rafter M (2005) Apexification: a review. *Dental Traumatology* **21**, 1–8.
- Seltzer S (1988) *Endodontology: Biologic Considerations in Endodontic Procedures*, 2nd edn. Philadelphia: Lea & Febiger.
- Shabahang S, Torabinejad M (2000) Treatment of theet with open apices using mineral trioxide aggregate. *Practical Periodontics and Aesthetic Dentistry* **12**, 315–20.
- Sheehy EC, Roberts GJ (1997) Use of calcium hydroxide for apical barrier formation and healing in non-vital immature permanent teeth: a review. *British Dental Journal* **183**, 241–6.
- Torabinejad M, Chivian N (1993) Clinical application of mineral trioxide aggregate. *Journal of Endodontics* **25**, 197–205.
- Torabinejad M, Hong CU, Pitt Ford TR, Kettering JD (1995a) Antibacterial effects of some root end filling materials. *Journal of Endodontics* **21**, 403–6.
- Torabinejad M, Smith PW, Kettering JD, Pitt Ford TR (1995b) Comparative investigation of marginal adaptation of mineral trioxide aggregate and other commonly used root-end filling materials. *Journal of Endodontics* **21**, 295–9.
- Xavier CB, Weismann R, de Oliveira MG, Demarco FF, Pozza DH (2005) Root-end filling materials: apical microleakage and marginal adaptation. *Journal of Endodontics* **31**, 539–42.

This document is a scanned copy of a printed document. No warranty is given about the accuracy of the copy. Users should refer to the original published version of the material.