



CLINICAL ARTICLE

The potential applications of cone beam computed tomography in the management of endodontic problems

S. Patel^{1,2}, A. Dawood², T. Pitt Ford¹ & E. Whaites³

¹Endodontic Postgraduate Unit, Guy's, King's & St Thomas' Dental Institute, King's College, London; ²Private practice, 45 Wimpole Street, London; and ³Department of Dental Radiology, Guy's, King's & St Thomas' Dental Institute, King's College, London, UK

Abstract

Patel S, Dawood A, Pitt Ford T, Whaites E. The potential applications of cone beam computed tomography in the management of endodontic problems. *International Endodontic Journal*, **40**, 818–830, 2007.

Aim To provide core information on cone beam computed tomography (CBCT) technology and its potential applications in endodontic practice.

Summary CBCT has been specifically designed to produce undistorted three-dimensional information of the maxillofacial skeleton as well as three-dimensional images of the teeth and their surrounding tissues. This is usually achieved with a substantially lower effective dose compared with conventional medical computed tomography (CT). Periapical disease may be detected sooner using CBCT compared with periapical views, and the true size, extent, nature and position of periapical and resorptive lesions can be assessed. Root fractures, root canal anatomy and the true nature of the alveolar bone topography around teeth may be assessed. CBCT scans are desirable to assess posterior teeth prior to periapical surgery, as the thickness of the cortical and cancellous bone can be accurately determined as can the inclination of roots in relation to the surrounding jaw. The relationship of anatomical structures such as the maxillary sinus and inferior dental nerve to the root apices may also be clearly visualized.

Key learning points

- CBCT has a low effective dose in the same order of magnitude as conventional dental radiographs.
- CBCT has numerous potential applications in the management of endodontic problems.

Keywords: cone beam computed tomography, management of endodontic problems.

Received 16 January 2007; accepted 26 April 2007

Correspondence: Shanon Patel, 45 Wimpole Street, London W1G 8SB, UK
(e-mail: shanonpatel@hotmail.com).

Introduction

Radiographic examination is an essential component of the management of endodontic problems. It underpins all aspects of endodontic treatment from diagnosis and treatment planning to assessing outcome. The amount of information gained from conventional film and digitally captured periapical radiographs is limited by the fact that the three-dimensional anatomy of the area being radiographed is compressed into a two-dimensional image. As a result of superimposition, periapical radiographs reveal limited aspects of the three-dimensional anatomy. In addition, there may also be geometric distortion of the anatomical structures being imaged (Gröndahl & Huuonen 2004). These problems may be overcome using small volume cone beam computed tomography (CBCT) imaging techniques which can produce three-dimensional images of individual teeth and the surrounding tissues.

The benefits of three-dimensional medical computer tomography (CT) imaging are already well established in certain dental specialities. The greatest uptake of this technology has been in the management of trauma to the maxillofacial skeleton (Finkle *et al.* 1985, Exadaktylos *et al.* 2005, Scarfe 2005). It has also been used for patients requiring surgical facial reconstruction, orthognathic surgery, dental implants and complicated extractions (Schwartz *et al.* 1987, Zeigler *et al.* 2002, Enciso *et al.* 2005). The high-radiation dose, cost, availability, poor resolution and difficulty in interpretation have resulted in limited use of CT imaging in endodontics. These issues may be addressed by recent cone beam innovations in CT technology, and could substantially alter the way that patients who have potentially complex endodontic problems are managed. The aim of this paper is to describe the potential applications of CBCT technology in endodontics with clinical examples.

Comparison of medical CT and CBCT

The medical CT scanner was developed in the late 1960s, and subsequently patented by Hounsfield (1973). Hounsfield's invention made an immediate and profound impact in diagnostic medical radiography for which he was awarded the Nobel Prize for Medicine in 1979. Early generations of the CT scanner acquired 'data' in the axial plane by scanning the patient *slice by slice*, by passing a narrow fan shaped X-ray beam through the patient to a single array of reciprocal detectors. Over the last three decades, there have been considerable advances in technology enabling scans in different planes. Current CT scanners have a linear array of multiple detectors, allowing *multiple slices* to be taken simultaneously, resulting in faster scan times and often less radiation exposure to the patient (Sukovic 2003). The slices of data are then 'stacked' up and can be re-formatted to obtain three-dimensional images. The interval between each slice may also be varied; closely approximated slices will give better spatial resolution, but will result in an increased dose to the patient. CT scanners are large and very expensive and therefore are usually only found in hospitals with dedicated medical imaging departments. They are not designed for general dental practice.

In the late 1990s Italian and Japanese groups (Arai *et al.* 1999, Mozzo *et al.* 1998), working independently of each other, developed a new tomographic scanner known as cone beam computed tomography (CBCT) or digital volume tomography (DVT) specifically for maxillofacial and dental use. CBCT differs from medical CT imaging, in that the whole three-dimensional volume of data is acquired in the course of a *single sweep* of the scanner, using a simple, direct relationship between sensor and source. The X-ray beam is cone-shaped (hence the name of the technique), and captures a cylindrical or spherical volume of data, described as the *field of view* (Fig. 1). The size of the *field of view* is variable, *large* volume CBCT scanners (e.g. i-CAT, Imaging Sciences International,

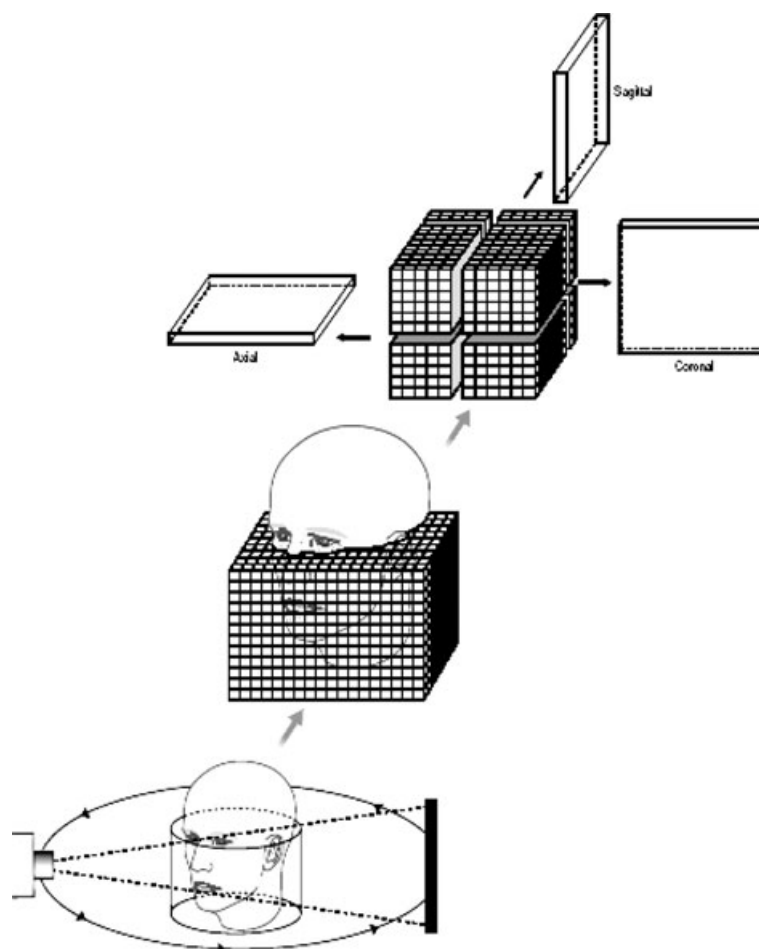


Figure 1 Diagram showing the basic concept of CBCT. A cone-shaped X-ray beam is used which orbits once around the patient obtaining information in a cylindrical volume. The patient's maxillofacial skeleton is positioned within the cylinder and is divided up into tiny cubes or voxels. Computer manipulation (multiplanar reconstruction) of the data obtained allows separate images in the sagittal, coronal and axial planes to be created. (Reproduced from Whaites' *Essentials of Dental Radiography and Radiology* 4th Ed, with kind permission from Elsevier).

Hatfield, PA, USA and NewTom 3 G, QR, Verona, Italy) capture the entire maxillofacial skeleton within a large cylindrical or spherical *field of view* (Fig. 2). Some CBCT scanners also allow the height of the cylindrical *field of view* to be adjusted to capture only the maxilla or mandible (e.g. i-CAT). *Limited* volume CBCT scanners capture small volumes of data that can include just two or three individual teeth. For example, the 3D Accuitomo (J Morita Corporation, Osaka, Japan) captures a 30 mm high by 40 mm diameter cylindrical volume of data which is similar in overall height and width to a periapical radiograph (Fig. 3). Recently, the Planmeca Promax 3D (Planmeca, Helsinki, Finland) has been introduced onto the dental market. This CBCT scanner like the 3D Accuitomo can also produce images of small specific areas of interest, with the smallest field of view being a 50 mm high by 30 mm diameter cylinder. In all current CBCT units, the data are acquired using either an image intensifier or a flat (CMOS or amorphous silicon) panel depending on the type of CBCT scanner (Mah & Hatcher 2004). As all the information is obtained in a single scan, it is essential that the patient remains absolutely still throughout the exposure.

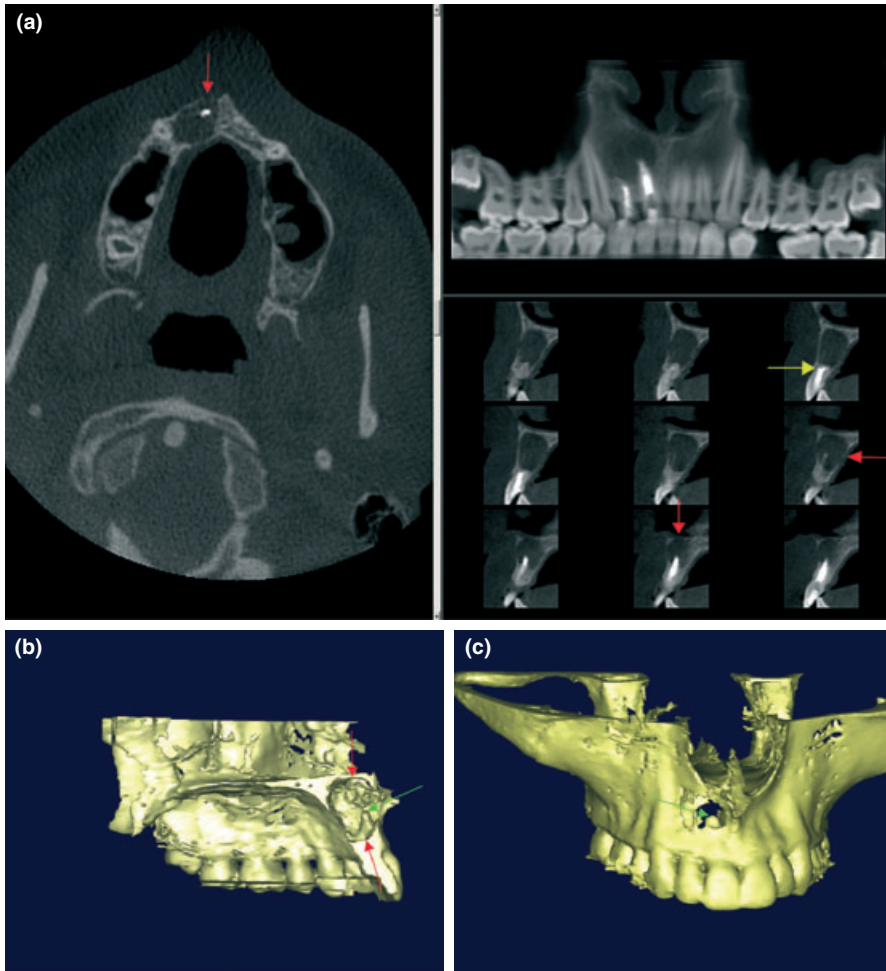


Figure 2 (a) A large volume CBCT scan using the i-CAT scanner. The monitor screen shows reconstructed axial, sagittal and panoramic images simultaneously. All three planes clearly show the full extent of the periapical radiolucency (red arrows) associated with teeth 11 and 12. The sagittal views reveal that the root filling in tooth 12 has perforated through the labial root surface (yellow arrow). (b, c) Three dimensional volume rendered models can be created using specially designed software. It allows the area of interest to be visualized and can be rotated in any angle for viewing: (b) is a sagittal view, (c) is a coronal view. The apical third of tooth 11 (green arrows) and the extent of the lesion (red arrows) can clearly be assessed.

Perhaps the most important and clinically useful aspect of CBCT scanners is their highly sophisticated software that allows the huge volume of data collected to be broken down and processed or re-constructed into a format which closely resembles that produced by medical CT scanners. The data are re-constructed to form small (e.g. 0.125 mm) isotropic cubic voxels (three-dimensional pixels). Typically, one scan contains over 100 million voxels. Tomographic slices, as thin as one voxel thick, may be displayed in a number of different ways. One option, for example, is for the images to be displayed in the three orthogonal planes, axial, sagittal and coronal, simultaneously. Selecting and moving the cursor on one image, automatically alters the other reconstructed slices; thus allowing images to be scrolled through in real time. Clinicians are not constrained by these predetermined views, *multiplanar reconstructions* are possible which allow virtually any view to be selected. For example, with most of the available software, it is possible to plot

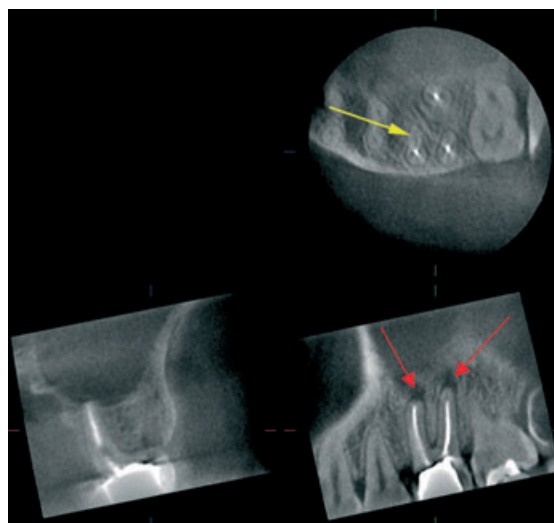


Figure 3 A limited volume CBCT scan using the 3D Accuitomo scanner has been taken of the maxillary left quadrant to manage tooth 26. The axial scan clearly shows an untreated second mesiobuccal canal (yellow arrow), the sagittal scan reveals periapical radiolucencies (red arrows) associated with the mesiobuccal and distobuccal roots. The coronal slice reveals that the apex of the palatal root appears to be healthy. Courtesy of J. Morita GmbH, Dietzenbach, Germany.

the curvature and shape of the dental arch to enable the computer to construct a panoramic image made up of voxels that coincide with the plotted arch shape. These points can re-plotted to produce another panoramic view representing a slightly different focal trough. Another option, as employed by the Sirona Galileos 3D (Sirona Dental Systems GmbH, Bensheim, Germany), is to display the data initially as a panoramic image that closely resembles a conventional dental panoramic radiograph. This image acts as a map from which the operator selects the region of interest, then the relevant sagittal, coronal and axial slices of the area are produced. All software includes basic enhancements including magnification, visual enhancements (grey scale, brightness and contrast levels), annotations may be added to images and measurements may be taken. Surface rendering is also possible to produce three-dimensional imagery.

One drawback of CBCT is its spatial resolution compared to conventional and digital radiographs. The spatial resolution of conventional direct-action packet film is in the order of 10–15 line pairs per millimetre (mm). For modern digital receptors, resolution varies but is typically 7–25 line pairs per mm. CBCT images have a spatial resolution of about 2 line pairs per mm.

Scan times are typically 10–40 s, although the actual exposure time is significantly less (2–5 s) as scans involve a number (up to 360) of separate, small, individual exposures rather than one continuous exposure. With medical CT scanners, the scanning and exposure times for the skull can be significantly longer. Reconstruction times for CBCT equipment vary, but usually take less than 5 min. The efficient use of a relatively high kV, combined with sophisticated image receptor sensors, contribute to the huge reduction in radiation exposure compared with medical CT scanners. Most CBCT scanners are much smaller than medical CT scanners, taking up about the same space as a dental panoramic machine. They are also significantly less expensive than medical CT scanners. These advantages should increase the uptake of CBCT scanners both in the dental hospital and dental practice settings.

Comparing the radiation dose of different CBCT scanners with medical CT scanners may be confusing because of different units of radiation dose that can be used. Put simply, there are three basic dose units in radiation dosimetry. They are the *radiation absorbed dose* (D),

the *equivalent dose* (H) and the *effective dose* (E). The *radiation absorbed dose* is defined as the measure of the amount of energy absorbed from the radiation beam per unit mass of tissue and is measured in joules per kilogram. The unit used to compare different dosages is the Gray (Gy). It cannot be used to compare the dose from one investigation to another because it does not allow for how dangerous the type of radiation might be, nor does it allow for the sensitivity of the particular part of the body that is being irradiated. To achieve this comparability, various mathematical calculations are performed and the other dose units are used. The *equivalent dose* is defined as a measure that indicates the radiobiological effectiveness of different types of radiation and thus provides a common unit. It is calculated by multiplying the radiation-absorbed dose by the radiation-quality weighting factor. The radiation-quality weighting factor is a figure which describes the damaging nature of different types of radiation. It is also measured in joules per kilogram, but the unit used to compare different equivalent doses is the Sievert (Sv). A second mathematical calculation can now be performed to take into account the part of the body that is irradiated. This results in the *effective dose*, which is calculated by multiplying the equivalent dose by different tissue weighting factors which converts all doses to an equivalent whole body dose and allows doses from different investigations of different parts of the body to be compared. The unit remains as the Sievert (Sv) and can be used to estimate the damage from radiation to an exposed population.

As shown in Table 1, the reported effective doses from CBCT scanners vary, but can be almost as low as those from panoramic dental X-ray units and considerably less than that from medical CT scanners. The higher effective doses from particular makes of CBCT scanners is in part due to the larger size of the *field of view* used as well as the type of image receptor employed. As to be expected, the small volume scanners, such as the 3D Accuitomo and Planmeca Promax 3D, which are specifically designed to capture information from a small region of the maxilla or mandible deliver a very low *effective*

Table 1 Comparison of the effective dose of different radiographic sources and as a percentage of the annual per capita background X-ray dose

Radiographic source	Effective dose (μSv)		Dose as a % annual background radiation	
	ICRP 1990	ICRP 2005	ICRP 1990	ICRP 2005
Cone beam computed tomography				
3D Accuitomo ^a	7.3		0.2	
NewTom 3 G 12'' FOV ^b	44.5	58.9	1.2	1.6
Mercuray 9'' FOV ^b	288.9	435.5	8	12.1
Mercuray 6'' FOV ^b	168.4	283.3	4.7	7.9
i-CAT 12'' FOV ^b	134.8	193.4	3.7	5.4
i-CAT 9'' FOV ^b	68.7	104.5	1.9	2.9
Conventional computed tomography				
Conventional CT ^c	1400 (max.)		38.9%	
	1320 (mand)		36.7%	
Conventional radiography				
Panoramic ^d	6.3		0.2%	
Periapical ^c	5		0.14%	
Maxillary occlusal ^c	7		0.2%	
Cosmic radiation on board an aircraft flying a round trip between Paris & Tokyo ^e	150		4.2%	

^aArai *et al.* 2001.

^bLudlow *et al.* 2006.

^cNgan *et al.* 2003.

^dLudlow *et al.* 2003.

^eBottollier-Depois *et al.* 2003.

dose and are therefore best suited for endodontic imaging of only one tooth or two neighbouring teeth, as the *field of view* is similar in size to a conventional periapical radiograph. Indeed, the *effective dose* of the 3D Accuimotomo has been reported to be in the same order of magnitude as 2–3 standard periapical radiograph exposures (Arai *et al.* 2001), whilst the *effective dose* for a full mouth series of periapical radiographs has been reported to be of a similar order of magnitude to the *effective dose* of a large volume CBCT scan (Danforth & Clarke 2000, Gibbs 2000).

If multiple teeth in different quadrants require endodontic treatment, a large volume CBCT scan with a large *field of view* may be more appropriate. Equally, if endodontic information is required from multiple teeth in one jaw, a large volume CBCT scan with the *field of view* limited to that jaw could be the investigation of choice. This has the advantage of reducing the *effective dosage* from the full large volume CBCT scan by up to 65% (Ludlow *et al.* 2006).

Potential applications of cone beam computed tomography in the management of endodontic problems

Traditional radiographic examinations are usually limited to two-dimensional views captured using radiographic film or digital sensors. Crucially, essential information of the three-dimensional anatomy of the tooth/teeth and adjacent structures is obscured, and even with the best intentions and paralleling techniques, distortion and superimposition of dental structures in periapical views is unavoidable. A major advantage of CBCT that has been reported is the three-dimensional geometric accuracy compared with conventional radiographs (Sonick *et al.* 1994, Murmulla *et al.* 2005). Sagittal, coronal and axial CBCT images eliminate the superimposition of anatomical structures. For example, the roots of maxillary posterior teeth and their periapical tissues can be visualized separately and in all three orthogonal planes without superimposition of the overlying zygomatic buttress, alveolar bone and adjacent roots (Fig. 3).

CBCT enables periapical disease evidenced by radiolucent changes at the root apex to be detected earlier than on conventional radiographs (Fig. 4) (Lofthag-Hansen *et al.* 2007). Indeed, CBCT scans resulted in 62% more periapical radiolucent areas being detected on individual roots of posterior mandibular and maxillary teeth when compared with two-angled periapical radiographs. Endodontic treatment is more successful in teeth treated early, before obvious radiographic signs of periapical disease (Friedman 2002). Thus, earlier detection of periradicular radiolucent changes with CBCT should result in earlier identification and management of endodontic disease; this in turn should result in a better outcome from endodontic treatment as teeth could be treated sooner. In situations where patients have poorly localized symptoms associated with an untreated or previously root-filled tooth and clinical and periapical radiographic examination show no evidence of disease; CBCT may be indicated to detect the presence of previously undiagnosed periapical disease (Nakata *et al.* 2006).

Simon *et al.* (2006) compared the ability of CBCT and biopsy with histological examination to differentiate between periapical cysts and granulomas in teeth with large periapical lesions. It was stated that grey scale value measurements of periapical lesions on CBCT images were able to differentiate solid (granulomas) from cystic or cavity (cyst) type lesions. It was concluded that CBCT *may be clinically more accurate and more useful than biopsy*. If confirmed, these findings may influence the decision-making process when considering a non-surgical or surgical approach to endodontic retreatment.

Both medical CT and CBCT have already been used for the planning of periradicular endodontic surgery (Velvart *et al.* 2001, Rigolone *et al.* 2003). Three-dimensional imaging allows the anatomical relationship of the root apices to important neighbouring anatomical structures such as the inferior dental canal, mental foramen and maxillary sinus (Fig. 5) to be

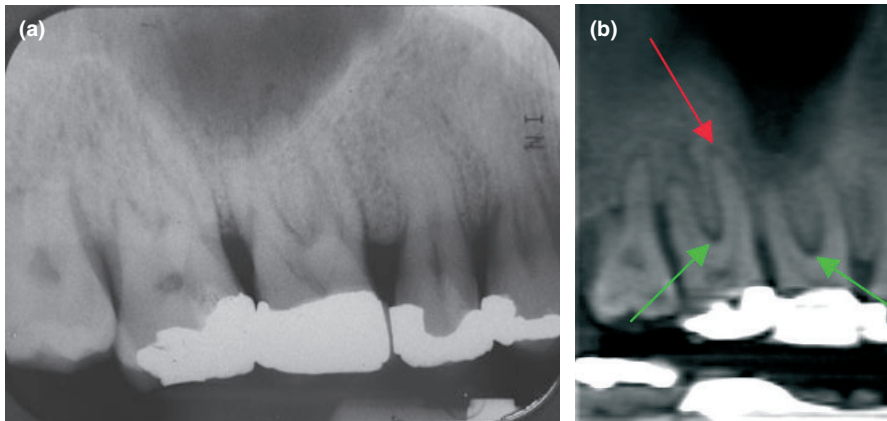


Figure 4 (a–b) This patient has undergone non-surgical periodontal treatment, the posterior teeth have not responded well to treatment, the patient was referred for an endodontic opinion of the maxillary right quadrant prior to periodontal surgery. (a) A periapical radiograph of the maxillary right quadrant was inconclusive. (b) CBCT sagittal slice reveals periapical radiolucencies (red arrows) associated with teeth 16 and 17, and furcation (green arrows) involvement.

clearly identified. Velvart *et al.* (2001) found that the relationship of the inferior dental canal to the root apices could be determined in every case when using medical CT, but in less than 40% of cases when using conventional radiography. It is likely that similar results could be achieved with CBCT using considerably less radiation. Rigolone *et al.* (2003) concluded that CBCT may play an important role in periapical microsurgery of palatal roots of maxillary first molars. The distance between the cortical plate and the palatal root apex could be measured, and the presence or absence of the maxillary sinus between the roots could be assessed.

In addition, the thickness of the cortical plate, the cancellous bone pattern, fenestrations, the shape of the maxilla and mandible as well as the inclination of the roots of teeth planned for periapical surgery should be able to be determined before starting surgery (Nakata *et al.* 2006). Root morphology can be visualized in three dimensions, as can the number of root canals and whether they converge or diverge from each other. Unidentified (and untreated) root canals in root filled teeth may be identified using axial slices (Fig. 3) which may not be readily identifiable with periapical radiographs even if taken at different angles. The true size, location and extent of periapical disease should finally be appreciated, whilst the actual root to which the lesion is associated should be able to be identified with confidence.

CBCT may also prove useful in the diagnosis of dento-alveolar trauma, because the exact nature and severity of alveolar and luxation injuries can be assessed from just one scan (Fig. 6). It has been reported that CBCT has been used to detect a horizontal root fracture (Terakado *et al.* 2000). The same fracture may have needed multiple periapical radiographs taken at several different angles to be detected and even then may not have been visualized. Recently CBCT scans (Fig. 7) have been successfully used in the management of external cervical resorption lesions (Patel & Dawood 2007).

Perhaps the most exciting area in which CBCT may be applied in endodontics is in determining the outcome of treatment. Detailed CBCT scans should result in a more objective and therefore more accurate determination of the outcome of endodontic treatment. The CBCT images are geometrically accurate (Murmulla *et al.* 2005) and there is no distortion of the teeth being assessed or superimposition of overlying anatomy as often seen with conventional film and digitally captured periapical radiographs. Future research may show that root-filled teeth that appear to have 'healed' on conventional

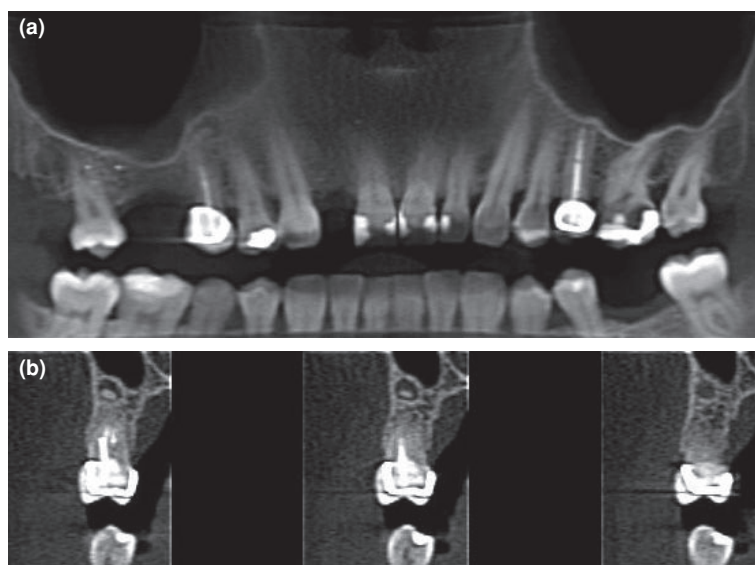


Figure 5 (a) Panoramic (b) coronal CBCT views. Tooth 15 has a failing endodontic treatment, and has been scheduled for periapical microsurgery. The CBCT scan is helpful in this situation as it provides vital information on the extent of the periapical lesion and its proximity to the floor of the maxillary sinus.

radiographs may still have signs of periapical disease (e.g. widened periodontal ligament space, periapical radiolucency) when imaged using CBCT. This in turn may have implications for decision making and selection criteria when considering (re-) placing coronal restorations on teeth which have previously been endodontically treated and appear to have successfully healed radiographically (Faculty of General Dental Practitioners UK, 2004).

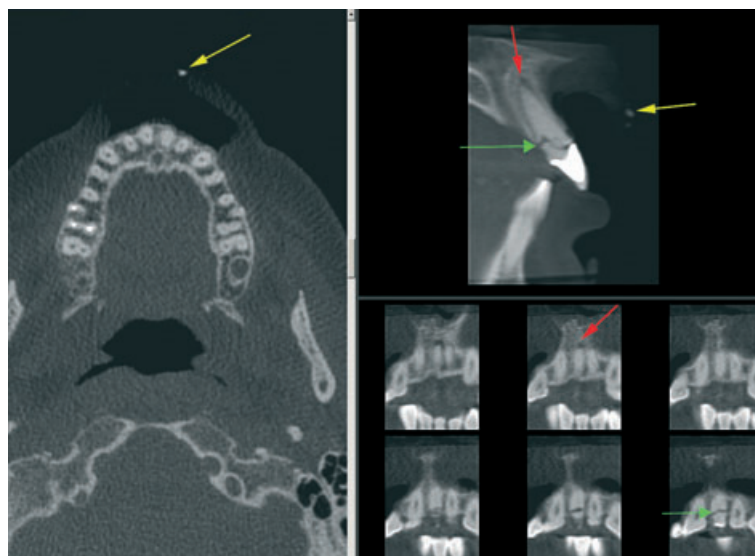


Figure 6 A single CBCT scan used in the management of a luxation injury. The axial (left) and sagittal (top right) views reveal the presence and exact location of the fractured portion of the crown fragment (yellow arrow) in the upper lip, the scan also reveals an oblique fracture of tooth 21 (green arrow) and widened labial apical-third periodontal space as a result of a lateral luxation injury (red arrow).

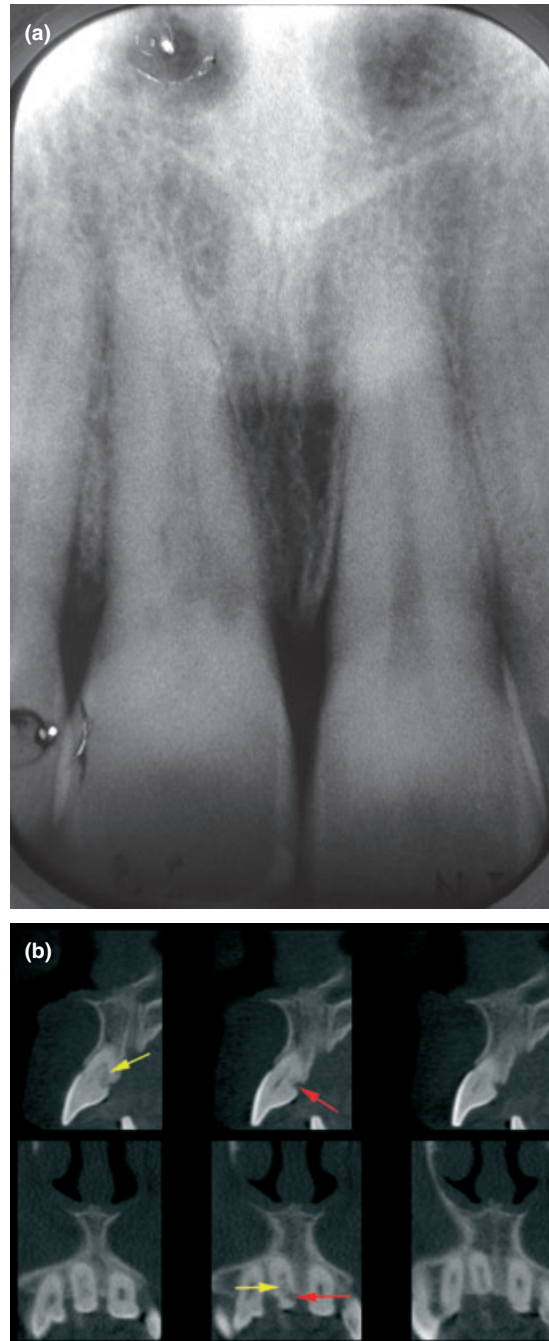


Figure 7 (a) Periapical radiograph reveals external cervical resorption in tooth 11. CBCT images reveal the exact location and dimensions of the resorptive lesion. (b) Sagittal (top) and axial (bottom) slices reveal the true nature of the lesion, the resorptive lesion has two distinct areas. The outer portion (red arrow) has the classical appearance of external cervical resorption, (i.e. radiolucent lesion with irregular borders), and the inner portion (yellow arrow) which has a mottled appearance (which was not completely detectable on the periapical radiographs), suggesting this portion of the lesion contained fibro-osseous tissue.

It is worth remembering that CBCT still uses ionizing radiation and is not without risk. It is essential that patient radiation exposure is kept as low as reasonably practicable and that evidence-based *selection criteria* for CBCT are developed. Endodontic cases should be judged individually and until further evidence is available, CBCT should only be considered when it has been decided that conventional radiographic view(s) are yielding limited information, and that further radiographic details are required for diagnosis and treatment planning.

Conclusion

Radiological examination is an essential part of the diagnosis and management of endodontic disease. At present, radiological examination is usually limited to two-dimensional periapical images. Crucially, essential information of the three-dimensional anatomy of the tooth/teeth and adjacent anatomy is not visible, even with the best intentions and paralleling techniques. CBCT should provide an effective and safe way to overcome some of these problems and may, in time, change the way in which the outcome of endodontic treatment is assessed.

Acknowledgements

Cavendish Imaging, London, UK.

Disclaimer

Whilst this article has been subjected to Editorial review, the opinions expressed, unless specifically indicated, are those of the author. The views expressed do not necessarily represent best practice, or the views of the IEJ Editorial Board, or of its affiliated Specialist Societies.

References

- Arai Y, Tammisalo E, Iwai K, Hashimoto K, Shinoda K (1999) Development of a compact computed tomographic apparatus for dental use. *Dentomaxillofacial Radiology* **28**, 245–8.
- Arai Y, Honda K, Iwai K, Shinoda K (2001) Practical model '3DX' of limited cone-beam X-ray CT for dental use. *International Congress Series* **1230**, 713–8.
- Bottollier-Depois JF, Chau Q, Bouisset P, Kerlau G, Plawinski L, Lebaron-Jacobs L (2003) Assessing exposure to cosmic radiation on board aircraft. *Advanced Space Research* **32**, 59–66.
- Danforth RA, Clarke DE (2000) Effective doses from radiation absorbed during a panoramic examination with a new generation machine. *Oral Surgery, Oral Medicine, Oral Pathology, Oral Radiology and Endodontics* **89**, 236–43.
- Enciso R, Danforth RA, Alexandroni ES, Memon A, Mah J (2005) Third-molar impaction diagnostic with cone-beam computerized tomography. *CARS International Congress Series* **1281**, 1196–9.
- Exadaktylos AK, Sclabas GM, Smolka K, Rahal A, Andreas RH, Iizuka T (2005) The value of computed tomographic scanning in the diagnosis and management of orbital fractures associated with head trauma: a prospective study at a level 1 trauma center. *Journal of Trauma* **58**, 336–441.
- Faculty of General Dental Practitioners (UK) (2004) The Royal College of Surgeons of England. *Selection criteria for dental radiography. FGDP (UK) Good Practice Guidelines*. London, UK.
- Finkle DR, Ringer SL, Luttenton CR, Beernink JH, Peterson NT, Dean RE (1985) Comparison of the diagnostic methods used in maxillofacial trauma. *Plastic Reconstructive Surgery* **75**, 32–41.
- Friedman S (2002) Prognosis of initial endodontic therapy. *Endodontic Topics* **2**, 59–98.

- Gibbs SJ (2000) Effective does equivalent and effective dose: comparison for common projections in oral and maxillofacial radiology. *Oral Surgery, Oral Medicine, Oral Pathology, Oral Radiology and Endodontics* **90**, 538–45.
- Gröndahl H-G, Huuononen S (2004) Radiographic manifestations of periapical inflammatory lesions. *Endodontic Topics* **8**, 55–67.
- Hounsfield GN (1973) Computerised transverse axial scanning (tomography): part 1. Description of system. *British Journal of Radiology* **46**, 1016–22.
- ICRP (1990) ICRP Publication 60: recommendations of the International Commission on Radiological Protection. *Annals of the ICRP* **21**, 1–201.
- ICRP (2005) Draft Recommendations of the International Commission on Radiological Protection. Available at: www.icrp.org/docs/2005_recs_consultation_draft_1a.pdf.
- Lofthag-Hansen S, Huuononen S, Gröndahl K, Gröndahl H-G (2007) Limited cone-beam CT and intraoral radiography for the diagnosis of periapical pathology. *Oral Surgery, Oral Medicine, Oral Pathology, Oral Radiology and Endodontology* **103**, 114–9.
- Ludlow JB, Davies-Ludlow LE, Brooks SL (2003) Dosimetry of two extraoral direct imaging devices: NewTom cone beam CT and Orthophos Plus DS panoramic unit. *Dentomaxillofacial Radiology* **32**, 229–34.
- Ludlow JB, Davies-Ludlow LE, Brooks SL, Howerton WB (2006) Dosimetry of 3 CBCT devices for oral and maxillofacial radiology: CB Mercuray, NewTom 3 G and i-CAT. *Dentomaxillofacial Radiology* **35**, 219–26.
- Mah J, Hatcher D (2004) Three-dimensional craniofacial imaging. *American Journal of Orthodontics and Dentofacial Orthopedics* **126**, 308–9.
- Mozzo P, Procacci C, Tacconi A, Martini PT, Andreis IA (1998) A new volumetric CT machine for dental imaging based on the cone-beam technique: preliminary results. *European Radiology* **8**, 1558–64.
- Murmulla R, Wörtche R, Mühling J, Hassfeld S (2005) Geometric accuracy of the NewTom 9000 Cone Beam CT. *Dentomaxillofacial Radiology* **34**, 28–31.
- Nakata K, Naitoh M, Izumi M, Inamoto K, Arijji E, Nakamura H (2006) Effectiveness of dental computed tomography in diagnostic imaging of periradicular lesion of each root of a multirrooted tooth: a case report. *Journal of Endodontics* **32**, 583–7.
- Ngan DCS, Kharbanda OP, Geenty JP, Darendeliler MA (2003) Comparison of radiation levels from computed tomography and conventional dental radiographs. *Australian Dental Journal* **19**, 67–75.
- Patel S, Dawood A (2007) The use of cone beam computed tomography in the management of external cervical resorption lesions. *International Endodontic Journal*, **40**, 730–7.
- Rigolone M, Pasqualini D, Bianchi L, Berutti E, Bianchi SD (2003) Vestibular Surgical Access to the Palatine Root of the Superior First Molar: "Low-dose Cone-beam" CT analysis of the Pathway and its Anatomic Variations. *Journal of Endodontics* **29**, 773–5.
- Scarfe CS (2005) Imaging of maxillofacial trauma: evolutions and emerging revolutions. *Oral Surgery, Oral Medicine and Oral Pathology, Oral Radiology and Endodontics* **100**, 575–96.
- Schwartz MS, Rothman SLG, Rhodes ML, Chafetz N (1987) Computed tomography: part II. Preoperative assessment of the maxilla for endosseous implant surgery. The International. *Journal of Oral Maxillofacial Implants* **2**, 143–9.
- Simon JHS, Enciso R, Malfaz J-M, Roges R, Bailey-Perry M, Patel A (2006) Differential diagnosis of large periapical lesions using cone-beam computed tomography measurements and biopsy. *Journal of Endodontics* **32**, 833–7.
- Sonick M, Abrahams J, Faiella RA (1994) A comparison of the accuracy of periapical, panoramic, and computerized tomographic radiographs in locating the mandibular canal. *The International Journal of Oral Maxillofacial Implants* **9**, 455–60.
- Sukovic P (2003) Cone beam computed tomography in craniofacial imaging. *Orthodontic Craniofacial Research* **6**(Suppl. 1), 31–6.
- Terakado M, Hashimoto K, Arai Y, Honda M, Sekiwa T, Sato H (2000) Diagnostic imaging with newly developed ortho cubic super-high resolution computed tomography (Ortho-CT). *Oral Surgery, Oral Medicine and Oral Pathology, Oral Radiology and Endodontics* **89**, 509–18.

- Velvart P, Hecker H, Tillinger G (2001) Detection of the apical lesion and the mandibular canal in conventional radiography and computed tomography. *Oral Surgery, Oral Medicine, Oral Pathology, Oral Radiology and Endodontics* **92**, 682–8.
- Zeigler CM, Woertche R, Brief J, Hassfield S (2002) Clinical indications for digital volume tomography in oral and maxillofacial surgery. *Dentomaxillofacial Radiology* **28**, 126–30.

This document is a scanned copy of a printed document. No warranty is given about the accuracy of the copy. Users should refer to the original published version of the material.