

## CASE REPORT

# Intentional replantation for the management of maxillary sinusitis

**M. Peñarrocha<sup>1</sup>, B. García<sup>1</sup>, E. Martí<sup>2</sup>, M. Palop<sup>3</sup> & T. von Arx<sup>4</sup>**

<sup>1</sup>Department of Oral Surgery, University of Valencia, Valencia, Spain; <sup>2</sup>Private practice, Valencia, Spain; <sup>3</sup>ENT specialist, Alcoy, Spain; and <sup>4</sup>Department of Oral Surgery and Stomatology, University of Berne, Berne, Switzerland

### Abstract

**Peñarrocha M, García B, Martí E, Palop M, von Arx T.** Intentional replantation for the management of maxillary sinusitis. *International Endodontic Journal*, **40**, 891–899, 2007.

**Aim** To present a case that emphasizes the importance of the use of intentional replantation as a technique to successfully treat a periapical lesion and an odontogenic maxillary sinusitis through the alveolus at the same time.

**Summary** This case report presents a patient with odontogenic maxillary sinusitis secondary to periapical disease of a maxillary molar that had previously received root canal treatment. The molar was extracted, with drainage and rinsing of the maxillary sinus. The apices were resected extra-orally, the retrograde cavities prepared with ultrasound and retrograde fillings of silver amalgam placed. The tooth was then replanted. After 2 years, the patient was asymptomatic, periapical radiography showed no evidence of root resorption and computed tomography scanning demonstrated the resolution of maxillary sinusitis.

### Key learning points

- When root canal treatment or periapical surgery cannot be undertaken or has failed, intentional replantation may be considered.
- This alternative treatment may be predictable in certain cases.

**Keywords:** intentional replantation, maxillary sinusitis, periapical surgery.

Received 30 October 2006; accepted 5 March 2007

### Introduction

The posterior maxillary teeth are in close relation to the maxillary sinus (Waite 1971, Bailey 1998, von Arx *et al.* 2001), and in up to 40% of cases the molar roots establish contact with the floor of the maxillary sinus (Bailey 1998). Maxillary sinusitis may be of infectious origin, because periapical infection of dental origin can spread towards the maxillary sinus (Peñarrocha *et al.* 1997, Bogaerts *et al.* 2003). It may also constitute a complication of

Correspondence: Miguel Peñarrocha-Diago, Unidad Médico-Quirúrgica, Clínica Odontológica, Gascó Oliag 1, Valencia 46010, Spain (Tel.: +34-96-3864144; e-mail: miguel.penarrocha@uv.es).

extractions, endodontic treatments (Theaker *et al.* 1995) and periradicular surgery (Dierickx & Bossuyt 1981).

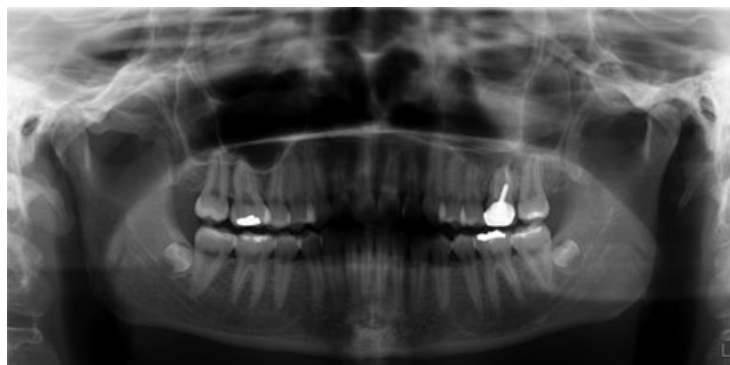Intentional replantation (IR) is the planned extraction and reinsertion of a tooth into its socket to correct an apparent clinical or radiographic endodontic failure (Ward 2004). This procedure differs from the reinsertion of a tooth after an accidental avulsion (Bender & Rossman 1993).

This case report presents the management of a patient with maxillary sinusitis secondary to periapical disease of a root canal treated maxillary molar that was treated by IR.

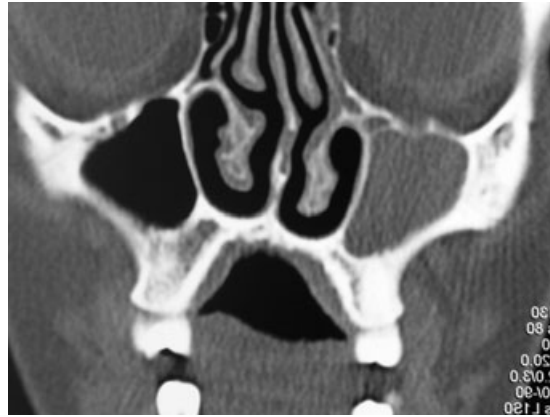
### Clinical case

A 20-year-old woman presented with a 4-month history of continuous mild pain on the left side of her face that increased with physical exertion. The intensity of pain had increased in recent days. Tooth 26, which had been root filled 8 months before, had a ceramo-metal crown and pain on percussion. The patient showed no signs of fever, cold or flu symptoms. Periodontal probing depths did not exceed 3 mm, and there was no pathological mobility. Pressure to the left malar process was painful. The panoramic radiograph revealed a root filled tooth 26 with a post and a periapical radiolucency (Fig. 1). Computed tomography (CT) revealed the left maxillary sinus to be filled with material of liquid density, with the diagnosis of odontogenic maxillary sinusitis (Fig. 2).

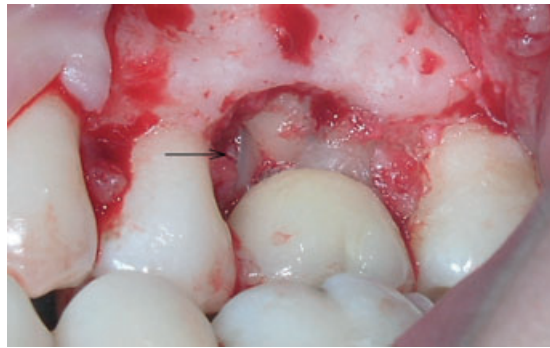Periapical surgery of the affected molar was proposed. Under local anaesthesia (4% articaine and adrenaline 1 : 100 000) (Laboratorios Inibsa, SA, Lliça de Vall, Barcelona, Spain) a triangular full-thickness flap was raised from distal tooth 24 to distal of tooth 27. After lifting the flap, loss of the buccal cortical bone, 4 mm in height, and an apparent small radicular fracture was observed (Fig. 3 arrow), consequently it was decided not to continue with the periapical surgery, and the tooth was extracted as atraumatically as possible and purulent material was drained (Fig. 4). On extraction, a radicular defect was detected but no fracture was found, so an intentional replantation (IR) procedure was proposed. During the extra-oral period, the periodontal tissue was frequently irrigated with sterile saline solution. The alveolus was subjected to curettage, in order to remove the inflammatory tissue and part of the affected sinus membrane. The maxillary sinus was irrigated with abundant sterile saline solution. Root-end resection of the molar tooth was performed extra-orally, with ultrasound and root-end filling using silver amalgam (Fig. 5). This procedure took approximately 5 min. Thereafter, the tooth was replanted (Fig. 6) and secured with 3-0 silk suture (Lorca-Marin®, Murcia, Spain) crossing the occlusal surface of the tooth (Raghoobar & Vissink 1999). The occlusion was adjusted in order to ensure



**Figure 1** Panoramic radiograph view showing an endodontically treated maxillary molar with a post and a periapical radiolucency. There was a close relation between the apices of tooth 26 and the sinus.



**Figure 2** Computed tomography showing the filled left maxillary sinus with material of liquid density, with the diagnosis of odontogenic maxillary sinusitis.



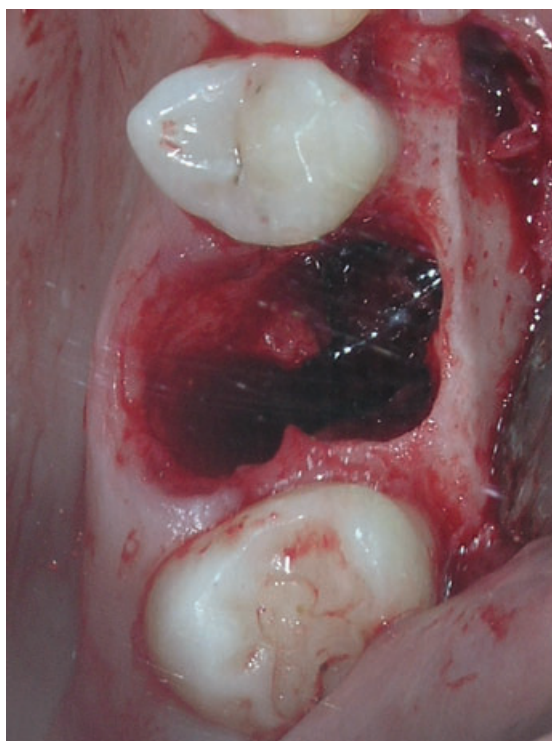
**Figure 3** After lifting the flap, a mesial radicular fracture of the tooth was found (arrow).

the tooth to be free of interference. A panoramic radiograph after periapical surgery revealed the root-end filling of the apices projecting into the maxillary sinus (Fig. 7). Augmentine® (GlaxoSmith Kline, SA, Madrid, Spain) 875/125 mg/8 h for 10 days; ibuprofen (Bexistar®; Laboratorio Bacino, Barcelona, Spain) 600 mg/8 h during 4 days; 0.12% chlorhexidine rinses (GUM®; John O. Butler CO, A Sunstar Company, Chicago, IL, USA) three times a day for 7 days were prescribed.

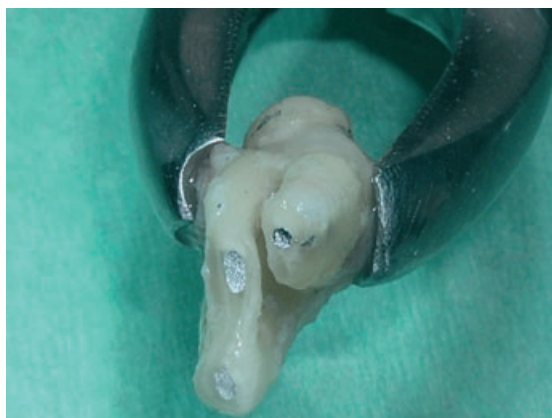The sutures were removed 1 week after surgery, and good healing of the soft tissues was noted. The patient had no pain or discomfort during the postoperative period. After 3 months the patient was asymptomatic, percussion was negative and the CT revealed a slight enlargement of the sinus membrane (Fig. 8). A new ceramo-metal crown was placed. After 2 years, the patient was asymptomatic and there was no pathological mobility, good gingival health and no periodontal pocket (Fig. 9). A periapical film revealed no root resorption and complete bone regeneration (Fig. 10). The root surface and periodontal ligament appeared intact; moreover, a CT control demonstrated the resolution of maxillary sinusitis, with just slight residual enlargement of the sinus membrane (Fig. 11).

## Discussion

In the case of maxillary sinusitis resulting from chronic periapical disease of a maxillary posterior tooth, the underlying cause must be eliminated in conjunction with treatment of the maxillary sinusitis.

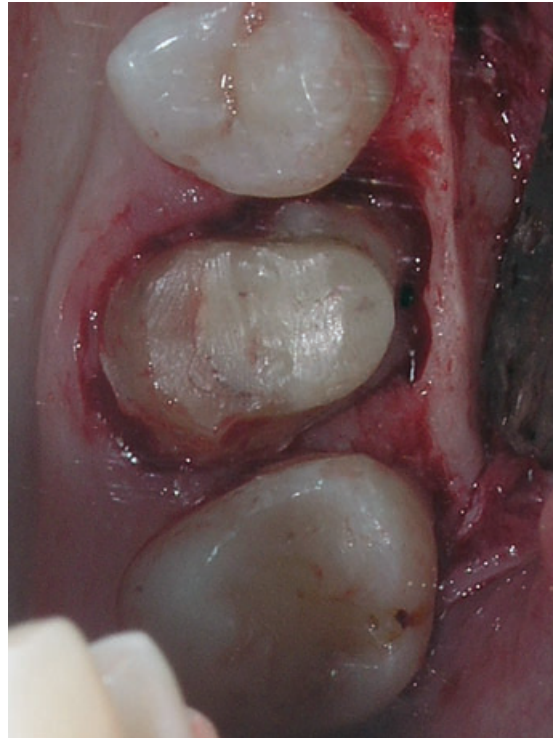

**Figure 4** The tooth was removed as atraumatically as possible to minimize damage to the periodontal ligament, the buccal and lingual bone, and the interradiacal bony septum.

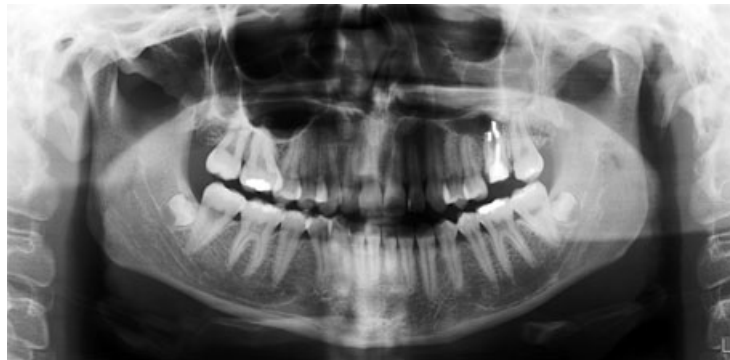

**Figure 5** Root-end resection of the molar was performed extra-orally, with ultrasound and retrograde filling with silver amalgam.

Four options have been proposed: removal of the tooth and drainage of the maxillary sinus (Dierickx & Bossuyt 1981, Sandler 1999); conventional endodontic re-treatment (Bogaerts *et al.* 2003); trans-antral periapical surgery, eliminating the lesion from a vestibular approach (Wallace 1996) with performance of a Caldwell-Luc procedure (Politi *et al.* 1990), or root-end resection and root-end filling extra-orally and IR of the tooth (Marcantonio *et al.* 1974, Weine 1980, Dryden 1986, Bender & Rossman 1993, Benenati 2003, Chandra & Bhat 2006).

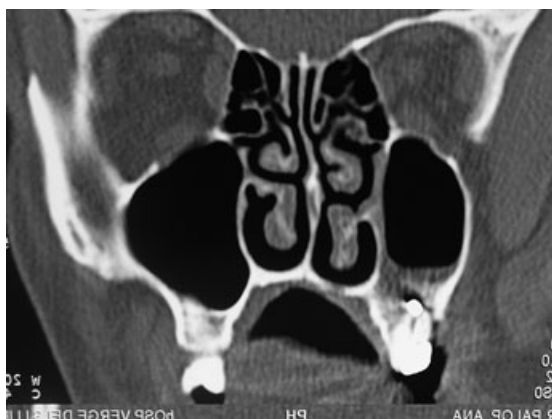

**Figure 6** The tooth was carefully replanted in the socket.

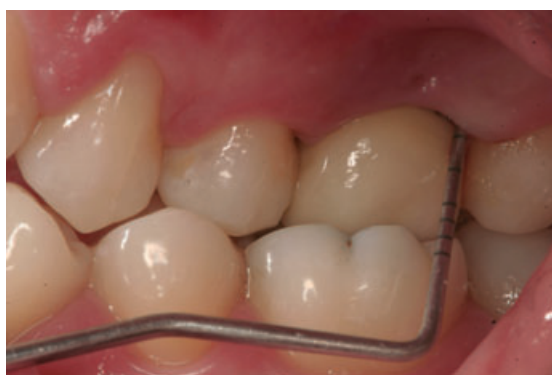

**Figure 7** Panoramic radiography after periapical surgery.

In the present case, conventional endodontic re-treatment was not possible due to the presence of a post (Cotter & Panzarino 2006) and an extensive restoration in the maxillary molar, with the consequent risk of fracturing the root on post-removal, or the impossibility of reconstructing the tooth. Furthermore, any re-treatment would not have allowed the drainage of the purulent material from the maxillary sinus. Initially it was planned to carry out the periapical surgery trans-antrally in order to eliminate the periapical lesion, drain the maxillary sinus and fill the canals with root-end fillings. However, the tooth was extracted because of the apparent existence of a radicular fracture. On extraction, although there was a radicular defect, there was no fracture. Therefore, following drainage of the maxillary sinus the IR, not planned at the beginning of the surgery, was performed. If the tooth had been removed, not only would a chronic oral-antral communication have



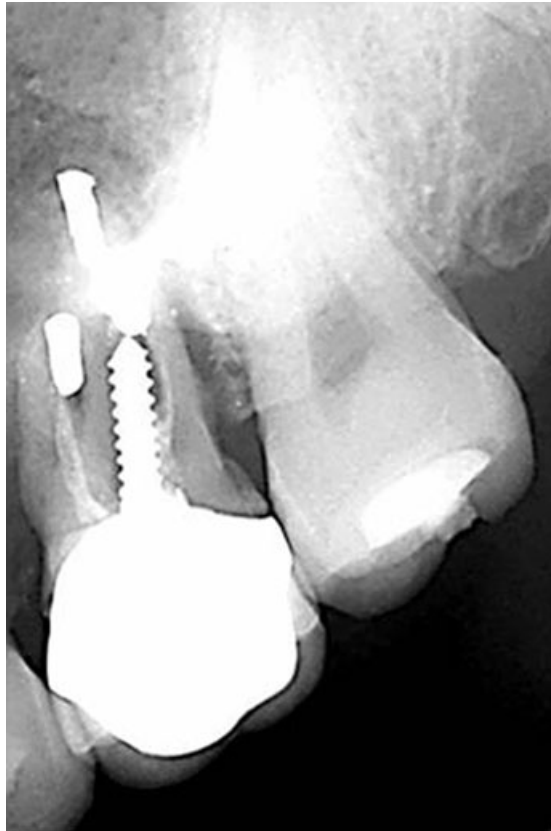**Figure 8** The computed tomography image 3 months after surgery showing minimal thickening in the sinus membrane.



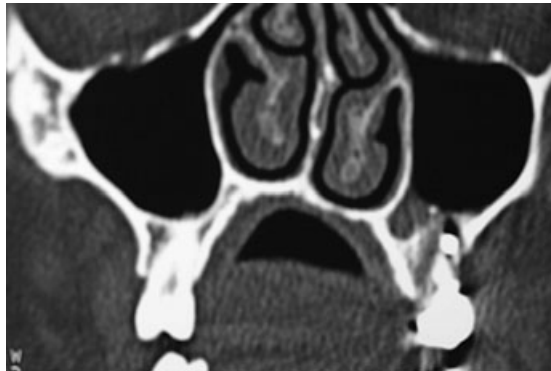
**Figure 9** Clinical image showing the periodontal probe; no periodontal pocket was found.

resulted, but an important bone defect would also have been produced requiring regeneration before dental implant placement. Moreover, implant placement in a patient with previous maxillary sinusitis would have needed a control CT to confirm healing of the maxillary sinus. Extraction, periapical surgery of the tooth and replantation made it possible to preserve the tooth that would otherwise have needed extraction, and thus avoid a possible antral communication. In addition, this approach made it possible to directly treat the sinusitis with drainage of purulent material through the alveolus, irrigate it with sterile saline solution and provide antibiotic coverage (Marcantonio *et al.* 1974, Peñarrocha *et al.* 1997).

Bender & Rossman (1993) carried out the IR of 31 teeth following periapical surgery outside the mouth, with an overall success rate of 80.6%. The survival periods varied from 1 day to 22 years. Of these, four were maxillary molars with a success rate of 66.7%. The authors propose some indications and contraindications for IR. Raghoobar & Vissink (1999) treated 29 patients with IR of molars as conventional periapical surgery was not possible. Twenty-one molars (72%) were successfully treated. Recently, Chandra & Bhat (2006) presented an IR of a mandibular second molar. After 20 years of follow-up, the patient was asymptomatic and the tooth remained functional with no evidence of gross root resorption or ankylosis. Furthermore, Tözüm *et al.* (2006) used autologous platelet-rich plasma to treat a periodontally mandibular right central incisor. They observed new bone formation around the apical portion of the root.



**Figure 10** After 2 years of follow-up, the periapical film showed no evidence of root resorption, and the root surface and periodontal ligament appeared intact.



**Figure 11** Computed tomography control showing no pathology at 2 years follow-up.

In IR procedures, failures are associated with replacement resorption and ankylosis as a result of degeneration or missing periodontal ligament, pulp disease and periapical infection (Bender & Rossman 1993, Benenati 2003).

In the present case, the molar was outside the mouth for approximately 5 min, manipulation was kept to a minimum, and the periodontal ligament was not removed as recommended by most authors (Garcia & Shaffar 1990, Gonda *et al.* 1990, Messkoub

1991). The best reimplantation prognosis is directly related to the amount of time the tooth is maintained extra-orally during the procedure (Benenati 2003). From some reports (Andreasen & Hjorting-Hansen 1966, Raghoobar & Vissink 1999) the potential for resorption in replanted teeth increases if they remain outside the mouth for more than 30 min.

After lifting the full-thickness flap, loss of the buccal plate 4 mm in height was observed, but without mobility. Wang *et al.* (2004) found longer survival in teeth with loss of the buccal plate less than 4 mm and, Zuolo *et al.* (2000) preferred not to treat teeth with loss of the entire buccal cortical bone. In this clinical case, a tooth with partial loss of the cortical bone, perhaps related to the small radicular defect, was successfully treated with extra-oral root-end resection and reimplantation, and no mobility was observed at 2 years follow-up.

### Conclusions

Some authors consider IR to be a last resort; whereas others consider it as another treatment modality for posterior teeth. This alternative treatment may be predictable and suggested for certain cases when routine re-treatment cannot be undertaken or has failed, where periapical surgery would either be impracticable or unlikely to succeed, or when extraction is the only alternative.

### Disclaimer

Whilst this article has been subjected to Editorial review, the opinions expressed, unless specifically indicated, are those of the author. The views expressed do not necessarily represent best practice, or the views of the IEJ Editorial Board, or of its affiliated Specialist Societies.

### References

- Andreasen JO, Hjorting-Hansen E (1966) Replantation of teeth. Part II. Histological study of 22 replanted anterior teeth in humans. *Acta Odontologica Scandinavica* **24**, 287–308.
- von Arx T, Gerber C, Hardt N (2001) Periradicular surgery of molars: a prospective clinical study with a one-year follow-up. *International Endodontic Journal* **34**, 520–5.
- Bailey BJ (1998). *Head and Neck Surgery – Otolaryngology*. Philadelphia, USA: Lippincott-Raven Publishers.
- Bender IB, Rossman LE (1993) Intentional replantation of endodontically treated teeth. *Oral Surgery, Oral Medicine and Oral Pathology* **76**, 623–30.
- Benenati FW (2003) Intentional replantation of a mandibular second molar with long-term follow-up: report of a case. *Dental Traumatology* **19**, 233–6.
- Bogaerts P, Hanssens JF, Siquet JP (2003) Healing of maxillary sinusitis of odontogenic origin following conservative endodontic retreatment: case reports. *Acta Otorhinolaryngologica Belgica* **57**, 91–7.
- Chandra RV, Bhat KM (2006) Twenty-year follow-up of an intentional replantation. *Journal of the Canadian Dental Association* **72**, 639–42.
- Cotter MR, Panzarino J (2006) Intentional replantation: a case report. *Journal of Endodontics* **32**, 579–82.
- Dierickx A, Bossuyt M (1981) Maxillary sinusitis of dental origin. *Revue Belge de Médecine Dentaire* **36**, 67–75.
- Dryden J (1986) Ten-year follow-up of intentionally replanted mandibular second molar. *Journal of Endodontics* **12**, 265–7.
- Garcia A, Shaffar JL (1990) Bone reactions around transplanted roots. A 5-month quantitative study in dogs. *Journal of Clinical Periodontology* **17**, 211–6.



- Gonda F, Nagase M, Chen RB, Yakata H, Nakajima T (1990) Replantation: an analysis in 29 teeth. *Oral Surgery, Oral Medicine and Oral Pathology* **70**, 650–5.
- Marcantonio E, Ramalho AC, Leonardo MR, Comelli Lia RC, Gullo N (1974) Tooth reimplant followed by apicoectomy: clinical, radiographic and historical considerations. *Revista Brasileira de Odontologia* **31**, 150–4.
- Messkoub M (1991) Intentional replantation: a successful alternative for hopeless teeth. *Oral Surgery, Oral Medicine and Oral Pathology* **71**, 743–7.
- Peñarrocha M, Gregori R, Bagán JV, Sanchis JM, Peñarrocha MA (1997) Sinusitis de origen odontogénico: presentación de cinco casos clínicos y revisión de la literatura. *Archivos de Odontoestomatología* **13**, 100–9.
- Politi M, Rossetti G, Consolo U, Nocini PF, Fugazzola C (1990) Odontogenic sinusitis. An evaluation and radiographic checkup protocol after a Cadwell-Luc intervention. *Minerva Stomatologica* **39**, 119–22.
- Raghoobar GM, Vissink A (1999) Results of intentional replantation of molars. *Journal of Oral and Maxillofacial Surgery* **57**, 240–4.
- Sandler HJ (1999) Clinical update – the teeth and the maxillary sinus: the mutual impact of clinical procedures, disease conditions and their treatment implications. Part 2. Odontogenic sinus disease and elective clinical procedures involving the maxillary antrum: diagnosis and management. *Australian Endodontic Journal* **25**, 32–6.
- Theaker ED, Rushton VE, Corcoran JP, Hatton P (1995) Chronic sinusitis and zinc-containing endodontic obturating pastes. *British Dental Journal* **22**, 179, 64–8.
- Tözüm TF, Keçeli HG, Serper A, Tuncel B (2006) Intentional replantation for a periodontally involved hopeless incisor by using autologous platelet-rich plasma. *Oral Surgery Oral Medicine Oral Pathology Oral Radiology and Endodontics* **101**, e119–24.
- Waite DE (1971) Maxillary sinus. *Dental Clinics of North America* **15**, 349–68.
- Wallace JA (1996) Transantral endodontic surgery. *Oral Surgery, Oral Medicine, Oral Pathology, Oral Radiology and Endodontics* **82**, 80–3.
- Wang Q, Cheung GS, Ng RP (2004) Survival of surgical endodontic treatment performed in a dental teaching hospital: a cohort study. *International Endodontic Journal* **37**, 764–75.
- Ward J (2004) Intentional replantation of a lower premolar. *Australian Endodontic Journal* **30**, 99–102.
- Weine FS (1980) The case against intentional replantation. *Journal American Dental Association* **100**, 664–8.
- Zuolo ML, Ferreira MOF, Gutmann JL (2000) Prognosis in periradicular surgery: a clinical and prospective study. *International Endodontic Journal* **33**, 91–8.

This document is a scanned copy of a printed document. No warranty is given about the accuracy of the copy. Users should refer to the original published version of the material.