



CASE REPORT

A novel technique for the removal of fractured instruments in the apical third of curved root canals

M. Rahimi & P. Parashos

School of Dental Science, The University of Melbourne, Melbourne, Victoria, Australia

Abstract

Rahimi M, Parashos P. A novel technique for the removal of fractured instruments in the apical third of curved root canals. *International Endodontic Journal*, **42**, 264–270, 2009.

Aim To report on a conservative approach for removal of a fractured file in the severely curved apical portion of the distobuccal canal of a mandibular molar.

Summary With the assistance of stainless steel hand files and a chloroform-dipped gutta-percha cone, a fractured rotary NiTi instrument was successfully removed. The use of this technique may assist in removal of loose instrument fragments that are not easily accessible to other removal techniques.

Key learning points

- Instrument fractures do not always lead to an unfavourable prognosis and their removal from the apical third of curved canals should not be routinely attempted.
- The case highlights that it is possible to conservatively remove loosely bound objects from the hard-to-reach areas of the root canal system.

Keywords: chloroform-dipped gutta-percha, curved mandibular molar, fractured instrument.

Received 10 March 2008; accepted 13 July 2008

Introduction

Instrument fractures within the root canal during root canal treatment are an unwanted and frustrating complication. Fracture often results from incorrect use or overuse of an endodontic instrument, and seems to occur most commonly in the apical third of a root canal (Crump & Natkin 1970, Al-Fouzan 2003, Ankrum *et al.* 2004, Parashos & Messer 2004). A number of studies have concluded that attempts at removing fractured instruments in the apical third are often unsuccessful and may lead to unwanted effects such as excessive dentine removal and weakening of the tooth, ledge formation, root

Correspondence: Mehdi Rahimi, School of Dental Science, The University of Melbourne, 720 Swanston Street, Melbourne, Victoria 3010, Australia (Tel.: + 61 3 9348 1570; fax: +61 3 9341 1595; e-mail: mehdi@mail.usyd.edu.au).

perforation and apical extrusion of the fragment into the periradicular tissues (Nagai *et al.* 1986, Ward *et al.* 2003a,b, Souter & Messer 2005, Suter *et al.* 2005). Therefore, when an instrument fractures in the root canal, the clinician must evaluate carefully the options of attempting to remove the instrument, attempting to bypass the instrument, or preparing and filling to the fractured instrument (Suter *et al.* 2005). The chances of successful removal must be weighed against potential complications (Parashos & Messer 2006). Furthermore, only a limited number of studies have examined the influence of instrument fracture on the outcome of endodontic treatment (Crump & Natkin 1970, Spili *et al.* 2005). The authors of these studies have suggested that prognosis may ultimately depend on the stage of canal preparation when the instrument fracture occurs, reflecting the extent to which microbial control is compromised (Crump & Natkin 1970, Spili *et al.* 2005). Hence, not all fractured instruments have a negative impact on prognosis. Despite all of the above considerations, at times the clinician may be faced with a situation where a fractured instrument may be loosely bound in the canal system, but is located in hard-to-reach areas that do not allow direct vision or straight-line access. In these situations, the clinician faces the dilemma of how to remove the fractured instrument. Until now, no device or instrument removal technique has been described that can result in successful and conservative removal of fractured instruments in the hard-to-reach areas of the canal system. The following case report describes an example of such a clinical scenario.

Case report

A 13-year-old male was referred to the Endodontic Unit, University of Melbourne, Australia, regarding endodontic management of the mandibular right first molar (tooth 46). At the time of examination, an access cavity had been prepared and pulp extirpation performed as a result of irreversible pulpitis.

On presentation, the tooth exhibited no discomfort to percussion or palpation. A detailed radiographic examination of the roots of tooth 46 revealed that both mesial and distal roots had a periapex with slightly widened periodontal ligament spaces, and the distal root had a severe apical curvature (Fig. 1).

Root canal treatment was initiated. Four canals were negotiated with size 6, 8, 10 and 15 stainless steel hand files to their apices. A combination of rotary NiTi RaCe (FKG,

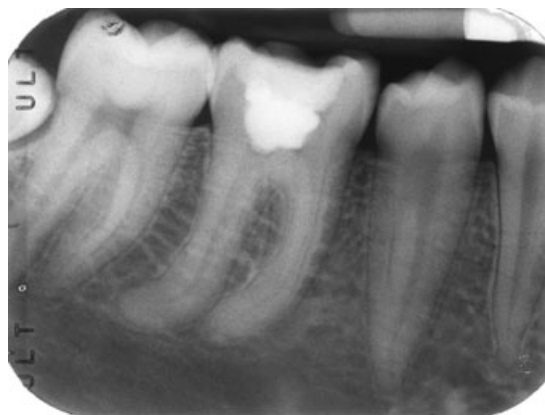


Figure 1 Preoperative radiograph showing tooth 46 with a distinct 80–85° apical curvature in the distal root. There is a slight widening of the lamina dura/periodontal ligament space associated with both roots.

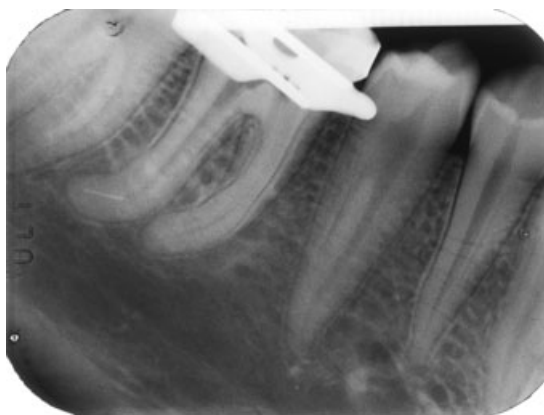


Figure 2 Radiograph showing a fractured 25/0.02 RaCe rotary file in the distobuccal canal.

LaChaux De Fonds, Switzerland) and Flexmaster (Gunz Dental, VDW, Munich, Germany) files were used to prepare all four canals. During preparation of the distobuccal canal, approximately 3 mm of a size 25, 0.02 taper RaCe rotary instrument fractured (Fig. 2). Following this event, the patient was informed and the principal author continued to prepare all other canals. The distolingual canal was prepared to an apical size of 35, 0.04 taper and the mesial canals to size 40, 0.04 taper. Prior to filling of the canals, an attempt was made to determine if the fractured RaCe file could be removed conservatively. Initial use of stainless steel Hedström files 8, 10 and 15 revealed that the instrument could be partially bypassed and that it was loose within the root canal. Although the instrument was loosely bound, several attempts at removal with hand files and copious irrigation with 1% sodium hypochlorite were unsuccessful. Following this, the apical 2–3 mm of a size 40, 0.04 taper gutta-percha point (Dentsply Maillefer, Ballaigues, Switzerland) was dipped in chloroform (S.D. Fine Chem, Mumbai, India) for approximately 30 s. The softened gutta-percha was then inserted into the distobuccal canal and allowed to harden for approximately 3 min. The gutta-percha point and fractured instrument were then successfully removed using careful and delicate clockwise and counter clockwise pulling

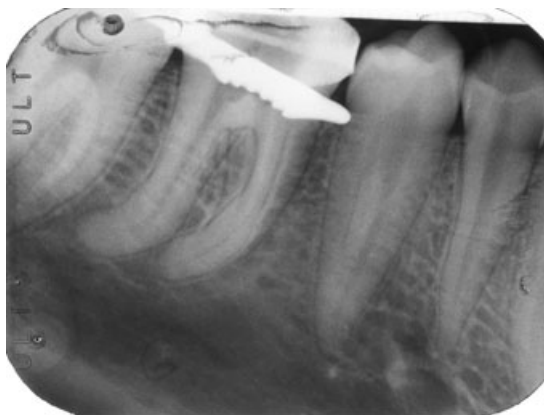

Figure 3 Radiograph showing successful removal of the fractured instrument.




Figure 4 (a) Shows fractured 25/0.02 RaCe rotary file. Microscopic examination of the file tip revealed a sharp break without any accompanying defect indicating a flexural fracture. (b) Shows the chloroform softened texture of a 40/0.04 taper gutta-percha cone with attached fractured instrument at the apical tip. (c) The length of the fractured 25/0.02 RaCe rotary file tip was approximately 3 mm.

action (Figs 3 and 4). The canal was then routinely prepared and all canals filled with lateral compaction of gutta-percha and AH26 (Dentsply®) sealer (Fig. 5).

Discussion

The following factors should be considered when treatment planning a fractured instrument case (Parashos & Messer 2006):

1. Preoperative pulpal and periapical diagnosis
2. Extent of chemo-mechanical debridement prior to instrument breakage
3. Position of the fractured instrument, i.e. is there direct vision and adequate straight line access?

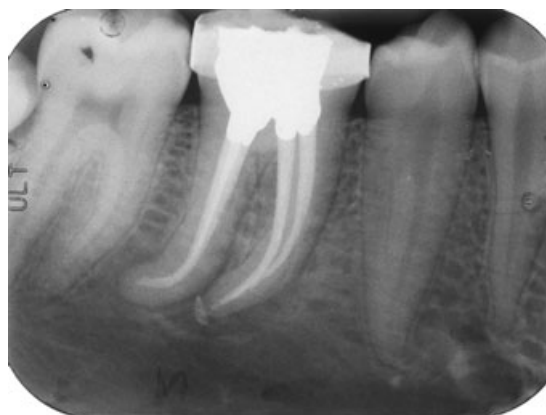

Figure 5 Final result showing completed obturation and placement of an amalgam core through the stainless steel orthodontic band. Tooth to have crown in the near future.

4. Length of fragment
5. Anatomy of the root (thickness, presence of concavities and curvature of the root canal)
6. Can the instrument be bypassed? If yes, bypass it and do not actively attempt removal.

In the case described, many of the above-mentioned criteria were not favourable. Also, the fact that the tooth did not have an obvious periapical lesion and the fracture occurred at a later stage of the chemo-mechanical procedure, one could argue that the instrument could have been left *in situ* without attempting the removal, especially when that would necessitate dentine removal. However, the reasons for attempting removal were that the instrument was easily loosened with hand files and the technique employed was conservative with little or no potential complications. Furthermore, because of the severe curvature the instrument underwent flexural (work hardening and metal fatigue) rather than torsional (instrument winds into canal) type fracture (Fig. 4). This would mean that the instrument may have not been as tightly locked into the canal and hence there was more potential for its removal (Parashos & Messer 2006). The worst possible complication may have been the detachment of the softened portion of the gutta-percha cone. Should this have been the case, careful use of stainless steel files would have most likely resulted in successful retrieval of the separated gutta-percha fragment. In any case, it is unlikely that detachment of the gutta-percha would have affected the overall prognosis.

Most previously described instrument removal techniques such as the Masseran-kit (Masserann 1966), ultrasonics (Chenail & Teplitsky 1985, Souyave *et al.* 1985, Nagai *et al.* 1986, Nehme 1999, Ward *et al.* 2003a,b), use of adhesives such as cyanoacrylate (Coutinho Filho *et al.* 1998), the Canal-Finder system (Hülsmann 1990a,b, 1994), the tube and Hedström technique (Suter 1998) and use of chemical agents such as iodine trichloride (Hülsmann 1993) are not conservative and/or safe options for removal of fractured instruments especially in difficult to access areas of the canal. The use of ultrasonics such as Endosonore (Dentsply Tulsa, Johnson City, TN, USA) stainless steel files with copious irrigation to remove loosened fractured instruments is another conservative technique. However, there is a possibility of excessive dentine removal and fracture of such files in severely curved canals such as the case described here (Souyave *et al.* 1985, Hülsmann 1994). In comparison to the above techniques, the softened gutta-percha removal technique is a conservative technique in that it does not require dentine removal, is simple and quick to perform, and does not require direct vision or straight line access.

Conclusion

This report has described a conservative, safe and plausible technique for removal of loosely fractured instruments in hard to access areas of the canal.

Acknowledgements

The authors thank Drs Angsana Jainan and Thai Yeng for their contributions to this case report.

Disclaimer

Whilst this article has been subjected to Editorial review, the opinions expressed, unless specifically indicated, are those of the author. The views expressed do not necessarily represent best practice, or the views of the IEJ Editorial Board, or of its affiliated Specialist Societies.

References

- Al-Fouzan KS (2003) Incidence of rotary ProFile instrument fracture and the potential for bypassing in vivo. *International Endodontic Journal* **36**, 864–7.
- Ankrum MT, Hartwell GR, Truitt JE (2004) K3 Endo, ProTaper, and ProFile systems: breakage and distortion in severely curved roots of molars. *Journal of Endodontics* **30**, 234–7.
- Chenail BL, Teplitsky PE (1985) Endosonics in curved root canals. *Journal of Endodontics* **11**, 369–74.
- Coutinho Filho T, Krebs RL, Berlinck TC, Galindo RG (1998) Retrieval of a broken endodontic instrument using cyanoacrylate adhesive. Case report. *Brazilian Dental Journal* **9**, 57–60.
- Crump MC, Natkin E (1970) Relationship of broken root canal instruments to endodontic case prognosis: a clinical investigation. *Journal of American Dental Association* **80**, 1341–7.
- Hülsmann M (1990a) Removal of fractured root canal instruments using the Canal Finder System. *Dtsch Zahnärztl Z* **45**, 229–32.
- Hülsmann M (1990b) Removal of silver cones and fractured instruments using the Canal Finder System. *Journal of Endodontics* **16**, 596–600.
- Hülsmann M (1993) Methods for removing metal obstructions from the root canal. *Endodontics and Dental Traumatology* **9**, 223–37.
- Hülsmann M (1994) Removal of fractured instruments using a combined automated/ultrasonic technique. *Journal of Endodontics* **20**, 144–7.
- Masserann J (1966) [The extraction of posts broken deeply in the roots]. *Actual Odontostomatology (Paris)* **75**, 329–42.
- Nagai O, Tani N, Kayaba Y, Kodama S, Osada T (1986) Ultrasonic removal of broken instruments in root canals. *International Endodontic Journal* **19**, 298–304.
- Nehme W (1999) A new approach for the retrieval of broken instruments. *Journal of Endodontics* **25**, 633–5.
- Parashos P, Messer HH (2004) Questionnaire survey on the use of rotary nickel–titanium endodontic instruments by Australian dentists. *International Endodontic Journal* **37**, 249–59.
- Parashos P, Messer HH (2006) Rotary NiTi instrument fracture and its consequences. *Journal of Endodontics* **32**, 1031–43.
- Souter NJ, Messer HH (2005) Complications associated with fractured file removal using an ultrasonic technique. *Journal of Endodontics* **31**, 450–2.
- Souyave LC, Inglis AT, Alcalay M (1985) Removal of fractured endodontic instruments using ultrasonics. *British Dental Journal* **159**, 251–3.
- Spili P, Parashos P, Messer HH (2005) The impact of instrument fracture on outcome of endodontic treatment. *Journal of Endodontics* **31**, 845–50.
- Suter B (1998) A new method for retrieving silver points and separated instruments from root canals. *Journal of Endodontics* **24**, 446–8.

- Suter B, Lussi A, Sequeira P (2005) Probability of removing fractured instruments from root canals. *International Endodontic Journal* **38**, 112–23.
- Ward JR, Parashos P, Messer HH (2003a) Evaluation of an ultrasonic technique to remove fractured rotary nickel–titanium endodontic instruments from root canals: an experimental study. *Journal of Endodontics* **29**, 756–63.
- Ward JR, Parashos P, Messer HH (2003b) Evaluation of an ultrasonic technique to remove fractured rotary nickel–titanium endodontic instruments from root canals: clinical cases. *Journal of Endodontics* **29**, 764–7.

This document is a scanned copy of a printed document. No warranty is given about the accuracy of the copy. Users should refer to the original published version of the material.