

## Use of cone-beam computed tomography to evaluate root and canal morphology of mandibular molars in Chinese individuals

R. Zhang<sup>1</sup>, H. Wang<sup>1</sup>, Y.-Y. Tian<sup>1</sup>, X. Yu<sup>1</sup>, T. Hu<sup>1</sup> & P. M. H. Dummer<sup>2</sup>

<sup>1</sup>State Key Laboratory of Oral Diseases, West China Hospital of Stomatology, Sichuan University, Chengdu, China; and <sup>2</sup>School of Dentistry, Cardiff University, Heath Park, Cardiff, UK

### Abstract

**Zhang R, Wang H, Tian Y-Y, Yu X, Hu T, Dummer PMH.**

Use of cone-beam computed tomography to evaluate root and canal morphology of mandibular molars in Chinese individuals. *International Endodontic Journal*, **44**, 990–999, 2011.

**Aim** To evaluate the root canal configuration of permanent mandibular first and second molar teeth in a Chinese subpopulation using cone-beam computed tomography (CBCT).

**Methodology** Patients who required CBCT radiographic examinations as part of their routine examination, diagnosis and treatment planning, were enrolled. Cases where the anatomy was compromised by physiological or pathological processes and the original root canal morphology was not clear were excluded. A total of 389 healthy, untreated, fully developed mandibular molars in Chinese individuals were included. The following observations were recorded: (i) the number of roots and their morphology; (ii) the number of canals per root; (iii) the canal configuration; (iv) the frequency of distolingual roots in the mandibular first molars and (v) the frequency of C-shaped canals in the mandibular second molars. The root canal configurations were classified according to the method of Vertucci (*Oral Surgery, Oral Medicine, and Oral Pathology* **58**, 1984, 589).

**Results** The majority of mandibular molars (70% of first molars, 76% of second molars) had two separate roots; however, three roots were identified in 29% of first molars. C-shaped roots occurred in 29% of second molars. Three canals were found in 56% of mandibular first molars and 43% had four canals. In the mandibular second molars, 46% had three canals and 38% had two canals. Most distal roots had a simple type I configuration, whereas mesial roots had more complex canal systems, with more than one canal. There were seven variants of the root canal morphology amongst the mandibular first molars and eight variants amongst the mandibular second molars, without considering the various root types.

**Conclusions** Three-rooted mandibular first molars and C-shaped mandibular second molars occurred frequently in this Chinese population. CBCT is an effective tool for the detection of additional distolingual roots and C-shaped roots/canals, and it is a valuable aid for dentists providing root canal treatment.

**Keywords:** cone-beam computed tomography, C-shaped root and canal configuration, distolingual root, mandibular molars, root canal system.

Received 19 April 2011; accepted 14 May 2011

Correspondence: Prof. Tao Hu, West China Hospital of Stomatology, Sichuan University, Chengdu, 610041, China (Tel.: 028 85407723; fax: 028 85582167; e-mail: acomnet@263.net).

### Introduction

The study of root and canal morphology is important not only for endodontic treatment but also for anthropological analyses (Dahlberg 1965, Vertucci 1984, Gulabivala *et al.* 2002). Variations in the root canal

morphology of mandibular molars are thought to be racially and genetically determined (Curzon 1974, Ahmed *et al.* 2007). Therefore, it is necessary to investigate variations in tooth anatomy and their characteristic features in different racial groups (Sperber 1999, Neelakantan *et al.* 2010). Mandibular molars in Chinese populations are more variable than those of others, typically including a high prevalence of distolingual roots in the mandibular first molars and C-shaped canals in the mandibular second molars (Gulabivala *et al.* 2002, Huang *et al.* 2007, 2010, Pattanshettil *et al.* 2008, Fan *et al.* 2009). For example, it has been reported in studies of Chinese populations that 22% of mandibular first molars have a distolingual root (Huang *et al.* 2007, 2010).

In the clinical context, awareness of the presence of a distolingual root in a mandibular first molar is a key to successful root canal treatment and periodontal care (Gulabivala *et al.* 2002, Huang *et al.* 2007), especially in complex cases.

Another reported variation, which has a relatively high prevalence in the mandibular second molars of Chinese and Lebanese populations, but is seldom found in Caucasian populations, is the 'C-shaped root and canal configuration' (Walker 1988, Weine *et al.* 1988, Yang *et al.* 1988, Manning 1990b). On traditional periapical radiographic films, the recognition of C-shaped canals is challenging because of the two-dimensional nature of the images produced, inevitable geometric distortion and anatomical noise.

Staining and clearing are the techniques most commonly used to study root and canal morphology (Pineda & Kuttler 1972, Gulabivala *et al.* 2001, Ng *et al.* 2001, Alavi *et al.* 2002, Awawdeh *et al.* 2008). However, a sufficient sample size is essential in such studies, so that any findings can be applied to the whole population (Gulabivala *et al.* 2001, Wasti *et al.* 2001). It is often difficult to collect sufficient numbers of extracted teeth of known origin for such laboratory-based investigations. Furthermore, most extracted mandibular molars collected are severely compromised, which results in difficulties in determining accurately the tooth notation; an additional negative impact if only sound teeth are selected is selection bias.

*In vivo* studies with operating microscopes (Sempira & Hartwell 2000) and conventional radiography (Omer *et al.* 2004) are undertaken frequently to evaluate tooth anatomy. Previous studies (Tu *et al.* 2007, Schäfer *et al.* 2009) have suggested that three-dimensional radiographic techniques, such as computed

tomography (CT) scans, could offer a more accurate method for these investigations. Recently, cone-beam computed tomography (CBCT) images have been found to be useful and accurate in detecting periapical lesions and assessing root canal morphology (Tsiklakis *et al.* 2005, Nakata *et al.* 2006, Lofthag-Hansen *et al.* 2007, Zhang *et al.* 2011). CBCT has also been used to estimate the inter-orifice distances of root canals in three-rooted mandibular molars in Taiwanese individuals (Tu *et al.* 2009). As an emerging technology in endodontics, CBCT, with its lower radiation and higher resolution than traditional CT scans (Arai *et al.* 2000, Patel 2009, Patel *et al.* 2009), has produced valid root and canal details in three dimensions for diagnosis and prognosis in the context of endodontic therapy (Cotton *et al.* 2007, Matherne *et al.* 2008).

The aims of this study were to identify the root canal morphology of mandibular first and second molars and to explore the distolingual roots of mandibular first molars and the C-shaped canals in Chinese mandibular second molars using CBCT.

## Materials and methods

### Patients

In total, 211 consecutive patients, who were referred to the West China Hospital of Stomatology at Sichuan University, Chengdu, China, between May 2009 and September 2010, were enrolled. The patients included those suffering facial trauma or odontogenic tumours, who required a preoperative assessment for implants or who needed orthodontic treatment for an ectopic impacted tooth. The CBCT images were taken as part of the routine examination, diagnosis and treatment planning of these patients. Understanding and written consent of each patient was obtained, and the study was approved by the Ethics Committee of the West China Hospital. To obtain clear images of the mandibular molar teeth, those teeth with physiological and/or pathological defects were excluded. Teeth were selected according to the following criteria: (i) mandibular permanent molars with no periapical lesions; (ii) no root canal treatment; (iii) no root canals with open apices, resorption or calcification and (iv) the CBCT images of good quality.

### Radiographic techniques

The CBCT images were taken using a 3D Accuitomo Tomograph (Morita, Kyoto, Japan), operating at

80 kV and 5.0 mA, with an exposure time of 17 s. The voxel size was 0.125 mm and the slice thickness was 1.0 mm. The scans were produced according to the manufacturer's recommended protocol. According to the examination requirements, a field of view of 40 × 40 mm or 60 × 60 mm was used. All CBCT exposures were performed by an appropriately licensed radiologist, with the minimum exposure necessary for adequate image quality. The lowest-dose radiation and the smallest field of view were ensured.

### Evaluation of the images

The CBCT images were analysed with the inbuilt software (i-Dixel One Volume Viewer 1.5.0) in a Dell Precision T5400 workstation (Dell, Round Rock, TX, USA), with a 32-inch Dell LCD screen with a resolution of 1280 × 1024 pixels in a darkroom. The contrast and brightness of the images were adjusted using the image processing tool in the software to ensure optimal visualisation. An oral radiologist and an endodontist evaluated concurrently all the images to reach a consensus in the interpretation of the radiographic findings.

The teeth involved were investigated radiographically by CBCT for (i) number of roots and their morphology; (ii) number of canals per root; (iii) root canal configuration (Vertucci 1984); (iv) number of distolingual roots in the mandibular first molars; (v) C-shaped canals in the mandibular second molars and

**Table 1** Distributions and percentages of the seven categories of variants in the root canal anatomy of mandibular first molars

	Variant							Total
	1	2	3	4	5	6	7	
Number	4	2	122	35	5	63	1	232
Percentage	1.7	0.9	52.6	15.1	2.2	27.2	0.4	100

Variant 1: Two separate roots, a mesial and a distal root, with one canal in each root.

Variant 2: Two separate roots, with one canal in the mesial root and two canals in the distal root.

Variant 3: Two separate roots, with two canals in the mesial root and one canal in the distal root.

Variant 4: Two separate roots, with two canals in the mesial root and two canals in the distal root.

Variant 5: Three separate roots, the mesial, distobuccal and distolingual roots, with one canal in each root.

Variant 6: Three separate roots, with two canals in the mesial root and one canal in the distobuccal and distolingual roots.

Variant 7: Four separate roots, the mesiobuccal, mesiolingual, distobuccal and distolingual roots, with one canal in each root.

**Table 2** Distributions and percentages of the eight categories of variants in the root canal anatomy of mandibular second molars

	Variant								Total
	1	3	4	5	6	8	9	10	
Number	50	66	4	1	1	20	10	5	157
Percentage	31.9	42.0	2.6	0.6	0.6	12.7	6.4	3.2	100

Variants 1, 3, 4, 5 and 6 are same as those in Table 1.

Variant 8: One root with one canal in it.

Variant 9: One root with two canals in it.

Variant 10: One root with three canals in it.

(vi) primary variations in the morphology of the root canal systems (Tables 1 and 2):

For the purposes of the study, the type of canal system in each variant was not classified further.

### Results

Of the patients enrolled, 110 were women and 101 were men, with a mean age of 37 years (range 18–57 years). In total, 389 teeth (232 mandibular first molars and 157 mandibular second molars) were analysed.

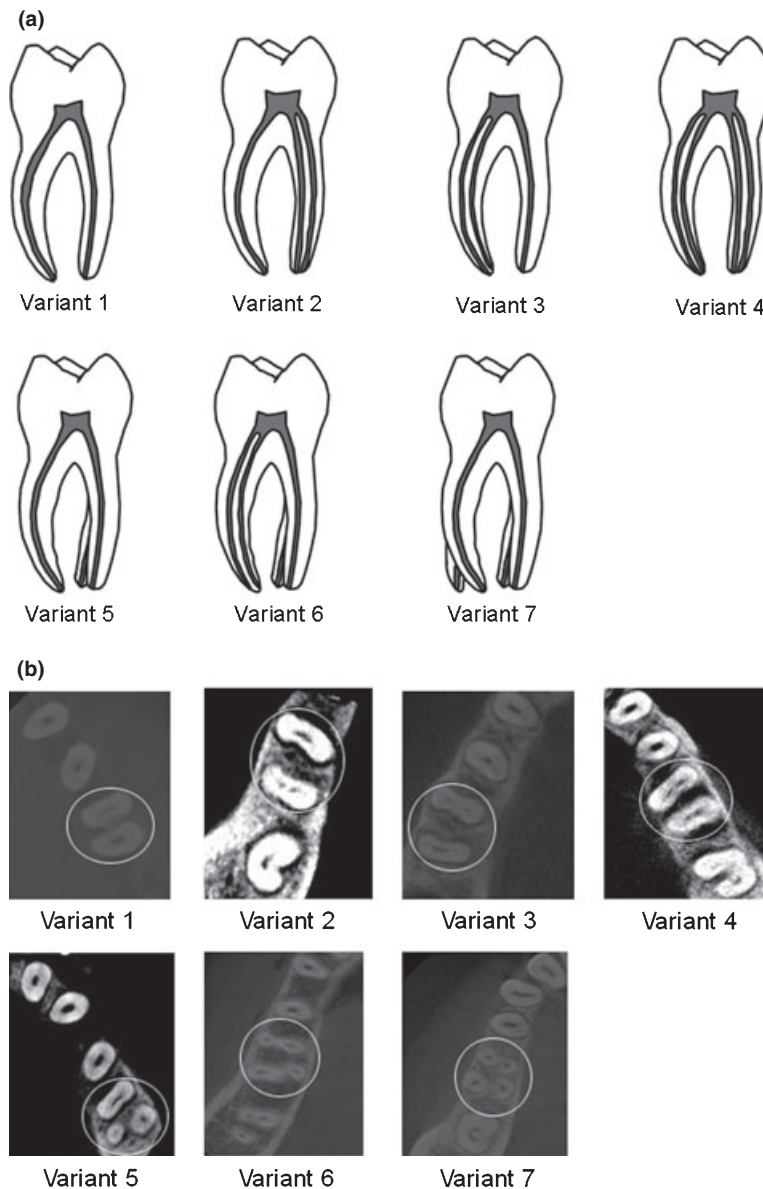
#### Mandibular first molars

The majority (70%) of mandibular first molars had two separate roots, with 29% having three roots; only 1 four-rooted tooth was identified. When a third root was present, it was always on the lingual aspect of the main distal root. In total, 56% of the mandibular first molars had three canals, 43% had four canals and only four teeth had two canals.

Whether there was a distolingual root or not, the majority (84%) of the distal roots had a simple Vertucci type I configuration, whereas the canal system of the mesial roots was more complex. Of the 232 mandibular first molars, 220 (95%) mesial roots contained two canals, amongst which type IV (81%) and type V (15%) were the most prevalent.

Overall, 30% of these teeth had distolingual roots. All of the distolingual roots had the type I configuration. Of the 69 teeth with a distolingual root, 75% of the mesial roots were type IV, followed by type V (6.7%).

There were seven variants (Fig. 1a,b) in the root canal morphology of the mandibular first molars, without considering further the classification in each root. The distributions and percentages of the seven categories of variants in the root canal anatomy of the mandibular first molars are listed in Table 2.



**Figure 1** (a) Illustration showing the categorisation of the seven variants in mandibular first molars. (b) Cone-beam computed tomography images showing the categorisation of the seven variants in mandibular first molars found in this study. The white circles indicate the examined tooth.

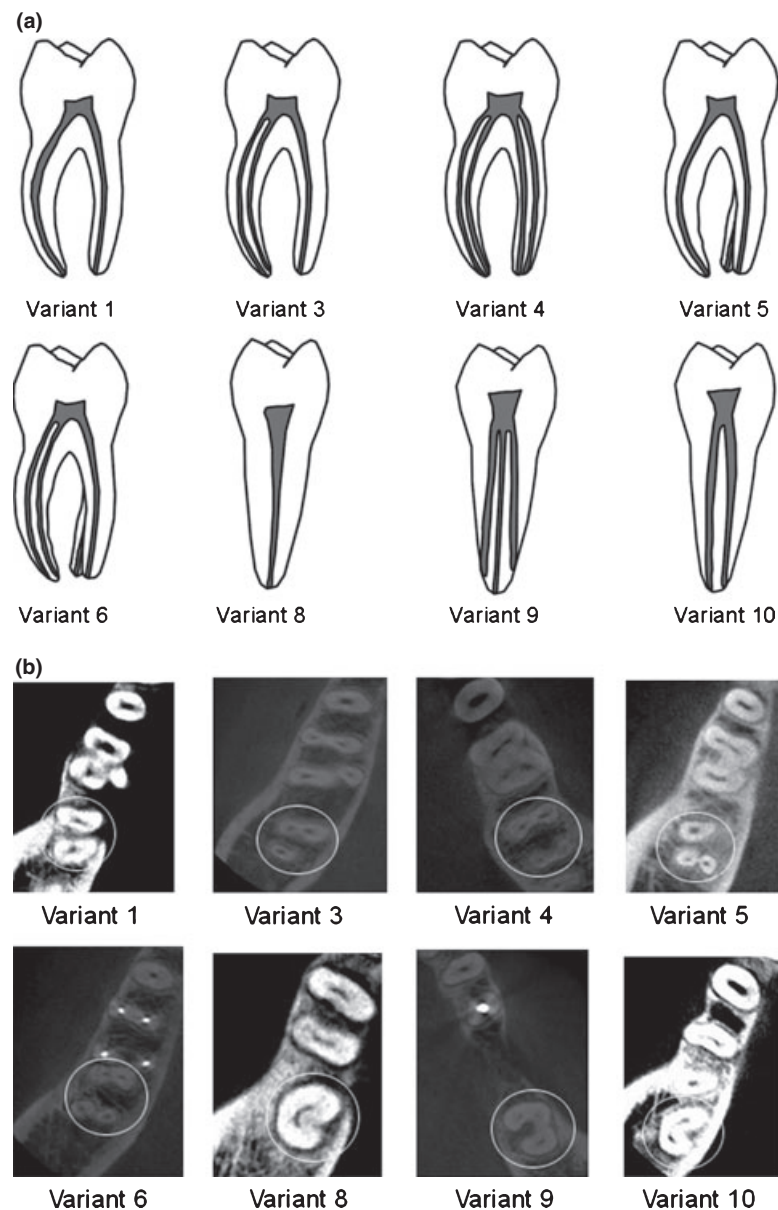
### Mandibular second molars

Most of the mandibular second molars (76%) had two separate roots, whereas 22% had one root. Only 2-second molars in the present study had three roots. The majority of mandibular second molars had three canals (46%) or two canals (38%).

In the two-rooted cases, the majority (97%) of the distal roots had a type I canal morphology, whereas

42% of the mesial roots had type I canal morphology. The majority of mesial roots with two canals had a type IV (65%) configuration, followed by type V (27%).

Of the 157 mandibular second molars, 29% had C-shaped canals. There were eight variants (Fig. 2a,b) in the root canal morphology of the mandibular second molars, without considering further the classification in each root. The distributions and percentages of the



**Figure 2** (a) Illustration showing the categorisation of the eight variants in mandibular second molars. (b) Cone-beam computed tomography images showing the categorisation of the eight variants in mandibular second molars found in this study. The white circles indicate the examined tooth.

eight categories of variants in the root canal anatomy of the mandibular second molars are listed in Table 2.

## Discussion

The patients who were enrolled in this study required the CBCT examination for valid diagnostic or treatment reasons, including for ectopic impacted teeth and pre-

implant evaluation of bone mass. For such cases, the traditional CT examination would have led to a higher radiation dose, so CBCT was a reasonable alternative. From these cases, images that had mandibular molars were selected for the present study. Several factors will affect evaluation of the morphology of root canals including:

- canal obliteration and internal resorption;



- filling materials that will create noise (artefacts) on the CBCT images;
- long-term periapical disease that may result in resorption and destroy root apices.

In the present study, to ensure the integrity of the original morphology of the root canals, only mandibular molar teeth that were healthy, fully developed and untreated were included.

### Mandibular first molars

The presence of a third root is a typical variation in Chinese mandibular first molars. The high prevalence (29%) of third roots in the present study is consistent with the previous studies (Huang *et al.* 2007, 2010), which reported a slightly lower percentage (22%) in a Chinese subpopulation in Taiwan. This is higher than the 13% reported for a Thai population (Gulabivala *et al.* 2002) and the 10% reported for a Burmese population (Gulabivala *et al.* 2001), using a canal staining and clearing technique. The incidence of the extra distolingual roots in the Caucasian population is not more than 5% (Curzon 1973, 1974, Vertucci & Williams 1974, Schäfer *et al.* 2009). These differences may reflect race-based variations. The predominance of two roots and three canals (54%) in Chinese mandibular first molars is, in general, similar to the observations of Huang *et al.* (2007, 2010).

Generally, the third root was located on the lingual side of the distal aspect of the tooth as shown in Fig. 3, which is consistent with the results of Walker (1988) and Gulabivala *et al.* (2002). Those authors identified the distolingual root in the mandibular first molars and proposed that it should not be considered a developmental anomaly, but rather a genetic trait. This differs from a previous study (Sperber & Moreau 1998) that reported a third root on the buccal aspect.

On conventional periapical radiographic images, it is difficult to identify the presence of a distolingual root on a mandibular molar, especially when the distal roots overlap to give the illusion of one root. Therefore, it is important to suspect a second distal root in Chinese patients and, in addition, it is advisable to search for additional orifice when the initial preparation and debridement of the pulp chamber has been completed.

All of the distal roots were classified as Vertucci type I. The high prevalence of the Vertucci type I canal configuration in the distal canals is consistent with the previous observations in Chinese populations (Gulabivala *et al.* 2001). However, the mesial roots were more variable, with 12 type I, 5 type II, 5 type III, 177 type

IV, 32 type V and 1 type VII roots. The mesial roots displayed great variation in canal configuration, consistent with other studies (Barker *et al.* 1974, Vertucci 1984). In teeth with distolingual roots, 70% of the mesial roots had a type IV configuration, and in these teeth, the majority of mesial canals ended in separate foramina. The presence of a distolingual root was associated with variability in the root morphology, including the number of roots, the number of canals per root and the root types.

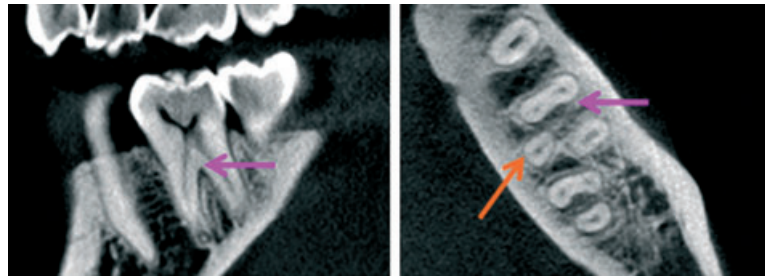
Interestingly, a mandibular first molar with four roots and one separate canal in each root was identified along with four mandibular first molars with two separate canals in two roots. Other variations in the root canal morphology of the mandibular first molar are possible (Sperber & Moreau 1998, Chen *et al.* 2009), and particular attention must be paid to this during treatment.

### Mandibular second molars

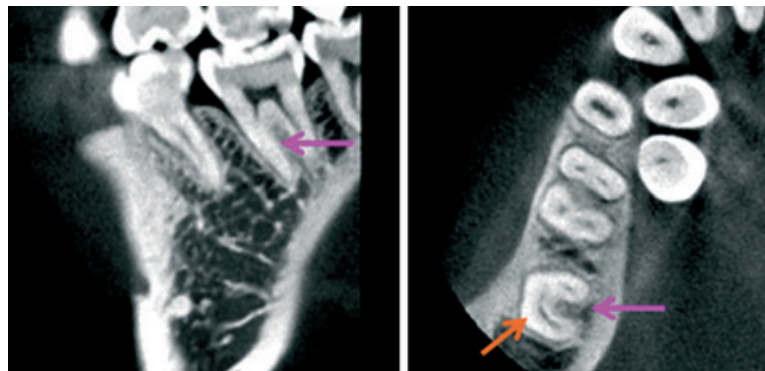
The prevalence of two-rooted second molars was higher than those reported for other populations (Weine *et al.* 1988, Manning 1990a, Gulabivala *et al.* 2001, 2002, Ahmed *et al.* 2007). In the present study, 29% of mandibular second molars had C-shaped canals, consistent with the previous studies of the root canal anatomy of mandibular second molars in Japanese, Chinese and Hong Kong Chinese populations (Yang *et al.* 1988, Huang *et al.* 2010), in which high prevalences of C-shaped roots and canals (14%–52%) were reported. In the present study, the prevalence of 29% in Chinese mandibular second molars falls within the range previously reported, although it is a little higher than some (Huang *et al.* 2007, 2010, Tu *et al.* 2007, 2009). C-shaped root and canal configurations were seldom found in Caucasian populations (Vertucci 1984).

Research into root and canal morphology of mandibular second molars is important in tracing the racial origins of populations. The most common morphology is the two-rooted tooth, with type IV and type I canal systems predominating in the mesial and distal roots, respectively, as shown in Fig. 4. This has been reported as a Mongoloid trait (Gulabivala *et al.* 2002).

The C-shaped root canal configuration is considered to be complex (Vertucci & Williams 1974, Loh 1990). The present investigation revealed that 57%, 29% and 14% of the C-shaped roots had a single canal, two canals and three canals, respectively. The C-shaped roots showed wide variations in their canal



**Figure 3** Cross-sectional cone-beam computed tomography image of a mandibular first molar with a clearly distinguishable distolingual root. The purple arrows denote the mandibular first molar and the orange arrows denote the distolingual root.



**Figure 4** Cross-sectional cone-beam computed tomography image of a mandibular second molar with a clearly distinguishable C-shaped canal. The purple arrows denote the mandibular second molar and the orange arrows denote the C-shaped canal.

configurations, consistent with other reports (Vertucci & Williams 1974, Loh 1990, Gulabivala *et al.* 2001, 2002, Song *et al.* 2010). The high incidence of lateral canals, transverse anastomoses, apical deltas and irregularities associated with C-shaped canals makes it difficult to shape, clean and fill the root canal system (Melton *et al.* 1991).

C-shaped roots may appear as a single, fused root or as two distinct roots with a communication. Clinically, C-shaped root canals have often, but not always, been recognized because of the C-shaped canal orifice (Yang *et al.* 1988). However, CBCT can provide an accurate image with which the dentist can evaluate the entire canal system, which may assist the endodontic management of C-shaped roots.

### Clinical significance

It is difficult to detect the third roots of mandibular molars with conventional radiography because the images of the roots overlap and the roots themselves are narrow. Moreover, branching of the canals may not

be obvious, especially if they are fine. An angled view (vertically and horizontally) may be helpful (Cooke & Cox 1979), but achieving such a view is often difficult. If adjacent teeth, restorations or implants are present, there is even more overlap, reducing the clarity of the radiographic image. When root canal treatment is considered, special attention to the extra distolingual roots is necessary, especially when they are smaller than the other roots and are curved (Vertucci *et al.* 2006). Clearly, the failure to locate and negotiate the narrow additional distolingual canal may result in treatment failure (Gulabivala *et al.* 2002).

When C-shaped canals are visualized on preoperative radiographs (Grocholewicz *et al.* 2009), it is possible to debride and fill the system. However, the radiographic appearances of C-shaped roots in mandibular second molars can be diverse, depending on the exact nature and orientation of the root. It may appear as a single, fused root or as two distinct roots with a communication. When it appears as two distinct roots with a communication, the C-shaped canal may not be easily recognized on conventional periapical films (Huang

et al. 2010). Although Cooke & Cox (1979) considered it impossible to diagnose a C-shaped canal, CBCT now makes this more predictable (Fig. 4). C-shaped root and canal configurations are challenging in terms of diagnosis, instrumentation and filling. They present a complex and irregular space containing potentially infected soft-tissue remnants or debris that may escape normal cleaning and filling procedures, especially when the C-shaped orifice does not continue to the apical third of the root (Cooke & Cox 1979, Barril et al. 1989, Jerome 1994, Jafarzadeh & Wu 2007). Proper management and additional effort are required to accomplish a successful root canal treatment.

Various techniques have been adopted to evaluate canal morphology, and it has been reported that the most detailed information can be obtained following demineralization and staining of extracted teeth (Vertucci 1984, Neaverth et al. 1987, Sieraski et al. 1989). However, clinically, CBCT is a good option because it can detect most distolingual roots and C-shaped canals, and it is regarded as an excellent method for the three-dimensional evaluation of root canal morphology. Examination of the fine details, together with the Vertucci classification (Vertucci 1984), can be taken into consideration. The quality of CBCT is sufficiently high to visualize root canal morphology for clinical endodontic treatment.

Although the present study indicates that CBCT is helpful for the investigation of root canal morphology and the final root filling, over-exposure to radiation is a risk. In simple cases, when root canal assessment is possible from traditional periapical images or clinical procedures, the use of CBCT is unnecessary. When there are abnormal findings on traditional periapical films and/or variations detected with magnification in the clinical setting, it may be impossible to evaluate the root canal system effectively. In these situations, it is necessary and sensible to adopt CBCT for further diagnosis, whilst at the same time ensuring that the patients' exposure to radiation is kept as low as possible.

## Conclusions

The root and canal anatomy of 389 Chinese mandibular molars was investigated using CBCT. Three-rooted mandibular first molars occurred in 29% of cases and C-shaped roots in mandibular second molars 29% of cases. There were seven variants in the root canal morphology of mandibular first molars and eight variants in mandibular second molars. CBCT is a potentially effective tool in the detection of distolingual

roots and C-shaped roots/canals for radiographic evaluation during root canal treatment.

## Acknowledgements

This work was supported by the Key Clinical Program of the Ministry of Health of China. The funders had no role in study design, data collection and analysis, decision to publish or preparation of the manuscript. We thank Li Liu, Guo Li and Yuanyuan Liu for their help with the acquisition of the raw data.

## References

- Ahmed HA, Abu-bakr NH, Yahia NA, Ibrahim YE (2007) Root and canal morphology of permanent mandibular molars in a Sudanese population. *International Endodontic Journal* **40**, 766–771.
- Alavi AM, Opananon A, Ng YL, Gulabivala K (2002) Root and canal morphology of Thai maxillary molars. *International Endodontic Journal* **35**, 478–85.
- Arai Y, Tammisalo E, Iwai K, Hashimoto K, Shinoda K (2000) Fundamental efficiency of limited cone-beam X-ray CT (3DX multi image micro CT) for practical use. *Dental Radiology* **40**, 145–54.
- Awawdeh L, Abdullah H, Al-Qudah A (2008) Root form and canal morphology of Jordanian maxillary first premolars. *Journal of Endodontics* **34**, 956–61.
- Barker BCW, Parson KC, Mills PR, Williams GL (1974) Anatomy of root canals. III. Permanent mandibular molars. *Australian Dental Journal* **19**, 408–13.
- Barril I, Cochet JY, Ricci C (1989) Treatment of a canal with a “C” configuration. *Revue Francaise D Endodontie* **8**, 47–58.
- Chen G, Yao H, Tong C (2009) Investigation of the root canal configuration of mandibular first molars in a Taiwan Chinese population. *International Endodontic Journal* **42**, 1044–9.
- Cooke HG III, Cox FL (1979) C-shaped canal configurations in mandibular molars. *Journal of the American Dental Association* **99**, 836–9.
- Cotton TP, Geisler TM, Holden DT, Schwartz SA, Schindler WG (2007) Endodontic applications of cone-beam volumetric tomography. *Journal of Endodontics* **33**, 1121–32.
- Curzon MEJ (1973) Three-rooted mandibular permanent molars in English Caucasians. *Journal of Dental Research* **52**, 181.
- Curzon MEJ (1974) Miscegenation and the prevalence of three-rooted mandibular first molars in the Baffin Eskimo. *Community Dentistry and Oral Epidemiology* **2**, 130–1.
- Dahlberg A (1965) Geographic distribution and origin of dentitions. *International Dental Journal* **15**, 348–55.
- Fan B, Min Y, Lu G, Yang J, Cheung GS, Gutmann JL (2009) Negotiation of C-shaped canal systems in mandibular second molars. *Journal of Endodontics* **35**, 1003–8.



- Grocholewicz K, Lipski M, Weyna E (2009) Endodontic and prosthetic treatment of teeth with C-shaped root canals. *Annales Academiae Medicae Stetinensis* **55**, 55–9.
- Gulabivala K, Aung TH, Alavi A, Ng YL (2001) Root and canal morphology of Burmese mandibular molars. *International Endodontic Journal* **34**, 359–70.
- Gulabivala K, Opananon A, Ng YL, Alavi A (2002) Root and canal morphology of Thai mandibular molars. *International Endodontic Journal* **35**, 56–62.
- Huang RY, Lin CD, Lee MS et al. (2007) Mandibular distolingual root: a consideration in periodontal therapy. *Journal of Periodontology* **78**, 1485–90.
- Huang RY, Cheng WC, Chen CJ et al. (2010) Three-dimensional analysis of the root morphology of mandibular first molars with distolingual roots. *International Endodontic Journal* **43**, 478–84.
- Jafarzadeh H, Wu YN (2007) The C-shaped root canal configuration: a review. *Journal of Endodontics* **33**, 517–23.
- Jerome CE (1994) C-shaped root canal systems: diagnosis, treatment, and restoration. *General Dentistry* **42**, 424–7.
- Lofthag-Hansen S, Huuomonen S, Gröndahl K, Gröndahl HG (2007) Limited cone-beam CT and intraoral radiography for the diagnosis of periapical pathology. *Oral Surgery Oral Medicine, Oral Pathology, Oral Radiology, and Endodontology* **103**, 114–9.
- Loh HS (1990) Incidence and features of three-rooted permanent mandibular molars. *Australian Dental Journal* **35**, 434–7.
- Manning SA (1990a) Root canal anatomy of mandibular second molars. Part I. *International Endodontic Journal* **23**, 34–9.
- Manning SA (1990b) Root canal anatomy of mandibular second molars. Part II. C-shaped canals. *International Endodontic Journal* **23**, 40–5.
- Matherne RP, Angelopoulos C, Kulild JC, Tira D (2008) Use of cone-beam computed tomography to identify root canal systems in vitro. *Journal of Endodontics* **34**, 87–9.
- Melton DC, Krell KV, Fuller MW (1991) Anatomical and histological features of C-shaped canals in mandibular second molars. *Journal of Endodontics* **17**, 384–8.
- Nakata K, Naitoh M, Izumi M, Inamoto K, Arijii E, Nakamura H (2006) Effectiveness of dental computed tomography in diagnostic imaging of periradicular lesion of each root of a multirrooted tooth: a case report. *Journal of Endodontics* **32**, 583–7.
- Neaverth EJ, Kotler ML, Kaltenbach RF (1987) Clinical investigation (in vivo) of endodontically treated maxillary first molars. *Journal of Endodontics* **13**, 506–12.
- Neelakantan P, Subbarao C, Subbarao CV, Ravindranath M (2010) Root and canal morphology of mandibular second molars in an Indian population. *Journal of Endodontics* **36**, 1319–22.
- Ng YL, Aung TH, Alavi A, Gulabivala K (2001) Root and canal morphology of Burmese maxillary molars. *International Endodontic Journal* **34**, 620–30.
- Omer OE, Al Shalabi RM, Jennings M, Glennon J, Claffey NM (2004) A comparison between clearing and radiographic techniques in the study of the root-canal anatomy of maxillary first and second molars. *International Endodontic Journal* **37**, 291–6.
- Patel S (2009) New dimensions in endodontic imaging: part 2. Cone beam computed tomography. *International Endodontic Journal* **42**, 463–75.
- Patel S, Dawood A, Wilson R, Horner K, Mannocci F (2009) The detection and management of root resorption lesions using intraoral radiography and cone beam computed tomography: an in vivo investigation. *International Endodontic Journal* **42**, 831–8.
- Pattanshettil N, Gaidhanel M, Kandari AM (2008) Root and canal morphology of the mesiobuccal and distal roots of permanent first molars in a Kuwait population—a clinical study. *International Endodontic Journal* **41**, 755–62.
- Pineda F, Kuttler Y (1972) Mesiodistal and buccolingual roentgenographic investigation of 7275 root canals. *Oral Surgery, Oral Medicine, and Oral Pathology* **33**, 101–10.
- Schäfer E, Breuer D, Janzen S (2009) The prevalence of three-rooted mandibular permanent first molars in a German population. *Journal of Endodontics* **35**, 202–5.
- Sempira HN, Hartwell GR (2000) Frequency of second mesiobuccal canals in maxillary molars as determined by use of an operating microscope: a clinical study. *Journal of Endodontics* **26**, 673–4.
- Sieraski SM, Taylor GN, Khon RA (1989) Identification and endodontic management of three-canal maxillary premolars. *Journal of Endodontics* **15**, 29–32.
- Song JS, Choi HJ, Jung IY, Jung HS, Kim SO (2010) The prevalence and morphologic classification of distolingual roots in the mandibular molars in a Korean population. *Journal of Endodontics* **36**, 653–7.
- Sperber GH (1999) The phylogeny and odontogeny of dental morphology. In: Sperber GH, ed. *From Apes to Angels*. New York: Wiley-Liss, pp. 215–9.
- Sperber GH, Moreau JL (1998) Study of the number of roots and canals in Senegalese first permanent mandibular molars. *International Endodontic Journal* **31**, 117–22.
- Tsiklakis K, Donta C, Gavala S, Karayianni K, Kamenopoulou V, Hourdakis CJ (2005) Dose reduction in maxillofacial imaging using low dose Cone Beam CT. *European Journal of Radiology* **56**, 413–7.
- Tu MG, Tsai CC, Jou MJ et al. (2007) Prevalence of three-rooted mandibular first molars among Taiwanese individuals. *Journal of Endodontics* **33**, 1163–6.
- Tu MG, Huang HL, Hsue SS et al. (2009) Detection of permanent three-rooted mandibular first molars by cone-beam computed tomography imaging in Taiwanese individuals. *Journal of Endodontics* **35**, 503–7.
- Vertucci FJ (1984) Root canal anatomy of the human permanent teeth. *Oral Surgery, Oral Medicine, and Oral Pathology* **58**, 589–99.

- Vertucci FJ, Williams RG (1974) Root canal anatomy of mandibular first molar. *Journal of the New Jersey Dental Association* **45**, 27–8.
- Vertucci FJ, Haddix JE, Britto LR (2006) Tooth morphology and access cavity preparation. In: Cohen S, Hargreaves KM, eds. *Pathways of the Pulp*, 9th edn. St Louis: CV Mosby, pp. 149–232.
- Walker RT (1988) Root form and canal anatomy of mandibular second molars in a Southern Chinese population. *Journal of Endodontics* **14**, 325–9.
- Wasti F, Shearer AC, Wilson NHF (2001) Root canal systems of the mandibular and maxillary first permanent molar teeth of South Asian Pakistanis. *International Endodontic Journal* **34**, 263–6.
- Weine FS, Pasiewicz RA, Rice RT (1988) Canal configuration of the mandibular second molar using a clinically oriented *in vitro* method. *Journal of Endodontics* **14**, 207–13.
- Yang ZP, Yang SF, Lin YC, Shay JC, Chi CY (1988) C-shaped root canals in mandibular second molars in a Chinese population. *Endodontics and Dental Traumatology* **4**, 160–3.
- Zhang R, Yang H, Yu X, Wang H, Hu T, Dummer PMH (2011) Use of CBCT to identify the morphology of maxillary permanent molar teeth in a Chinese subpopulation. *International Endodontic Journal* **44**, 162–9.

This document is a scanned copy of a printed document. No warranty is given about the accuracy of the copy. Users should refer to the original published version of the material.